



# Effect of mouse nerve growth factor combined with the exposure of the external branch of superior laryngeal nerve on voice changes after thyroidectomy: a prospective non-randomized controlled trial

Jiaoping Zhang<sup>1</sup>, Wo Zhang<sup>2</sup>, You Peng<sup>1</sup>, Li Sun<sup>1</sup>, Min Wang<sup>3</sup>

<sup>1</sup>Department of Surgical Oncology, Affiliated Hangzhou First People's Hospital, Zhejiang University School of Medicine, Hangzhou, China;

<sup>2</sup>Department of Thyroid Surgery, Zhejiang Provincial Hospital of Chinese Medicine, Hangzhou, China; <sup>3</sup>Hangzhou Emergency Center, Hangzhou, China

*Contributions:* (I) Conception and design: J Zhang, M Wang; (II) Administrative support: Y Peng; (III) Provision of study materials or patients: L Sun; (IV) Collection and assembly of data: W Zhang; (V) Data analysis and interpretation: L Sun; (VI) Manuscript writing: All authors; (VII) Final approval of manuscript: All authors.

*Correspondence to:* Min Wang. Hangzhou Emergency Center, Hangzhou, China. Email: 15805710558@163.com.

**Background:** The superior laryngeal nerve (SLN) injury may also affect vocal fold function and voice quality. It is efficient yet simple approach to expose the external branch of the superior laryngeal nerve (EBSLN). Neurotrophic agent mouse nerve growth factor (mNGF) to treat patients after thyroid surgery, and found it had significant efficacy in improving the voice of patients. However, the potential effectiveness and safety of mNGF combined with EBSLN were unclear.

**Methods:** In this study, 96 patients who suffered from hoarseness after thyroidectomy at Hangzhou First People's Hospital between January 2018 and October 2019 were screened and divided into the control group and the observation group by patients' choice. In the control group, the SLN was not exposed. In the observation group, the SLN was exposed. The mNGF treatment was administered for observation group once a day at 20 µg each time for 4 weeks. The data of acoustic voice indicators was analysis by univariate analyses. Patients in both groups were followed up for more than 6 months. The rate of SLN damage was compared between two groups.

**Results:** The baseline clinical characteristics of the two groups showed no statistic difference. The results showed that the fundamental frequency was significantly lower 1 month after surgery than 3 days after surgery in both groups. The fundamental frequency perturbation, shimmer, maximum phonation time, highest fundamental frequency, and dysphonia severity index in 1 month after surgery were significantly higher than they were 3 days after surgery (all  $P < 0.001$ ). There was no significant difference in the postoperative harmonic-to-noise ratio between the 2 groups ( $P = 0.426$ ).

**Conclusions:** MNGF combined with the exposure and protection of the EBSLN effectively may prevent voice damage after thyroid surgery.

**Keywords:** Thyroid; surgery; mouse nerve growth factor (mNGF); external branch of the superior laryngeal nerve (EBSLN); voice

Submitted Nov 04, 2022. Accepted for publication Dec 16, 2022.

doi: 10.21037/gs-22-703

**View this article at:** <https://dx.doi.org/10.21037/gs-22-703>

## Introduction

Thyroidectomy is currently a routine surgical procedure for thyroid diseases, such as nodular goitre, follicular adenoma, and thyroid cancer, which has good effects. However, postoperative complications such as dyspnoea, and especially hoarseness seriously affect the life and work of patients (1-3). An abnormal voice after thyroidectomy mainly manifests as hoarseness. It is mainly related to anatomical and functional abnormalities of the recurrent laryngeal nerve (RLN) and the superior laryngeal nerve (SLN) (4). Due to the application of intraoperative nerve monitoring (IONM), the ability of surgeons to protect the RLN has greatly improved (5).

Traditionally, voice changes after thyroidectomy were attributed to iatrogenic RLN injury. However, Holler found that some patients still experienced voice abnormalities after surgery, even if their RLN was not injured during thyroidectomy (6).

SLN injury may also affect vocal fold function and voice quality. Fibrosis, vascular changes, injury of the external branch of the SLN, and psychosocial reactions have been implicated in the etiology of this syndrome. It is efficient yet simple approach to expose the external branch of the superior laryngeal nerve (EBSLN) (7). However, remains as to whether it is necessary to routinely expose the SLN during thyroid surgery concerning collateral tissue damage (8,9).

We also used the neurotrophic agent mouse nerve growth factor (mNGF) to treat patients after thyroid

surgery, and found it had significant efficacy in improving the voice of patients. However, the potential effectiveness and safety of mNGF combined with EBSLN were unclear. In this prospective study, we applied IONM to routinely expose the EBSLN during thyroid surgery. We further explored the possible of mNGF combined with EBSLN pathways of action. We present the following article in accordance with the TREND reporting checklist (available at <https://gs.amegroups.com/article/view/10.21037/gS-22-703/rc>).

## Methods

### Patients

Patients who underwent thyroid surgery at Hangzhou First People's Hospital between January 2018 and October 2019 were screened. The patients enrolled in this study were strictly selected according to the inclusion and exclusion criteria. To be eligible for inclusion in this study, patients had to meet the following inclusion criteria: (I) suffer from hoarseness after thyroid surgery; (II) be aged 18 to 70 years; (III) have no hoarseness, difficulty vocalizing, or limited vocal cord movement before surgery; (IV) have no vocal cord paralysis or cricoarytenoid joint dislocation on postoperative laryngoscopy; (V) have no history of neck surgery or trauma, no history of neck radiation, and no congenital vocal cord or laryngeal developmental abnormalities; and (VI) have no history of throat inflammation, vocal cord nodules, polyps, or tumours in the past 3 months. Patients were excluded from the study if they met any of the following exclusion criteria: (I) had a severe allergic reaction to the treatment drugs in this study; (II) had undergone an intraoperative transection of the RLN; and/or (III) had experienced significant nerve clamping, traction, or thermal injury during the surgery. The study was conducted in accordance with the Declaration of Helsinki (as revised in 2013). The study was approved by the Ethics Committee of Hangzhou First People's Hospital [ID:2018(008)-01]. Informed consent was taken from all the patients. The screening process is shown in *Figure 1*.

### Treatment methods

Allocation to groups was done by patients' choice (non-randomized). In the control group, the EBSLN was not exposed. When the cricothyroid interval was entered, the

### Highlight box

#### Key findings

- We found mNGF combined with the exposure and protection of the EBSLN effectively may prevent voice damage after thyroid surgery.

#### What is known and what is new?

- SLN injury may also affect vocal fold function and voice quality. And mNGF was applied to nerve nutrition. But it is little known about the effect of mNGF combined with the exposure and protection of the EBSLN on patients after thyroid surgery.
- Ninety-six patients were included in our study. The mNGF combined with the exposure and protection of the EBSLN as intervention was applied in different two groups.

#### What is the implication, and what should change now?

- The mNGF combined with the exposure and protection of the EBSLN may prevent voice injury and it is worthy of promotion in clinical practice.

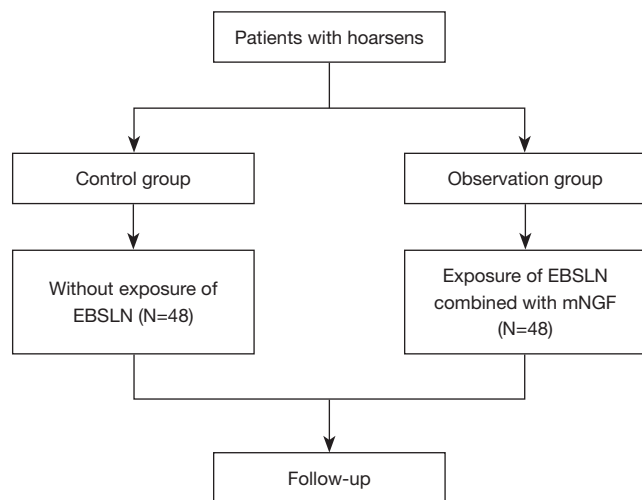
vessels were ligated at the superior pole of the thyroid, and the EBSLN was not routinely identified or exposed. In the observation group, the following 4-step process was used to monitor and expose the EBSLN: (I) an electrode was used to directly stimulate the surface of the cricothyroid muscle to observe the contraction morphology of the cricothyroid muscle to confirm the normal function of the entire neuromonitoring system before the blood vessels of the superior pole of the thyroid were ligated; (II) the surface of the vascular connective tissue above the superior pole of the thyroid was stimulated with an electrode at 1–2 mA, and the contraction of the cricothyroid muscle was observed to find and locate the course of the EBSLN; (III) the superior pole thyroid vessels were separated and clamped at a point away from the path of the EBSLN where electrode stimulation confirmed the absence of cricothyroid muscle contractile activity (see *Figure 2*), the nerve above the clamp point was re-stimulated to observe whether there was cricothyroid

muscle contractile activity, and after confirming normal nerve function, the vessels of the superior pole of the thyroid were dissected; and (IV) after the superior pole blood vessels were processed, electrodes were used to re-stimulate the EBSLN to confirm the integrity of the nerve function.

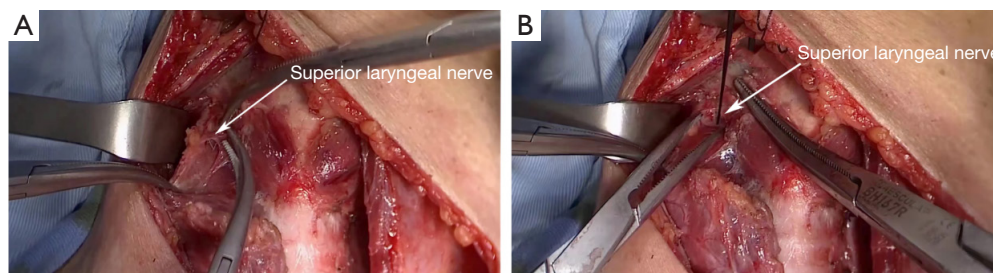
On the 3rd day after surgery, 20 µg of mNGF (Wuhan Hiteck Biopharmaceutical Co., Ltd., China; approval number: GYZZ S20060051), dissolved in 2 mL of water, was injected in the gluteus maximus, and then administered once a day for 4 weeks of continuous treatment. The same group of surgeons performed all the operations to exclude any interference from different surgical procedures.

### Analysis of acoustic voice indicators

DiVAS 2.5 voice analysis software (Germany) was used in the examination room, which had an environmental noise of <45 dB. The patient wore a head-mounted microphone, and the acoustic signal was detected by the microphone. The mouth was kept about 10 cm from the microphone. The patient was instructed to relax, breathe calmly, and pronounce the long vowel sound /a:/ with a natural tone and intensity for >3 seconds. The maximum phonation time (MPT), vocal range, fundamental frequency (F0), fundamental frequency perturbation (jitter), highest fundamental frequency (F0-High), fundamental frequency standard deviation (F0SD), amplitude perturbation (shimmer), lowest sound intensity (I-Low), sonogram (fast Fourier transform), normalized noise energy (NNE), harmonic-to-noise ratio (HNR), and signal-to-noise ratio (SNR) were tested to calculate the dysphonia severity index (DSI). Three consecutive measurements were performed, and those with the strongest and most stable signal were selected for analysis. DSI was calculated using the following regression equation:  $DSI = 0.13 \times MPT (s) + 0.0053 \times F0\text{-high (Hz)} - 0.26 \times I\text{-low (dB)} - 1.18 \times \text{jitter (\%)} + 12.4 (10)$ .



**Figure 1** Screening flowchart. EBSLN, external branch of the superior laryngeal nerve; mNGF, mouse nerve growth factor.



**Figure 2** Process by which the EBSLN was exposed. EBSLN, external branch of the superior laryngeal nerve.

### Follow-up methods

Cricothyroid muscle electromyogram (EMG) was performed during surgery. The EMG signals were loss, which was defined as temporary SLN injury. We assessed postoperative hoarseness as “a patient-assessed change in voice quality”. A postoperative laryngeal examination was performed after surgery if a patient presented with subjective voice or swallowing complaints. Patients in both groups were followed up for more than 6 months.

### Statistical analysis

SPSS 22.0 software was used to analyse the data in this study. The measurement data are expressed as the mean  $\pm$  standard deviation. The paired-sample *t*-test was used for the intragroup comparisons, and the independent-sample *t*-test was used for the intergroup comparisons. The count data are described as the percentage, and the chi-squared test was used to compare the count data. A *P* value  $<0.05$  indicated a statistically significant difference.

## Results

### Comparison of the baseline data

A total of 96 patients were enrolled in this study. In the control group, there were 12 males and 36 females with an average age of  $37.59 \pm 5.72$  years. In the experimental group, there were 10 males and 38 females with an average age of  $37.30 \pm 5.91$  years. For the 48 patients undergoing thyroid surgery in the observation group, we used neuromonitoring equipment to help find the EBSLN, and successfully found the exposed EBSLNs in 48 patients (48 EBSLNs) with a success rate of 100%. The acoustic voice conditions were detected on the second day after surgery. There was no significant difference in the baseline data between the 2 groups ( $P > 0.05$ , *Table 1*).

### Acoustic voice analysis of the 2 groups

An acoustic voice analysis was performed on the enrolled patients 1 month after surgery. The results showed that the F0 was significantly lower 1 month after surgery than 3 days after surgery in both groups. The jitter, shimmer, MPT, F0SD, and DSI in 1 month after surgery were significantly higher than they were 3 days after surgery ( $P < 0.001$ ).

We then compared the observation group and the control group, and found that the F0, jitter, shimmer, MPT, F0SD,

and DSI of the observation group at 1 month after surgery differed significantly to those of the control group ( $P < 0.001$ ). However, there was no significant difference in postoperative HNR between the 2 groups ( $P = 0.426$ ) (*Table 2*).

### Follow-up results of the 2 groups

According to the EMG records, 8 EBSLN palsy occurred in the 2 groups with an incidence rate of 8.33%, of which 6 occurred in the control group and 2 occurred in the observation group. There was no significant difference in the incidence of EBSLN injury between the 2 groups ( $P = 0.268$ ). There was no loss to follow-up, and the median follow-up time was 6.8 months. All EBSLN paralysis was temporary and returned to normal during follow-up (*Table 3*).

## Discussion

EBSLN injury is a common complication of thyroid surgery, with an injury rate of 1% to 14% (11). EBSLN injury can cause primary cricothyroid muscle paralysis, hoarseness, and decreased sound frequency. The SLN is a branch of the vagus nerve that descends along the pharyngeal side and is divided into an internal branch and an external branch at the level of the greater horn of the hyoid bone. The external branch is mainly the motor nerve, which innervates the cricothyroid muscle and the upper part of the inferior constrictor of the pharynx. Some branches enter the pharyngeal plexus, but there are also sensory branches that cross the cricothyroid membrane and distribute at the mucosa of the vocal folds and the anterior part of the subglottis (12). The cricothyroid muscle has the effect of increasing the tone of the vocal cords and has a regulatory effect on pitches with a frequency  $>150$  Hz. Due to the low position of the EBSLN outside the larynx, the long courses, the large variation in these courses, and the close association of the EBSLN with blood vessels at the superior pole of the thyroid gland, the EBSLN is prone to damage in the intraoperative dissection or ligation of thyroid vessels (e.g., during thyroid surgery for clinically severe goitres, and tumours of the superior pole of the thyroid), especially in patients with short, thick necks (13). Currently, it is recommended that conventional methods be used to expose the EBSLN in clinical thyroid surgery (14).

The diameter of the SLN was reported to be  $2.1 \pm 0.2$  mm by Kiray *et al.* and 1.8 to 2.0 mm by Stephens *et al.* (15,16). Cernea *et al.* observed 3 typing among the EBSLN, the superior thyroid artery, and the upper pole of the thyroid

**Table 1** Description of the baseline data

Variable	Control group	Observation group	t/ $\chi^2$	P
Age (years old)	37.59±5.72	37.30±5.91	0.244	0.404
Sex			0.236	0.627
Male	12	10		
Female	36	38		
Thyroid cancer			0.061	0.805
Yes	37	38		
No	11	10		
Hashimoto's disease			0.171	0.679
Yes	21	19		
No	27	29		
Nodular goitre			0.408	0.525
Yes	16	19		
No	32	29		
Surgical method			0.211	0.646
Unilateral	36	34		
Bilateral	12	14		
Operation time (min)	65.91±8.15	66.25±9.44	0.189	0.425
F0 (Hz),	191.90±21.82	191.01±21.03	0.204	0.420
Jitter (%)	0.17±0.04	0.16±0.04	1.225	0.112
Shimmer (%)	1.21±0.14	1.91±0.21	0.315	0.377
HNR (dB)	27.90±4.91	27.82±4.09	0.087	0.466
MPT (s)	10.51±1.78	10.43±1.93	0.211	0.417
F0SD (Hz)	1.94±0.25	1.99±0.28	0.000	1.000
DSI	-3.30±0.46	-3.39±0.44	0.980	0.165

Data were presented as No. and mean ± standard deviation. F0, fundamental frequency; HNR, harmonic-to-noise ratio; MPT, maximum phonation time; F0SD, fundamental frequency standard deviation; DSI, fundamental frequency standard deviation.

**Table 2** Acoustic voice analysis of the 2 groups 1 month after surgery

Variable	Control group	Observation group	t	P
F0 (Hz)	170.31±18.85	180.44±20.16	3.045	<0.001
Jitter (%)	0.23±0.04	0.19±0.03	5.543	<0.001
Shimmer (%)	1.51±0.19	1.33±0.15	5.152	<0.001
HNR (dB)	27.78±4.40	27.63±3.33	0.188	0.426
MPT (s)	13.41±1.61	15.82±1.94	6.623	<0.001
F0SD (Hz)	1.71±0.22	1.56±0.21	3.417	<0.001
DSI	1.34±0.19	1.57±0.17	6.250	<0.001

Data were presented as mean ± standard deviation. F0, fundamental frequency; HNR, harmonic-to-noise ratio; MPT, maximum phonation time; F0SD, fundamental frequency standard deviation; DSI, fundamental frequency standard deviation.

**Table 3** Comparison of SLN injury between the 2 groups during the follow-up period

Variable	Injury	Normal	$\chi^2$	P
Control group, n	6	42	1.227	0.268
Observation group, n	2	46		

SLN, superior laryngeal nerve.

gland (17). Thus, the diameter of the EBSLN is relatively small, and variation is common. The nerve is prone to accidental injury in the process of exposing the SLN. The SLN trophoblastic vessels may also be severed during the isolation process, affecting their functions. SLN exposure is not recommended during thyroid surgery; rather, an “avoidance strategy” is recommended whereby the superior thyroid artery close to the superior pole of the thyroid gland is ligated (18). However, the position of some SLNs crossing the superior thyroid artery is lower than the boundary of the superior pole of the thyroid, and even if the avoidance strategy is adopted, accidental injury is still likely.

Some scholars believe that the EBSLN should be routinely exposed during thyroid-related surgery, as its anatomical and functional integrity are more likely to be preserved under direct vision and thus the rate of nerve injury reduced (19). In recent years, the IONM technique has been successfully applied in the localization, identification, and protection of the RLN during surgery, and has become an important auxiliary means for the prevention of RLN injury during thyroid surgery (20). The use of IONM to identify the EBSLN in the treatment of the superior pole of the thyroid has reduced the injury rate of the EBSLN from 12.3% to 1.5% (20). In this study, neuromonitoring equipment was used to help identify the EBSLN in the 48 patients undergoing thyroid surgery. The success rate was 100%, which provides further evidence that IONM is an advantageous procedure.

Injectable mouse neurotrophic factors are a class of active polypeptides that can effectively prevent the degeneration and death of damaged neurons, promote axon growth, promote the development, differentiation, and maturation of nerve cells, promote the directional regeneration of axons, accelerate the repair of damaged nerve cells, and increase the efficiency of nerve myelin repair and the conduction speed of nerve motor fibres (21). The mNGF can promote the regeneration of damaged RLNs and restore the action potentials of the laryngeal compound muscle (21).

The results of this study showed that the F0 and DSI of the observation group were significantly higher than those of the control group at 1 month after surgery, while the jitter, shimmer, MPT, and F0SD of the observation group were significantly lower than those of the control group. During the follow-up period of >6 months, 8 cases of EBSLN palsy appeared, including 2 cases in the control group and 6 cases in the observation group. There was no significant difference in the incidence of SLN injury between the 2 groups. The above results indicate that the exposure and protection of the EBSLN during thyroid surgery and the administration of mNGF postoperatively effectively protects the voices of patients and improves their quality of life.

For patients with EBSLN injury, the guidelines recommend treatments, such as hormones and tropic nerves, during the early stage (22). MNGF is a biologically active substance extracted from the submandibular glands of mice. It is an essential protein molecule for nerve growth and development and has a repair effect on nerve injury (23). Thus, the results of this study showed that the local application of mNGF can repair the damaged SLN, restore the action potential of the laryngeal compound muscle, and promote the recovery of nerve function.

However, the present study had some limitations. First, due to the limited number of cases included in this study, the efficacy of mNGF combined with exposure and the EBSLN on voice changes still needs to be tested in large samples. Second, due to lack of a group that was exposed to EBSLN without receiving the treatment of mNGF, the evidence that the mNGF protects the voice is limited.

## Conclusions

In summary, the mNGF combined with the exposure and protection of the EBSLN effectively prevents voice injury. The strategy of routine exposure and protection of the EBSLN may be worthy of promotion in clinical practice.

## Acknowledgments

*Funding:* This study was supported by Basic Public Welfare Research Program of Zhejiang Province (No. LGF22H070008).

## Footnote

*Reporting Checklist:* The authors have completed the

TREND reporting checklist. Available at <https://gs.amegroups.com/article/view/10.21037/gS-22-703/rc>

*Data Sharing Statement:* Available at <https://gs.amegroups.com/article/view/10.21037/gS-22-703/dss>

*Conflicts of Interest:* All authors have completed the ICMJE uniform disclosure form (available at <https://gs.amegroups.com/article/view/10.21037/gS-22-703/coif>). The authors have no conflicts of interest to declare.

*Ethical Statement:* The authors are accountable for all aspects of the work in ensuring that questions related to the accuracy or integrity of any part of the work are appropriately investigated and resolved. The study was conducted in accordance with the Declaration of Helsinki (as revised in 2013). The study was approved by the Ethics Committee of Hangzhou First People's Hospital (ID:2018(008)-01). Informed consent was taken from all the patients.

*Open Access Statement:* This is an Open Access article distributed in accordance with the Creative Commons Attribution-NonCommercial-NoDerivs 4.0 International License (CC BY-NC-ND 4.0), which permits the non-commercial replication and distribution of the article with the strict proviso that no changes or edits are made and the original work is properly cited (including links to both the formal publication through the relevant DOI and the license). See: <https://creativecommons.org/licenses/by-nc-nd/4.0/>.

## References

- Dekhou AS, Morrison RJ, Gemechu JM. The Superior Laryngeal Nerve and Its Vulnerability in Surgeries of the Neck. *Diagnostics (Basel)* 2021;11:1243.
- Schneider M, Dahm V, Passler C, et al. Complete and incomplete recurrent laryngeal nerve injury after thyroid and parathyroid surgery: Characterizing paralysis and paresis. *Surgery* 2019;166:369-74.
- Huang TY, Yu WV, Chiang FY, et al. Correlation Between Objective and Subjective High-Pitched Voice Impairment in Patients After Thyroid Surgery. *Front Endocrinol (Lausanne)* 2021;12:788878.
- Varaldo E, Ansaldo GL, Mascherini M, et al. Neurological complications in thyroid surgery: a surgical point of view on laryngeal nerves. *Front Endocrinol (Lausanne)* 2014;5:108.
- Naytah M, Ibrahim I, da Silva S. Importance of incorporating intraoperative neuromonitoring of the external branch of the superior laryngeal nerve in thyroidectomy: A review and meta-analysis study. *Head Neck* 2019;41:2034-41.
- Holler T, Anderson J. Prevalence of voice & swallowing complaints in Pre-operative thyroidectomy patients: a prospective cohort study. *J Otolaryngol Head Neck Surg* 2014;43:28.
- Liu L, Ma Y, Saleh E, Qiu T, Zhuang P. Exploring the Clinical Characteristics of Superior Laryngeal Nerve Injury. *J Voice* 2022. [Epub ahead of print]. doi: 10.1016/j.jvoice.2022.04.009.
- Lee J, Fraser S, Glover A, et al. Prospective evaluation of the utility of routine neuromonitoring for an established thyroid surgical practice. *ANZ J Surg* 2017;87:E138-42.
- Minuto MN, Reina S, Monti E, et al. Morbidity following thyroid surgery: acceptable rates and how to manage complicated patients. *J Endocrinol Invest* 2019;42:1291-7.
- Ruotsalainen J, Sellman J, Lehto L, et al. Systematic review of the treatment of functional dysphonia and prevention of voice disorders. *Otolaryngol Head Neck Surg* 2008;138:557-65.
- Potenza AS, Araujo Filho VJF, Cernea CR. Injury of the external branch of the superior laryngeal nerve in thyroid surgery. *Gland Surg* 2017;6:552-62.
- Lu KN, Ding JW, Zhang Y, et al. The Anatomical and Clinical Significance of the Superior Laryngeal Nerve. *Otolaryngol Head Neck Surg* 2021;165:690-5.
- Naidoo D, Boon JM, Mieny CJ, et al. Relation of the external branch of the superior laryngeal nerve to the superior pole of the thyroid gland: an anatomical study. *Clin Anat* 2007;20:516-20.
- Barczyński M, Randolph GW, Cernea C, et al. International survey on the identification and neural monitoring of the EBSLN during thyroidectomy. *Laryngoscope* 2016;126:285-91.
- Kiray A, Naderi S, Ergur I, et al. Surgical anatomy of the internal branch of the superior laryngeal nerve. *Eur Spine J* 2006;15:1320-5.
- Stephens RE, Wendel KH, Addington WR. Anatomy of the internal branch of the superior laryngeal nerve. *Clin Anat* 1999;12:79-83.
- Cernea CR, Ferraz AR, Nishio S, et al. Surgical anatomy of the external branch of the superior laryngeal nerve. *Head Neck* 1992;14:380-3.
- Morton RP, Whitfield P, Al-Ali S. Anatomical and surgical considerations of the external branch of the superior

- laryngeal nerve: a systematic review. *Clin Otolaryngol* 2006;31:368-74.
19. Zhao Y, Zhao Z, Zhang D, et al. Improving classification of the external branch of the superior laryngeal nerve with neural monitoring: a research appraisal and narrative review. *Gland Surg* 2021;10:2847-60.
  20. Uludag M, Aygun N, Kartal K, et al. Contribution of intraoperative neural monitoring to preservation of the external branch of the superior laryngeal nerve: a randomized prospective clinical trial. *Langenbecks Arch Surg* 2017;402:965-76.
  21. Knüsel B, Burton LE, Longo FM, et al. Trophic actions of recombinant human nerve growth factor on cultured rat embryonic CNS cells. *Exp Neurol* 1990;110:274-83.
  22. Barczyński M, Randolph GW, Cernea CR, et al. External branch of the superior laryngeal nerve monitoring during thyroid and parathyroid surgery: International Neural Monitoring Study Group standards guideline statement. *Laryngoscope* 2013;123 Suppl 4:S1-14.
  23. Korsching S, Thoenen H. Nerve growth factor in sympathetic ganglia and corresponding target organs of the rat: correlation with density of sympathetic innervation. *Proc Natl Acad Sci U S A* 1983;80:3513-6.
- (English Language Editor: L. Huleatt)

**Cite this article as:** Zhang J, Zhang W, Peng Y, Sun L, Wang M. Effect of mouse nerve growth factor combined with the exposure of the external branch of superior laryngeal nerve on voice changes after thyroidectomy: a prospective non-randomized controlled trial. *Gland Surg* 2022;11(12):1976-1983. doi: 10.21037/gS-22-703