

Treatment of Class I crowding using simple tubes bonded with customized resin coverings: A case report

Seo-Rin Jeong 
Hye-In Kim
Sung-Hoon Lim 

Department of Orthodontics, College
of Dentistry, Chosun University,
Gwangju, Korea

As an alternative to the conventional fixed appliance that uses orthodontic brackets, a simple round tube without a bonding base can be bonded to the tooth surface by covering the tube with flowable resin. In this technique, bent wires cannot be inserted into the simple tubes; therefore, repositioning of the simple tubes is often required for adjustments. To reduce repositioning of simple tubes, a dome-shaped resin covering of the simple tube can be designed with a customized in-and-out compensation, using three-dimensional computer-aided design software based on digital simulation of orthodontic tooth movement. In the present case, the use of simple tubes bonded with customized resin coverings in a Class I nonextraction case is described in a 17-year-old male, in whom moderate crowding of the anterior teeth was treated over an 8-month period. This case shows that simple tubes can be used as an alternative to brackets in some Class I nonextraction cases, with the potential benefit of reducing decalcification.

[Korean J Orthod 2019;49(2):116-123]

Key words: Appliance, Bracket, Digital simulation, Computer-aided design

Received June 4, 2018; Revised August 13, 2018; Accepted October 5, 2018.

Corresponding author: Sung-Hoon Lim.

Professor, Department of Orthodontics, College of Dentistry, Chosun University, 303 Pilmun-daero, Dong-gu, Gwangju 61452, Korea.

Tel +82-62-220-3870 e-mail shlim@chosun.ac.kr

How to cite this article: Jeong SR, Kim HI, Lim SH. Treatment of Class I crowding using simple tubes bonded with customized resin coverings: A case report. Korean J Orthod 2019;49:116-123.

© 2019 The Korean Association of Orthodontists.

This is an Open Access article distributed under the terms of the Creative Commons Attribution Non-Commercial License (<http://creativecommons.org/licenses/by-nc/4.0>) which permits unrestricted non-commercial use, distribution, and reproduction in any medium, provided the original work is properly cited.

INTRODUCTION

Several methods¹⁻¹⁰ have been suggested as more esthetic alternatives to orthodontic brackets. A nickel-titanium (NiTi) archwire can be bonded directly to the lingual side of the anterior teeth with composite resin, in order to correct minor crowding.² NiTi wires can also be used with or without simple tubes to resolve crowding.^{2,3} A simple tube is a generic term for various tubes without bonding bases that can be bonded to the tooth by covering the tube with flowable resin. A mini-tube appliance¹⁰ is the first simple tube manufactured for alignment of the anterior teeth. Alternatively, a small crimpable mini stop, which is used for holding a NiTi archwire, can also be used as a simple tube when crimping is not applied. The most important potential benefit of this approach is increased ease of oral hygiene care, due to the reduction of undercut areas underneath the simple tubes.¹¹ Furthermore, patient comfort may be increased due to the small size and low profile of the simple tube.

However, simple tubes are used mainly with unbent superelastic NiTi archwires,¹⁰ because a bent wire cannot be inserted through the openings of the tube. Therefore, adjustments of tooth position are typically performed through repositioning of simple tubes, rather than wire

bending. To reduce the repositioning of simple tubes, customized composite resin covering that holds the simple tube can be made by injecting flowable resin into the mold formed inside of the customized transfer tray, then applying light curing. This case report illustrates the method of fabricating customized resin coverings using a virtual setup, computer-aided design (CAD), three-dimensional (3D) printing, and fabrication of transfer tray.

DIAGNOSIS AND ETIOLOGY

A 17-year-old male presented with the chief complaint of crooked anterior teeth. He exhibited a convex profile, and intraoral examination revealed palatal eruption of the maxillary left lateral incisor without transverse shift of the maxillary dental midline. The mandibular right lateral incisor had erupted lingually, and the dental midline was shifted 2.5 mm to the right. Crossbite was present in the areas of the maxillary left lateral incisor and mandibular right canine. The right and left molars exhibited Class I relationships. Pretreatment panoramic radiographs showed a favorable tooth axis and normal root length. Cephalometric analysis revealed a mild Class II skeletal pattern with retrognathic mandible. The maxillary incisors were tipped lingually, and there was a

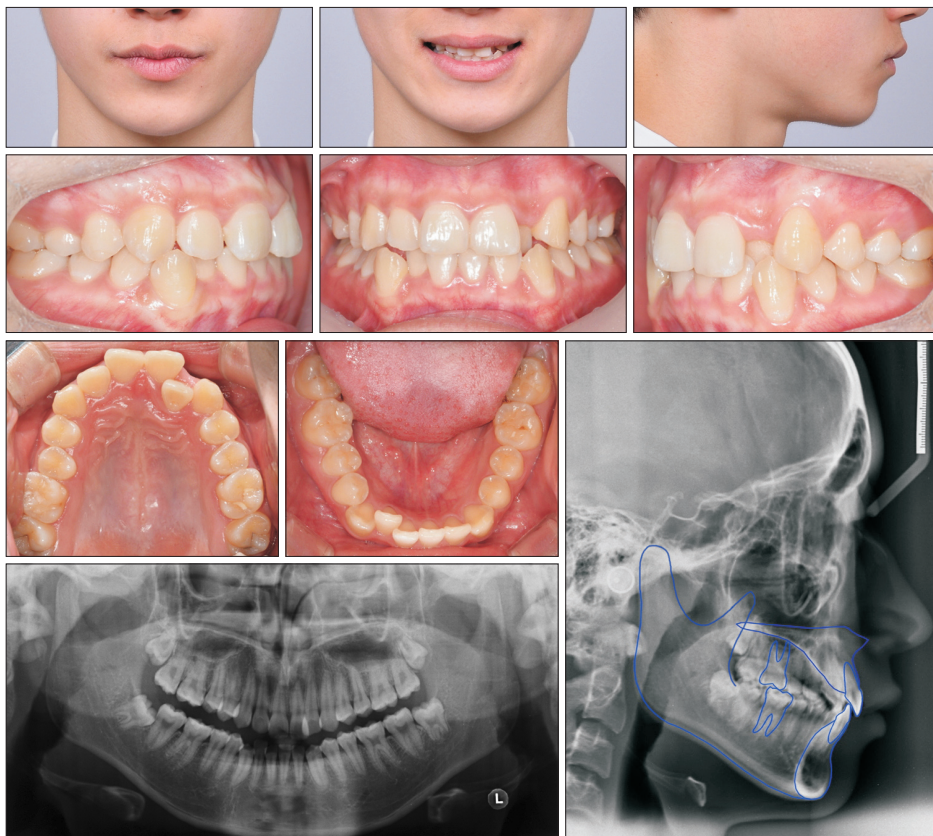

Figure 1. Pretreatment records of a 17-year-old male with anterior crowding exhibiting dental Class I and mild skeletal Class II relationships.

normal relationship between the esthetic line and the lip (Figure 1, Table 1). The suspected etiology of crowding was typical tooth size-arch length discrepancy.

TREATMENT OBJECTIVES

The treatment objectives were as follows: decrowding without severe proclination of incisors, and establishment of normal overbite and overjet while maintaining Class I canine and molar relationships.

TREATMENT ALTERNATIVES

Because the facial profile was favorable and the molar relationships were Class I, there was no consideration of orthognathic surgery to improve the retrognathic mandible, or premolar extraction treatment to improve the convex profile. Therefore, nonextraction treatment was chosen; interproximal reduction was also planned to avoid severe flaring of the incisors during the alignment process. Because posterior occlusion was good, anteroposterior movement of the posterior teeth was not needed. Therefore, fixed appliance using simple tubes was chosen, with the potential benefit of reducing the possibility of decalcification during orthodontic treatment.¹¹

Table 1. Cephalometric measurements

Measurement	Norm	Pretreatment	Posttreatment
SNA (°)	81.8	81.0	79.3
SNB (°)	80.2	77.1	75.3
ANB (°)	1.8	3.9*	4.1*
U1 to SN (°)	109.3	96.3 [†]	102.9*
U1 to FH (°)	116.5	107.3*	116.3
FMIA (°)	63.3	66.1	55.3*
IMPA (°)	90.2	88.4	99.5*
IIA (°)	126.2	138.8*	119.1
UL to E-line (mm)	-1.0	1.1	1.1
LL to E-line (mm)	0.3	1.6	2.2
Wits	-2.2	-1.2	-0.5

SNA, Sella-Nasion-point A angle; SNB, Sella-Nasion-point B angle; ANB, point A-Nasion-point B angle; U1-SN, upper incisor inclination to Sella-Nasion; U1-FH, upper incisor inclination to frankfort horizontal plane; FMIA, Frankfort-mandibular incisor angle; IMPA, lower incisor to mandibular plane angle; IIA, inter-incisor angle; UL, upper lip; E-line, esthetic line; LL, lower lip.

*> one standard deviation from the norm; [†]> two standard deviations from the norm.

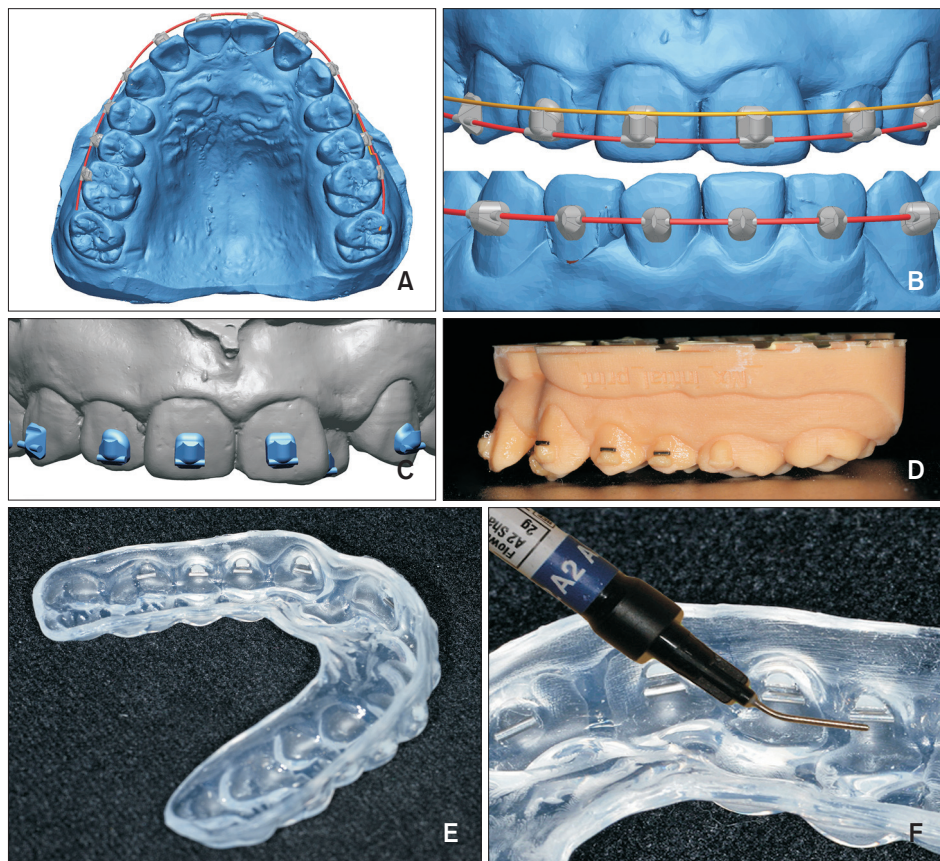


Figure 2. A and B, Design of the simple tubes and customized resin coverings on the setup model. C, Customized resin coverings were transferred onto the pretreatment models. D, Gingival simple tubes were placed on the printed model into the recesses receiving them, and transfer trays were fabricated by thermoforming. E, Occlusal simple tubes were placed into the recesses, thereby fixing the mesiodistal ends of the tubes in the transfer tray. F, Flowable resin was injected into the central recesses for customized resin coverings, which fixed the central part of the occlusal simple tubes.

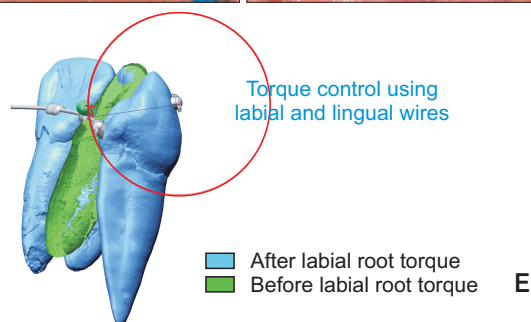
TREATMENT PROGRESS

Silver tubes with 2- or 3-mm widths (Hubit Co., Ltd, Uiwang, Korea) were used as simple tubes. These tubes have an inner diameter of 0.46 mm (0.018 inches [in]) and an outer diameter of 0.71 mm.¹ A pretreatment model was scanned to fabricate a digital model; then, digital setup was performed using setup software (Maestro 3D Ortho Studio; AGE Solutions, Pontedera, Italy). Stereolithography files of the setup model were imported into 3D CAD software. In the maxillary arch, double simple tubes consisting of a 3-mm wide occlusal tube and a 2-mm wide gingival tube were designed to control tooth positions in three dimensions. In the mandibular arch, only occlusal simple tubes were designed because torque control was not required. Occlusal and gingival simple tubes and customized resin coverings

holding the central portions of occlusal tubes were designed on the setup models. For the gingival simple tubes, only recesses in which the gingival simple tubes would be placed were modeled during the design of customized resin covering, in order to allow freedom for adding gingival simple tubes later when necessary (Figure 2). These recesses were modeled by subtracting the gingival simple tubes from the customized resin covering. Customized resin coverings and simple tubes that had been designed from the ideal setup were transferred to the pretreatment digital model. These were then merged with the pretreatment digital model and produced using a 3D printer (D35; Prodways, Les Mureaux, France). By thermoforming the transfer tray on this printed model, the negative forms of simple tubes and customized resin domes were made in the transfer tray. In the left half of the maxillary model, Vaseline[®] was applied to the

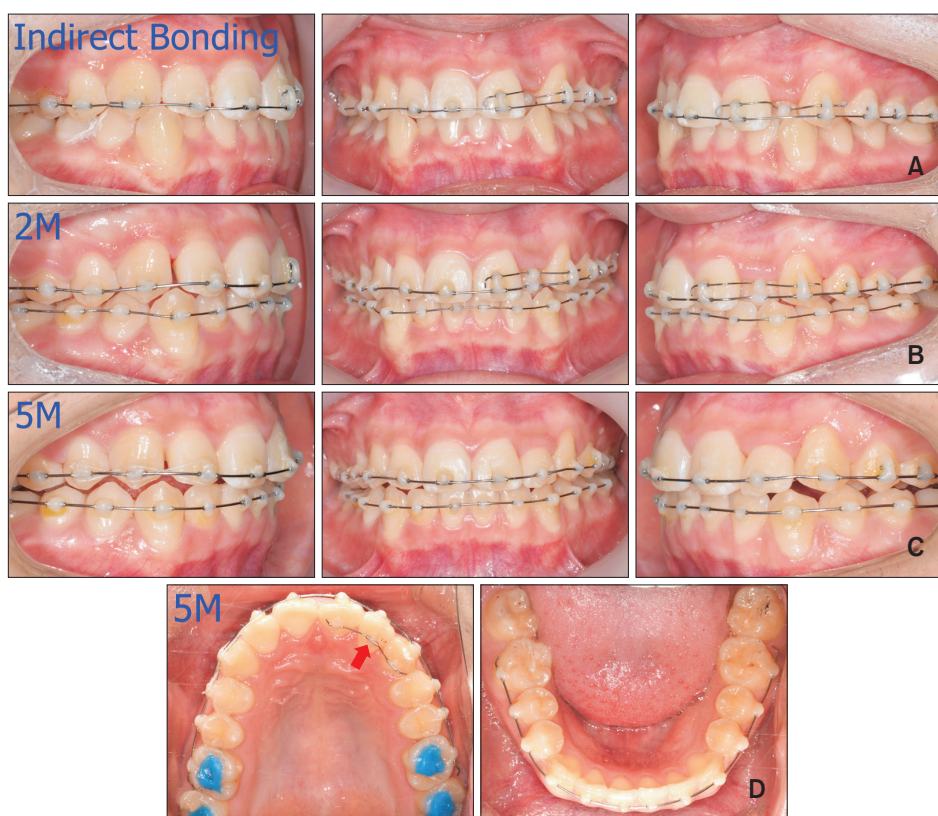

Figure 3. Treatment progress. **A**, Simple tubes were bonded using the transfer tray and an additional wire segment was inserted into the gingival simple tubes bonded on the maxillary left central incisor, lateral incisor, and canine. **B**, After 2 months of treatment, an occlusal simple tube was bonded on the maxillary left lateral incisor. **C** and **D**, After 5 months of treatment, lingual simple tubes were bonded on the maxillary left central and lateral incisors, as well as the canine. **E**, Simple tubes were bonded passively on the lingual surfaces of the maxillary left central incisor and canine, and another simple tube was positioned occlusally and lingually from the tooth surface of the lateral incisor (green color). As the wire deflection is resolved, buccal root torque will be achieved (blue color). This illustration of three teeth was made using micro computed tomography scan images of extracted teeth from different patients. 2M, 2 Months; 5M, 5 months.



recesses designed for the gingival tubes; gingival simple tubes were then placed on these recesses and fixed with flowable resin (Filtek Z350 XT; 3M ESPE, St. Paul, MN, USA) before thermoforming (Figure 2). A transfer tray was then thermoformed with 1.0-mm Bioplast® (Scheu Dental, Iserlohn, Germany). Gingival simple tubes fixed with flowable resin were automatically transferred into the transfer tray through the process of thermoforming. The occlusal simple tubes were manually inserted into the holes for the mesiodistal ends of tubes formed on the transfer tray (Figure 2). The resin used to fix the gingival simple tubes was sandblasted, cleaned, and then treated with plastic conditioner (Reliance Orthodontic Products, Inc., Itasca, IL, USA).

After preparing the tooth for indirect bonding (i.e., oral prophylaxis, etching, washing, drying, and applica-

tion of bonding agent), flowable resin (Filtek Z350 XT) was injected into the recesses for the resin coverings in the transfer tray. Flowable resin was also applied on the tooth side surfaces of resin coverings for gingival simple tubes, after application of the bonding agent. Then, the tray was securely positioned over the arch and cured using a light curing unit. Because crossbite was present on the maxillary left lateral incisor, the 0.013-in copper NiTi archwire (Ormco, Brea, CA, USA) that was inserted into the occlusal simple tubes bypassed the maxillary left lateral incisor. Instead, a 0.013-in copper NiTi wire segment was inserted on the gingival simple tubes of the maxillary left central incisor, lateral incisor, and canine (Figure 3).

When applying simple tubes to the whole arch, an archwire can be inserted between the canine and first

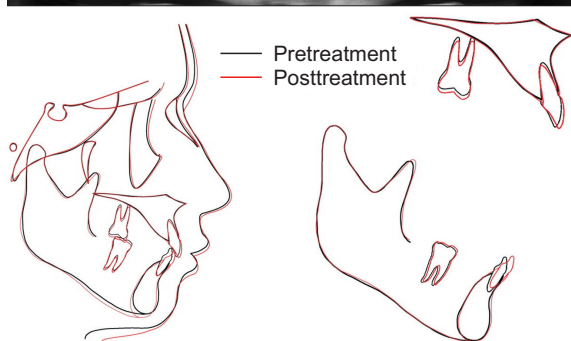
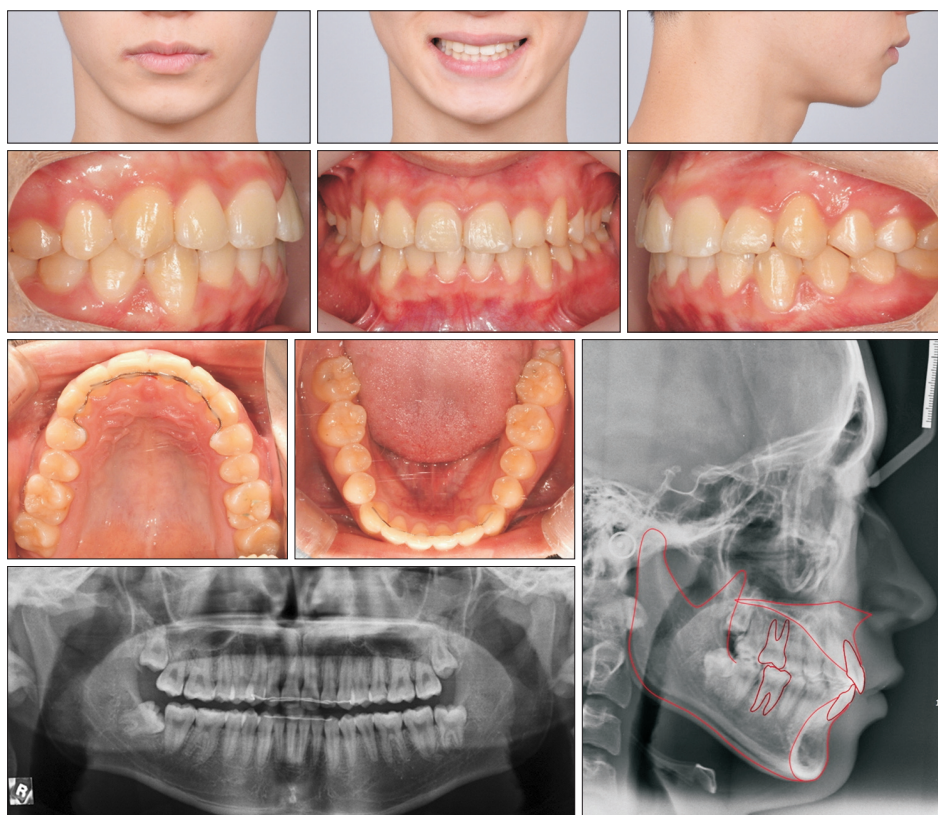


Figure 4. Posttreatment records. Superimposition of pretreatment (black line) and posttreatment (red line) cephalometric radiographs reveals labioversion of both maxillary and mandibular incisors, as well as slight backward rotation of the mandible.

premolar, where there is a large inter-tube distance; both anterior and posterior teeth are approachable from this area. Alternatively, a NiTi archwire can be inserted from the distal opening of a molar tube, while holding the opposite end with a mosquito to prevent poking soft tissues.

After 2 months of alignment, interproximal reduction was performed between the maxillary right lateral incisor and canine, and the mesial and distal sides of the maxillary left first premolar. An occlusal simple tube was also bonded onto the maxillary left lateral incisor (Figure 3). In the maxillary arch, 0.016-in NiTi (Sentalloy; Dentsply sirona, York, PA, USA) was used for the main archwire; a 0.013-in copper NiTi wire segment was maintained for the gingival simple tubes. In the mandibular arch, 0.013-in copper NiTi was used first, followed 3 months later by 0.016-in NiTi. During bite jumping of the maxillary left lateral incisor, blue bite-raising resin (Bisfil™ Core; Bisco, Schaumburg, IL, USA) was bonded onto the maxillary molars, in order to reduce occlusal interference on the maxillary left lateral incisor (Figure 3). After 5 months of treatment, the crossbite of the maxillary left lateral incisor was nearly resolved. Because the torque control of the maxillary lateral incisor (using the main occlusal archwire and the gingival wire segment) was

unsuccessful due to the short distance between the two wires, and because the wires exhibited an unaesthetic appearance, gingival simple tubes were debonded and lingual simple tubes were bonded directly onto the maxillary left central incisor, lateral incisor, and canine. For this bonding procedure, simple tubes were inserted on a 0.013-in copper NiTi wire segment before bonding. Lingual simple tubes were bonded passively on the maxillary left central incisor and canine; the simple tube for the maxillary left lateral incisor was then positioned more occlusally, in order to exert labial root torque on the lateral incisor (Figure 3). This bonding procedure is known as “deflection-based bonding,”¹² because a wire is deflected as needed during this bonding procedure; this differs from the conventional bracket bonding procedure, in which brackets are bonded in their ideal positions in contact with tooth surfaces. Lingual simple tubes on the lateral incisor were positioned along a circle established with the labial simple tube as its center; its radius comprised the distance between labial and lingual simple tubes (Figure 3). After 8 months of treatment, orthodontic appliances were removed, and maxillary and mandibular fixed retainers were bonded (Figure 4).

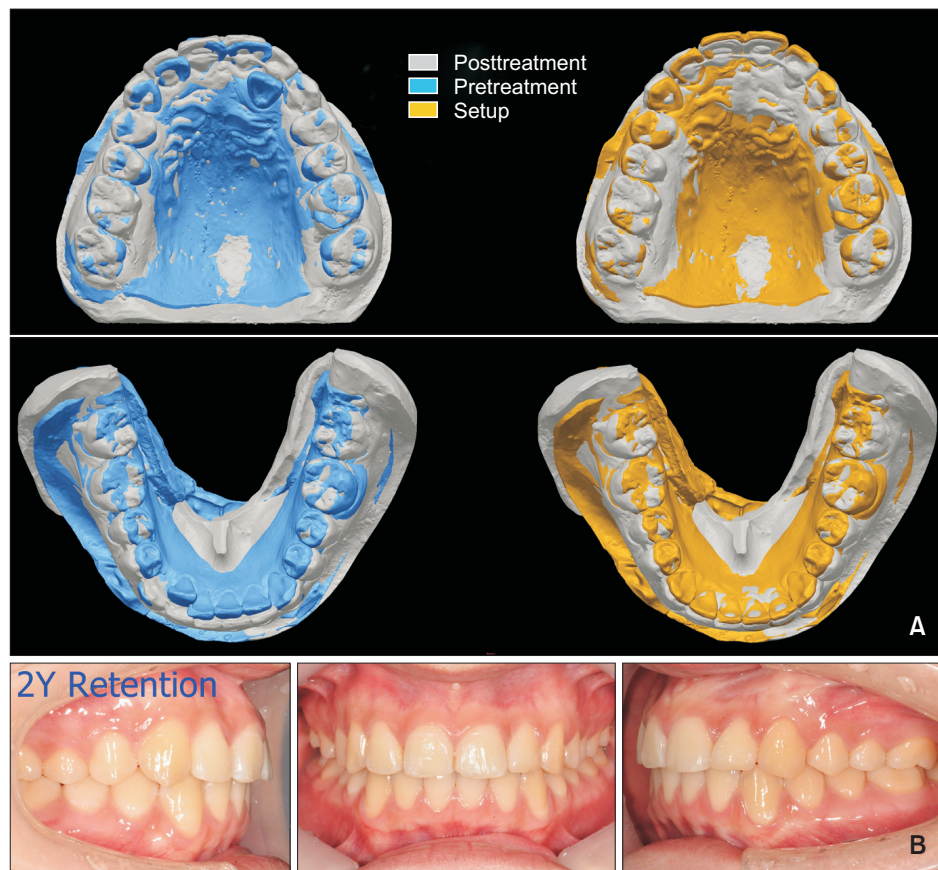


Figure 5. A, Superimposition of pretreatment (blue), post-treatment (gray), and digital setup (yellow) models. **B,** Intraoral photographs obtained after 2 years (2Y) of retention. Gingival recession was noted on the maxillary left lateral incisor.

RESULTS

Superimposition of the pretreatment and posttreatment cephalometric radiographs revealed mild labioversion of both maxillary and mandibular incisors (Figure 4). A posttreatment panoramic radiograph showed no significant root resorption. Superimposition of pretreatment and posttreatment digital models¹³ revealed that the alignment was completed with mild arch expansion (Figure 5). Superimposition of the digital setup model and posttreatment model showed a high degree of similarity between the models, except that the intercanine width was wider in the posttreatment model (Figure 5).

The treatment results were stable after 2 years of retention. However, gingival recession was evident on the maxillary left lateral incisor (Figure 5). This could have been caused by the rapid movement of the root into the buccal cortical bone. Slower movement of the maxillary left lateral incisor might have reduced gingival recession.

DISCUSSION

The limitations of bracketless or bracket-free¹⁻¹⁰ orthodontic treatments are similar to those of treatment using two-dimensional (2D) brackets.^{14,15} These methods use only round wires. Unlike 2D brackets, simple tubes can receive only superelastic NiTi wire without any sharp bends, which limits the indications for treatment using simple tubes, compared with those for treatment using 2D brackets. Control of tipping and rotation of teeth is also difficult when using simple tubes with narrow width. Therefore, use of simple tubes of > 3 mm width is recommended, unless severe crowding is observed. Another limitation of this treatment method is that rectangular or heavy wires cannot be used; thus, space closure and key correction are impossible, and torque control is difficult. Therefore, only mild Class I or relapse cases can be treated with this appliance. Although the indications are limited, patients who prefer treatment using a clear aligner for aesthetic reasons frequently accept this alternative approach using simple tubes.

To overcome these limitations, double wires can be used. In the present case, labial archwire and lingual wire segments were used to apply labial root torque to the maxillary left lateral incisor (Figure 3). In this application, the maxillary left lateral incisor had been constrained with thicker and stiffer labial archwire. The occlusally-deflected lingual wire segment generated an intrusive force passing through the lingual side of the center of resistance of the maxillary left lateral incisor, thus producing a moment for labial root torque (Figure 3).

Decalcification occurs frequently in orthodontic patients with poor oral hygiene. Bracket wings and hooks can act as a trap or reservoir for food debris and den-

tal plaque. In addition, orthodontic appliances disturb the salivary flow field on tooth surfaces and can lead to reduction in salivary velocity and increased bacterial numbers.⁸ Local vortexes that form in areas gingival to the bracket, together with the constraint of narrow space, contribute to a periodontal inflammatory response.⁸ When 0.71-mm-thick simple tubes are bonded with dome-shaped customized resin coverings, the self-cleansing action of the salivary flow is less affected than when using brackets. When poor oral hygiene is observed during fixed treatment using brackets, simple tubes can be used to replace the brackets after completion of the space closure or key correction. Rotation and extrusion are difficult to achieve with clear aligners.^{16,17} Simple tubes can be used in combination with clear aligners to achieve tooth movements that are difficult to realize with aligners.¹⁶ Currently, the fabrication process for customized resin covering is technique-sensitive and time-consuming. Therefore, direct application of simple tubes may be more practical. However, as 3D CAD¹⁸ and 3D printing technologies continue to advance, the present approach may evolve and its indications are likely to broaden in the future with an additional use of auxiliary wires or aligners. Hopefully, this is helpful for patients who is reluctant to accept the fixed appliance treatment using brackets, thus broadening acceptance of orthodontic treatment.

CONCLUSION

Simple tubes can be bonded with customized resin coverings produced by 3D CAD and 3D printing. This simplified fixed appliance can be used to treat mild Class I malocclusions with the potential benefit of reducing decalcification.

CONFLICTS OF INTEREST

No potential conflict of interest relevant to this article was reported.

ACKNOWLEDGEMENTS

This study was supported by research fund from Chosun University Dental Hospital, 2018.

REFERENCES

1. Liou EJ, Chen LI, Huang CS. Nickel-titanium mandibular bonded lingual 3-3 retainer: for permanent retention and solving relapse of mandibular anterior crowding. *Am J Orthod Dentofacial Orthop* 2001;119:443-9.
2. Park SH, Lee YK, Chun YS. Correction of palatally

- displaced maxillary lateral incisors using a tube system. *J Clin Orthod* 2008;42:461-5; quiz 455-6.
3. Choi KH, Lee Y, Kim M, Chun YS. Correction of palatally displaced maxillary lateral incisors without brackets. *Korean J Orthod* 2013;43:201-6.
 4. Kim M, Kim M, Chun YS. Molar uprighting by a nickel-titanium spring based on a setup model. *Am J Orthod Dentofacial Orthop* 2014;146:119-23.
 5. Jung JM, Wi YJ, Koo HM, Kim MJ, Chun YS. Maxillary molar derotation and distalization by using a nickel-titanium wire fabricated on a setup model. *Korean J Orthod* 2017;47:268-74.
 6. Musilli M. The Bracketless Fixed Orthodontics: nine years of clinical experimentation. *Prog Orthod* 2008;9:72-92.
 7. Musilli M, Acanfora M, Gherlone E, Lucchese A. Anterior torque correction with bracketless fixed orthodontics. *J Clin Orthod* 2012;46:558-62; quiz 581-2.
 8. Mariniello A, Cozzolino F. Atlas of bracketless fixed lingual orthodontics: basic concepts. Milan: Quintessence Publishing; 2015.
 9. Kim TK. Bracket-free orthodontics. Seoul: Daehan Narae Publishing; 2015.
 10. Hwang HS, Jeon HR, Kim SP, Kim WS, Lee GH. A new orthodontic appliance for rapid anterior alignment in adults; mini-tube appliance (MTA). *J Korean Dent Assoc* 2011;49:398-409.
 11. Zhu P, Lin H, Han Y, Lin Y, Xu Y, Zhang Z. A computational fluid dynamic analysis of peri-bracket salivary flow influencing the microbial and periodontal parameters. *PLoS One* 2013;8:e62242.
 12. Roh YY, Lim SH, Jeong SR. Orthodontic correction of bialveolar protrusion by interproximal reproximation and water-soluble tubes bonded with deflection-based bonding technique: a case report. *J Korean Dent Assoc* 2017;55:850-60.
 13. Jang I, Tanaka M, Koga Y, Iijima S, Yozgatian JH, Cha BK, et al. A novel method for the assessment of three-dimensional tooth movement during orthodontic treatment. *Angle Orthod* 2009;79:447-53.
 14. Macchi A, Tagliabue A, Levrini L, Trezzi G. Philippe self-ligating lingual brackets. *J Clin Orthod* 2002;36:42-5.
 15. Macchi A, Norcini A, Cacciafesta V, Dolci F. The use of bidimensional brackets in lingual orthodontics: new horizons in the treatment of adult patients. *Orthodontics* 2004;1:21-32.
 16. Lim SH. Digital fabrication and application of clear aligner after alignment with NiTi archwires. *J Korean Dent Assoc* 2016;54:551-62.
 17. Rossini G, Parrini S, Castroflorio T, Deregibus A, Debernardi CL. Efficacy of clear aligners in controlling orthodontic tooth movement: a systematic review. *Angle Orthod* 2015;85:881-9.
 18. Kim JY, Yu WJ, Koteswaracc PNK, Kyung HM. Effects of bracket slot size during en-masse retraction of the six maxillary anterior teeth using an induction-heating typodont simulation system. *Korean J Orthod* 2017;47:158-66.