

Infolding of fenestrated endovascular stent graft

Jason G. E. Zelt, MSc,^{a,b,c,d} Prasad Jetty, MD,^{e,f} Adnan Hadziomerovic, MD,^g and Sudhir Nagpal, MD,^{e,f}
Ottawa, Ontario, Canada

ABSTRACT

We report a case of infolding of a fenestrated stent graft involving the visceral vessel segment after a juxtarenal abdominal aorta aneurysm repair. The patient remains free of any significant endoleak, and the aortic sac has shown regression. The patient remains asymptomatic, with no abdominal pain, with normal renal function, and without ischemic limb complications. We hypothesize that significant graft oversizing (20%-30%) with asymmetric engineering of the diameter-reducing ties may have contributed to the infolding. Because of the patient's asymptomatic nature and general medical comorbidities, further intervention was deemed inappropriate as the aneurysmal sac is regressing despite the infolding. (*J Vasc Surg Cases and Innovative Techniques* 2017;3:159-62.)

Endovascular aneurysm repair is a minimally invasive technique for the treatment of aortic disease and remains an attractive approach for aneurysm repair, proving to have lower perioperative and equal long-term mortality compared with open surgical repair.¹ The development of fenestrated stent graft models has increased the utility of endovascular aneurysm repair to include treatment options for high-risk patients with juxtarenal aneurysms. In 2012, it was estimated that the Zenith (Cook Medical, Bloomington, Ind) fenestrated stent graft system was used to treat >3000 patients worldwide with complex aortic aneurysms.² Endograft infolding or collapse is a rare complication. Cases have been predominantly reported in thoracic endovascular cases³⁻¹⁰; however, to our knowledge, only one previous case has been reported in the abdominal aorta (Excluder; W. L. Gore & Associates, Flagstaff, Ariz).¹¹ We present a case of infolding of a fenestrated endograft (custom Cook graft) for a juxtarenal aneurysm repair. The patient has been followed up conservatively and remains asymptomatic 1 year after intervention. The patient consented to the publication of this report.

CASE REPORT

We present a case of a 71-year-old man with a 5.6-cm abdominal aortic aneurysm. His comorbidities included significant coronary artery disease with two preceding myocardial infarcts requiring coronary artery bypass as well as three coronary stents. He presented with mild to moderate left ventricular dysfunction and lateral wall hypokinesia. He currently is a nonsmoker for the past 4 years and suffers from mild stable angina. He also suffers from hypertension and chronic obstructive pulmonary disease.

His computed tomography (CT) scan revealed a juxtarenal aneurysm not amenable to standard infrarenal endovascular repair. Considering his comorbidities, he was evaluated for a fenestrated endograft using a custom Cook graft. The operative plan called for a four-vessel fenestrated graft to allow good sealing into normal aorta. Aortic measurements were determined during the preinterventional CT scan; the abdominal aorta at the celiac artery measured 25 mm in diameter, which narrowed to 23 mm at the renal vessels. The fenestrated component of the graft from the graft plan measured 30 mm in diameter. The lower component of the graft plan was a bifurcated graft with diameters of 13 mm in the left iliac artery and 12 mm in the right iliac artery.

The operative procedure. This procedure was done under general anesthesia. The fenestrated component of the graft was inserted through the right femoral artery. The appropriate graft markers were oriented for rotational alignment (check mark and cross hairs). The renal markers were then aligned to the angiographically confirmed renal vessels, and the main body was deployed to the level of the single diameter-reducing tie. We then used three separate punctures in the left common femoral artery to initially cannulate the superior mesenteric artery as well as both renal arteries with 7F sheaths. Atrium stents (Atrium Medical, Hudson, NH) were inserted into the sheaths awaiting deployment. Some torqueing of the graft was required to cannulate the left renal artery as there appeared to be some malalignment. This did not appear to be excessive. With these three visceral vessels cannulated and sheaths in appropriate alignment, the diameter-reducing ties were then released. The Atrium stents were then deployed without difficulty. The celiac fenestration was then assessed. Angiography through the superior mesenteric artery revealed excellent flow

From the Molecular Function and Imaging Program, National Cardiac PET Centre,^a and Cardiac Research Methods Centre,^b University of Ottawa Heart Institute; and the Division of Cardiology, Department of Medicine,^c Department of Cellular and Molecular Medicine, Faculty of Medicine,^d Division of Vascular Surgery,^e Ottawa Hospital Research Institute,^f and Department of Medical Imaging, The Ottawa Hospital,^g University of Ottawa.

Author conflict of interest: none.

Correspondence: Sudhir Nagpal, MD, The Ottawa Hospital Civic Campus, 1053 Carline Ave, Rm A280, Ottawa, ON K1Y 4E9, Canada (e-mail: snagpal@toh.on.ca).

The editors and reviewers of this article have no relevant financial relationships to disclose per the Journal policy that requires reviewers to decline review of any manuscript for which they may have a conflict of interest.

2468-4287

© 2017 The Authors. Published by Elsevier Inc. on behalf of Society for Vascular Surgery. This is an open access article under the CC BY-NC-ND license (<http://creativecommons.org/licenses/by-nc-nd/4.0/>).

<http://dx.doi.org/10.1016/j.jvscit.2017.04.008>

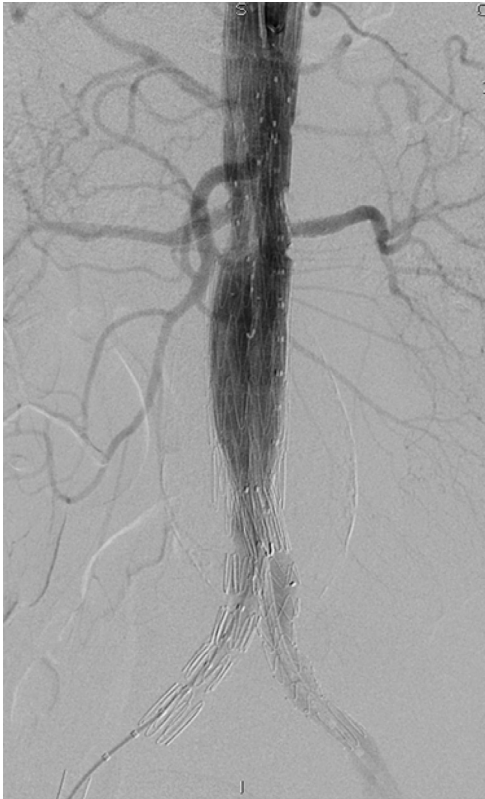

Fig 1. Completion angiogram showing excellent visceral perfusion with no endoleak. No abnormality was noted at implantation.

going into the celiac artery. Because the proximal celiac artery had a significant stenosis, we thought that a stent would not be required for either visceral perfusion or sealing of the aneurysm. The bifurcated segment of the fenestrated graft was then inserted without incident. We ballooned the overlap segments of the bifurcated graft, but no ballooning was done over the visceral component. Completion angiography revealed no endoleak and excellent visualization of all visceral vessels (Fig 1). The patient was discharged home on the fourth postoperative day in excellent condition.

During the standard surveillance protocol at 1 month, the CT scan revealed an impressive infolding of the proximal component, which included the visceral vessels (Fig 2). The tubular component of the fenestrated main body was not infolded, just the visceral component. The patient remained asymptomatic with no abdominal pain or any renal dysfunction. He maintained a good appetite and had no visceral or lower limb ischemic symptoms. We observed him conservatively with repeated CT scan in approximately 3 months and found no deterioration in the patency of his visceral vessels. He remains free of any significant endoleak, and the aortic sac has regressed. He remains asymptomatic up to 1 year with no abdominal pain and normal renal function.

DISCUSSION

This case illustrates a four-vessel fenestrated stent graft that presents with significant infolding on the posterior

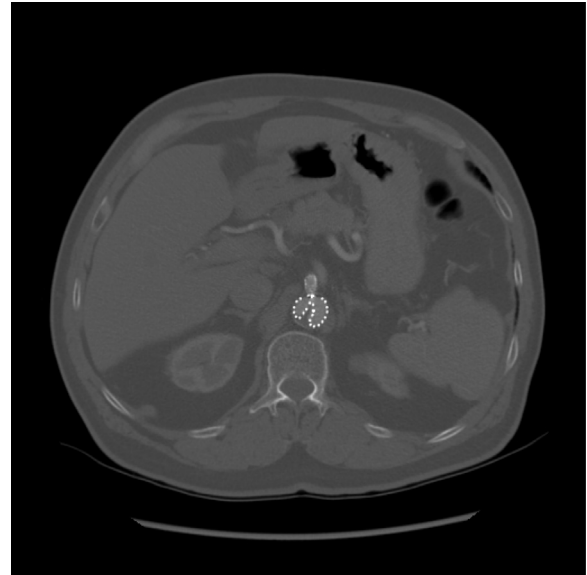


Fig 2. The 1-month postoperative computed tomography (CT) image showing the fenestrated graft with infolding of perivisceral segment.

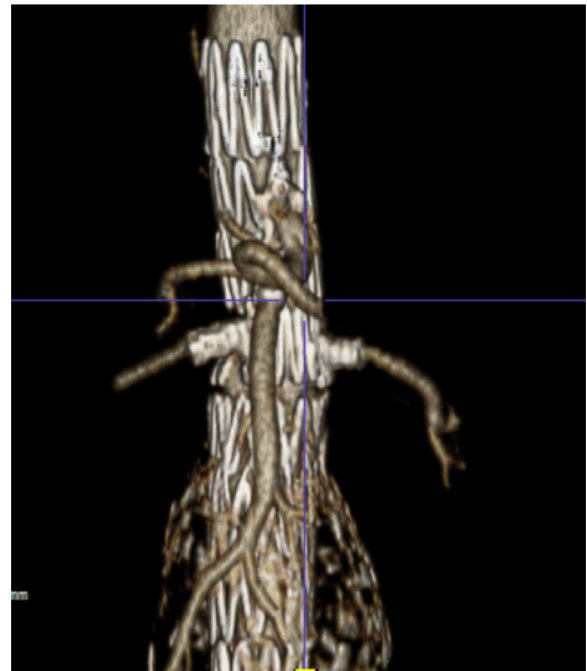


Fig 3. Three-dimensional reconstruction from the 1-month postoperative computed tomography (CT) scan demonstrating the patency of the visceral vessels.

aspect on the 1-month postoperative CT scan. All vessels remain patent, and the patient is asymptomatic from any visceral or lower limb ischemia (Fig 3). On review of the literature, infolding most commonly occurs in the thoracic aorta relating to bird beaking along the distal arch of the aorta.^{5,7,9,12} To our knowledge, only one previous case of graft infolding has been reported in the

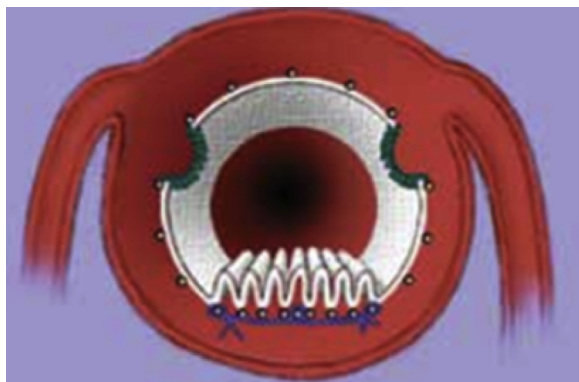

Fig 4. Diagram of a fenestrated graft demonstrating the asymmetric, posterior-oriented diameter-reducing ties. (From Oderich GS. Fenestrated stent graft repair for complex aneurysms. *Endovasc Today* 2013;May[Suppl]:16-26. Reprinted with permission.)

abdominal aorta,¹¹ and our case is the first report of infolding in a fenestrated or branch graft.

The cause of infolding is thought to be multifactorial, including graft material, percentage of graft oversizing, aorta diameter, and poor endograft apposition to the aortic wall.^{6-8,13} In our case, significant oversizing may have played a role as the fenestrated component measured 30 mm compared with the visceral aorta, measuring 23 to 25 mm (20%-30%). The fenestrated component had a single diameter-reducing tie, as is commonly the case (Fig 4). Asymmetric opening probably occurred when the diameter-reducing ties were released. The superior mesenteric artery and renal vessels were cannulated with 7F sheaths during the release, which stabilized the anterior component of the graft. The excessive oversizing then likely pushed posteriorly, which caused the infolding. During fenestrated endograft procedures, cannulation of the visceral vessels occasionally requires torsion of the fenestrated component to allow cannulation. The authors do not recall any excessive torsion during this procedure.

Prevention of this unusual problem may center on evaluating the diameter of the aortic neck along its full course as opposed to just its maximal dimension. Custom fenestrated grafts could potentially be tapered to allow different diameters along the visceral segment to be accommodated. This would obviously have limitations, depending on the length of the segment. Advances in intraoperative technology including cone beam CT would have allowed us to visualize this complication and to institute possible therapeutic measures, such as kissing balloon techniques, to help open up the graft.

There is no consensus in the literature on the management of patients with indolent graft infolding. The management is case based and related to factors such as the location, the degree of infolding, and the patient's symptoms and comorbidities. When warranted, repair of

collapse or infolding can be accomplished with a variety of percutaneous or surgical methods.⁷ Case reports of thoracic aorta infolding have been published with management strategies that range from balloon and stent remodeling^{9,11} or open surgery to conservative management for asymptomatic patients.^{7,14} In this case, balloon remodeling over the infolded area would crush the visceral stents, although protecting the stents with a kissing balloon technique may have been feasible. Surgical repair with graft removal would require supraceliac clamping and removal of at least the fenestrated component as well as the visceral stents. Because of the patient's asymptomatic nature and general medical comorbidities, it was thought that any further intervention would not be suitable as the aneurysmal sac is regressing despite the infolding. The gutter caused by the infolding has not led to an endoleak to the aneurysmal sac. During 3 months, the aneurysm has regressed from 5.6 cm to 5.3 cm, indicating depressurization of the sac.

CONCLUSIONS

Fenestrated endograft infolding in the abdominal aorta is an extremely rare complication and is likely to be related to several contributing factors, including oversizing and asymmetry of the diameter-reducing ties. Intervention for this complication is more complex than for infolding from the thoracic or abdominal aorta because of visceral artery involvement. Conservative therapy in the short and medium term appears viable from our case.

REFERENCES

1. United Kingdom EVAR Trial Investigators, Greenhalgh RM, Brown LC, Powell JT, Thompson SG, Epstein D, Sculpher MJ. Endovascular versus open repair of abdominal aortic aneurysm. *N Engl J Med* 2010;362:1863-71.
2. British Society for Endovascular Therapy and the Global Collaborators on Advanced Stent-Graft Techniques for Aneurysm Repair (GLOBALSTAR) Registry. Early results of fenestrated endovascular repair of juxtarenal aortic aneurysms in the United Kingdom. *Circulation* 2012;125:2707-15.
3. Leung DA, Davis I, Katlaps G, Tisnado J, Sydnor MK, Komorowski DJ, et al. Treatment of infolding related to the Gore TAG thoracic endoprosthesis. *J Vasc Interv Radiol* 2008;19:600-5.
4. Mestres C, Maeso J, Fernandez V, Matas M. Symptomatic collapse of a thoracic aorta endoprosthesis. *J Vasc Surg* 2006;43:1270-3.
5. Rodd CD, Desigan S, Hamady MS, Gibbs RG, Jenkins MP. Salvage options after stent collapse in the thoracic aorta. *J Vasc Surg* 2007;46:780-5.
6. van Prehn J, Schlösser FJ, Muhs BE, Verhagen HJ, Moll FL, van Herwaarden JA. Oversizing of aortic stent grafts for abdominal aneurysm repair: a systematic review of the benefits and risks. *Eur J Vasc Endovasc Surg* 2009;38:42-53.
7. Sze DY, Mitchell RS, Miller DC, Fleischmann D, Frisoli JK, Kee ST, et al. Infolding and collapse of thoracic endoprostheses: manifestations and treatment options. *J Thorac Cardiovasc Surg* 2009;138:324-33.
8. Sternbergh WC, Money SR, Greenberg RK, Chuter TA. Influence of endograft oversizing on device migration, endoleak,

- aneurysm shrinkage, and aortic neck dilation: results from the Zenith multicenter trial. *J Vasc Surg* 2004;39:20-6.
9. Steinbauer MG, Stehr A, Pfister K, Herold T, Zorger N, Töpel I, et al. Endovascular repair of proximal endograft collapse after treatment for thoracic aortic disease. *J Vasc Surg* 2006;43:609-12.
 10. Idu MM, Reekers JA, Balm R, Ponsen KJ, de Mol BA, Legemate DA. Collapse of a stent-graft following treatment of a traumatic thoracic aortic rupture. *J Endovasc Ther* 2005;12:503-7.
 11. Matsagas MI, Papakostas JC, Arnaoutoglou HM, Michalis LK. Abdominal aortic endograft proximal collapse: successful repair by endovascular means. *J Vasc Surg* 2009;49:1316-8.
 12. Hinchliffe RJ, Krasznai A, SchultzeKool L, Blankensteijn JD, Falkenberg M, Lönn L, et al. Observations on the failure of stent-grafts in the aortic arch. *Eur J Vasc Endovasc Surg* 2007;34:451-6.
 13. Muhs BE, Balm R, White GH, Verhagen HJ. Anatomic factors associated with acute endograft collapse after Gore TAG treatment of thoracic aortic dissection or traumatic rupture. *J Vasc Surg* 2007;45:655-61.
 14. Won JY, Suh SH, Ko H, Lee KH, Shim WH, Chang BC, et al. Problems encountered during and after stent-graft treatment of aortic dissection. *J Vasc Interv Radiol* 2006;17:271-81.

Submitted Dec 1, 2016; accepted Apr 30, 2017.