

# Cementoblastoma of a primary molar: A rare pediatric occurrence

Gotur Palakshappa Suhasini<sup>1</sup>, Vijay Wadhwan<sup>1</sup>, Nitin Garg<sup>2</sup>

<sup>1</sup>Department of Oral Pathology and Microbiology, Subharti Dental College and Hospital, Swami Vivekanand Subharti University, Meerut,

<sup>2</sup>Dr. Nitin Multispeciality Dental Clinic and Facial Trauma Centre, Bharatpur, Rajasthan, India

## Abstract

Cementoblastoma is a relatively uncommon, benign odontogenic mesenchymal tumor that is associated with and attached to the roots of teeth. It is considered to be the only true neoplasm of cemental origin. Its prevalence has been reported to vary from 0.69% to 8% of all odontogenic tumors. The tumor is frequently seen in the second and third decades of life and affects the molar and premolar regions of the mandible predominantly. We herein describe a case of cementoblastoma occurring in association with primary teeth in a 5-year-old male patient with a brief review of literature. Only 20 cases of cementoblastoma involving primary teeth were found after the English literature search, the current case being the 21<sup>st</sup>. Moreover, the deciduous teeth-associated cementoblastomas (14 out of 20) show a distinct predilection for the right side of the face. The current case is the seventh one to involve the left side.

**Keywords:** Cementoblastoma, cementum, odontogenic tumor, primary molar, tooth root

**Address for correspondence:** Dr. Gotur Palakshappa Suhasini, Department of Oral Pathology and Microbiology, Subharti Dental College and Hospital, Swami Vivekanand Subharti University, Meerut, Uttar Pradesh, India.

E-mail: suhasrajukk@gmail.com

**Submitted:** 25-Oct-2019, **Accepted:** 06-Aug-2020, **Published:** 09-Jan-2021

## INTRODUCTION

Cementoblastoma, earlier known as benign cementoblastoma (true cementoma), is a relatively uncommon, benign odontogenic mesenchymal tumor that is associated with and attached to the roots of teeth. It is considered to be the only true neoplasm of cemental origin.<sup>[1]</sup>

Cementoblastoma is frequently seen in the second and third decades of life.<sup>[1]</sup> Well-documented cementoblastomas occurring in the first decade of life are scarce with less than 15 reports published till now. We herein describe a rare case of pediatric cementoblastomas occurring in association with primary teeth in a 5-year-old male patient with a brief

review of literature. Only 20 cases of cementoblastomas occurring in association with primary teeth are available in the literature,<sup>[2-21]</sup> the current case being the 21<sup>st</sup>. Moreover, the deciduous teeth-associated cementoblastomas (14 out of 20 published cases) show a distinct predilection for the right side of the face. The current case is the seventh one to involve the left side.

## CASE REPORT

A 5-year-old male patient reported to a general dental practitioner with a chief complaint of a pain and swelling in his left back teeth region for 10 days. His parents noticed mild swelling on the lower left side of the child's face for 1 week. Clinical examination revealed a diffuse firm

This is an open access journal, and articles are distributed under the terms of the Creative Commons Attribution-NonCommercial-ShareAlike 4.0 License, which allows others to remix, tweak, and build upon the work non-commercially, as long as appropriate credit is given and the new creations are licensed under the identical terms.

**For reprints contact:** WKHLRPMedknow\_reprints@wolterskluwer.com

**How to cite this article:** Suhasini GP, Wadhwan V, Garg N. Cementoblastoma of a primary molar: A rare pediatric occurrence. J Oral Maxillofac Pathol 2020;24:548-53.

### Access this article online

#### Quick Response Code:



#### Website:

www.jomfp.in

#### DOI:

10.4103/jomfp.JOMFP\_307\_19

tender swelling on the lower left side of the face and also intraorally in relation to mandibular posterior teeth with obliteration of the buccal vestibule. On palpation, there was mild expansion of the buccal cortical plate in relation to deciduous mandibular left second molar. Primary second molar on the involved side was also tender on percussion. Orthopantomograph showed a circumscribed globular radiopaque mass in continuity with the mesial root from which it arose. The tumor mass was surrounded by a thin, uniform radiolucent halo. The second premolar tooth bud was displaced distally by the tumor mass [Figure 1]. On the basis of the clinical and radiographic features, cementoblastoma, osteoblastoma, osteoma and odontoma were included in the differential diagnosis of this lesion. Considering the attachment to the tooth root on the radiograph, cementoblastoma seemed to be the appropriate diagnosis which needed the histopathological confirmation. Following written consent from the patient's parents, the tooth with the attached tumor mass was extracted under local anesthesia and was fixed in 10% formalin. The specimen was sent to the department of oral pathology and microbiology for histopathological examination. Postoperative period was uneventful.

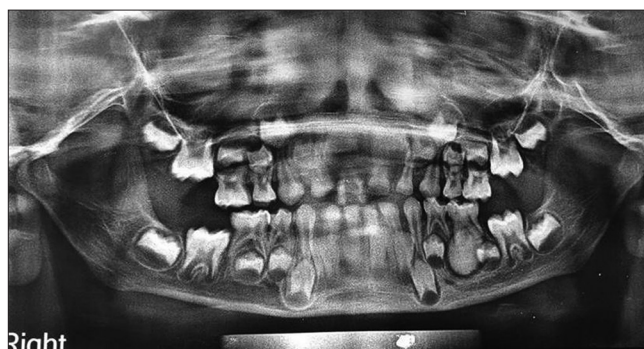### Gross

The specimen consisted of a left deciduous second mandibular molar with the mesial root completely embedded within a smooth, globular mass of hard tissue [Figure 2]. The tumor mass was creamish white to tan brown in color and measured 1.5 cm × 1.5 cm × 1 cm in dimensions. The specimen was bisected in mesial–distal direction using a low-speed rotating disc. Examination of the bisected surface showed partial resorption of both roots with mesial root embedded within the tan hard tissue and the other root lying on the surface of the hard tissue mass [Figure 3]. The continuity of the tumor mass with cementum was well appreciated in the stereomicroscopic photomicrograph of the specimen.

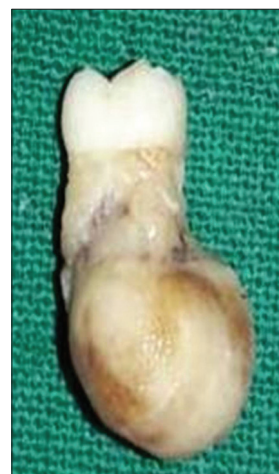### Microscopy

Histopathologically, examination of decalcified hemisection showed areas of radicular dentin with cementum-like tissue attached to it. The tumor mass was seen in continuity with root cementum [Figure 4]. It revealed abundant irregular trabeculae of basophilic mineralized tissue with prominent reversal lines, suggestive of cementum, interspersed with fibrovascular connective tissue. Toward the periphery of the hypocellular mineralized tissue, large cells within lacunae spaces were seen suggestive of cementoblasts [Figure 5]. A capsule-like band of fibrous connective tissue covering was apparent at few areas. Peripherally, characteristic perpendicular arrangement of the trabeculae to the external

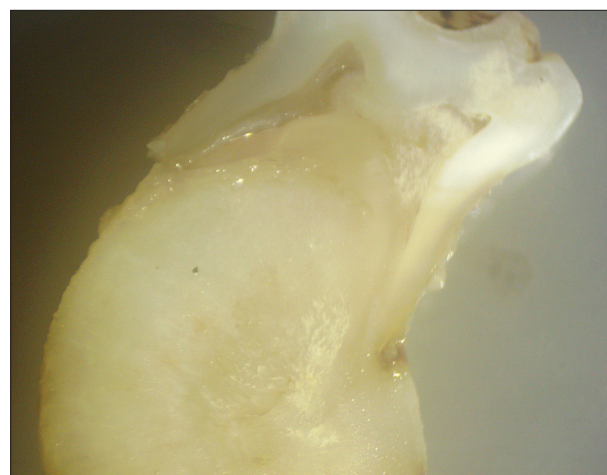
capsule was noted in the stereomicroscopic picture of the decalcified section [Figure 6]. All these radiographic and microscopic features confirmed the diagnosis of cementoblastoma.



**Figure 1:** Panoramic view showing well-defined radio-opacity surrounded by a radiolucent line attached to the mesial root of 75, displacing second premolar tooth bud



**Figure 2:** Gross specimen showing left deciduous second mandibular molar with the mesial root embedded within a smooth, hard globular tumor mass



**Figure 3:** Stereomicroscopic picture of the one half of the sectioned gross specimen, showing continuity of the tumor mass with the cementum

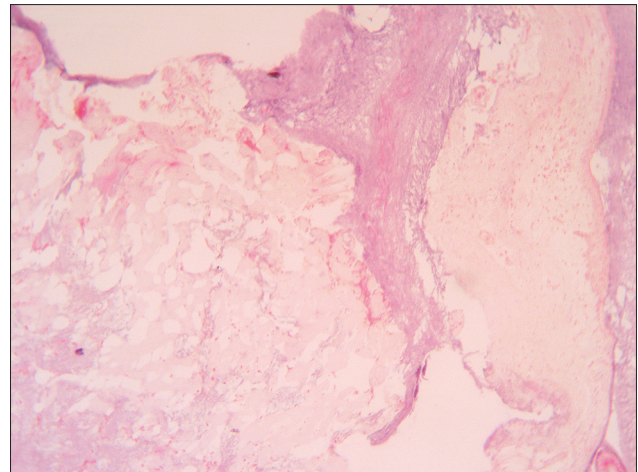


## DISCUSSION

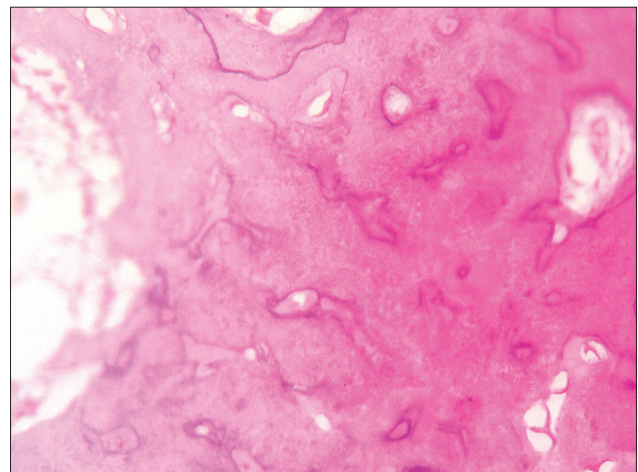
Cementoblastoma has been updated and continued in the WHO histological classification of odontogenic and maxillofacial bone tumors (4<sup>th</sup> edition, 2017) as benign mesenchymal odontogenic tumor (9273/0).<sup>[22]</sup> It is derived from the odontogenic ectomesenchyme of dental follicle which forms cementum. It was first described by Dewy in the year 1927<sup>[14]</sup> and was described by Norberg in the year 1930 as a slow-growing, benign odontogenic tumor arising from cementoblasts. It has three stages during its course of development – periapical osteolysis stage, cementoblastic stage and maturation and calcification stage.<sup>[23]</sup>

Its prevalence has been reported to vary from 0.69% to 8% of all odontogenic tumors. There does not appear to be any significant gender or racial predilection.<sup>[14]</sup> However, few studies suggested the predilection in Caucasians<sup>[24]</sup> and slight male predilection. The mean age of occurrence was 20.7 years.<sup>[25]</sup> Most cases are asymptomatic and detected on routine radiological examination although symptomatic cases have also been reported.<sup>[17]</sup> Clinical symptoms include expansion of bone, swelling and pain. The mandible is the most common site and usually associated with the roots of a mandibular permanent first molar or second premolar. The tumor also has been found to be associated with multiple teeth, impacted molars and deciduous teeth.<sup>[14]</sup> Even giant cementoblastoma almost spanning an entire quadrant<sup>[21]</sup> and a rare case of multiple cementoblastoma have been reported.<sup>[26]</sup> Most teeth affected by the cementoblastoma respond normally to the vitality tests during early stages of the lesion, but necrotic pulp can occur with this entity, usually in later stages.<sup>[27]</sup> The associated tooth may be nonresponsive to the vitality test, probably due to disruption of normal impulse transmission as the tumor mass encloses the root apex.<sup>[28]</sup>

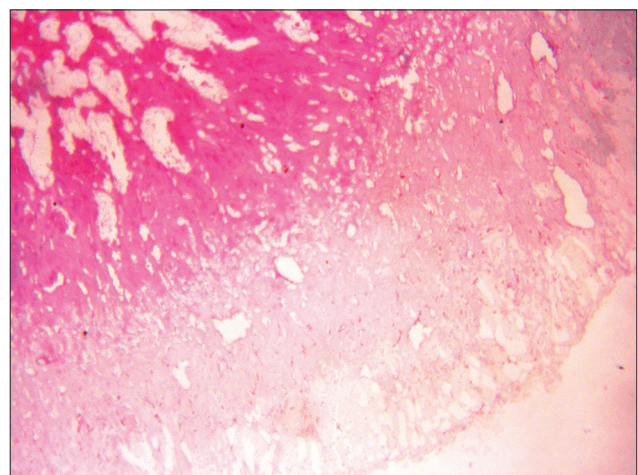
Well-documented cementoblastomas occurring in the first decade of life are scarce with <15 reports published till now. We herein describe a rare case of pediatric cementoblastomas occurring in association with primary teeth in a 5-year-old male patient with a brief review of literature. Only 20 cases of cementoblastomas occurring in association with primary teeth are available in the literature, the current case being the 21<sup>st</sup>. Moreover, the deciduous teeth-associated cementoblastomas (fourteen out of twenty published cases) show a distinct predilection for the right side of the face. The current case is the seventh one to involve the left side. Their sex, age and site distribution, together with the current case, are summarized in Table 1.



**Figure 4:** Photomicrograph of the decalcified section showing lesional tissue continuous with tooth root (H&E, x50)



**Figure 5:** Photomicrograph of the decalcified section cementum-like material with prominent reversal lines and intervening fibrovascular stroma (H&E, x100)



**Figure 6:** Stereomicroscopic picture of the decalcified section showing a perpendicular arrangement of trabeculae of mineralized tissue to the external surface (H&E, x50)

Of the 20 cases reported, 60% (12) were females and the age distribution of the reviewed cases at diagnosis varied

**Table 1: Reported cases of cementoblastoma involving deciduous teeth in chronological order**

Serial number	Author (years)	Age/sex	Involved tooth (side)
1	Chaput and Marc (1965) <sup>[2]</sup>	10/female	85 and 44 (right)
2	Vilasco <i>et al.</i> (1969) <sup>[3]</sup>	8/female	85 (right)
3	Zachariades <i>et al.</i> (1985) <sup>[4]</sup>	7/female	84, 85, 46 and 47 (right)
4	Herzog (1987) <sup>[5]</sup>	7/female	84 and 85 (right)
5	Papageorge <i>et al.</i> (1987) <sup>[6]</sup>	6/male	85 (right)
6	Cannell (1991) <sup>[7]</sup>	8/female	85 (right)
7	Schafer <i>et al.</i> (2001) <sup>[8]</sup>	8/female	85 (right)
8	Ohki <i>et al.</i> (2004) <sup>[9]</sup>	12/male	85, 44, 45, 46 and 47 (right)
9	Lemberg <i>et al.</i> (2007) <sup>[10]</sup>	11/female	85 (right)
10	Vieira <i>et al.</i> (2007) <sup>[11]</sup>	7/female	75 (left)
11	Netto <i>et al.</i> (2012) <sup>[12]</sup>	4/female	74 (left)
12	Monti <i>et al.</i> (2013) <sup>[13]</sup>	11/female	75 (left)
13	Lavanya <i>et al.</i> (2015) <sup>[14]</sup>	8/male	84, 85 (right)
14	Urs <i>et al.</i> (2016) <sup>[15]</sup>	10/male	54, 55 (right)
15	Nuvvula <i>et al.</i> (2016) <sup>[16]</sup>	7/female	85 (right)
16	Jolehar <i>et al.</i> (2016) <sup>[17]</sup>	5/male	85 (right)
17	Mohammadi <i>et al.</i> (2018) <sup>[18]</sup>	4.5/male	85 and 46 (right)
18	Garg B <i>et al.</i> (2019) <sup>[19]</sup>	10/male	75 (left)
19	Nagvekar <i>et al.</i> (2017) <sup>[20]</sup>	12/male	65 (left)
20	Javed A <i>et al.</i> (2017) <sup>[21]</sup>	10/female	65 and 22-27 (left)
21	Present case	5/male	75 (left)

from 4.5 to 12 years. The right side was the most frequent site of involvement (70%). Of these, 13 cases were found in associated with 85 and 12 cases had a single-tooth involvement.

Radiographically, cementoblastoma presents as a well-defined capsulated nonhomogenized radiopaque mass related to the root apex. The outline of the affected root is generally obliterated because of the resorption of the root and fusion of the mass to the tooth.<sup>[27]</sup> It may present as a wheel spoke pattern radiopaque–radiolucent lesion.<sup>[11]</sup> Immature lesions usually appear radiolucent, and then, the differential diagnosis should include an inflammatory cyst, osseous dysplasia, central giant cell lesions and ameloblastoma. As the lesion matures, its radiopacity increases, and ossifying fibroma, odontoma, osteoblastoma, fibrous dysplasia and calcifying odontogenic tumor must be considered. In a review of 36 diagnosed cases of cementoblastoma by Brannon *et al.*, 24 (66.7%) were radiopaque, 10 (27.7%) had mixed density and remaining 2 (5.5%) were radiolucent.<sup>[29]</sup>

Histopathologically, the tumor consists of a calcified mass fused with the tooth roots resulting in obliteration of the periodontal ligament. The tumor comprises sheets of calcified tissue with numerous prominent reversal lines and cementoblasts. The peripheral columns of cemental trabeculae show characteristic radiating arrangement perpendicular to the surface of the lesion, which was well appreciated in the present lesion. This

type of trabecular arrangement is responsible for a wheel spoke pattern radiopaque–radiolucent lesion presented in few case reports.<sup>[11]</sup> Use of van Gieson staining under polarized microscopy is also advocated to support the histopathological diagnosis with respect to its cemental origin.<sup>[15]</sup> The polarized light microscopy reveals a quilt-like pattern of the tumor mass. The radiological and histological features observed were sufficient for the diagnosis as cementoblastoma in the present case.

The differential diagnoses for cementoblastoma include solitary periapical cemental dysplasia, osteoblastoma, odontome, hypercementosis, condensing osteitis, juvenile ossifying fibroma and osteoma.<sup>[8,14,16,18,19]</sup> Rarely, fibrous dysplasia (radiographically) and osteosarcoma (histologically) can also be considered in the differential diagnosis.<sup>[8,14,23]</sup> The cementoblastoma is differentiated from its common mimickers by feature enlisted in Table 2.

Cementoblastoma’s clinical behavior is generally benign. It is not uncommon to see signs of local aggressiveness and destruction associated with these lesions. These signs include bony expansion, erosion of cortical plates, displacement of adjacent teeth, invasion of pulp chamber and root canals, and extension to and incorporation of adjacent teeth.<sup>[11]</sup> Involvement of adjacent structures such as maxillary sinus and nasal cavity has also been reported.<sup>[31,32]</sup> Aggressive signs such as root resorption, tooth displacement and bone expansion were observed in the present case.<sup>[11]</sup>

The treatment of choice is a complete removal of the lesion with extraction of associated tooth, followed by thorough curettage and peripheral ostectomy. A case has also been reported of endodontically preserving the tooth, while surgical removal of benign cementoblastoma is done.<sup>[33]</sup> Furthermore, there is a case report of cementoblastoma which is surgically treated while retaining the involved tooth.<sup>[34]</sup> As complete excision of the lesion had already been performed for biopsy purposes, no further treatment was required in this case. However, the patient was advised for a regular follow-up.<sup>[11]</sup> It is also a good plan to provide a space maintainer considering risk of space loss, as shown in a few case reports.<sup>[16]</sup> However, evaluation of follow-up data in a case series reported by Brannon *et al.* showed a high recurrence rate of about 37%. This was much higher as compared to a recurrence rate of 5.9% from the other reported cases.<sup>[32]</sup> With incomplete removal, recurrence is common and it appears to be highest for those who are treated with curettage alone.<sup>[19]</sup>



**Table 2: Differential diagnosis of cementoblastoma**<sup>[8,14,16,18,19,23]</sup>

Serial number	Lesion	Distinguishing radiographic or histologic feature
1	Cementoblastoma	Typical radiopaque mass attached to the root apex, described as golf-ball appearance, <sup>[30]</sup> histologically characterized by the formation of cementum-like tissue with numerous reversal lines. Histologically, fusion of the tumor with dental roots (which is known as replacement resorption) is a distinguishing feature <sup>[17]</sup>
2	Solitary periapical cemental dysplasia	It is small in size, shows a progressive change in radiographs from radiolucent to mixed to radiopaque over time and has an ill-defined radiolucent band surrounding the lesion, which is more clear and uniform in cementoblastoma
3	Osteoblastoma,	The cementoblastoma is distinguished from the histologically very closely related osteoblastoma by its location in an intimate association with the tooth root. The osteoblastoma arises in the medullary cavity of long bones
4	Odontome	It is usually not fused with the tooth root and appears as a more heterogeneous radiopacity
5	Hypercementosis	Hypercementosis is a small lesion and is not associated with pain or jaw swelling
6	Condensing osteitis	It can be differentiated by the presence of carious tooth with lack of peripheral radiolucent halo as seen in cementoblastoma
7	Juvenile ossifying fibroma	It is not attached with roots although is found in a similar age group with a predilection for the maxilla
8	Osteomas	Osteomas are not associated with a tooth
9	Fibrous dysplasia	It exhibits a ground-glass appearance radiographically blending with the normal host bone. Histologically, it consists of irregular separate trabecular of immature bone supported by a fibrous tissue stroma. The lesional bone fuses with the normal bone, thus masking the demarcation between lesional and host bone
10	Osteosarcoma	Sometimes because of highly active cellular appearance and pleomorphism of the cells, particularly at the periphery, cementoblastoma can be mistaken for osteosarcoma; however, cementoblastoma cells do not show mitotic activity

**CONCLUSION**

The present case describes a cementoblastoma associated with the left deciduous tooth. Despite its rare occurrence, cementoblastoma should be considered in the differential diagnosis of periapical radio-opaque lesions in the deciduous and transitional dentition in children. Due to their unlimited growth potential and the possibility of aggressive behavior, it is necessary to diagnose and treat such lesions at the earliest. Moreover, its early diagnosis is crucial to rule out more serious illnesses such as osteomas in Gardner’s syndrome preventing unnecessary treatment procedures.<sup>[14]</sup>

**Financial support and sponsorship**

Nil.

**Conflicts of interest**

There are no conflicts of interest.

**REFERENCES**

1. Wright JM, Soluk Tekkesin M. Odontogenic tumors: Where are we in 2017? J Istanbul Univ Fac Dent 2017;51:S10-S30.
2. Chaput A, Marc A. A case of cementoma localized on a temporary molar. SSO Schweiz Monatsschr Zahnheilkd 1965;75:48-52.
3. Vilasco J, Mazère J, Douesnard JC, Loubière R. A case of cementoblastoma. Rev Stomatol Chir Maxillofac 1969;70:329-32.
4. Zachariades N, Skordalaki A, Papanicolaou S, Androulakakis E, Bournias M. Cementoblastoma: Review of the literature and report of a case in a seven-year-old girl. Br J Oral Maxillofac Surg 1985;23:456-61.
5. Herzog S. Benign cementoblastoma associated with the primary dentition. J Oral Med 1987;42:106-8.

6. Papageorge MB, Cataldo E, Thanh M, Ngheim FT. Cementoblastoma involving multiple deciduous teeth. Oral Surg Oral Med Oral Path 1987;63:602-5.
7. Cannell H. Cementoblastoma of deciduous tooth. Oral Surg Oral Med Oral Pathol 1991;71:648.
8. Schafer TE, Singh B, Myers DR. Cementoblastoma associated with a primary tooth: A rare pediatric lesion. Pediatr Dent 2001;23:351-3.
9. Ohki K, Kumamoto H, Nitta Y, Nagasaka H, Kawamura H, Ooya K. Benign cementoblastoma involving multiple maxillary teeth: Report of a case with a review of the literature. Oral Surg Oral Med Oral Pathol Oral Radiol Endod 2004;97:53-8.
10. Lemberg K, Hagström J, Rihtniemi J, Soikkonen K. Benign cementoblastoma in a primary lower molar, a rarity. Dentomaxillofac Radiol 2007;36:364-6.
11. Vieira AP, Meneses JM Jr, Maia RL. Cementoblastoma related to a primary tooth: A case report. J Oral Pathol Med 2007;36:117-9.
12. de Noronha Santos Netto J, Marques AA, da Costa DO, de Queiroz Chaves Lourenço S. A rare case of cementoblastoma associated with the primary dentition. Oral Maxillofac Surg 2012;16:399-402.
13. Monti LM, Souza AM, Soubhia AM, Jorge WA, Anichinno M, Da Fonseca GL. Cementoblastoma: A case report in deciduous tooth. Oral Maxillofac Surg 2013;17:145-9.
14. Sirigala L, Dude Y, Gavada J, Sama B. Benign cementoblastoma of primary mandibular molars: A rarity. Sch J App Med Sci 2015;3:1312-5.
15. Urs AB, Singh H, Rawat G, Mohanty S, Ghosh S. Cementoblastoma solely involving maxillary primary teeth: A rare presentation. J Clin Pediatr Dent 2016;40:147-51.
16. Nuvvula S, Manepalli S, Mohapatra A, Mallineni SK. Cementoblastoma relating to right mandibular second primary molar. Case Rep Dent 2016;2016:2319890.
17. Jolehar M, Khalili M, Baghaee F. A rare odontogenic tumor known as cementoblastoma: A case report. J Res Dentomaxillofac Sci 2016;1:41-5.
18. Mohammadi F, Aminishakib P, Niknami M, Razi Avarzamani A, Derakhshan S. Benign cementoblastoma involving deciduous and permanent mandibular molars: A case report. Iran J Med Sci 2018;43:664-7.
19. Garg B, Chavada R, Pandey R, Gupta A. Cementoblastoma associated

- with the primary second molar: An unusual case report. *J Oral Maxillofac Pathol* 2019;23:111-4.
20. Nagvekar S, Syed S, Spadigam A, Dhupar A. Rare presentation of cementoblastoma associated with the deciduous maxillary second molar. *BMJ Case Rep* 2017;pii: bcr-2017-221977.
  21. Javed A, Hussain Shah SM. Giant cementoblastoma of left maxilla involving a deciduous molar. *J Ayub Med Coll Abbottabad* 2017;29:145-6.
  22. Takata T, Slootweg PJ. Odontogenic and maxillofacial bone tumours. In: El-Naggar AK, Chan JK, Grandis JR, Takata T, Slootweg PJ, editors. *WHO Classification of Head and Neck Tumours*. 4<sup>th</sup> ed. Lyon: IARC; 2017.
  23. Sitapathi R, Venkatapathy R, Balamurali PD, Nirima O. Benign cementoblastoma: A case report. *Int J Med Res Health Sci* 2016;5:73-6.
  24. Johny J, Kunjumon R, George GB, Sebastian J. A rare case of benign aggressive cementoblastoma. *J Indian Acad Oral Med Radiol* 2016;28:445-8.
  25. Sharma N. Benign cementoblastoma: A rare case report with review of literature. *Contemp Clin Dent* 2014;5:92-4.
  26. Iannaci G, Luise R, Iezzi G, Piattelli A, Salierno A. Multiple cementoblastoma: A rare case report. *Case Rep Dent* 2013;2013:828373.
  27. Kumar S, Prabhakar V, Angra R. Infected cementoblastoma. *Natl J Maxillofac Surg* 2011;2:200-3.
  28. Cundiff EJ 2<sup>nd</sup>. Developing cementoblastoma: Case report and update of differential diagnosis. *Quintessence Int* 2000;31:191-5.
  29. Brannon RB, Fowler CB, Carpenter WM, Corio RL. Cementoblastoma: An innocuous neoplasm? A clinicopathologic study of 44 cases and review of the literature with special emphasis on recurrence. *Oral Surg Oral Med Oral Pathol Oral Radiol Endod* 2002;93:311-20.
  30. Whaites E. *Essentials of Dental Radiography and Radiology*. 3<sup>rd</sup> ed. Edinburgh: Churchill Livingstone; 2002.
  31. Harada H, Omura K, Mogi S, Okada N. Cementoblastoma arising in the maxilla of an 8-year-old boy: A case report. *Int J Dent* 2011;2011:384578.
  32. Dadhich AS, Nilesh K. Cementoblastoma of posterior maxilla involving the maxillary sinus. *Ann Maxillofac Surg* 2015;5:127-9.
  33. Keyes G, Hilderbrand K. Successful surgical endodontics for benign cementoblastoma. *J Endod* 1987;13:566-9.
  34. Biggs JT, Benenati FW. Surgically treating a benign cementoblastoma while retaining the involved tooth. *J Am Dent Assoc* 1995;126:1288-90.