



Computational Fluid Dynamics Analysis of Trigeminal Neuralgia Associated with the Vertebral Artery: A Report of Two Cases

Kapil Patil¹ Fuminari Komatsu¹ Riki Tanaka¹ Kento Sasaki¹ Yasuhiro Yamada¹ Mai Okubo²
Tomoka Katayama² Kyosuke Miyatani¹ Sachin Chemate³ Toru Satoh⁴ Yoko Kato¹

¹Department of Neurosurgery, Fujita Health University, Bantane Hospital, Nagoya, Japan

²Department of Nurse Practitioner, Fujita Health University Hospital, Aichi, Japan

³Department of Neurosurgery, Noble Hospitals, Pune, Maharashtra, India

⁴Department of Neurosurgery, Satoh Neurosurgical Hospital, Matsunaga, Fukuyama, Japan

Address for correspondence Kapil Lotanrao Patil, MBBS, MCh, Department of Neurosurgery, Fujita Health University Bantane Hospital, Nagoya 454-0012, Japan (e-mail: dr.kapilpatil@gmail.com).

Asian J Neurosurg 2023;18:626–630.

Abstract

Keywords

- ▶ computational fluid dynamics
- ▶ microvascular decompression
- ▶ neurovascular contact
- ▶ trigeminal neuralgia
- ▶ wall shear stress magnitude

Trigeminal neuralgia is a nerve disorder that causes unilateral severe facial pain. The clinical features of trigeminal neuralgia are agonizing, paroxysmal, anticipated in one or more divisions of the trigeminal nerve, with repetitive bursts of a few seconds, exacerbated by cutaneous stimuli. Microvascular decompression is proven effective, resulting in a positive outcome. Here, we report two cases of trigeminal neuralgia associated with the vertebral artery, who underwent endoscopic microvascular decompression. This case report aims to show the benefit of computational fluid dynamics evaluation of the neurovascular contact and its effect on change in wall shear stress magnitude of the offending vertebral artery after surgical management with microvascular decompression.

Introduction

Trigeminal neuralgia (TN) has been referred to with the description of unilateral facial pain causing spasms by Greek physician Aretaeus in the 2nd century AD.¹ In 1756, Nicholas André coined the French term “tic douloureux” to describe the clinical characteristics of this syndrome.² Subsequently, the TN clinical features have been precisely characterized as agonizing, paroxysmal, perceived in one or more divisions of the trigeminal nerve, with repetitive bursts of few seconds, exacerbated by cutaneous stimuli.³

The specific mechanism of pain genesis of TN is still not known⁴; however, microvascular decompression (MVD) is effective and results in a favorable outcome in cases showing contact between an artery and the nerve, neurovascular contact (NVC).^{5,6} The offending arteries include the superior cerebellar artery (SCA), anterior inferior cerebellar artery, posterior inferior cerebellar artery (PICA), and vertebral artery (VA).^{7,8} Computational fluid dynamics (CFD) evaluation of the NVC may enhance the treatment strategy for TN and the morphological contact at the preoperative imaging and actual operative field.

article published online
September 22, 2023

DOI <https://doi.org/10.1055/s-0043-1771324>.
ISSN 2248-9614.

© 2023. Asian Congress of Neurological Surgeons. All rights reserved.

This is an open access article published by Thieme under the terms of the Creative Commons Attribution-NonDerivative-NonCommercial-License, permitting copying and reproduction so long as the original work is given appropriate credit. Contents may not be used for commercial purposes, or adapted, remixed, transformed or built upon. (<https://creativecommons.org/licenses/by-nc-nd/4.0/>)

Thieme Medical and Scientific Publishers Pvt. Ltd., A-12, 2nd Floor, Sector 2, Noida-201301 UP, India

Methods

In this study, the NVC of two cases of VA causing TN was investigated from the viewpoint of hemodynamic stress on VA at the NVC. The wall shear stress magnitude (WSSM) of the offending VA on computed tomography angiography (CTA) was analyzed and compared before and after MVD using CFD software (Hemoscope, EBM, Tokyo, Japan).

Results

Case 1

A 51-year-old man suffered from pinprick pain over the right lower lip. He received analgesics but had no relief. Neurological examination was normal. Magnetic resonance

cisternography (MRC) showed NVC at the proximal part of the trigeminal nerve by the VA (**Fig. 1A**). The fusion image of CT and MR images allows simultaneous visualization of details by CTA and trigeminal provided by MRC. CTA and MRC showed NVC; the right VA, SCA, and PICA complex compressed the trigeminal nerve (**Fig. 1B**).

Endoscopic MVD was performed. The trigeminal nerve was severely compressed directly by the PICA and indirectly by the VA. (**Fig. 1C**). For the decompression procedure, initially, the VA was transposed caudally and fixed with Teflon felt and fibrin glue. Next, Teflon felt was interposed between the PICA and the trigeminal nerve (**Fig. 1E**). The patient had complete relief from symptoms in the immediate postoperative period without complications.

CFD analysis was studied on the offending VA around NVC region before (**Fig. 1D**) and after MVD (**Fig. 1F**). The VA

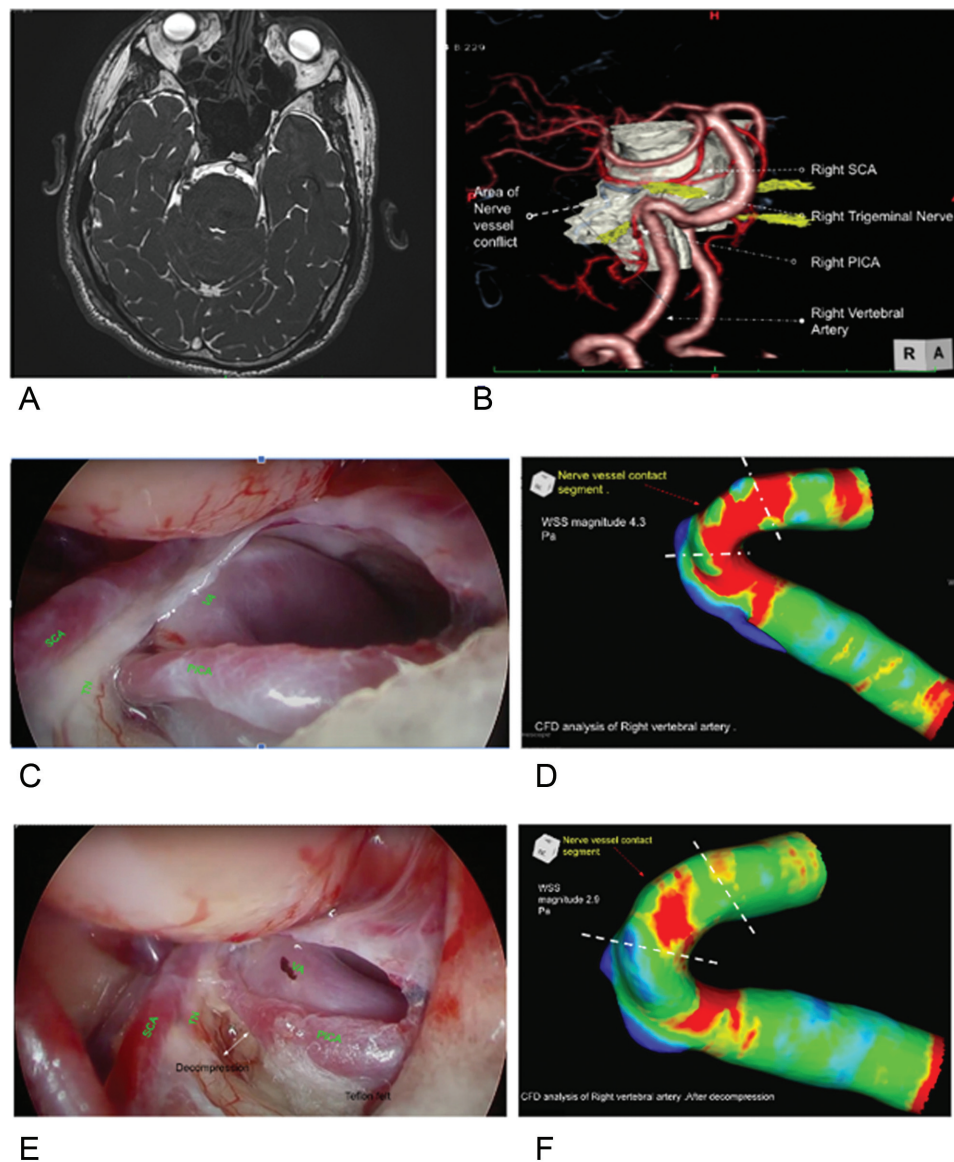


Fig. 1 (A) Magnetic resonance imaging (MRI) cisternogram showing right trigeminal nerve and vertebral artery nerve contact. (B) Computed tomography angiography (CTA) and MRI cisternogram fusion image showing neurovascular contact of the trigeminal nerve and vertebral artery (VA), superior cerebellar artery (SCA), and posterior inferior cerebellar artery (PICA). (C,E) Intraoperative endoscopic view before and after decompression. (D,F) Computational fluid dynamics (CFD) analysis before and after decompression. WSS, wall shear stress.

Table 1 WSS magnitude before and after endoscopic microvascular decompression showing a decrease in WSS magnitude from 4.3 Pa to 2.9 Pa

	WSS magnitude (Pa)
Preoperative	4.3
Post operative	2.9

Abbreviation: WSS, wall shear stress.

was separated into four segments for CFD analysis. The WSSM was obtained and compared before (►Fig. 1D) and after MVD (►Fig. 1F). As a result, WSSM at the NVC segment on the VA (4.3 Pa) was decreased after MVD (2.9 Pa; ►Table 1).

Case 2

A 75-year-old man suffered from pinprick pain over the left side of the tongue, lower jaw, and lower lip for 2 years. Conservative treatment by carbamazepine was given; however, complete pain relief was not obtained. MRC showed NVC at the proximal part of the trigeminal nerve by the left VA (►Fig. 2A).

The fusion image of CTA and MRC showed NVC. The trigeminal nerve was directly compressed by the PICA, and indirectly compressed by the VA (►Fig. 2B). The patient underwent endoscopic MVD. The trigeminal nerve was compressed by the VA and PICA complex (►Fig. 2C). VA was transposed caudally and fixed with Teflon felt and fibrin glue. Next, Teflon felt was interposed between the PICA and

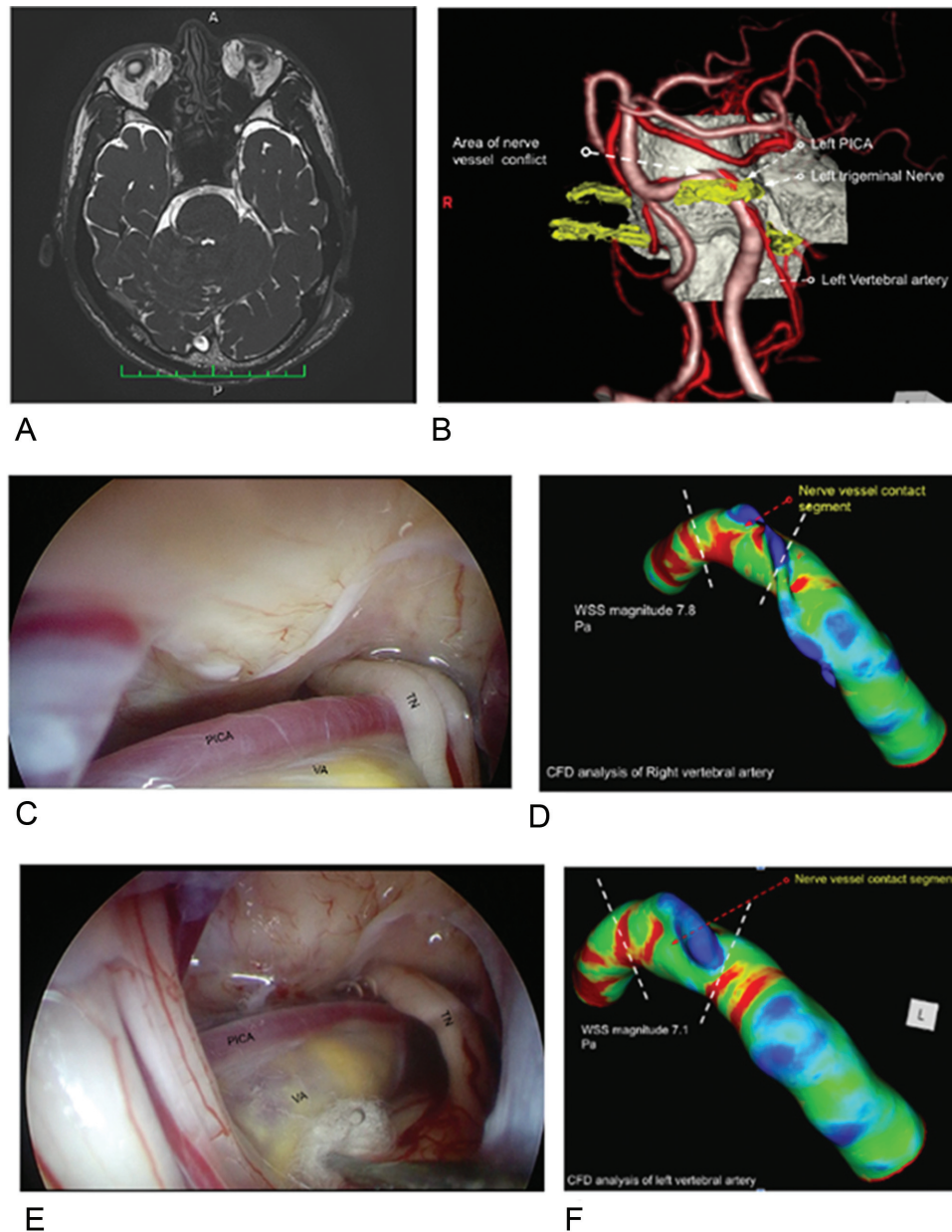


Fig. 2 (A) Magnetic resonance imaging (MRI) cisternogram showing right trigeminal nerve and vertebral artery nerve vessel contact. (B) Computed tomography angiography (CTA) and MRI cisternogram fusion image showing neurovascular contact of the trigeminal nerve and vertebral artery (VA), superior cerebellar artery (SCA), and posterior inferior cerebellar artery (PICA). (C,E) Intraoperative endoscopic view before and after decompression. (D,F) Computational fluid dynamics (CFD) analysis before and after decompression. TN, trigeminal neuralgia; WSS, wall shear stress.

Table 2 WSS magnitude before and after endoscopic microvascular decompression showing a decrease in WSS magnitude from 7.8 Pa to 7.1 Pa

	WSS magnitude (Pa)
Preoperative	7.8
Postoperative	7.1

Abbreviation: WSS, wall shear stress.

the trigeminal nerve (►Fig. 2E). The patient had complete relief from symptoms in the immediate postoperative period without complications.

CFD analysis was studied on the offending VA around NVC region before (►Fig. 2D) and after MVD (►Fig. 2F). The VA was separated into four segments for CFD analysis. The WSSM was obtained and compared before (►Fig. 2D) and after MVD (►Fig. 2F). As a result, WSSM at the NVC segment on the VA (7.8 Pa) was decreased after MVD (7.1 Pa; ►Table 2).

Discussion

The VA is associated with TN in 2 to 6% of cases.^{7,8} Usually, multiple vessels are associated with nerve vessel conflict in VA-related cases. Evaluation of the pathogenicity of the compression is mandatory to inspect the cause of TN because NVC also occurs in many asymptomatic patients.^{9,10}

Lin et al reported that a large diameter of the compressing artery increases the possibility of the contact being symptomatic.⁹ Since arteries are more expected to become symptomatic than veins, information, like flow, velocity, or pressure originating from blood flow, would also influence the pathogenicity of NVC.⁹

While assessing local hemodynamic parameters of cerebral arteries in vivo is challenging, image based CFD simulations have recently been proposed to investigate the local hemodynamics of cerebral vascular diseases.^{10,11} Among the various parameters secured from CFD simulation, WSS has been contemplated to play a key role in the interaction between blood flow and surrounding tissue. WSS is a frictional force of the blood on the epithelial layer. It is known to modulate intracellular signaling cascades and gene expression via stimulation of mechanoreceptors on the endothelial cells, resulting in the formation of cerebral vascular diseases, such as cerebral aneurysms and atherosclerosis.^{10,11} Thus, WSS may be used to indicate hemodynamic stress caused by the blood flow of the offending artery in TN patients. There may be a relationship between WSS and the pathogenicity of NVC. Recent studies have indicated the involvement of CFD in neurovascular compression syndrome.^{12–14} Satoh et al retrospectively analyzed the offending artery of 20 symptomatic TN and hemifacial spasm patients. They reported a relatively high magnitude of WSS at NVC compared with the surrounding site of NVC.¹³ We investigated the WSSM and numerically assessed WSSM in the individual cases in preoperative and post-operative CTA. At the offending segment, the segment of contact had multiple thin slices, and the mean of all thin slices was considered.

We have multiple vessels associated with symptomatic TN in these two cases. It is necessary to establish the involvement of a particular vessel in the causation of symptomatic nerve vessel conflict. WSSM is reduced after decompression. Both patients have complete symptomatic relief after decompression. Retrospectively we can conclude that the reduction in WSSM of the offending artery after MVD is associated with adequate decompression of nerve vessel conflict. Significant involvement of the VA in nerve vessel conflict. After analyzing a large number of cases, we may come up with statistical significance.

Conclusion

In this study, we report two cases of TN who underwent endoscopic MVD. This preliminary study indicates that CFD evaluation of the NVC may enhance the treatment strategy for TN, in addition to the morphological contact at the preoperative imaging and actual operative field and decrease of WSSM on the offending artery at the NVC after MVD can be an additional indicator of decompression.

Authors' Contributions

Kapil L. Patil contributed to conceptualization and drafting of the case report, review of the literature, and compilation of data. Fuminari Komatsu helped in operations and procedures, proofread the manuscript, and contributed substantially to the discussion. Kento Sasaki, Kyosuke Miyatani, Riki Tanak, Yasuhiro Yamada, Mai Okubo, Tomoka Katayama, and Sachin Chemate helped in data collection. Toru Satoh and Yoko Kato proofread the manuscript and contributed substantially to the discussion.

Conflicts of Interest

None declared.

References

- Rose FC. Trigeminal neuralgia. *Arch Neurol* 1999;56(09): 1163–1164
- Barker FG II, Jannetta PJ, Bissonette DJ, Jho HD. Trigeminal numbness and tic relief after microvascular decompression for typical trigeminal neuralgia. *Neurosurgery* 1997;40(01):39–45
- Burchiel KJ. A new classification for facial pain. *Neurosurgery* 2003;53(05):1164–1166, discussion 1166–1167
- Burchiel KJ. Trigeminal neuralgia: new evidence for origins and surgical treatment. *Neurosurgery* 2016;63(Suppl 1):52–55
- Jannetta PJ. Microsurgical approach to the trigeminal nerve for tic douloureux. *Prog Neurol Surg* 1976;7:180–200. Doi: 10.1159/000428328
- Cruccu G, Gronseth G, Alksne Jet al; American Academy of Neurology Society; European Federation of Neurological Society. AAN-EFNS guidelines on trigeminal neuralgia management. *Eur J Neurol* 2008;15(10):1013–1028
- Linskey ME, Jho HD, Jannetta PJ. Microvascular decompression for trigeminal neuralgia caused by vertebrobasilar compression. *J Neurosurg* 1994;81(01):1–9
- Vanaclocha V, Herrera JM, Martínez-Gómez D, Rivera-Paz M, Calabuig-Bayo C, Vanaclocha L. Is there a safe and effective way to treat trigeminal neuralgia associated with vertebrobasilar dolichoectasia? Presentation of 8 cases and literature review. *World Neurosurg* 2016;96:516–529

- 9 Lin W, Zhu WP, Chen YL, et al. Large-diameter compression arteries as a possible facilitating factor for trigeminal neuralgia: analysis of axial and radial diffusivity. *Acta Neurochir (Wien)* 2016;158(03):521–526
- 10 Malek AM, Alper SL, Izumo S. Hemodynamic shear stress and its role in atherosclerosis. *JAMA* 1999;282(21):2035–2042
- 11 Nixon AM, Gunel M, Sumpio BE. The critical role of hemodynamics in the development of cerebral vascular disease. *J Neurosurg* 2010;112(06):1240–1253
- 12 Kamath MV, Yamada Y, Kato Y. Computational fluid dynamics as an indicator of offending vessel in trigeminal neuralgia and hemifacial spasms. *Romanian Neurosurgery* 2018;32(3):418–425. <https://journals.lapub.co.uk/index.php/roneurosurgery/article/view/1111>
- 13 Satoh T, Yagi T, Onoda K, et al. Hemodynamic features of offending vessels at neurovascular contact in patients with trigeminal neuralgia and hemifacial spasm. *J Neurosurg* 2018;130(06):1–7
- 14 Temkar P, Kato Y, Yamada Y, Ansari A. Is there a role for computational fluid dynamics (CFD) in neurovascular compression syndrome? *Romanian Neurosurgery* 2018;32(2): 290–296. <https://journals.lapub.co.uk/index.php/roneurosurgery/article/view/1093>