

Airway management in cervical spine ankylosing spondylitis: Between a rock and a hard place

Address for correspondence:

Dr. Naveen Eipe,
Department of Anesthesiology,
University of Ottawa,
249C-1053 Carling Ave,
Suite B310, Ottawa, K1Y 4E9,
Ontario, Canada.
E-mail: neipe@toh.on.ca

Naveen Eipe, Susan Fossey, Stephen P Kingwell

Department of Anesthesiology, The Ottawa Hospital, 1053 Carling Ave, Suite B310, Ottawa, K1Y 4E9, Ontario, Canada

ABSTRACT

We report the perioperative course of a patient with long standing ankylosing spondylitis with severe dysphagia due to large anterior cervical syndesmophytes at the level of the epiglottis. He was scheduled to undergo anterior cervical decompression and the surgical approach possibly precluded an elective pre-operative tracheostomy. We performed a modified awake fiberoptic nasal intubation through a split nasopharyngeal airway while adequate oxygenation was ensured through a modified nasal trumpet inserted in the other nares. We discuss the role of nasal intubations and the use of both the modified nasopharyngeal airways we used to facilitate tracheal intubation. This modified nasal fiberoptic intubation technique could find the application in other patients with cervical spine abnormalities and in other anticipated difficult airways.

Key words: Airways, airways - difficult anticipated, co-existing diseases - ankylosing spondylitis, diffuse idiopathic skeletal hyperostosis, fiberoptic, intubation, intubation - awake, modified nasal trumpet, nasal, nasal - airway, split nasopharyngeal airway

Access this article online
Website: www.ijaweb.org
DOI: 10.4103/0019-5049.123333
Quick response code


INTRODUCTION

Ankylosing spondylitis (AS) is characterized by progressive ossification of the spinal column with resultant stiffness. AS does not typically result in dysphagia as the syndesmophytes are marginal. Dysphagia in the elderly is more commonly associated with diffuse idiopathic skeletal hyperostosis (DISH). Both these conditions, DISH and AS can be associated with anticipated difficult airway.^[1,2] We report the anaesthetic management of a patient with the unusual combination of a rigidly fused spine and focal exuberant anterior osteophytosis.

Patient has provided written consent to the reporting and publication of this case report.

CASE REPORT

A 69-year-old gentleman presented with 3 year history of progressive dysphagia. His past medical history was significant for AS with previous anaesthetics notable

for failed direct laryngoscopy and considerably difficulty with fiberoptic orotracheal intubation.

The patient's presenting dysphagia was first evaluated by the ear nose and throat (ENT) surgeon whose awake flexible fiberoptic nasoendoscopy revealed a significant bulging of the posterior pharyngeal wall into the airway at the level of the epiglottis. A plain X-ray and computed tomography scan of the spine demonstrated significant anterior cervical osteophytes from C3 to C5 with the largest osteophyte of size equivalent to the diameter of the vertebral body at level C3 and C4 [Figure 1 a and b]. Patient was referred to the Spine Surgery Unit and he was scheduled to undergo removal of the exuberant anterior cervical osteophytes for symptomatic relief of his dysphagia. The surgeons requested that an elective pre-operative tracheostomy be avoided, if possible as this would interfere with the planned surgical approach through an incision through the anterior triangle of the neck. In the Pre-anaesthetic Clinic, after careful evaluation and discussion with the patient, an awake fiberoptic intubation was planned.

How to cite this article: Eipe N, Fossey S, Kingwell SP. Airway management in cervical spine ankylosing spondylitis: Between a rock and a hard place. *Indian J Anaesth* 2013;57:592-5.

After an appropriate period of fasting, patient was brought to the OR with both the ENT and Spine Surgery teams in attendance. After standard monitoring was instituted, in the semi-sitting position; airway topicalization with 2% lidocaine spray was attempted. A right superior laryngeal nerve block and trans-tracheal injection were performed with 2 ml each of 2% lidocaine. Patient was placed supine, but as his head did not touch the mattress (*phantom pillow sign*); a stack of flannel in the configuration of a ramp was placed under his head, neck, and torso.

A modified nasal trumpet (MNT) was prepared by inserting a 15 mm universal connector from a 7.0 mm ID tracheal tube into the flanged end of a 30Fr nasal airway [simulated in Figure 2]. This was lubricated and inserted into the left nares. Oxygen (3 l/min) was delivered through this airway using the anaesthetic breathing circuit and capnography confirmed a patent airway and adequate spontaneous breathing. Into the other nares, the split nasopharyngeal airway (SNPA) was inserted. The SNPA is a 32Fr nasal airway, which had previously been cut spirally [simulated in Figure 2]. A standard adult fiberoptic bronchoscope (5.5 mm) was loaded with a size 7.0 mm ID reinforced tracheal tube (LMA Fastrach tube, Vitaid, Toronto, Canada). The bronchoscope was introduced through the SNPA and the large posterior pharyngeal wall bulge was evident. Advancing and rotating the SNPA caudad and posterior to the bony bulge was required to facilitate visualisation of the vocal cords, caudad and posterior to the bony bulge. The vocal cords were sprayed with 2cc of 2% lidocaine and the bronchoscope passed into the trachea without resistance. The SNPA was withdrawn out of the nares and peeled off the bronchoscope. The lubricated tracheal tube was then threaded off the bronchoscope into the trachea. Patient tolerated the procedure well and after confirmation of the appropriate position of the tracheal tube, anaesthesia was induced intravenously and then maintained with sevoflurane in an air-oxygen mixture using controlled ventilation.

The surgeons performed a left-sided anterior neck approach to the cervical spine and then proceeded to dissect the pharynx off of the osteophytes. The dissection was carried down to the pre-vertebral fascia covering the osteophytes. They removed the anterior osteophytes from C3 to 5. After removal of the bony elements, the pharynx was once again evaluated to make sure there was no soft-tissue pathology. The neck was closed in layers. Throughout the surgery, all monitored parameters remained stable.

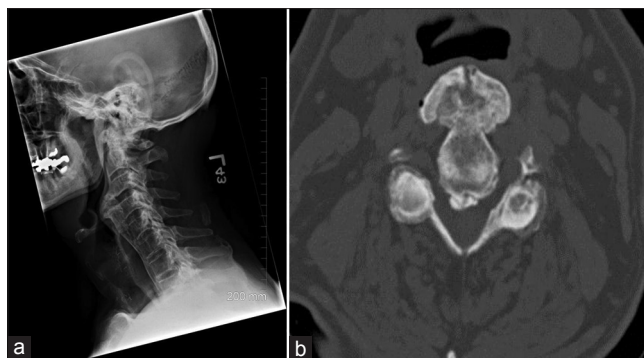

Figure 1: (a) Pre-operative plain radiograph of the neck showing anterior cervical osteophytes at the level of the epiglottis, (b) Pre-operative computerized tomogram showing the anterior cervical osteophyte at the level of the epiglottis with size equal to that of vertebral body




Figure 2: Simulation of the fiberoptic nasal intubation technique through split nasopharyngeal airway with a modified nasal trumpet *in situ*

At the end of surgery, the need for a definitive postoperative airway was discussed. The possibility of pharyngeal oedema and anticipated difficult airway due to the AS were considered and though leaving the trachea intubated was considered, it was decided that the patient would be best served by an elective tracheostomy. After the oxygen delivery was reduced to FiO_2 of 0.3, a tracheostomy was performed and the tracheal tube was removed. He woke up breathing comfortably and was monitored in the Post-Anaesthetic Care Unit overnight. The tracheostomy was decannulated on the 3rd post-operative day and he was discharged on the 5th post-operative day. When followed-up 6 weeks later, he continued to be doing well - his dysphagia partially resolved and he was able to swallow semi-solid food.

DISCUSSION

AS is a chronic, progressive autoimmune exonerative spondyloarthopathy that affects primarily the posterior

articulations of the spine and adjacent tissues.^[1] As the cervical spine involvement progresses, the decreasing neck extension can progress to a “chin on chest” deformity.^[2] There are other features of AS that contribute to the difficulty reported with videolaryngoscopy.^[3] Awake fiberoptic intubation is still widely recommended as the technique of choice in AS.^[4]

This patient presented with dysphagia attributed to large anterior cervical osteophytes. These osteophytes are more commonly associated with DISH. DISH is a non-inflammatory enthesopathy causing ossification of the anterior and lateral elements of the spine. Interestingly, it is reported as a common cause of dysphagia and aspiration in elderly patients with good results from surgical excision of the osteophytosis.^[5] Though there have been previous reports of patients with co-existent DISH and AS, our patient did not meet the criteria for the diagnosis of DISH.^[6] The etiology of this patient’s focal osteophytosis is unclear although may be post-traumatic or the result of incomplete fusion of the motion segment [Figure 1a]. Nevertheless, the DISH-like presentation of this patient was taken into consideration in our airway management plan. Failure of videolaryngoscopy has been reported in DISH, attributed to the disparity between size and angulation of the blade and the limited oro-pharyngeal space due to the cervical osteophytes.^[7]

Our planned modified awake fiberoptic intubation and preference for the nasal route was based on these abnormalities and the radiological images. Nasotracheal intubation is useful in some anticipated difficult airways and shown to require (and or produce) less cervical spine movement.^[8,9] Nasal fiberoptic intubation has previously been recommended in patients with lesions of the cervical spine.^[4,10] We believe that if only minimal movement of the neck is allowed (or possible), the nasopharyngeal axis is better aligned with the laryngeal and tracheal axes. In our patient, this is evident from the radiological images [Figure 1a]. Nasal bleeding is a concern with fiberoptic nasal intubation and it may either prevent fiberoptic view or contribute to airway obstruction.

We preferred to use the tracheal tube that is available with the LMA Fastrach because not only is this tube reinforced, its silicone tip is relatively soft and tends to “hug” the bronchoscope better. These latter two features may decrease the bleeding from nasotracheal intubations.

We also used two nasopharyngeal airways—one to ensure delivery of adequate oxygen (MNT) and the other (SNPA) to facilitate the fiberoptic intubation [Figure 2]. The MNT allows for connection to the anaesthetic breathing circuit and thereby facilitating continuous capnographic monitoring of airway patency and breathing. In addition, as required uninterrupted delivery of positive pressure ventilation and oro-pharyngeal suctioning can be performed while the fiberoptic intubation is being performed.^[11,12]

The SNPA was originally described for atraumatic nasogastric tube insertion.^[13] We suggest that the split be performed spirally as cutting it straight through tends to make the SPNA collapse in the nasopharynx. If the SPNA is adequately prepared (warm, soft, and lubricated with local anesthetic gel), it allows for nasal fiberoptic endoscopy to be performed with little distress to the awake patient. Most importantly, since the SNPA can be peeled off the bronchoscope, nasotracheal intubation can be facilitated [Figure 2]. When compared to direct nasal endoscopy, the SNPA may require less anaesthetic depth and affords for the fiberoptic procedure to be repeated atraumatically if required. In our patient, the SNPA additionally allowed us to navigate around the hard posterior pharyngeal bulge. We believe the use of these two nasal airways improved the safety and success of the difficult airway in the current patient.

The role of tracheostomies in cervical spine surgery is controversial.^[14] While they may be necessary in some patients, they may interfere with the surgical access to the spine and increase implant or surgical site infections. Airway management for the shared airway is often complicated by pre-operative abnormalities, intraoperative considerations and post-operative complications.^[15] This patient’s case report serves to provide additional information on various aspects of airway management for cervical spine surgery.

CONCLUSION

The use of the modified nasal airways and an awake fiberoptic nasal intubation was useful in our patient and should be considered in other similar situations. In such patients with bony hard anterior cervical osteophytes and a stiff spine from AS, literally; safe airway management may lie between a rock and a hard place.

REFERENCES

- Woodward LJ, Kam PC. Ankylosing spondylitis: Recent developments and anaesthetic implications. *Anaesthesia* 2009;64:540-8.
- Talikoti AT, Dinesh K, Kumar A, Goolappa. Ankylosing spondylitis: A challenge to anaesthesiologists due to difficulties in airway management and systemic involvement of disease. *Indian J Anaesth* 2010;54:70-1.
- Lai HY, Chen IH, Chen A, Hwang FY, Lee Y. The use of the GlideScope for tracheal intubation in patients with ankylosing spondylitis. *Br J Anaesth* 2006;97:419-22.
- Crosby ET, Grahovac S. Diffuse idiopathic skeletal hyperostosis: An unusual cause of difficult intubation. *Can J Anaesth* 1993;40:54-8.
- Kos MP, van Royen BJ, David EF, Mahieu HF. Anterior cervical osteophytes resulting in severe dysphagia and aspiration: Two case reports and literature review. *J Laryngol Otol* 2009;123:1169-73.
- Olivieri I, D'Angelo S, Palazzi C, Padula A, Mader R, Khan MA. Diffuse idiopathic skeletal hyperostosis: Differentiation from ankylosing spondylitis. *Curr Rheumatol Rep* 2009;11:321-8.
- Thompson C, Moga R, Crosby ET. Failed videolaryngoscope intubation in a patient with diffuse idiopathic skeletal hyperostosis and spinal cord injury. *Can J Anaesth* 2010;57:679-82.
- Eipe N. Nasotracheal intubation. *Br J Anaesth* 2005;95:426-7.
- Brimacombe J, Keller C, Künzel KH, Gaber O, Boehler M, Pühringer F. Cervical spine motion during airway management: A cinefluoroscopic study of the posteriorly destabilized third cervical vertebrae in human cadavers. *Anesth Analg* 2000;91:1274-8.
- Fuchs G, Schwarz G, Baumgartner A, Kaltenböck F, Voit-Augustin H, Planinz W. Fiberoptic intubation in 327 neurosurgical patients with lesions of the cervical spine. *J Neurosurg Anesthesiol* 1999;11:11-6.
- Beattie C. The modified nasal trumpet maneuver. *Anesth Analg* 2002;94:467-9.
- Shetty S, Henthorn RW, Ganta R. A method to reduce nasopharyngeal trauma from nasogastric tube placement. *Anesth Analg* 1994;78:410-1.
- Boyce JR, Waite PD, Louis PJ, Ness TJ. Transnasal jet ventilation is a useful adjunct to teach fibreoptic intubation: A preliminary report. *Can J Anaesth* 2003;50:1056-60.
- Crosby ET. Considerations for airway management for cervical spine surgery in adults. *Anesthesiol Clin* 2007;25:511-33, ix.
- Eipe N, Choudhrie A, Dildeep Pillai A, Choudhrie R. Elective pre-operative tracheostomy for head and neck oncological surgery. *Acta Anaesthesiol Scand* 2006;50:523-4.

Source of Support: Nil, **Conflict of Interest:** None declared

Announcement

FAMILY BENEVOLENT FUND OF ISA

Family Benevolent Fund (FBF) is one of the welfare programs of Indian Society of Anaesthesiologists (ISA). It is registered under the Societies Registration Act. Please visit the website www.isafbf.com. Membership is limited only to ISA members and President and Secretary are in the executive body of FBF. ISA member can be a member of FBF by paying the Membership fee depending on the age of members.

Up to 35 years	-	3,000/-
Up to 40 years	-	4,500/-
Up to 45 years	-	6,000/-
Up to 50 years	-	8,000/-
Up to 55 years	-	10,000/-
Up to 60 years	-	15,000/-

Age proof is required, the membership fee increased from April 2010. Immediate settlement of Fraternity amount to the nominee, in case of death of a member. So far 14 members were supported with an amount of Rs. 18 Lakhs.

Dr. S S C Chakra Rao

Secretary. FBF/ISA

67-B, Shanti Nagar,

Kakinada, Andhra Pradesh – 533003, India.

Mob.: +91 94401 76634

Email: secretaryfbf@isaweb.in

Website: www.isaweb.in and www.isafbf.com