

# A case report of congenital scoliosis associated with situs inversus totalis

Ce Zhu, MM, Shishu Huang, MD, Chunguang Zhou, MD, Xi Yang, MD, Lei Wang, MD, Tingxian Ling, MD, Limin Liu, MD\*, Yueming Song, MD

## Abstract

**Rationale:** Situs inversus totalis is a rare anomaly disease in which the organs in the chest and abdomen are positioned in a mirror image reversal of normal positions. Although this has been confirmed to be associated with spinal abnormalities, reports about situs inversus totalis with congenital scoliosis remain limited.

**Patient concerns:** We present a 9-year-old girl having congenital scoliosis associated with situs inversus totalis.

**Diagnoses:** She also had other associated anomalies: ventricular septal defect, mild restrictive ventilatory dysfunction, hydronephrosis, and syringomyelia. Her preoperative Cobb angle (T11–L3) was 78°.

**Interventions:** She received single growing rods treatment and subsequent posterior spinal fusion correction surgery for her scoliosis.

**Outcomes:** The coronal Cobb angle of the main curve was corrected to 20° postoperatively and no obvious loss of spinal corrective angle was identified 1 year after the correction surgery.

**Lessons:** Growing rods technique could be a safe and effective alternative for the treatment of scoliosis associated with situs inversus totalis. In the correction of left-sided lumbar curve of this kind of patients, the risks of aorta impingements should not be neglected when placing pedicle screws on the concave sides.

**Abbreviations:** EF = ejection fraction, EOS = early onset scoliosis, FEV<sub>1</sub> = forced expiratory volume in the first second, FVC = forced vital capacity, LEV = lower end vertebra, MRI = magnetic resonance imaging, NV = neutral vertebra, PS = pedicle screw, SV = stable vertebra, UEV = upper end vertebra, VBS = vertebral body stapling, VEPTR = vertical expandable prosthetic titanium rib.

**Keywords:** correction surgery, scoliosis, situs inversus totalis

## 1. Introduction

Situs inversus totalis is a rare disease in which organs of chest and abdomen are arranged in a mirror image reversal of the normal position. The prevalence is between 1: 5000 and 1: 10,000.<sup>[1]</sup> It has been reported to be associated with spinal anomalies such as tethered spinal cord, spina bifida, and scoliosis.<sup>[2–4]</sup> Congenital scoliosis is the most frequent congenital deformity of the spine and frequently associated with congenital heart disease, spinal

cord dysraphism, kidney malformations, and other malformations.<sup>[5]</sup> A coronal Cobb angle >70° could be treated as severe scoliosis.<sup>[6]</sup> Up to date, there are limited reports regarding the diagnosis and surgical treatment of congenital scoliosis associated with situs inversus totalis. As such, we present a 9-year-old girl having congenital scoliosis with situs inversus totalis who received a series of correction for her scoliosis.

## 2. Ethics approval and consent

This study was approved by the Medical Ethics Committee of West China Hospital of Sichuan University. And written informed consent was obtained from the patient's parents on behalf of the child for her correction surgery and publication of this case report and any accompanying images.

## 3. Case report

We present a 9-year-old patient who was admitted for her scoliosis deformity correction. The patient had no dyspnea, numbness or weakness of the limbs, headache, backache or extremity pain, or other symptoms. Her systemic examination revealed the apex cardiac beat on the right side, liver dullness on the left side, and the rib hump deformity. There was no family history of scoliosis and situs inversus totalis. She received convex growth arrest at another hospital because of the congenital scoliosis caused by T3 hemivertebra at the age of 2.

Her spinal plain radiographs showed that the Risser sign was 0, the cardiac silhouette and gastric air bubble were on the right side, and the coronal Cobb angle of the main curve (T11–L3) was

Editor: Richard Rison.

Funding: Nature Science Foundation of China (81472078) and Science and Technology Support Project of Sichuan Province (no. 2015SZ0028).

Ethical approval: This study was approved by the Medical Ethics Committee of West China Hospital of Sichuan University.

Informed consent: Informed consent was obtained from the parents of the child.

The authors have no conflicts of interest to disclose.

Department of Orthopedics Surgery, West China Hospital, Sichuan University, Chengdu, Sichuan, China.

\* Correspondence: Limin Liu, Department of Orthopedics Surgery, West China Hospital, Sichuan University, Chengdu, Sichuan, China (e-mail: liulimin\_spine@163.com).

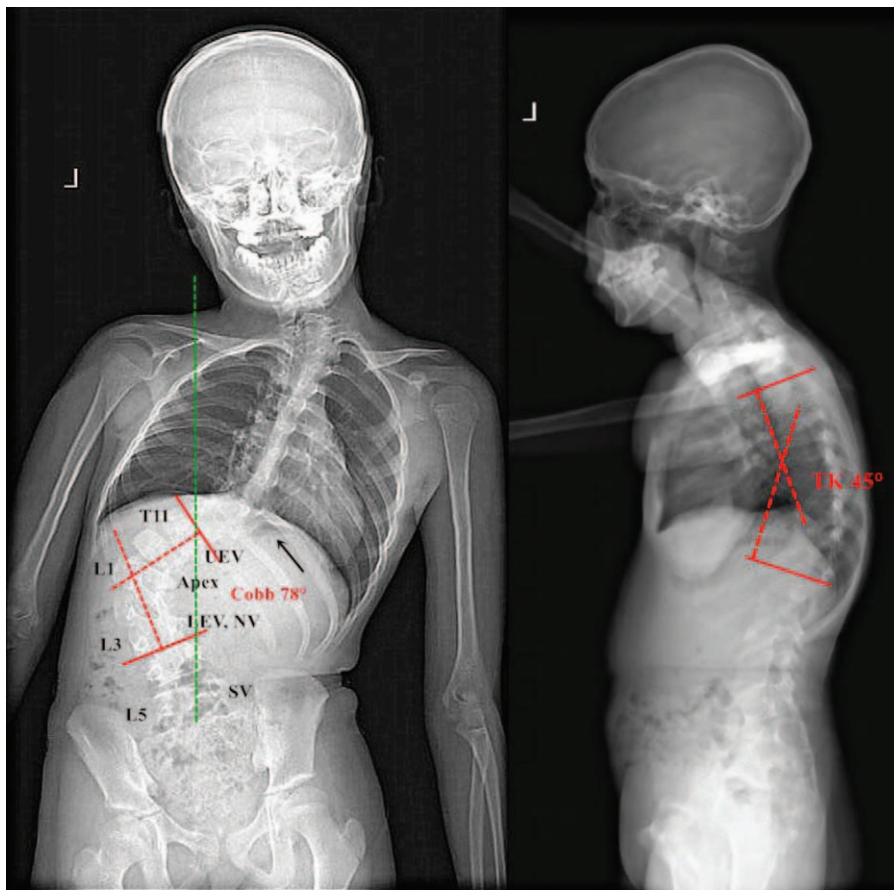
Copyright © 2017 the Author(s). Published by Wolters Kluwer Health, Inc. This is an open access article distributed under the Creative Commons Attribution-NoDerivatives License 4.0, which allows for redistribution, commercial and non-commercial, as long as it is passed along unchanged and in whole, with credit to the author.

Medicine (2017) 96:50(e9239)

Received: 3 January 2017 / Received in final form: 27 September 2017 /

Accepted: 21 November 2017

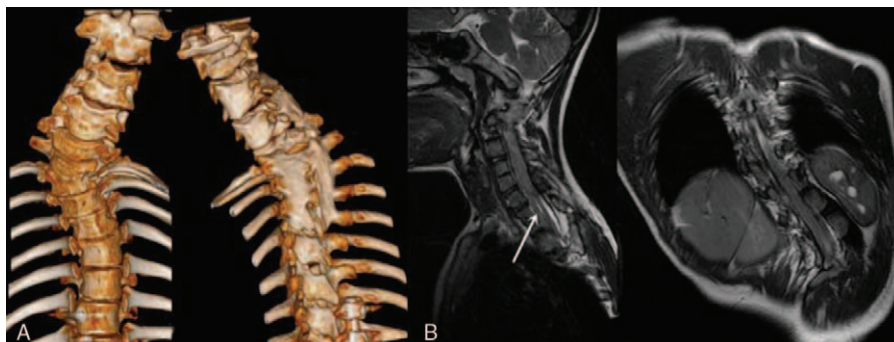
<http://dx.doi.org/10.1097/MD.0000000000009239>



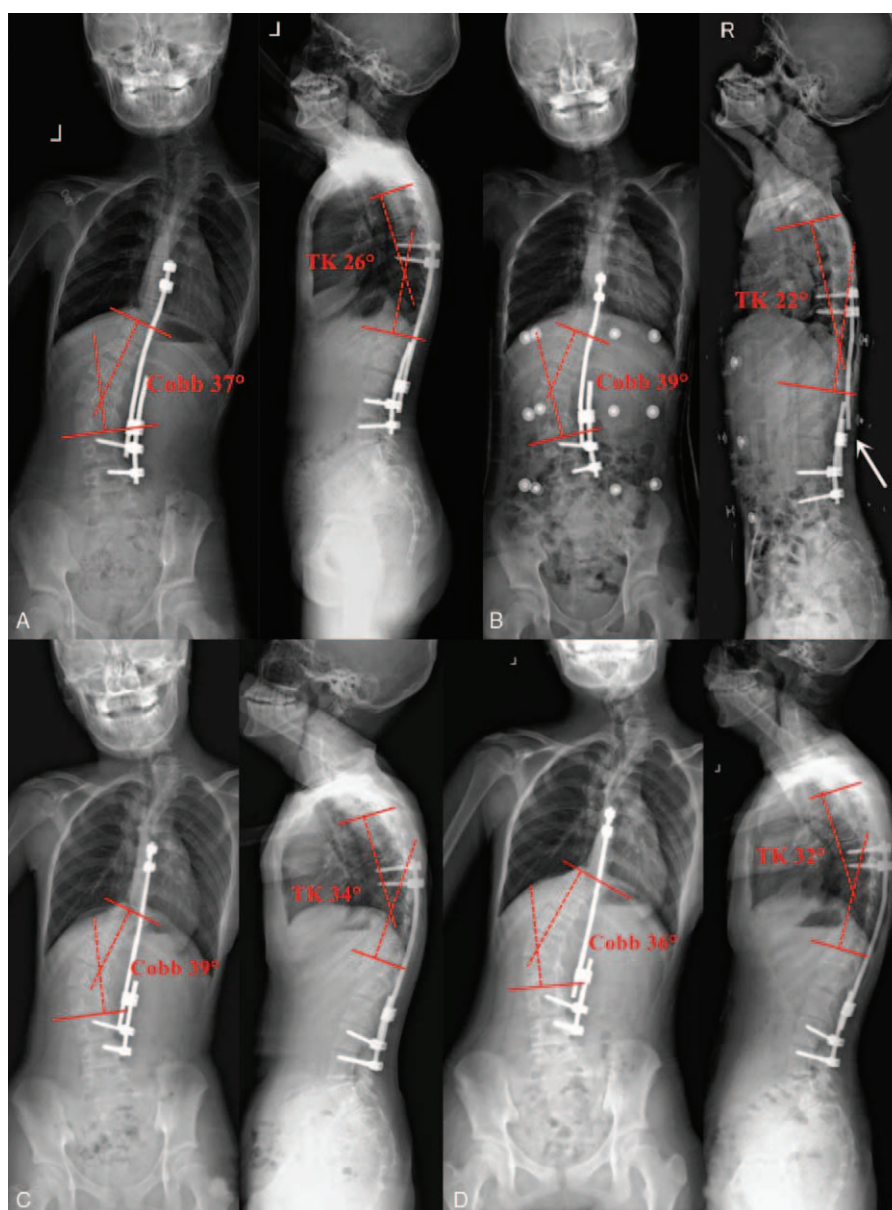
**Figure 1.** The preoperative spinal plain radiographs showing the cardiac silhouette and gastric air bubble (arrow) on the right side. They also demonstrated that the main curve (T11–L3) was 78° and TK was 45°. Apex = apex vertebra, LEV = lower end vertebra, NV = neutral vertebra, SV = stable vertebra, TK = thoracic kyphosis, UEV = upper end vertebra.

78°, suggesting the need for surgical correction (Fig. 1). She had an apex left curve and the upper end vertebra, lower end vertebra, apex vertebra, neutral vertebra, and stable vertebra was T11, L3, L1, L3, and L5, respectively (Fig. 1). The computed tomography (CT) scan showed congenital fusion of C2–3, C4–5, C6–7, the fusion of T1–4 resulting from previous growth arrest surgery, and left 1st and 2nd rib synostosis (Fig. 2A). Magnetic resonance imaging revealed the syrinx at the C6–T1 level without any other spinal cord or canal abnormalities (Fig. 2B). The cardiac ultrasound demonstrated that the diameter of the ventricular

septal defect was 2 mm and the ejection fraction was 68%. The pulmonary function test showed that the forced vital capacity (FVC) was 79.7% of predicted and the forced expiratory volume in 1 second/FVC ratio was 107.7%, which revealed the mild restrictive ventilatory dysfunction of the patient. The abdominal ultrasound revealed the hydronephrosis on the left side. Laboratory examination results, including full blood count, urinalysis, stool routine, hepatic, and renal functions, were normal. The preoperative Scoliosis Research Society (SRS)-22 pain, general self-image, function/activity, satisfaction, mental



**Figure 2.** (A) The CT scan showing congenital fusion of C2–3, C4–5, C6–7, the fusion of T1–4 resulting from previous growth arrest surgery, and left 1st and 2nd rib synostosis. (B) Magnetic resonance imaging (MRI) revealing the syrinx (arrow) at the C6–T1 level. CT = computed tomography.



**Figure 3.** The spinal plain radiographs before the final fusion surgery: (A) after the initial distraction, the main curve was corrected to 37° and TK was corrected to 26°; (B) the proximal rod was broken 4 months after the first lengthening (arrow); (C) after the revision surgery, the main curve was 39° and TK was 34°; (D) after the second distraction, the main curve was 36° and TK was 32°. TK = thoracic kyphosis.

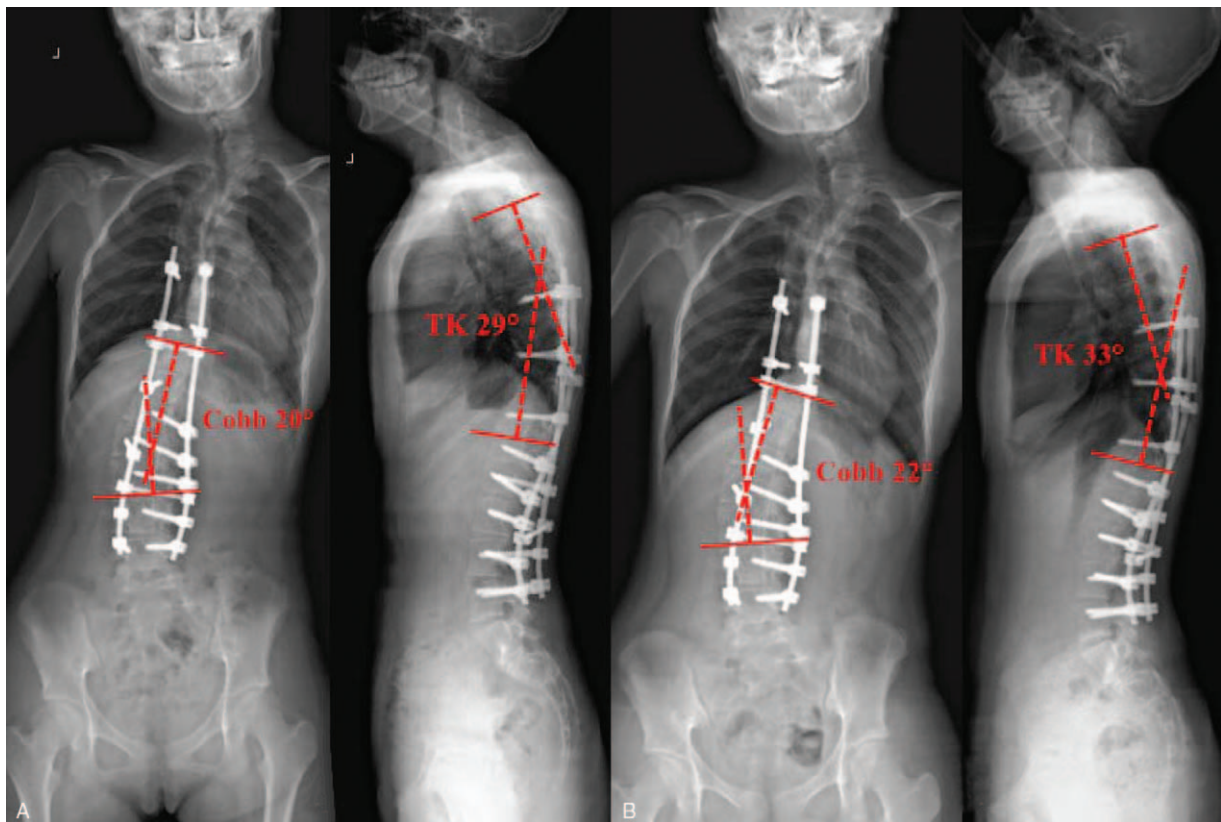
health, and total score were 5, 1.2, 4.4, 4.2, 2.5, and 17.3, respectively.

The diagnoses were severe congenital scoliosis, situs inversus totalis, syringomyelia, congenital heart defect, pulmonary dysfunction, and hydronephrosis. Before the surgical procedures, the patient was evaluated for her above-mentioned anomalies by cardiologists, respiratory physicians, urologists, general surgeons, neurosurgeons, and spine surgeons. And no specific treatments were required for her ventricular septal defect, mild restrictive ventilatory dysfunction, hydronephrosis, situs inversus totalis, or syringomyelia.

The patient underwent single growing rods treatment. The proximal and distal rod was attached to the T8 and T9 pedicle screws (PSs) and L4 and L5 PSs, respectively. They were connected by a Domino Connector (Medtronic, Fort Worth, TX). She underwent 2 distraction procedures before the final

fusion when she reached skeletal maturity (Fig. 3). The time interval of these 2 distraction procedures was 6 and 13 months, respectively. In the fourth month after the first lengthening, she underwent a revision surgery of her growing rods because the proximal rod was broken due to a strenuous exercise. At the age of 13, the Risser sign was 5, and she underwent the final fusion from T8 to L5 with posterior pedicle screw fixation. The operation took 4 hours and 5 minutes and the estimated blood loss amount was 500 mL. No abnormal signal was detected during the process of neuromonitoring. There were no neurological or other major complications related to the surgery. The coronal Cobb angle of the main curve was corrected to 20° postoperatively (Fig. 4A). The scoliosis correction rate was 74.3%, and the thoracic kyphosis had been corrected from 45° to 29°. At 1-year follow-up, there was no obvious loss of spinal corrective angle (Fig. 4B). Additionally, the SRS-22 scores





**Figure 4.** The spinal plain radiographs: (A) after the final fusion surgery, the main curve was corrected to 20° and TK was corrected to 29°; (B) at 1 year follow-up, the main curve was 22° and TK was 33°. TK = thoracic kyphosis.

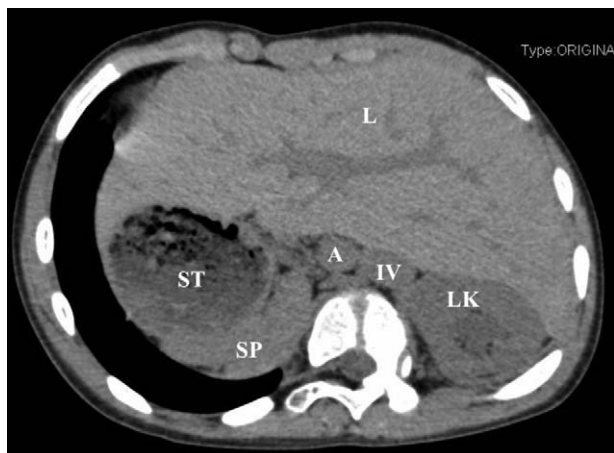improved than preoperation: SRS-22 pain, general self-image, function/activity, satisfaction, mental health and total score were 5, 3.8, 4.4, 4.4, 4.5, and 22.1, respectively. Both of the patient and her parents were satisfied with the outcomes.

#### 4. Discussion

Situs anomalies refers to an abnormal organ arrangement, which is rare, complex, and confusing.<sup>[7]</sup> Spinal malformations,

congenital heart disease, gastrointestinal or bowel malrotations, primary ciliary dyskinesia, and Kartagener syndrome have been identified among patients with situs anomaly.<sup>[8]</sup> There are 2 types of situs anomalies namely situs ambiguous and situs inversus.<sup>[8–10]</sup> Situs ambiguous, or heterotaxy, is characterized by disordered arrangement of the internal organs across the left–right axis of the body.<sup>[7]</sup> Unlike situs ambiguous, the organs maintain their normal relationship with each other in situs inversus.<sup>[10]</sup> Situs inversus is the mirror image of the normal visceral arrangement, including situs inversus with dextrocardia and situs inversus with levocardia.<sup>[11]</sup> Situs inversus with dextrocardia is also named situs inversus totalis and characterized by the complete mirror image of the normal arrangement of the heart and viscera. In our case, the x-ray and CT scan showed that the cardiac apex, spleen, stomach, and aorta were present on the right side, and the larger liver lobe and inferior vena cava were noted on the left side (Fig. 5). Thus, the image manifestations supported the diagnosis of situs inversus totalis.

Early onset scoliosis (EOS) is defined as curvature of the spine in children  $>10^\circ$  with onset before the age of 10 regardless of the etiology.<sup>[12]</sup> Our patient was a 9-year-old girl with congenital scoliosis, so she met the diagnostic criteria of EOS. The surgical treatment strategy for EOS includes growing rods technique, vertical expandable prosthetic titanium rib, the Shilla technique, vertebral body stapling, and hybrid systems.<sup>[12]</sup> Growing rods technique is widely used in the treatment of EOS with its satisfactory results of obtaining and maintaining deformity correction, achieving adequate spinal growth as well as thoracic growth, and allowing adequate lung development,<sup>[13]</sup> which is an important reason leading to our adoption of this technique. As



**Figure 5.** Preoperative CT scan. A=aorta, IV=inferior vena cava, L=liver, LK=left kidney, SP=spleen, ST=stomach. CT = computed tomography.

for the surgical approach, we did not choose anterior approaches, such as posterior instrumentation combined with an anterior release, or combined anterior and posterior surgical procedures with a period of halo traction after anterior release, in case of the risk caused by the position variation of the internal organs. Growing rods technique and subsequent spinal fusion correction surgery used in our patient were via posterior-alone approach and did not involve operations in thoracic or abdominal cavity, which meant that they were less affected by the abnormal visceral arrangement.

It has been widely recognized that the changed positions of scoliotic vertebrae can lead to the decreased distances between the vertebrae and the adjacent structures in scoliosis patients with increased potential risks of injuries of these structures from PS insertion.<sup>[14]</sup> And aorta impingement may be the most disastrous one among the complications caused by PSs.<sup>[15]</sup> Qiao et al<sup>[16]</sup> illustrated that the risks of the aorta impingement were mainly from the right PS in left-sided thoracolumbar/lumbar curves while from the left PS in right-sided curves. And placing PS carried more risks in the right-sided thoracolumbar/lumbar curve because the aorta was more proximal to entry points in the right-sided curve than that in the left-sided curve. For the patient in this study, she had a left-sided lumbar curve and her aorta shifted to the right side due to situs inversus totalis. Thus, the risks of aorta impingements were mainly from right PSs for her. Taking this into consideration, there were no aorta impingements intra- or postoperatively. In the correction of the left-sided lumbar curve of scoliosis associated with situs inversus totalis, the risks of aorta impingements should not be neglected when placing PSs on the concave sides.

The main strength in the management of this patient was the satisfactory correction of deformity with no neurological or other major complications related to the surgery. And optimal preoperative preparation and appropriate surgical option were the reasons for achieving this pleasant outcome. However, our patient lacked longer term follow-up time. Therefore, a longer follow-up period is needed to evaluate the clinical and radiographic outcomes.

## 5. Conclusions

Growing rods technique could be a safe and effective alternative for the treatment of scoliosis associated with situs inversus totalis.

In the correction of the left-sided lumbar curve of this kind of patients, the risks of aorta impingements should not be neglected when PSs are on the concave sides.

## References

- [1] Kamiike W, Itakura T, Tanaka H, et al. Hepatic segmentectomy on primary liver cancer with situs inversus totalis. *HPB Surg* 1996; 9:169–73.
- [2] Yazicioglu A, Alici IO, Karaoglanoglu N, et al. Pitfalls and challenges of lung transplant in a patient with Kartagener syndrome and scoliosis. *Exp Clin Transplant* 2016;71:13–4.
- [3] Piegger J, Gruber H, Fritsch H. Case report: human neonatus with spina bifida, clubfoot, situs inversus totalis and cerebral deformities: sequence or accident? *Ann Anat* 2000;182:577–81.
- [4] Dwarakanath S, Suri A, Garg A, et al. Adult complex spinal dysraphism with situs inversus totalis: a rare association and review. *Spine* 2005;30:225–8.
- [5] Arlet V, Odent T, Aebi M. Congenital scoliosis. *Eur Spine J* 2003; 12:456–63.
- [6] Qiu Y, Liu Z, Zhu F, et al. Comparison of effectiveness of Halo-femoral traction after anterior spinal release in severe idiopathic and congenital scoliosis: a retrospective study. *J Orthop Surg Res* 2007;2:23.
- [7] Applegate KE, Goske MJ, Pierce G, et al. Situs revisited: imaging of the heterotaxy syndrome. *Radiographics* 1999;19:837–52.
- [8] Bonic EE, Kettner NW. Total situs inversus: a rare anomaly presenting to a chiropractic teaching clinic. *J Manipulative Physiol Ther* 2009;32:321–5.
- [9] Maldjian PD, Saric M. Approach to dextrocardia in adults: review. *AJR Am J Roentgenol* 2007;188:S39–49.
- [10] Peeters H, Devriendt K. Human laterality disorders. *Eur J Med Genet* 2006;49:349–62.
- [11] Fulcher AS, Turner MA. Abdominal manifestations of situs anomalies in adults. *Radiographics* 2002;22:1439–56.
- [12] Yang S, Andras LM, Redding GJ, et al. Early-onset scoliosis: a review of history, current treatment, and future directions. *Pediatrics* 2015;137: e20150709.
- [13] Sun ZJ, Qiu GX, Zhao Y, et al. Dual growing rod treatment in early onset scoliosis: the effect of repeated lengthening surgeries on thoracic growth and dimensions. *Eur Spine J* 2015;24:1434–40.
- [14] Jiang J, Qian BP, Zhu ZZ, et al. Different potential risk of injury from thoracic pedicle screw insertion between left and right main-stem bronchus in Lenke 1 type adolescent idiopathic scoliosis. *Eur Spine J* 2016;25:1794–9.
- [15] Chen L, Xu L, Qiu Y, et al. The risks of aorta impingement from pedicle screw may increase due to aorta movement during posterior instrumentation in Lenke 5C curve: a computed tomography study. *Eur Spine J* 2015;24:1481–9.
- [16] Qiao J, Zhu F, Xu L, et al. Comparison of the aorta impingement risks between thoracolumbar/lumbar curves with different convexities in adolescent idiopathic scoliosis: a computed tomography study. *Eur Spine J* 2012;21:2043–9.