



Contents lists available at ScienceDirect

## International Journal of Surgery Case Reports

journal homepage: [www.casereports.com](http://www.casereports.com)

# Septic shock caused by acute appendicitis complicated with abscess formation within mesoappendix: A case report

Yifan Man, Shikuan Li\*, Zongping Yu

Department of Emergency General Surgery, The Affiliated Hospital of Qingdao University, Qingdao, Shandong 266003, PR China

## ARTICLE INFO

### Article history:

Received 15 August 2020

Received in revised form

20 September 2020

Accepted 22 September 2020

Available online 28 September 2020

### Keywords:

Appendicitis

Septic shock

Mesoappendix

Laparoscopic appendectomy

## ABSTRACT

**INTRODUCTION:** Acute appendicitis is the most common surgical emergency and may present with a wide variety of clinical manifestations. In rare circumstances, appendicitis can cause life-threatening complications e.g. septic shock. We present a case of septic shock caused by acute appendicitis complicated with abscess formation within the mesoappendix.

**PRESENTATION OF CASE:** A 42-year-old male was presented with migratory right lower abdominal pain, accompanied by septic shock and acute kidney failure. We performed emergency appendectomy and unexpectedly observed an abscess within the mesoappendix during surgery. The patient received antibiotic therapy perioperatively. *Escherichia coli* and *Klebsiella pneumoniae* subspecies were isolated from the intraoperative pus specimen, and *Bifidobacterium* was isolated from his preoperative blood culture. Histopathology revealed acute suppurative appendicitis. The patient recovered uneventful and was discharged 5 days after surgery.

**DISCUSSION:** We believe that the septic shock was associated with the small abscess formation in the mesoappendix. Bacteria within the mesoappendix could enter the bloodstream through the mesoappendiceal vessel and then septic shock and kidney failure occurred sequentially. We assume that the abscess within the mesoappendix was caused by a tiny perforation from the mesoappendiceal side.

**CONCLUSION:** The case of acute appendicitis complicated with abscess formation within mesoappendix explains one of the causes which may lead to septic shock.

© 2020 The Authors. Published by Elsevier Ltd on behalf of IJS Publishing Group Ltd. This is an open access article under the CC BY-NC-ND license (<http://creativecommons.org/licenses/by-nc-nd/4.0/>).

## 1. Introduction

Acute appendicitis is one of the most common surgical emergencies and may present with a wide variety of clinical manifestations [1]. In rare circumstances, appendicitis can cause life-threatening complications e.g. septic shock. It is well recognized that all cases of complicated appendicitis require surgical intervention because of the high risk for nonoperative treatment failure. In addition, in appendicitis complicated by septic shock, even though no evidence of perforation is seen in CT imaging, surgical decisions should be made while considering the strategy on infection source control. We present a case of septic shock caused by acute appendicitis complicated by abscess formation within the mesoappendix. This case report has been written in accordance with the SCARE criteria [2].

## 2. Presentation of case

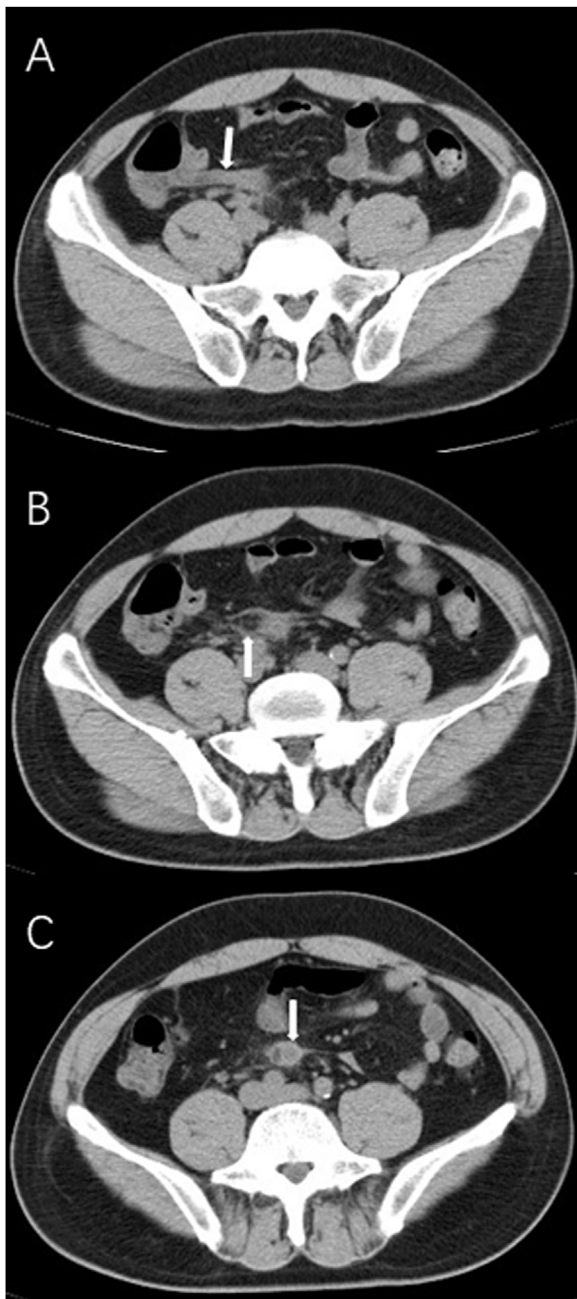A 42-year-old male farmer without any known comorbidities and an unremarkable past medical history, was presented to the

emergency room by ambulance with a four-day history of migratory right lower abdominal pain. Additionally, the patient also complained of anorexia, nausea and weakness. He was febrile with a body temperature as high as 38.7 °C. On examination, the patient was found to be tachycardic (129 beats/min) and hypotensive (70/40 mmHg). Abdominal examination demonstrated localized tenderness, rebound tenderness, and guarding in the right iliac fossa. Laboratory test results revealed leukocytosis ( $18.04 \times 10^9/L$  with 91.04% neutrophils), increased C-reactive protein (145.33 mg/L) and procalcitonin (>150 ng/mL). Renal function tests showed acute kidney injury with blood urea nitrogen to creatinine (BUN/Cr) ratio of 10.8 mmol/L/217.7 μmol/L. Liver function tests, electrolytes and urinalysis were unremarkable. CT scan of the abdomen and pelvis demonstrated a thickened appendix with swollen mesoappendix, and without appendicolith (Fig. 1).

The patient received fluid resuscitation due to septic shock and was started empirically on cefoperazone/sulbactam in the ER. Additionally, norepinephrine was given to maintain the blood pressure and emergency laparoscopic appendectomy was performed. We used the conventional three-trocar technique, and created and maintained pneumoperitoneum insufflation with carbon dioxide. Upon exploration of the abdominal cavity, the greater omentum and terminal ileum were found adhered to the right lateral abdom-

\* Corresponding author.

E-mail address: [worldwidth@aliyun.com](mailto:worldwidth@aliyun.com) (S. Li).



**Fig. 1.** CT demonstrated a thickened appendix (A), swollen mesoappendix (B) and enlarged tip of the appendix (C).

inal wall. After lysis of the abdominal adhesions, the inflamed appendix with a thickened and congestive distal end, and swollen mesoappendix, which lied between the terminal ileum and the posterior peritoneum, became visible. Then, we inserted an additional 5 mm trocar at the McBurney point to obtain better visualization.

We divided the mesoappendix towards the base of the appendix using an electrocautery hook. Unexpectedly, whitish-yellow pus squirted outside the incision of the mesoappendix into the abdominal cavity, a total volume of about 1 mL. We accurately identified that the leaking pus came from the swollen mesoappendix and not from an opening in the appendiceal lumen. The appendiceal artery was ligated using a Hem-o-lok® (Teleflex) clip; hereafter, the entire mesoappendix was coagulated and transected. The cut mesoappendix seemed gangrenous and no perforation was observed with the naked eye (Fig. 2). The appendix stump was closed with sin-

gle Endoloop® (Ethicon) ligature. The specimen was placed in an endoscopic retrieval bag and removed after clearly suctioning the operating field as well as the pelvis. Finally, a drainage tube was placed into the abdominal cavity through the side trocar. The specimen was sent for histopathology and the results indicated acute suppurative appendicitis.

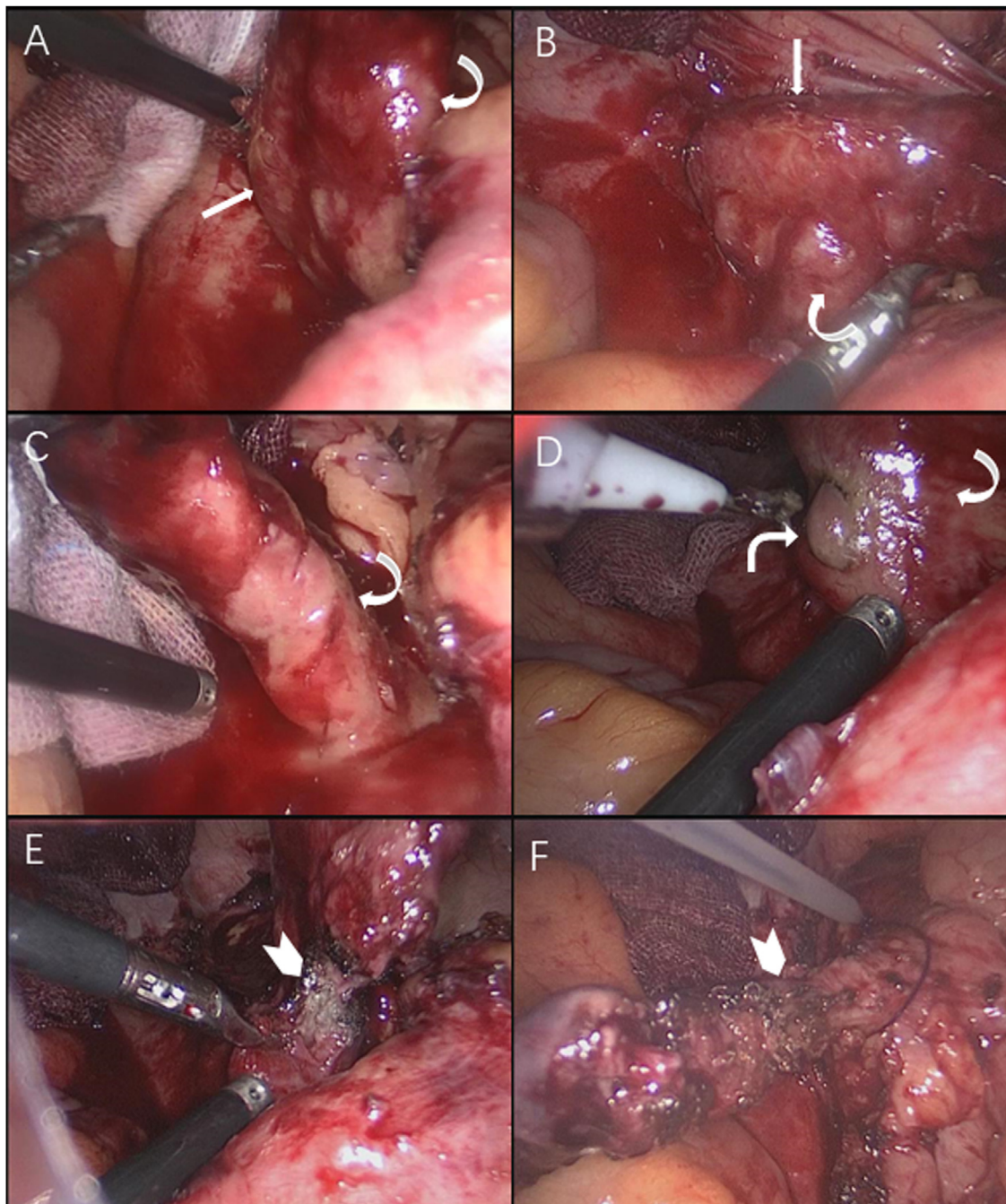
Antibiotic treatment was upgraded by prescribing imipenem/cilastatin instead of cefoperazone/sulbactam because we worried about cefoperazone/sulbactam resistance. The patient's postoperative vital signs gradually stabilized with the continuation of antibiotic therapy and the norepinephrine pump was withdrawn. *Escherichia coli* and *Klebsiella pneumoniae* subspecies were isolated from the intraoperative pus specimen, both of which were sensitive to cefoperazone/sulbactam and imipenem/cilastatin. The markers of infection such as white blood cell count, C reactive protein and procalcitonin declined rapidly, and the renal function test returned to the normal range. The drainage volume was less than 20 mL and the drainage tube was removed on postoperative day 3. The patient recovered uneventfully and was discharged from the hospital 5 days after surgery. After discharge, a delayed laboratory report revealed that Bifidobacterium was isolated from his preoperative blood culture which was also sensitive to previously used antibiotics. He has remained well till our recent follow-up at 18 months postoperatively. We have obtained permission from the patient to report this rare case for medical communication purposes.

### 3. Discussion

Acute appendicitis is an infectious disease. Both, aerobic and anaerobic, gram-negative and gram-positive bacteria are involved in appendicitis. The most common pathogens are Bacteroides species and gram-negative bacilli such as *Escherichia coli*, *Klebsiella* or *Enterobacter* [3]. Appendicitis is typically caused by luminal obstruction, and this may be due to lymphoid hyperplasia and appendicolith, resulting in the invasion of the appendix wall by the gut flora. The increased intraluminal pressure may lead to venous congestion, arterial insufficiency, ischemia, necrosis and ultimately perforation. In cases of perforated appendicitis, spillage of infected and fecal matter into the peritoneal cavity may lead to peritonitis and life-threatening infection. However, despite perforation, septic shock caused by appendicitis has rarely been reported [4,5].

In view of the clinical manifestations, perforated appendicitis is almost certain when signs of peritoneal irritation and septic shock occur. However, there no evidence of perforation was observed in this case, not on preoperative CT imaging, and certainly not during the operating procedure. Thus, we believe that septic shock was associated with the small abscess formation in the mesoappendix. Bacteria within the mesoappendix could enter the bloodstream through the mesoappendiceal vessel and then septic shock and kidney failure occurred sequentially. The question is: how was the abscess in the mesoappendix formed? Since the suppurative appendicitis microscopically appeared as transmural inflammation, ulceration, or thrombosis, with or without extramural pus [6], the pathogens may migrate to the serosa of the appendix including the mesoappendiceal direction. If focal mural necrosis had occurred, the appendiceal wall may perforate through antimesenteric portions and the mesoappendiceal margin and cause intraperitoneal infection. In fact, the perforation towards the mesoappendix could have happened but was ignored. We assumed that the abscess within the mesoappendix was caused by a tiny perforation on the mesoappendiceal side, because perforation was not always visible under the microscope [6].

Up to now, many studies have demonstrated that treating appendicitis with antibiotics alone appears feasible as an alter-



**Fig. 2.** The thickened appendix (straight arrow, A & B) and swollen mesoappendix (curved arrow, A, C & D) were presented during surgery. Pus squirted outside the incision of mesoappendix (right angle arrow, D). The cut mesoappendix seemed gangrenous with the naked eyes (arrowhead, E & F).

native to surgery. Of course, antibiotics played an important role in controlling the septic shock in this case; but we have reason to believe that appendectomy played a key and decisive role. Dr. Reginald Fitz, a Harvard pathologist, first described appendicitis as a surgical disease in 1886. [7]. So far surgery remains the golden standard for curing appendicitis. We suggest that the indication for a nonoperative approach of appendicitis should be strictly checked to avoid the risk of increased infection.

#### 4. Conclusion

Septic shock due to acute appendicitis is rarely encountered, and appendectomy in conjunction with antibiotics is an effective

therapy. To our knowledge, this is the first report on a case of acute appendicitis complicated by abscess formation within the mesoappendix, which is one of the causes that may lead to septic shock.

#### Declaration of Competing Interest

No conflict of interest exists

#### Funding

No.

**Ethical approval**

We have reported a single case, not a clinical study, with no requirement for ethical approval.

**Consent**

Written informed consent was obtained from the patient for publication of this case report and accompanying images. A copy of the written consent is available for review by the Editor-in-Chief of this journal on request.

**Author contribution**

Dr Yifan Man: Original draft.  
 Dr Shikuan Li: Performing the surgery. Review and editing.  
 Dr Zongping Yu: First assistant of the surgery.

**Registration of research studies**

Not applicable.

**Guarantor**

Dr Shikuan Li. Department of Emergency General Surgery, the Affiliated Hospital of Qingdao University, Qingdao, Shandong P.R. China.

**Provenance and peer review**

Not commissioned, externally peer-reviewed.

**References**

- [1] D.L.H. Baird, C. Simillis, C. Kontovounisios, S. Rasheed, P.P. Tekkis, Acute appendicitis, *BMJ* 357 (2017) j1703.
- [2] R.A. Agha, M.R. Borrelli, R. Farwana, K. Koshy, A. Fowler, D.P. Orgill, For the SCARE Group, The SCARE 2018 statement: updating consensus surgical Case REport (SCARE) guidelines, *Int. J. Surg.* 60 (2018) 132–136.
- [3] D.A. Leigh, K. Simmons, E. Norman, Bacterial flora of the appendix fossa in appendicitis and postoperative wound infection, *J. Clin. Pathol.* 7 (1974) 997–1000.
- [4] K. Kouzu, Y. Kajiwara, S. Aosasa, Y. Ishibashi, K. Yonemura, K. Okamoto, et al., Hepatic portal venous gas related to appendicitis, *J. Surg. Case Rep.* (2018), rjy333.
- [5] B. Chen, L. Xu, Acute appendicitis with septic shock as the first symptom: a case report, *J. Anest. Inten. Care. Med.* 10 (2020) 58–59.
- [6] A. Bhangu, K. Søreide, S. Di Saverio, J.H. Assarsson, F.T. Drake, Acute appendicitis: modern understanding of pathogenesis, diagnosis, and management, *Lancet* 386 (2015) 1278–1287.
- [7] D.H. Carmichael, Reginald Fitz and appendicitis, *South. Med. J.* 78 (1985) 725–730.

**Open Access**

This article is published Open Access at [sciencedirect.com](https://www.sciencedirect.com). It is distributed under the [IJSCR Supplemental terms and conditions](#), which permits unrestricted non commercial use, distribution, and reproduction in any medium, provided the original authors and source are credited.