

CASE REPORT

Open Access

Management of recurrent mechanical prosthetic tricuspid valve thrombosis in the perioperative period of noncardiac surgery: a case report

Amena Hussain* and Tudor Vagaonescu

Abstract

Introduction: Mechanical valves in the tricuspid position may be prone to thrombosis with even brief lapses in anticoagulation. The management of patients with a history of recurrent mechanical tricuspid valve thrombosis who require noncardiac surgery is complex.

Case presentation: A 43-year-old Pakistani woman with a mechanical tricuspid valve and a history of multiple episodes of mechanical valve thrombosis presented for noncardiac surgery. After her surgery she was found to have another episode of valve thrombosis and underwent a redo tricuspid valve replacement.

Conclusion: This case brings up the important dilemma that exists when patients with a mechanical tricuspid valve and a history of recurrent valve thrombosis require noncardiac surgery.

Introduction

Tricuspid valve (TV) replacement is not a common operation and low flows on the right side of the heart increase the risk of thrombosis. Thrombolytics have had good results and are the initial treatment for a thrombosed mechanical TV [1-3]. In patients who are in a recent postoperative state, however, thrombolytics are not an option.

Case presentation

A 43-year-old Pakistani woman presented for gynecologic surgery for an ovarian mass. Seventeen years prior, she had an emergency TV replacement with a St Jude bileaflet tilting disc prosthetic valve for bacterial endocarditis of her TV. The reasons for choosing a mechanical valve at that time are not known. Anticoagulation with warfarin without an antiplatelet agent was maintained and managed largely by our patient along with her primary care doctor. After her TV replacement she had three episodes of TV thrombosis, for which she received thrombolytics. Two of these episodes occurred during the discontinuation of warfarin and initiation of

heparin or low molecular weight heparin for pregnancy, necessitating the termination of her pregnancies. Her international normalized ratio on admission was at a therapeutic level of 2.5; heparin was initiated with a goal prothrombin time of 80 seconds and warfarin discontinued for the gynecologic surgery. A preoperative echocardiogram showed a mean gradient across the TV of 5 mmHg.

Our patient underwent an exploratory laparotomy, oophorectomy, removal of an ovarian mass and a cystotomy repair. The surgery was four hours long and she had 400 cm³ of blood loss. Heparin was off for a total of 13 hours. On postoperative day one, our patient complained that she could not hear the click of her mechanical valve. She was hemodynamically stable with a heart rate of 105 beats per minute. Doppler echocardiography showed a mean TV gradient of 18 mmHg (Figure 1). A transesophageal echo showed the St Jude valve to be stuck in the open position. This was confirmed by fluoroscopy (Figures 2 and 3).

Thrombolytics were not an option as she was in a recent postoperative state. She was maintained under close observation and serial echocardiograms showed that the gradients across her TV remained stable. Limited blood testing did not show any disorders in blood coagulation. Ten days after her initial surgery, when it was deemed

* Correspondence: amenahussain2@gmail.com

Department of Cardiovascular Diseases and Hypertension, Robert Wood Johnson University Hospital, 5th floor MEB, 1 RWJ Place New Brunswick, NJ 08901, USA

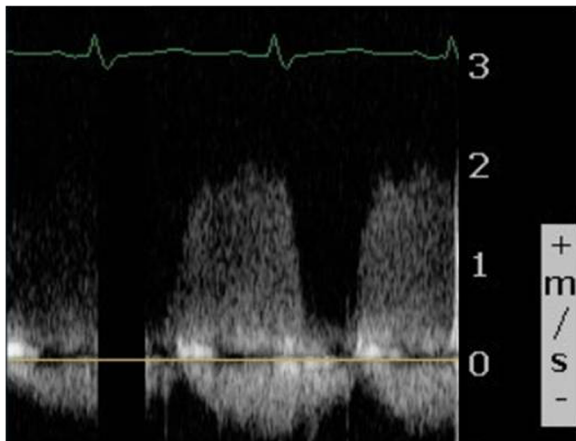


Figure 1 Continuous wave Doppler across the tricuspid valve showing increased inflow velocities.

safe to be placed on bypass, her St Jude TV was removed and a bioprosthetic valve was placed in the TV position. The explanted prosthesis showed fibrin and pannus that involved both discs (Figure 4). Our patient tolerated the procedure well and went home in stable condition.

Discussion

This case illustrates the dilemma associated with the need for noncardiac surgery in a patient who has had recurrent episodes of mechanical TV thrombosis.

TV replacement is not a common operation. Indications include severe primary tricuspid regurgitation with symptoms. The Society for Thoracic Surgeons national

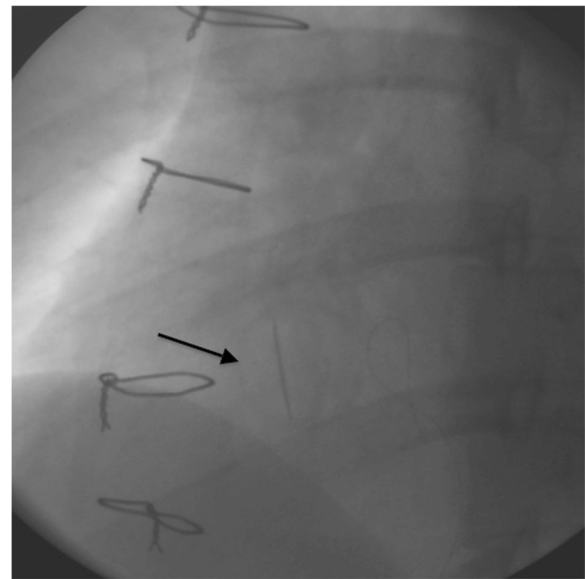


Figure 3 Fluoroscopy of the St Jude tilting disc tricuspid valve in different phases of the cardiac cycle showing the valve to be stuck in the partially open position (diastole).

database reveals that approximately 5,800 TV surgeries, both repair and replacements, were performed in North America as compared to approximately 211,000 mitral valve surgeries [4]. In most cases, TV repair with annuloplasty is considered the procedure of choice however this is not always possible due to severe disease. TV replacements are done at approximately one-eighth the frequency as repairs [5]. The low velocity of blood across the right-sided heart valve makes it more prone to thrombosis, with the risk being up to 20%, especially in the setting of poor anticoagulation [6,7]. The 20% incidence of valve thrombosis cited by Thorburn *et al.* in monoleaflet models (mainly Bjork-Shiley) corresponds to

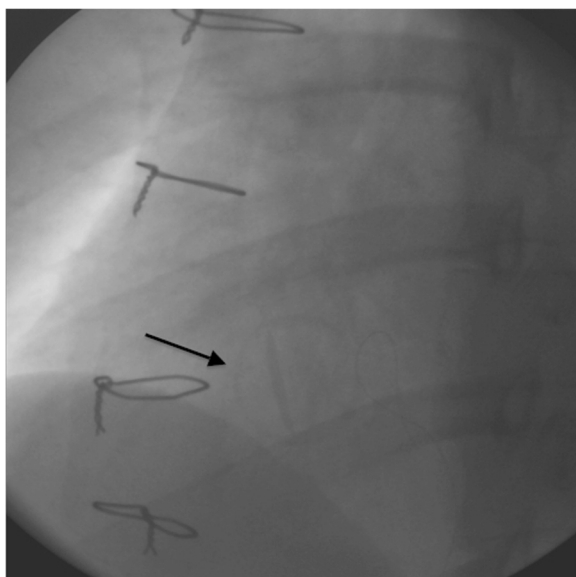


Figure 2 Fluoroscopy of the St Jude tilting disc tricuspid valve in different phases of the cardiac cycle, showing the valve to be stuck in the partially open position (systole).

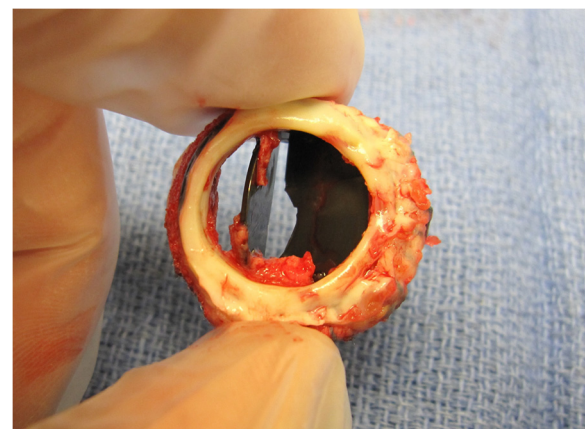


Figure 4 Explanted prosthesis showing fibrin and pannus involving both discs.

an incidence of 4% per patient-year. [7] This has improved with the use of bileaflet valves to an incidence approaching 1% [8,9]. Most studies do not show a clear superiority of bioprosthetic versus St Jude mechanical valves though experience is limited [10-12]. A large meta-analysis in 2007 concluded that there were no major differences with the insertion of a mechanical versus a biological TV [13]. Some studies do show superiority of the bioprosthetic valves and these authors conclude that it is their valve substitution of choice, though neither choice is clearly a gold standard [14,15].

Thrombolytics have had good results and are the initial treatment for a thrombosed mechanical TV [1-3]. In patients who are in a recent postoperative state, thrombolytics are not an option due to the high risk of bleeding. Our patient underwent TV replacement with a bioprosthetic valve after her noncardiac surgery when a thrombus was suspected. Cardiac surgery was cautiously delayed for a period during which she had close hemodynamic monitoring to reduce the risk of bleeding from her recent surgical site.

Conclusion

The management of patients with a history of recurrent mechanical TV thrombosis who require noncardiac surgery is complex. The elective replacement of a mechanical TV with a bioprosthetic valve before noncardiac surgery to lower the thrombotic risk would be considered too radical. Thrombolytics are the initial treatment for thrombosed mechanical valves but would be more dangerous in the postoperative state [1-3]. Reoperation of prosthetic valves has been shown to be low risk overall and new generations of bioprotheses have been shown to last longer [16]. The situation is unusual in that there are not many mechanical TVs placed, yet less so given the significant risk of thrombosis of the right-sided heart valve. Having to stop anticoagulation therapy in patients with mechanical valves for a period of time is common and pertinent to primary care physicians and surgeons, which makes education regarding valve choices and management of thrombotic complications important.

Consent

Written informed consent was obtained from the patient for publication of this case report and any accompanying images. A copy of the written consent is available for review by the Editor-in-Chief of this journal.

Competing interests

The authors declare that they have no competing interests.

Authors' contributions

AH wrote up the case report and discussion. TV revised the manuscript. Both authors were closely involved with the care of the patient and the acquisition of the images. Both authors read and approved the final manuscript.

Received: 1 July 2011 Accepted: 2 April 2012

Published: 12 June 2012

References

1. Alpert JS: **The thrombosed prosthetic valve: current recommendations based on evidence from the literature.** *J Am Coll Cardiol* 2003, **41**(4):659-660.
2. Hurrell DG, Schaff HV, Tajik A: **Thrombolytic therapy for obstruction of mechanical prosthetic valves.** *Mayo Clin Proc* 1996, **71**(6):605-613.
3. Caceres-Loriga FM, Santos-Gracia J, Perez-Lopez H: **Thrombotic obstruction of a mechanical prosthetic valve in tricuspid position: therapeutic considerations.** *Tex Heart Inst J* 2009, **36**(5):505.
4. Lee R, Li S, Rankin JS, O'Brien SM, Gammie JS, Peterson ED, McCarthy PM, Edwards FH, Society of Thoracic Surgeons Adult Cardiac Surgical Database: **Fifteen-year outcome trends for valve surgery in North America.** *Ann Thorac Surg* 2011, **91**(3):677-684.
5. Rogers JH, Bolling SF: **The tricuspid valve: current perspective and evolving management of tricuspid regurgitation.** *Circulation* 2009, **119**(20):2718-2725.
6. Lengyel M, Horstkotte D, Völler H, Mistiaen WP, Working Group Infection, Thrombosis, Embolism and Bleeding of the Society for Heart Valve Disease: **Recommendations for the management of prosthetic valve thrombosis.** *J Heart Valve Dis* 2005, **14**(5):567-575.
7. Thorburn CW, Morgan JJ, Shanahan MX, Chang VP: **Long-term results of tricuspid valve replacement and the problem of prosthetic valve thrombosis.** *Am J Cardiol* 1983, **51**(7):1128-1132.
8. Nakano K, Koyanagi H, Hashimoto A, Ohtsuka G, Nojiri C: **Tricuspid valve replacement with the bileaflet St. Jude Medical valve prosthesis.** *J Thorac Cardiovasc Surg* 1994, **108**(5):888-892.
9. Van Nooten GJ, Caes F, Taeymans Y, Van Belleghem Y, François K, De Bacquer D, Deuvaert FE, Wellens F, Primo G: **Tricuspid valve replacement: postoperative and long-term results.** *J Thorac Cardiovasc Surg* 1995, **110**(3):672-679.
10. Chang BC, Lim SH, Yi G, Hong YS, Lee S, Yoo KJ, Kang MS, Cho BK: **Long-term clinical results of tricuspid valve replacement.** *Ann Thorac Surg* 2006, **81**(4):1317-1324.
11. Ratnatunga CP, Edwards MB, Dore CJ, Taylor KM: **Tricuspid valve replacement: UK Heart Valve Registry mid-term results comparing mechanical and biological prostheses.** *Ann Thorac Surg* 1998, **66**(6):1940-1947.
12. Rizzoli G, Vendramin I, Nesseris G, Bottio T, Guglielmi C, Schiavon L: **Biological or mechanical prostheses in tricuspid position? A meta-analysis of intra-institutional results.** *Ann Thorac Surg* 2004, **77**(5):1607-1614.
13. Kunadian B, Vijayalakshmi K, Balasubramanian S, Dunning J: **Should the tricuspid valve be replaced with a mechanical or biological valve?** *Interact Cardiovasc Thorac Surg* 2007, **6**(4):551-557.
14. Kawano H, Oda T, Fukunaga S, Tayama E, Kawara T, Oryoji A, Aoyagi S: **Tricuspid valve replacement with the St. Jude Medical valve: 19 years of experience.** *Eur J Cardiothorac Surg* 2000, **18**(5):565-569.
15. Van Nooten GJ, Caes FL, François KJ, Taeymans Y, Primo G, Wellens F, Leclercq JL, Deuvaert FE: **The valve choice in tricuspid valve replacement: 25 years of experience.** *Eur J Cardiothorac Surg* 1995, **9**(8):441-447.
16. Beurtheret S, Gariboldi V, Feier H, Grisoli D, Riberi A, Mouly-Bandini A, Métras D, Kerbaul F, Collart F: **Short-term results of repeat valve replacement: a predictive factor analysis.** *J Heart Valve Dis* 2010, **19**(3):326-332.

doi:10.1186/1752-1947-6-150

Cite this article as: Hussain and Vagaonescu: Management of recurrent mechanical prosthetic tricuspid valve thrombosis in the perioperative period of noncardiac surgery: a case report. *Journal of Medical Case Reports* 2012 **6**:150.