

# Hypokalemic Paralysis Due to Primary Sjogren Syndrome

Anuj Sarma

Department of Anaesthesia and Critical Care, Down Town Hospital, Gauhati, Assam, India

## Abstract

Sjögren syndrome is an autoimmune disorder characterized by lymphocytic infiltration of exocrine gland. The most common symptom by virtue of its involvement includes dryness of eyes, mouth, and parotid gland enlargement. However, the disease may be associated with extraglandular manifestation affecting multiple organs. Such a presentation involves renal involvement with tubular dysfunction manifesting as severe hypokalemia.

**Keywords:** Distal renal tubular acidosis, hypokalemic paralysis, primary Sjögren syndrome

## INTRODUCTION

Hypokalemia defined as plasma potassium level  $<3.5$  mmol/L is one of the most common electrolyte disturbances encountered in clinical practice. Mild hypokalemia (plasma potassium 3.0–3.5 mmol/L) is usually asymptomatic; however, severe hypokalemia (plasma potassium  $<2.5$  mmol/L) can be associated with acute flaccid paralysis of limbs along with involvement of respiratory or cardiac system. Among the many causes of hypokalemia, distal renal tubular acidosis (RTA) due to Sjögren syndrome is an important entity. The following case report illustrates this scenario.

## CASE REPORT

Fifty two year old female presented with weakness of both upper and lower limbs of 1-day duration. Weakness was gradual in onset but slowly progressed over time resulting in difficulty in getting up from bed. The patient did not have any history of fever, trauma, chronic diarrhea, increase urine output, palpitations, tremors, excessive sweating, and chronic drug use. There is also no history of double vision, dropping of eyelid, difficulty in speech or swallowing or regurgitation, sensory complaints, bowel and bladder involvement, muscle cramps, joint pain, or diurnal variation of weakness. However, she did give a history of similar episodes of weakness of lower limbs 3 months back where she was treated in a local hospital with complete recovery, the details of which were not available. There is also no history of diabetes,

hypertension, cardiac, neurological or renal disease, and no family history of weakness

- On examination, Patient was conscious; pulse-84/mim/Regular, B.P-120/80mmhg, Respiratory Rate 16/minute., Eye-dryness of both eyes present. Neurological examination: hypotonia in all four limbs. Power in both upper and lower limb being (2/5). Deep tendon reflex in both limbs had diminished. Plantar bilaterally flexor. Cranial nerve function was normal.
- However within 2 hrs of her admission in the hospital, she had shallow breathing, tachypnea, respiratory fatigue and was electively intubated and connected to mechanical ventilator
- Blood investigation revealed. TLC - 8400cells(Polymorphocyte - 84%, Lymphocytes - 12%, Monocytes - 2%, Eosinophils- 1%). Hemoglobin - 12.9%, Erythrocyte Sedimentation rate (ESR) - 10 mmHg, serum creatinine - 1.01, RBS Hb - 12.9% , ESR - 10mmhg, and thyroid-stimulating hormone - 0.788 mIU. Serum glutamic-oxaloacetic transaminase - 40, serum glutamic pyruvic transaminase - 30, gamma-glutamyl transpeptidase - 18, ALP - 184, PT - 11 s, INR - 0.92,  $\text{Na}^+$  - 145.3 mmol/L,  $\text{K}^+$  - 1.44 mmol/L,  $\text{Cl}^-$  - 115 mmol/dl,  $\text{HCO}_3^-$  - 19.2 mmol/L, ABG-pH - 7.121,  $\text{PCO}_2$  - 30 mmHg,  $\text{PO}_2$  - 120 mmHg,

**Address for correspondence:** Dr. Anuj Sarma,  
Zoo Narengi Road, Chinakipath, Guwahati, Assam, India.  
E-mail: anujarma26@gmail.com

### Access this article online

#### Quick Response Code:



**Website:**  
www.ijem.in

**DOI:**  
10.4103/ijem.IJEM\_666\_17

This is an open access journal, and articles are distributed under the terms of the Creative Commons Attribution-NonCommercial-ShareAlike 4.0 License, which allows others to remix, tweak, and build upon the work non-commercially, as long as appropriate credit is given and the new creations are licensed under the identical terms.

**For reprints contact:** reprints@medknow.com

**How to cite this article:** Sarma A. Hypokalemic paralysis due to primary Sjogren syndrome. Indian J Endocr Metab 2018;22:287-9.

$\text{HCO}_3^-$  – 19.2 mmol/L. Calculated anion Gap is 10.2. HIV–negative, HBsAg–negative, IgM anti-HCV–negative, and venereal disease research laboratory – negative. Urine R/E–reaction–alkaline (pH - 8.0), protein, sugar, blood–nil, ultrasonography (W/A) – normal, computed tomography brain – normal

- Anion gap represents the unmeasured anions in the body, such as albumin, phosphate, and organic anions. It is calculated as  $\text{serum Na}^+ - (\text{serum Cl}^- + \text{serum HCO}_3^-)$  with all parameters being in mEq/L. Its normal value is between 10 and 12 mEq/L
- Thus, in this case, we had normal anion gap (hyperchloremic) metabolic acidosis with adequate respiratory compensation with severe hypokalemia. Normal anion gap metabolic acidosis is found in (1) gastrointestinal loss of bicarbonate (2) RTA (3) drug-induced causes. The patient neither had a history of vomiting/diarrhea nor any history of drug abuse. Hence, the urinary pH, osmolality, urinary Na, urinary K, and urinary chloride were sent and reports came as urine pH – 8.0, urine osmolality – 339.7 mosm/kg, urinary  $\text{Na}^+$  – 146.0 mmol/L, urinary  $\text{K}^+$  – 7.4 mmol/L, and urine chloride – 63 mg/dl. Urinary anion gap calculated is positive. Hence, this case was of high-(positive) urinary anion gap with urine pH of 8.0 with normal serum anion gap and by looking at the chart given below this proves to be case of distal RTA Type 1.

Causes of distal RTA include (1) familial (2) idiopathic (3) sarcoidosis (4) hyperparathyroidism, and (5) Vitamin D overdose 6 autoimmune conditions (systemic lupus erythematosus [SLE], autoimmune hepatitis, and Sjögren's syndrome).

- The patient was treated with intravenous potassium supplementation, protective low-tidal volume ventilation and slowly potassium levels got corrected and in the next 24 h; the patient was successfully weaned from ventilator and extubated. Further investigation revealed serum ACE – 26.00 U/L, serum PTH – 21.10 pg/ml, plasma ACTH – 36.50 pg/ml renin – 3.93  $\mu\text{IU/ml}$ . ANA – 1.6 IU/ml dsDNA – 2.6 IU/ml, Anti-ccp – <0.50 U/ml. serum SS-A/Ro – 86.43U, serum SS-B/La – 53.67U, and rheumatoid factor – 21.14 IU/ml
- From the investigations done, the positive finding was the high-positive level of serum SS-A/Ro – 86.43U, serum SS-B/La – 53.67U – the marker of Sjögren syndrome. Further, the evaluation was done by ophthalmology department when Schirmer's test showed severe dryness of both eyes (<5 mm) along with dryness of mouth. Lip biopsy showed chronic lymphocytic sialadenitis. With this, the patient is diagnosed to be a case of hypokalemic paralysis due to distal RTA caused by primary Sjögren syndrome.

## DISCUSSION

The patient presented with weakness of all four limbs without fever, sensory, bladder and bowel involvement.<sup>[1]</sup> The differentials that were considered included (1) periodic

paralysis (2) neuromuscular disorders–myasthenia gravis, Lambert–Eaton syndrome (3) Myelopathy–compressive myelopathy, transverse myelitis (4) miscellaneous causes such as porphyria, HIV, vasculitic neuropathy, drugs/toxin–alcohol, and heavy metals such as arsenic and thallium. Neuromuscular disorders such as myasthenia gravis presents with easy fatigability, extraocular muscle involvement, and variable weakness of voluntary muscle which is absent in this patient. Myelopathy ruled out as the patient did not sensory, bladder, and bowel involvement along with absent spasticity, extensor plantar response. Likewise miscellaneous causes were ruled through history, blood investigation.

Periodic paralysis are a group of disorders characterized by episodes of flaccid paralysis occurring at irregular interval with complete recovery in between attack. Most of the cases are as follows: (1) hereditary with autosomal dominance inheritance, (2) associated with alteration of sodium and potassium levels, (3) the various forms being hypokalemic, hyperkalemic, thyrotoxic, and paramyotonia congenital and (4) symptoms are most evident during childhood and adolescence and are triggered by large carbohydrate meal, vigorous exercise, and viral illness.

The patient in our case had severe hypokalemia with acute flaccid paralysis of all four limbs along with respiratory muscle. However, the age of onset being above 50 years, the likelihood of being an inherited condition becomes a remote possibility. Evaluation and careful investigation of hypokalemia brought to light condition of metabolic acidosis with normal anion gap with urine pH of >5 and positive urinary anion gap which in turn revealed distal RTA Type 1. When the causes of distal RTA were investigated, high-positive Sjögren antibodies were found. Further, examination of eyes, mouth revealed severe dryness with positive Schirmer's test, and lip biopsy showed chronic lymphocytic sialadenitis.<sup>[2]</sup> All this finding confirms the diagnosis of Sjögren syndrome according to the American European Consensus Group Criteria of Sjögren Syndrome (2002) given below.

1. Ocular symptoms (at least one)
  - Dry eyes >3 months?
  - Foreign body sensation in the eyes?
  - Use of artificial tears >>3 per day?
2. Oral symptoms (at least one)
  - Dry mouth >3 months?
  - Recurrent or persistently swollen salivary glands?
  - Need liquids to swallow dry foods?
3. Ocular signs (at least one)
  - Schirmer's test, (without anesthesia)  $\leq 5$  mm/5 min
  - Positive vital dye staining (van Bijsterveld  $\geq 4$ )
4. Histopathology lip biopsy showing focal lymphocytic sialoadenitis (focus score  $\geq 1/4$  mm<sup>2</sup>)<sup>[2]</sup>
5. Oral signs (at least one)
  - Unstimulated whole salivary flow ( $\leq 1.5$  mL in 15 min)
  - Abnormal parotid sialography<sup>[3]</sup>
  - Abnormal salivary scintigraphy<sup>[4]</sup>

6. Autoantibodies (at least one)
- Anti-SSA (Ro) or Anti-SSB (La).

For a primary Sjögren's diagnosis:

- Any four of the six criteria must include either item IV (histopathology) or VI (autoantibodies)
- Any three of the four objective criteria (III, IV, V, and VI).

For a secondary Sjögren's diagnosis:

- In patients with another well-defined major connective tissue disease, the presence of one symptom (I or II) plus two of the three objective criteria (III, IV, and V) is indicative of secondary SS.

Exclusion criteria:

- Past head and neck radiation treatment
- Hepatitis C infection
- Acquired immunodeficiency syndrome
- Preexisting lymphoma
- Sarcoidosis
- Graft versus host disease
- Current use of anticholinergic drugs<sup>[3]</sup>

Sjögren syndrome is chronic systemic autoimmune disorder characterized by lymphocytic infiltration of exocrine glands. The disease can present as alone (primary Sjögren syndrome) or associated with other autoimmune conditions such as SLE, rheumatoid arthritis, and scleroderma (secondary Sjögren syndrome). The prevalence of primary Sjögren's syndrome is ~0.5%–1% and middle-aged women (female-to-male ratio is 9:1) are primarily affected.<sup>[4]</sup> Most patients presents with sicca symptoms such as xerophthalmia (dry eyes), xerostomia (dry mouth), and parotid gland enlargement. In addition, various extraglandular features may develop. This includes arthralgia, arthritis, vasculitis, lymphoma, renal involvement, and Raynauds phenomenon.<sup>[5]</sup> Renal involvement includes proximal and

distal tubular acidosis, tubular proteinuria, and nephrogenic diabetes insipidus.<sup>[6]</sup> The mechanism of hypokalemia in Sjögren syndrome is because of distal RTA brought about by chronic interstitial nephritis which in turn leads to decrease tubular sodium delivery, defective H-KATPase, secondary hyperaldosteronism, and bicarbonaturia [Figure 1].

## CONCLUSION

When a patient presents with hypokalemic paralysis, the notion of labeling it to be a case of periodic paralysis may not always be a wise decision if other conditions are not ruled out. For this, a good history, clinical examination, thorough knowledge of arterial blood gas, and urine analysis are very important so that conditions such as Sjögren syndrome are not overlooked or missed.

## Declaration of patient consent

The author certify that they have obtained all appropriate patient consent forms and patient and family members has agreed to publish the clinical information in the journal. The patient understand that their names and initials will not be published and due efforts are taken to conceal their identity, but anonymity cannot be guaranteed.

## Acknowledgement

I want to thank almighty God, my wife Dr. Gargee Borthakur, my daughter Tapashya, my parents Hari Prasad Sarma and Bharati Sarma, my parents in law Sushil Borthakur and Gayatree Borthakur, and the legend Dr. Michael de Bakey whose blessings, inspiration gave me strengths to write this case report.

## Financial support and sponsorship

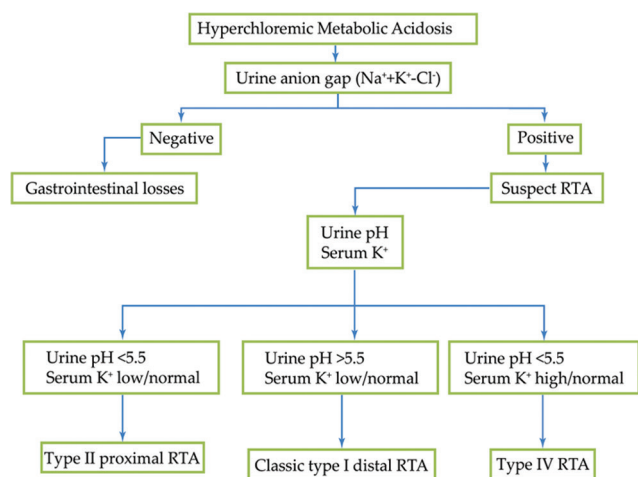
Nil.

## Conflicts of interest

There are no conflicts of interest.

## REFERENCES

- Venance SL, Cannon SC, Fialho D, Fontaine B, Hanna MG, Ptacek LJ, *et al*. The primary periodic paralyses: Diagnosis, pathogenesis and treatment. *Brain* 2006;129:8-17.
- Vitali C, Bombardieri S, Jonsson R, Moutsopoulos HM, Alexander EL, Carsons SE, *et al*. Classification criteria for Sjögren's syndrome: A revised version of the European criteria proposed by the American-European consensus group. *Ann Rheum Dis* 2002;61:554-8.
- Rischmueller M, Tieu J, Lester S. Primary Sjögren's syndrome. *Best Pract Res Clin Rheumatol* 2016;30:189-220.
- Fox RI. Sjögren's syndrome. *Lancet* 2005;366:321-31.
- Bossini N, Savoldi S, Franceschini F, Mombelloni S, Baronio M, Cavazzana I, *et al*. Clinical and morphological features of kidney involvement in primary sjögren's syndrome. *Nephrol Dial Transplant* 2001;16:2328-36.
- Maripuri S, Grande JP, Osborn TG, Fervenza FC, Matteson EL, Donadio JV, *et al*. Renal involvement in primary Sjögren's syndrome: A clinicopathologic study. *Clin J Am Soc Nephrol* 2009;4:1423-31.



**Figure 1:** Approach to the patient with normal anion gap metabolic acidosis