

REVIEW

Surgical anatomy of the vaginal vault

**Bernard T. Haylen MB, BS, MD, FRANZCOG, FRCOG, CU¹ |
Dzung Vu MB, BS, MD, FRANCO (Hon)²**

¹Department of Gynaecology, University of New South Wales, Sydney, New South Wales, Australia

²Department of Anatomy, University of Notre Dame, Sydney, New South Wales, Australia

Correspondence

Bernard T. Haylen, MB, BS, MD, FRANZCOG, FRCOG, CU, Suite 904, St Vincent's Clinic, 438 Victoria Street, Darlinghurst, NSW 2010, Australia.
Email: bernard@haylen.co

Abstract

Aim: Vaginal vault (VV) surgery should be a key part of surgery for a majority of pelvic organ prolapse (POP). The surgical anatomy of the VV, the upper most part of the vagina, has not been recently subject to a dedicated examination and description.

Methods: Cadaver studies were performed in (i) 10 unembalmed cadaveric pelvis (observation); (ii) 2 unembalmed cadaveric pelvis (dissection); (iii) 5 formalinized hemipelvis (dissection). The structural outline and ligamentous supports of the VV were determined. Further confirmation of observations in post-hysterectomy patients were from a separate study on 300 consecutive POP repairs, 46% of whom had undergone prior hysterectomy.

Results: The VV is equivalent to the Level I section of the vagina, measured posteriorly from the top of the posterior vaginal wall (apex or highest part of the vagina) to 2.5 cm below this point. It comprises the anterior fornix (through which cervix protrudes or is removed at hysterectomy), posterior fornix and two lateral fornices. Before hysterectomy, the posterior aspects of the cervix and upper vagina are supported by the uterosacral (USL) and cardinal ligaments (CL), the distal segments of which fuse together to form a cardinal-uterosacral ligament complex (cardinal utero-sacral complex), around 2–3 cm long. Post-hysterectomy, there is some residual USL support to the anterior fornix but the posterior fornix has no ligamentous support and is thus more vulnerable to prolapse.

Conclusion: Effective management of VV prolapse will need to be part of most POP repairs. Enhanced understanding of the surgical anatomy of the vaginal vault allows more effective planning of those POP surgeries.

KEYWORDS

cysto-enterocele, Level I Vagina, pelvic organ prolapse, recto-enterocele, surgical anatomy, vaginal vault

1 | INTRODUCTION

Vaginal vault (VV) surgery is a key part of surgery for a majority of pelvic organ prolapse (POP). The surgical anatomy of the VV, the upper most part of the vagina, has not been recently subject to a dedicated examination and description. This may be partly due to the VV being the furthest area to reach on a digital vaginal or speculum examination. It is sometimes difficult to assess even under examination under anesthetic, when traction using a forceps may be required.

The VV support can be compromised by parturition, hysterectomy and some heavier lifting activities over time. Genetic and demographic factors may play a role. Loss of VV support results in POP. Around 45% of a cystocele¹ is due to VV prolapse; around 55% of rectoceles² can be due to VV prolapse.

Our aim was to review current literature, then elucidate and expand current knowledge of the anatomy of the VV by cadaver studies with emphasis on clarification of some points clinically, particularly in posthysterectomy patients.²

2 | MATERIALS AND METHODS

There were three aspects to our studies of the VV and associated support ligaments, the uterosacral (USL) and cardinal ligaments (CL): (i) Observations were made on 10 unembalmed cadaveric pelves when they were dissected for the purpose of teaching gynecology trainees; (ii) Dissection was carried out on 2 unembalmed cadaveric pelves; (iii) Dissection was also carried out on 5 formalinized hemipelves. All the cadavers were bequeathed for scientific and teaching purposes. Only one pelvis was known to be nulliparous from the donor's medical records; the remaining pelves did not have parity recorded on files, but had parous cervical appearance. None of the dissected cadavers had evidence of hysterectomy or previous pelvic surgery. Further confirmation of observations in posthysterectomy patients were from a separate study on 300 consecutive prolapse repairs,² 46% of whom had undergone prior hysterectomy.

2.1 | A: Dissection of the unembalmed pelves

Fresh frozen cadavers were cut above the iliac crest and the gastrointestinal tube excised just proximal to the rectosigmoid junction to facilitate the study of relations of the VV, USL, and CL. Anterior traction was applied to the uterine fundus to accentuate the sacro-uterine folds (also known as

rectouterine folds), and the peritoneum was incised along the crest of the peritoneal folds. Peritoneum was carefully dissected off the underlying structures, on both the anterior and posterior surfaces of the fold, from the incision caudally down to the pelvic floor. Care was taken to preserve all the connective tissue and neurovascular structures lying deep to the peritoneum. The peritoneum was peeled off caudally to the pelvic floor, and laterally to expose the entire lateral pelvic wall from the sacrum to the pubic symphysis. Fat was carefully removed to expose the connective tissue and neurovascular structures. The entire USL was identified; its appearance, attachments and relations with surrounding structures were noted.

2.2 | B: Dissection of the embalmed hemipelves

The embalmed pelves were sectioned at the median plane. Dissection began from the median plane and the peritoneum was carefully detached to expose the underlying structures from the midline to the lateral pelvic wall, leaving intact the underlying connective tissue and neurovascular structures. The appearance of the USL, its attachments and the relations of the ligament with surrounding structures were noted. Measurements were taken with a flexible ruler and readings were recorded to the nearest 0.1 cm.

3 | RESULTS AND ANALYSIS

The approach taken in this paper has been to interweave the results and analysis. This has been initiated by the cadaveric studies and enhanced by other clinical studies.²

3.1 | A: Longitudinal/oblique

The VV is equivalent to the Level I section of the vagina (Figure 1) measured posteriorly from the top of the posterior vaginal wall (apex or highest part of the vagina) to 2.5 cm below this point.^{3,4} The average non-parous length of uterine cervix (if present) is also 2.5 cm.⁵ The superior oblique view in Figure 1A shows the uterine cervix entering the vagina through the anterior fornix, anterior to and below the vaginal apex. Before hysterectomy, the anterior fornix is generally lower and shorter than the posterior fornix.

Mean total vaginal length³ (apex to hymen in posterior measurement) in a series of 300 women undergoing posterior repair was 7.49 cm² with the VV thus 33% of this length; mean total posterior vaginal length³ (apex to anterior perineum in posterior measurement) was 9.25 cm with the VV representing 27% of this length.

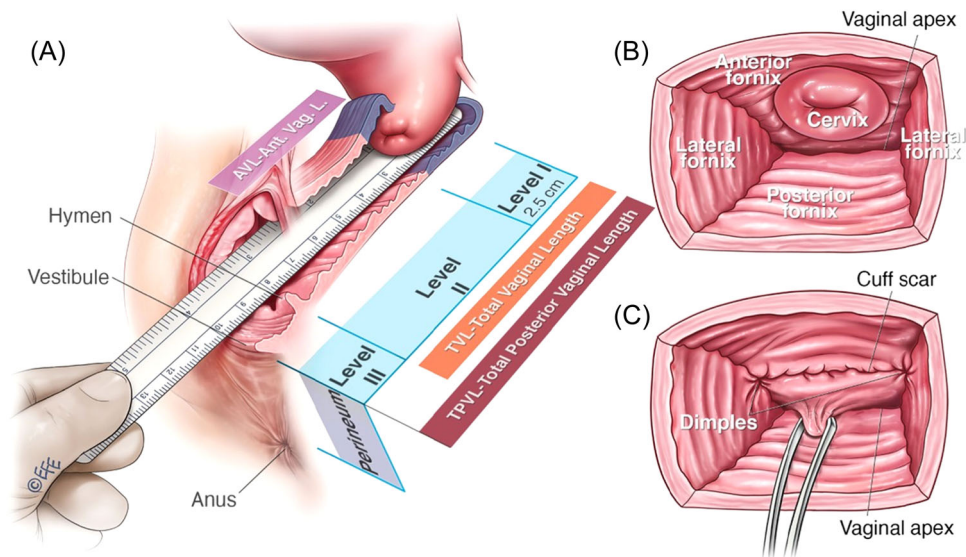


FIGURE 1 (A) Vaginal vault is the Level I section of the vagina (apex to 2.5 cm below this in posterior measurement)^{3,4}; (B) axial view of VV before hysterectomy; (C) axial view of VV posthysterectomy. VV, vaginal vault

3.2 | B: Axial views

Figure 1B shows the pre hysterectomy VV, with four fornices: (i) anterior fornix, through which the cervix protrudes; (ii) posterior fornix, behind the cervix, leading up to the vaginal apex; (iii, iv) two lateral fornices, to the side of the cervix. The name “vault” is appropriate as it has an “arched” appearance with divisions akin to the vault of a classical building.

Figure 1C shows the posthysterectomy VV: (i) anterior fornix with the cuff scar generally visible as a horizontal line, at the lateral ends of which are small depressions (“dimples”) in the vaginal wall (caused by tension of the intermediate segment of the USL); (ii) posterior fornix (iii, iv); two lateral fornices. The cuff scar line is anterior to the vaginal apex. A traction forcep has been placed around 1 cm below the cuff scar line, around the area of the vaginal apex, in preparation for the assessment of VV prolapse.

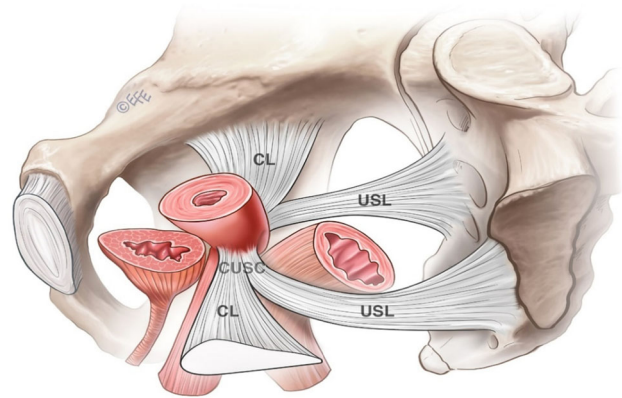


FIGURE 2 (A) (above—diagrammatic) (B) (below—cadaver): Cardinal ligament (CL) and Uterosacral (USL) have their distal segments fuse together to create a Cardinal utero-sacral complex (CUSC). From the cervix VV, the CL and passes postero-laterally whilst the USL passes supero-posteriorly. CL, cardinal ligaments; VV, vaginal vault

4 | VV SUPPORTS—PREHYSTERECTOMY

Before hysterectomy, the posterior aspects of the cervix and upper vagina are supported by the USL⁶ and CLs,⁷ the distal segments of which fuse together to create a cardinal-uterosacral ligament complex (cardinal utero-sacral complex [CUSC]), around 2–3 cm long (Figure 2A,B). That ligament complex represents the first pedicle of a vaginal hysterectomy (Figure 3), which is generally surgically reattached to the cuff scar (most commonly its lateral aspects) to provide support.⁴

The USL and CL are the only direct ligamentous supports for the VV. The round ligament, as a relatively weak support to the uterus anterior to the CL and USL, can provide an indirect VV support. It can be subjected to shortening (by concertina effect) as in a ventrosuspension,⁸ generally to antevert a retroverted uterus, connected to the VV. Figure 4 demonstrates the 3 ligaments in the one axial cadaveric section (from the Visible Human Project series).

The relatively unattached intermediate section of the USL is around 5 cm long, wide, thick, well-defined when placed under tension, more than 2 cm from the ureter and suitable for surgical use⁶ (Figure 2B).

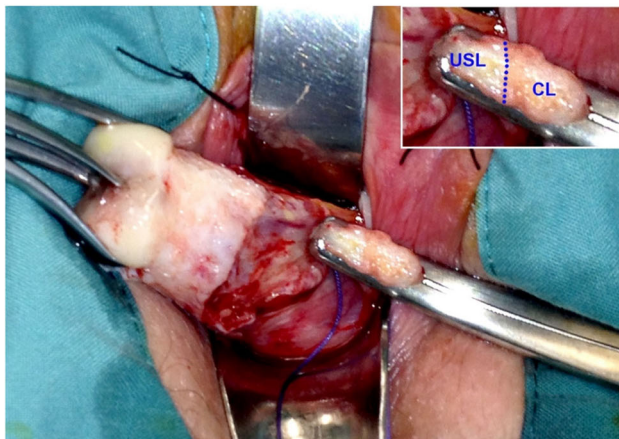
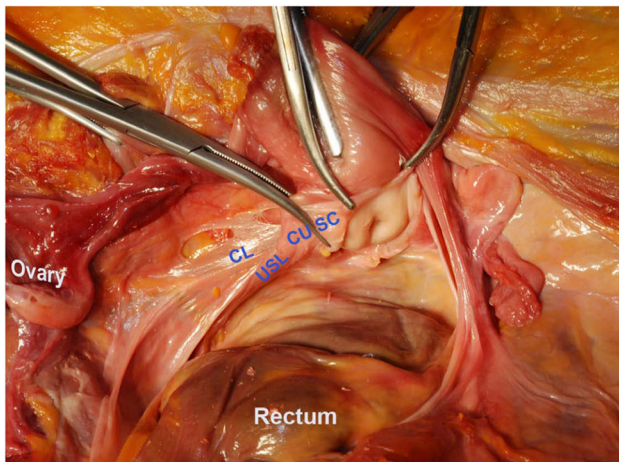


FIGURE 3 The distal segments of the USL and CL are fused. They are cut with the first pedicle of a vaginal hysterectomy, with CL more laterally placed. CL, cardinal ligaments; USL, uterosacral

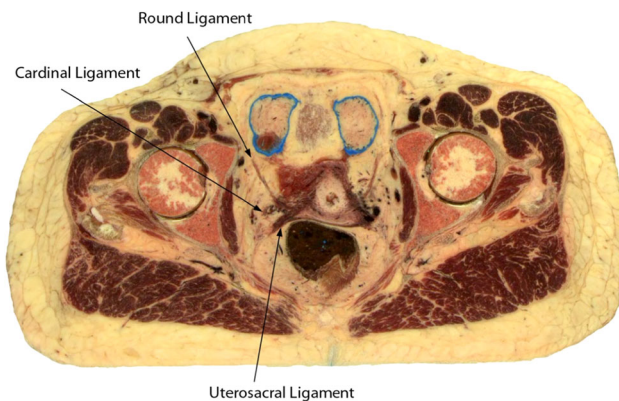


FIGURE 4 USL, CL and round ligaments displayed in the one axial cadaveric cut. (Visible Human Project, National Library of Medicine, NLM, USA—with permission). CL, cardinal ligaments; USL, uterosacral

The proximal section of the USL is around 5–6 cm long. It has a diffuse sacral attachment extending (i) vertically from the sacrococcygeal joint to S3 (with the sacro-uterine fold of peritoneum extending to S2 or sometimes S1) and

(ii) transversely from the pelvic sacral foramina medially to 5 cm lateral to the sacro-iliac joint where it is attached to fascia overlying piriformis and levator.

Early symptoms of VV prolapse include a low (period-like) backache centering around S3 that increases with standing and activities.³ This is most likely due to tension on a weakened USL. Late symptoms include sensations of heaviness, dragging, a bulge. Later symptoms include those of voiding and/or defecatory difficulty.³

5 | VV SUPPORTS— POSTHYSTERECTOMY

Residual USL (its intermediate segment⁶), above the cuff scar, is available for subsequent surgical use^{9–12} and accounts for the “dimples” at the end of the cuff scar. These surgeries might be done just above the cuff scar line⁹ (Figure 5) or in higher and more lateral areas of the USL intermediate segment.^{10–12} The more laterally placed cardinal ligament is not available for any further surgical use⁷ posthysterectomy and the round ligament is not relevant.

Posthysterectomy, there are no ligamentous supports for the VV posterior to the cuff scar, i.e. there are no ligamentous supports to the posterior fornix and vaginal apex, making them susceptible to post-hysterectomy VV prolapse. Surgical attachment of the USL/CL remnants in the first pedicle of a vaginal hysterectomy into the cuff scar⁴ gives support to the anterior fornix though not the posterior fornix. It might slightly anteriorize the vagina, which might also contribute to posterior fornix/apical prolapse.

6 | POSTERIOR VV PROLAPSE

The posterior fornix incorporating the vaginal apex is the most common site for VV prolapse, for the reasons mentioned above. The degree of posterior VV prolapse can be measured by the posterior vaginal vault descent (PVVD)^{2,3} or Point C in POP-Q.^{3,13} Figure 6A,B show the measurement of the PVVD.

In a series of 300 consecutive posterior repairs, the Level 1 defect is by far the greatest (mean PVVD^{2,3}—6.0 cm; mean Point C^{3,13}—minus 9.1 cm). This compares with 2.9 cm for the Level III defect (Perineal GAP—PG^{2,3}) and 1.0 cm (Point Ap^{3,13})—1.3 cm (mid-vaginal laxity-MVL^{2,3}). All of these measurements are obtained intraoperatively. A PVVD of 5 cm or more has been recommended as a cut-off for indicating the need for VV surgical support.² In a vaginal approach to POP surgery, this is commonly occurs using a sacrospinous colpopexy.¹⁴

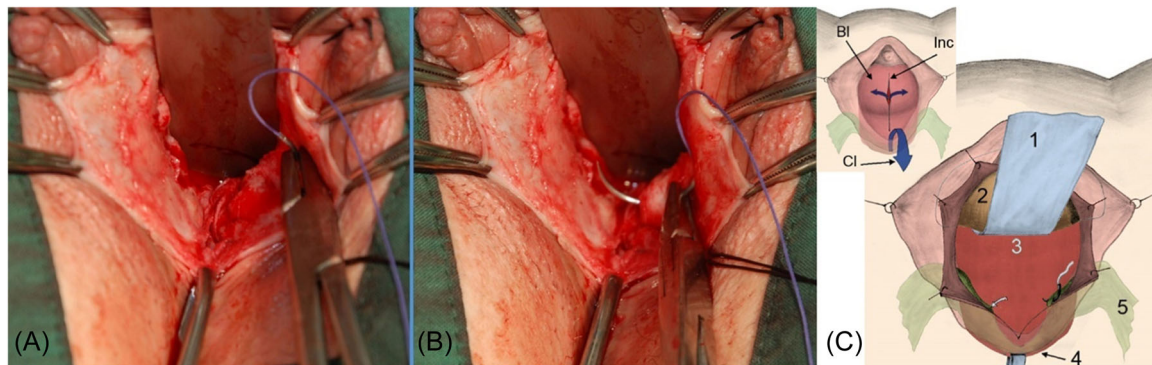


FIGURE 5 (A–C): (Short version). The intermediate section of the USL becomes visible, at the lower end of an anterior repair,⁷ just above the cuff scar line (A) when it is put under tension (B). Sutures can be used (C) to plicate the USL (Green—5): (Longer version) (A) A midline anterior vaginal wall incision with bladder mobilization and retraction. No USL is apparent as a wide shallow horizontal needle pass occurs through the dorsolateral aspect of the exposed vaginal vault superior to the cuff. (B) The intermediate section of the USL is readily seen when placed under tension. (C) Small inset shows the midline anterior vaginal wall incision (Inc) over the bladder (Bl) with the clamp (Cl) positioned to invert the vaginal vault to the vaginal introitus. The main part of (C) is a diagrammatic representation of (B) showing, 1, right-angled retractor; 2, retracted bladder; 3, retrovesical space; 4, inverted vaginal vault; and 5, USL placed under tension at the beginning of plication. CL, cardinal ligaments; USL, uterosacral

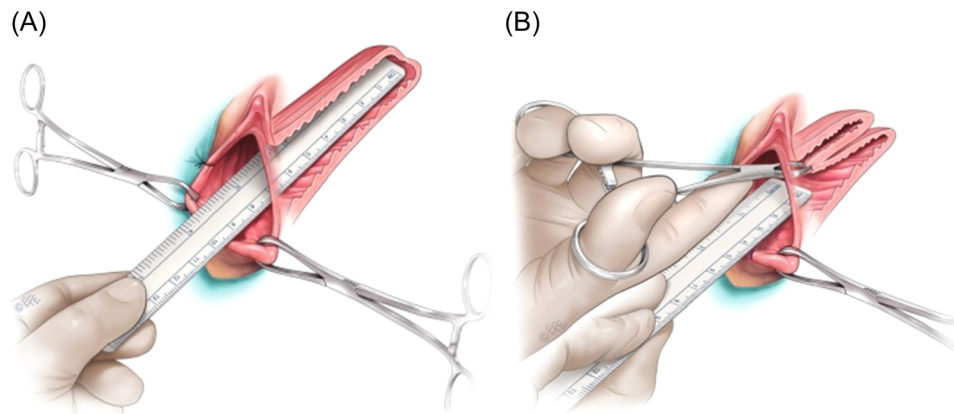


FIGURE 6 (A, left): Total posterior vaginal length (TPVL). (B, right): Distance from vaginal vault (on traction) to anterior perineum. Posterior vaginal vault descent (PVVD) is the subtraction of the latter measurement from the TPVL

7 | VV AND ASSOCIATED VAGINAL PROLAPSE

It was noted in the introduction, that VV prolapse can be a large component of other forms of vaginal prolapse. Figure 7B shows a recto-enterocele with components of rectocele and VV descent. The cuff scar is seen towards the top of the rectocele. Figure 6C shows that by pushing the forceps back, the rectocele component of the combined prolapse disappears, meaning that the majority of the POP is VV descent (Figure 8).

Similarly with a cystocele, particularly a larger one, it is more likely to be a combination cysto-enterocele. Again, the most comprehensive surgical approach vaginally is to correct the anterior, posterior and VV compartments, subject to a sufficient degree of PVVD.^{2,3}

8 | CONCLUSIONS

The VV is equivalent to the Level I section of the vagina, measured posteriorly from the top of the posterior vaginal wall (apex or highest part of the vagina) to 2.5 cm below this point.^{3,4} It comprises the anterior

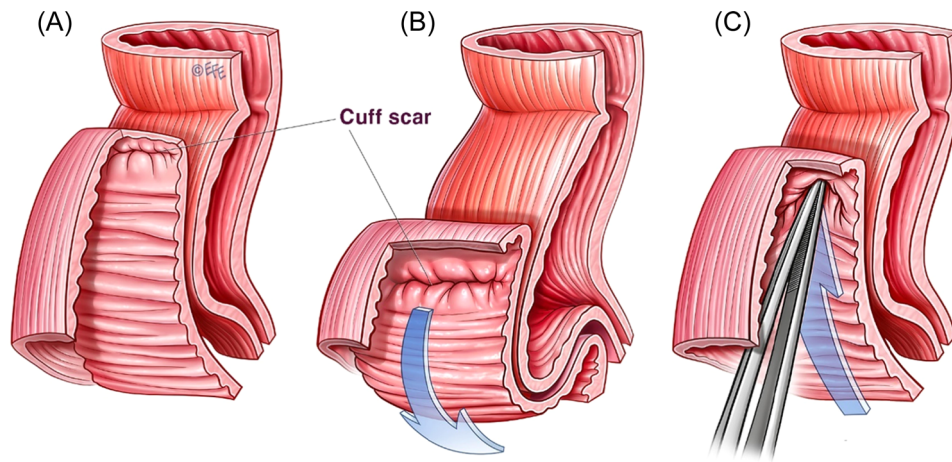
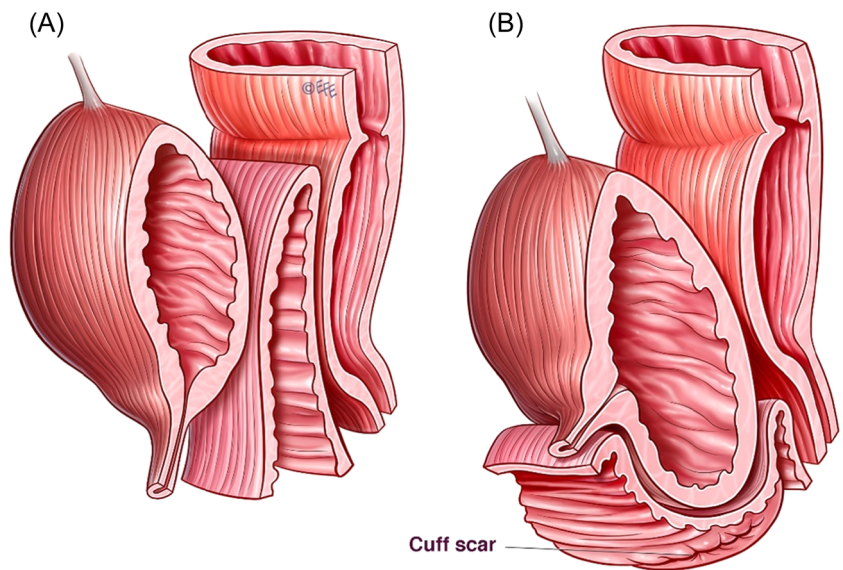


FIGURE 7 (A) Anterior-oblique view of posthysterectomy posterior vagina (anterior to the rectum) with cuff scar (marked) anterior to apex. (B) Apparent “rectocele” though with cuff scar at top of “bulge”, this makes it a recto-enterocele. (C) By pushing back postero-superiorly with forceps, the combined prolapse (vault and posterior) disappears, replicating a VV repair. Thus, the majority of the posterior prolapse is VV descent. VV, vaginal vault

FIGURE 8 (A) Anterior-oblique view of posthysterectomy: bladder, vagina, rectum; (B) Large cysto-enterocele—bladder behind anterior vaginal wall (marked) and cuff scar (marked). The cysto-enterocele with components of cystocele and VV descent. The cuff scar is seen towards the bottom of the cystocele. VV, vaginal vault



fornix (through which cervix protrudes or is removed at hysterectomy), posterior fornix and two lateral fornices. Before hysterectomy, the posterior aspects of the cervix and upper vagina are supported by the USL⁶ and CL,⁷ the distal segments of which fuse to create a cardinal-uterosacral ligament complex (CUSC), around 2–3 cm long. Posthysterectomy, there is some residual USL support to the anterior fornix though none to the posterior fornix, making that area more vulnerable to prolapse.

It is hoped that this review with further cadaver studies has allowed an updated, logical, sequential and greatly enhanced understanding of the surgical anatomy

of the VV. It is clear that VV defects, from whatever causative factors, genetic, obstetric, demographic or surgical (partial loss of ligamentous supports) are core to POP, particularly in the posthysterectomy circumstance. Before hysterectomy, the additional effect of a retroverted uterus causing a majority of uterine prolapse has been twice emphasized.^{15,16}

Effective management of VV prolapse will need to be part of most POP repairs.^{2,4} VV stabilization in combination with other vaginal repairs should result in the relief of key prolapse symptoms such as a bulge, dragging and low backache as well as significantly improved voiding and defecatory function.

ACKNOWLEDGMENTS

Open access publishing facilitated by University of New South Wales, as part of the Wiley-University of New South Wales agreement via the Council of Australian University Librarians.

CONFLICTS OF INTEREST

The authors declare no conflicts of interest.

REFERENCES

- Summers A, Winkel LA, Hussain HK, DeLancey JOL. The relation between anterior and apical compartment support. *Am J Obstet Gynecol.* 2006;194:1438-1443.
- Haylen BT, Naidoo S, Kerr SJ, Chiu HJ, Birrell W. Posterior vaginal compartment repairs: where are the main anatomical defects? *Int Urogynecol J.* 2016;27:741-745.
- Haylen BT, Maher CF, Barber MD, et al. An International Urogynecological Association (IUGA)/International Continence Society (ICS) Joint report on the Terminology for Pelvic Organ Prolapse. Dual publication. *Int Urogynecol J.* 2016;27(2):165-194.
- DeLancey JOL. Anatomical aspects of vaginal eversion after hysterectomy. *Am J Obstet Gynecol.* 1992;166:117-124.
- Zemlyn S. The length of the uterine cervix and its significance. *J Clin Ultrasound.* 1981;9(6):267-269.
- Vu D, Haylen BT, Tse K, Farnsworth A. Surgical anatomy of the uterosacral ligament. *Int Urogynecol J.* 2010;21(9):1123-1128.
- Samaan A, Vu D, Haylen BT, Tse K. Cardinal ligament surgical anatomy: cardinal points at hysterectomy. *Int Urogynecol J.* 2014;25(2):189-195.
- Haylen BT, Cerqui AJ. Postpartum uterine retroversion causing bladder outflow obstruction: cure by laparoscopic ventrosuspension. *Int Urogynecol J.* 1999;10(6):353-355.
- Haylen BT, Yang V, Tse VUD. K. Midline uterosacral plication anterior colporrhaphy combo (MUSPACC): preliminary surgical report. *Int Urogynecol J.* 2011;2011:69-75.
- Barber MD, Visco AG, Weidner AC, Amundsen CL, Bump CL. Bilateral uterosacral ligament vaginal vault suspension with site-specific endopelvic fascia defect repair for treatment of pelvic organ prolapse. *Am J Obstet Gynecol.* 2000;183:1402-1410.
- Schull BL, Bachofen C, Coates KW, Keuhl TJ. A transvaginal approach to repair of apical and other associated sites of pelvic organ prolapse with uterosacral ligaments. *Am J Obstet Gynecol.* 2000;183:1365-1373.
- Karram M, Goldwasser S, Kleeman S, Steele A, Vassallo B, Walsh P. High uterosacral vaginal vault suspension with fascial reconstruction for vaginal repair of enterocoele and vaginal vault prolapse. *Am J Obstet Gynecol.* 2001;185:1339-1343.
- Bump RC, Mattiasson A, Bø K, et al. The standardization of female pelvic organ prolapse and pelvic floor dysfunction. *Am J Obstet Gynecol.* 1996;175(1):10-17.
- Nichols DH. Sacrospinous fixation for massive eversion of the vagina. *Am J Obstet Gynecol.* 1992;142:901-904.
- Haylen BT. Retroverted uterus: ignored to date but core to prolapse. *Int Urogynecol J.* 2006;17(6):555-558.
- Haylen BT. The retroverted uterus: again ignored but still core to prolapse. *Neuro Urol.* 2022. doi:10.1002/nau.24926

How to cite this article: Haylen BT, Vu D. Surgical anatomy of the vaginal vault. *Neurourology Urodyn.* 2022;41:1316-1322. doi:10.1002/nau.24963