

# Perimitral atrial flutter with partial conduction block between left atrium and coronary sinus



Ryota Isogai, MD,\* Seiichiro Matsuo, MD,\* Ryohsuke Narui, MD,\* Shingo Seki, MD,\* Michihiro Yoshimura, MD,† Teiichi Yamane, MD†

From the \*Department of Cardiovascular Medicine, Katsushika Medical Center, The Jikei University School of Medicine, Tokyo, Japan, and †Department of Cardiology, The Jikei University School of Medicine, Tokyo, Japan.

## Introduction

As the indication of catheter ablation of atrial fibrillation (AF) expanded from a paroxysmal form to long-standing persistent AF, an ablation strategy for AF in the atrium to modify the AF substrate has been developed.<sup>1–3</sup> The diagnosis of atrial tachycardia (AT), following catheter ablation of persistent AF, could be challenging in some patients owing to extensive prior atrial ablation lesions. Among ATs related to AF ablation, macroreentrant AT circulating the mitral annulus is the most common tachycardia in patients who have undergone catheter ablation of AF.<sup>4</sup> Perimitral AT (PMAT) is generally diagnosed by activation mapping and entrainment analysis. PMAT presents 1 direction of activation sequence on the coronary sinus (CS), indicating propagation of the left atrial posterior wall. In the anterior aspect of the left atrium (LA), the vice-versa direction of the CS should be observed in PMAT. Thus, PMAT can be excluded from the diagnosis in patients with the same activation direction between the CS and anterior LA. However, ATs occurring in patients with prior LA ablation might be complex and require detailed mapping in the diagnosis and treatment of tachycardia. We herein describe the PMAT case with the CS activation sequence opposite the atrial activation direction.

## Case report

A 67-year-old man with a history of persistent AF underwent initial catheter ablation, which consisted of isolation of the pulmonary vein (PV), roof-line ablation between the left and right superior PVs, mitral isthmus ablation between the left inferior PV and mitral annulus, CS ablation including the endocardial aspect, and cavotricuspid isthmus ablation. Repeat ablation was conducted to treat the AF and AT, which

## KEY TEACHING POINTS

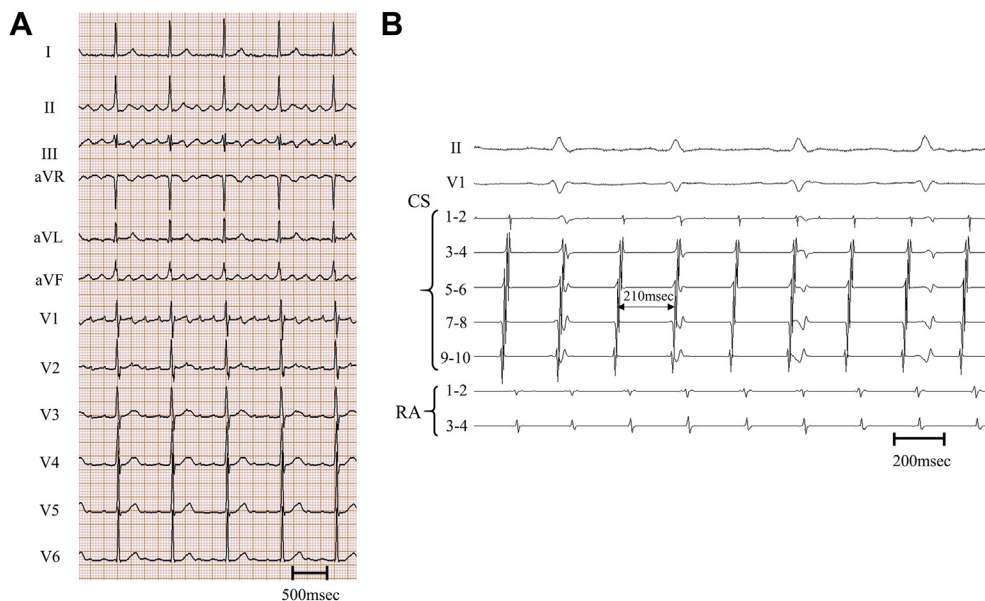
- Complex atrial tachycardia could be developed in patients with history of extensive catheter ablation for atrial fibrillation.
- Although the mechanism of tachycardia is commonly evaluated by use of high-density mapping system and entrainment analysis, inconsistent results of electrophysiological evaluations might be observed in some patients owing to prior extensive ablation of atrial fibrillation.
- In the present case, the activation sequence of the coronary sinus was not consistent with that in the posterior wall of the left atrium because of prior ablation of the coronary sinus. It is important to recognize and verify the prior ablation lesion set in patients with atrial tachycardia who underwent catheter ablation.

developed 1 year after the initial AF ablation. During the repeat procedure, isolation of the reconnected PVs (the left and right superior PVs) was performed. The AT was diagnosed as macroreentrant AT circulating around the mitral annulus in a counterclockwise direction. Subsequent radio-frequency application on the mitral isthmus line terminated the PMAT. Although stable sinus rhythm was obtained for 2 years without antiarrhythmic drug treatment, AT repeatedly and persistently developed. After informed consent was obtained, an electrophysiological study and catheter ablation were performed to treat the AT.

A 20-polar 2-site (10-polar for the right atrium and 10-polar for the CS) mapping catheter (Abbott, Chicago, IL) was positioned in the CS. An open-irrigated 3.5-mm-tip ablation catheter (FlexAbility, Abbott) and a steerable double circular 20-polar mapping catheter (Inquiry AFocus II, Abbott) were inserted into the LA to identify the AT mechanism.

**KEYWORDS** Atrial fibrillation; Atrial tachycardia; Catheter ablation; Coronary sinus; Mitral isthmus  
(Heart Rhythm Case Reports 2019;5:179–182)

**Address reprint requests and correspondence:** Dr Seiichiro Matsuo, Department of Cardiology, The Jikei University Katsushika Medical Center, 6-41-2, Aoto, Katsushika-ku, Tokyo 125-8506, Japan. E-mail address: [mattsuu@tc4.so-net.ne.jp](mailto:mattsuu@tc4.so-net.ne.jp).



**Figure 1** Surface electrocardiogram and intracardiac electrocardiogram of atrial tachycardia. **A:** The 12-lead electrocardiogram demonstrated narrow QRS tachycardia with a cycle length of 210 ms. **B:** Intracardiac cardiogram during atrial tachycardia. CS = coronary sinus (1–2 = most distal pair, 9–10 = most proximal pair); RA = right atrium; II and V1 represent recordings from the 12-lead surface electrocardiogram.

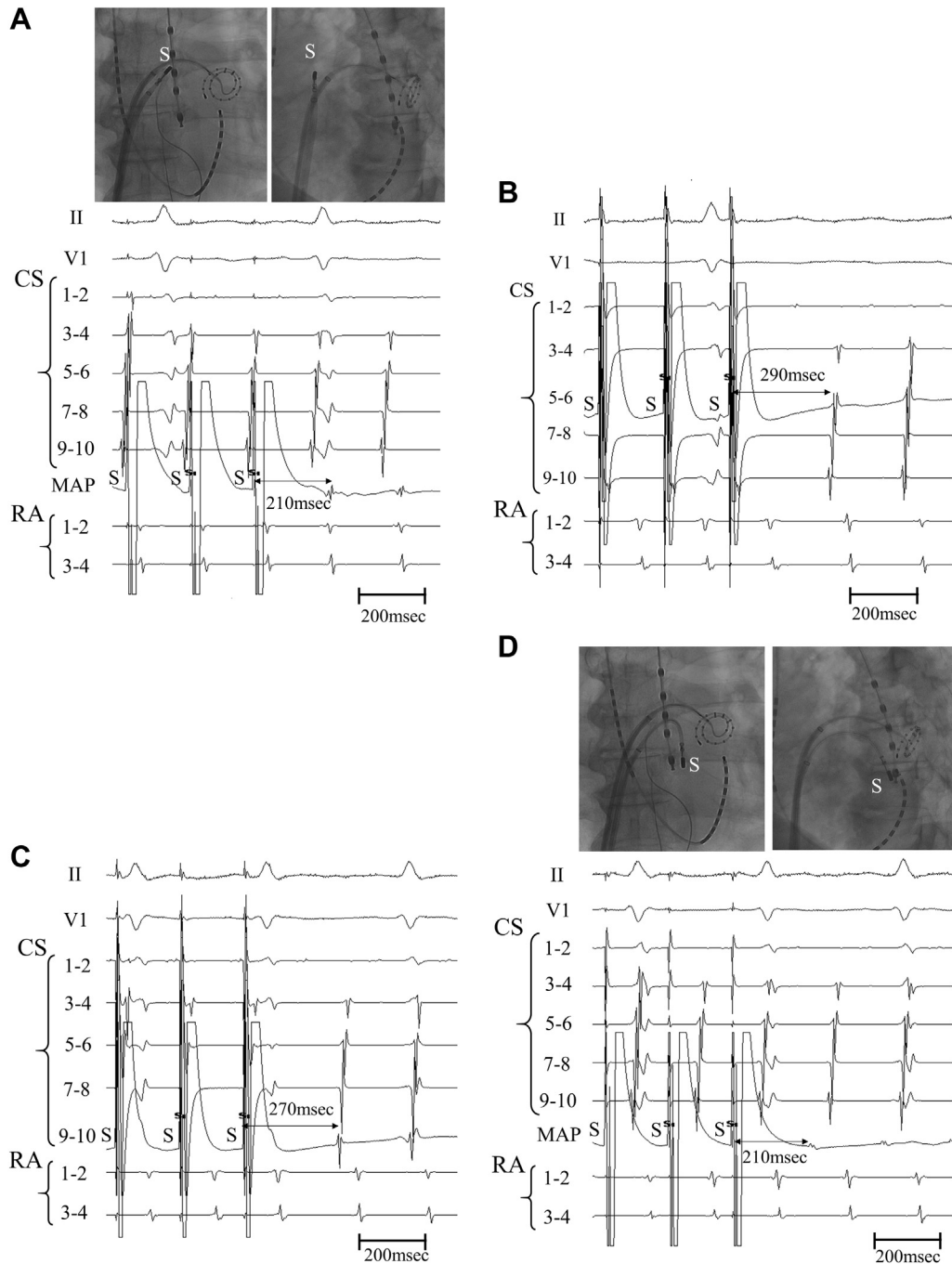
Both the surface and bipolar endocardial electrograms were continuously monitored and recorded for offline analysis (Bard Electrophysiology, Boston Scientific, Natick, MA). The intracardiac electrogram was filtered from 30 to 500 Hz and then measured at a sweep speed of 100 mm/s. Regular tachycardia was sustained at the beginning of the ablation procedure with 210 ms of tachycardia cycle length (Figure 1A). Recurrence of PMAT was suspected because the CS catheter demonstrated 1 propagative direction from septal to distal (Figure 1B). Brief mapping using an ablation catheter on the anterior LA revealed a septal-to-lateral propagation pattern as the CS activation sequence. The entrainment analysis in the anterior LA demonstrated that the postpacing interval (PPI) was equal to the tachycardia cycle length (Figure 2A). In contrast, the PPI was not consistent with the tachycardia cycle length at the 2 sites within the CS (Figure 2B and C). Thus, PMAT was possibly excluded by the entrainment analysis in these 3 sites, and high-density mapping of the LA was subsequently performed using a steerable double circular 20-polar mapping catheter (Inquiry AFocus II catheter, Abbott). Interestingly, the high-density mapping of the atrium diagnosed the AT as PMAT with a clockwise direction, which was in an opposite direction to the CS (Figure 3). In addition, entrainment analysis at the posterior LA presented the PPI as consistent with the tachycardia cycle length (Figure 2D). The PMAT was finally confirmed by the termination of AT by radiofrequency application of the mitral annulus side on the mitral isthmus line (Supplemental Figure 1). The bidirectional conduction block was confirmed by a classical pacing maneuver. No atrial arrhythmia was induced by the atrial burst pacing with isoproterenol administration. After a follow-up of 24

months, the patient has remained free from any atrial tachyarrhythmia recurrence, without antiarrhythmic medication.

## Discussion

This report describes a patient presenting with complex AT after multiple catheter ablations of persistent AF. This tachycardia demonstrated the same activation sequence between the anterior LA and CS, which can simply exclude PMAT. However, high-density mapping and entrainment analysis in the LA revealed the mechanism of AT as PMAT. In patients who had undergone prior ablation in the LA, detailed high-density activation mapping should be performed to evaluate and treat the tachycardia.

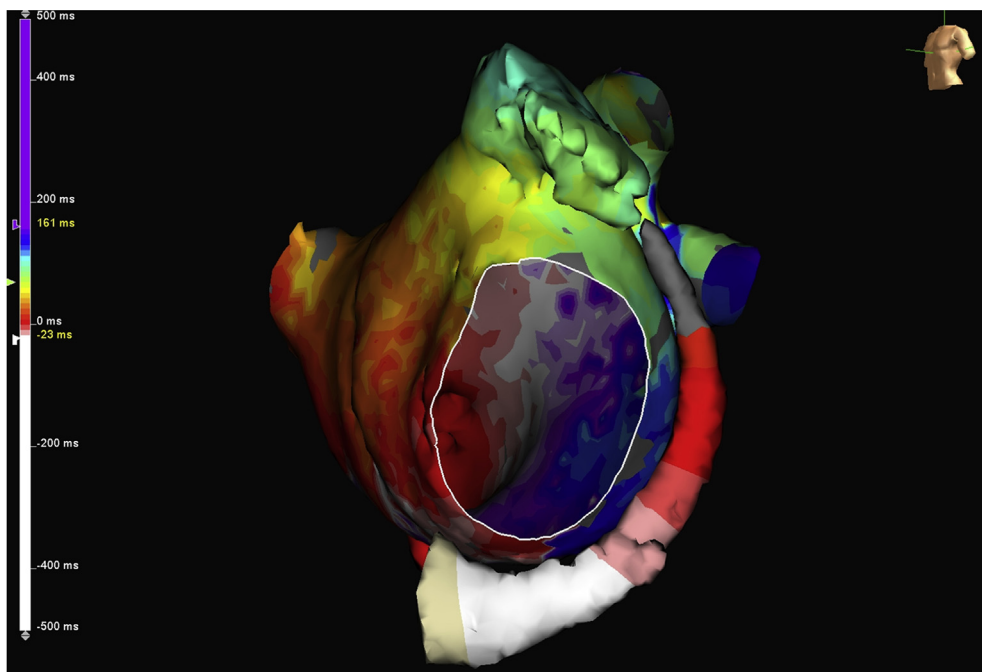
PMAT has been demonstrated as the most common macroreentrant AT in patients with persistent AF who have undergone catheter ablation. It could usually be diagnosed by a classical mapping method including activation mapping and entrainment analysis at the remote sites around the mitral annulus.<sup>4</sup> The activation sequence of the CS is useful in the diagnosis of AT. PMAT should be considered as the mechanism of AT in patients with 1-direction activation sequence of the CS. Furthermore, activation in the anterior LA is in the vice-versa direction to the CS, which indicates a propagation pattern circulating around the mitral annulus. Thus, PMAT could usually be excluded in patients with the same activation direction in the anterior LA and CS. In the present case, dissociation of the activation sequence in the CS was possibly because of CS ablation during the prior ablation of AF. CS ablation has been described as one of the therapeutic strategies for persistent AF.<sup>5</sup> CS ablation aiming at disconnection of the fiber between the CS and LA resulted in



**Figure 2** Entrainment analysis during atrial tachycardia. **A:** Intracardiac recordings during the entrainment analysis at the anterior left atrium by the mapping catheter. The postpacing interval (PPI) at the anterior left atrium was equal to the tachycardia cycle length. **B:** The entrainment analysis at the middle of the coronary sinus (CS) by pacing from CS 5 to CS 6. The PPI at CS 5–6 was 290 ms. **C:** The entrainment analysis at the proximal part of the CS (CS 9–10). The PPI at CS 9–10 was longer than the tachycardia cycle length (270 ms). **D:** The entrainment analysis in the posterior left atrium demonstrated that the PPI at this site was consistent with the tachycardia cycle length. MAP = mapping catheter; other abbreviations are the same as in [Figure 1](#).

prolongation of the cycle length of AF.<sup>5</sup> The partial disconnection of the distal CS by prior CS ablation resulted in the septal-to-lateral activation sequence even during PMAT with clockwise direction. PMAT could develop in patients with partial disconnection of CS, as in this case. To diagnose the AT mechanism, entrainment analysis has been performed

as the confirmation of the circuit of macroreentrant tachycardia, and the CS has been used in place of the posterior LA for electrophysiological study including entrainment analysis. However, the CS could not be used substantially because of elimination of electrical conduction between the CS and atrium in patients undergoing CS ablation. In the



**Figure 3** The high-density 3-dimensional mapping of the left atrium and coronary sinus. The activation mapping demonstrated the septal-to-lateral activation sequence within the coronary sinus, which is opposite to that of the posterior left atrium.

present case, the CS was connected to the LA only in the proximal portion. Interestingly, the entrainment analysis within the CS demonstrated that the PPI in the middle part of the CS (CS 5–6) was longer than that of the CS proximal part (CS 9–10) by 20 ms (Figure 2B and C). The prolongation of PPI at the distal part of the CS indicated that the proximal part of the CS is closer to the tachycardia circuit compared to the distal part, suggesting the partial connection between the CS and LA in the proximal lesion. In addition, following restoration of sinus rhythm by mitral isthmus ablation, standard pacing maneuver by pacing CS distal and proximal confirmed the establishment of bidirectional conduction block of the mitral isthmus. During the pacing, there was no double potential and no dissociated activity on the CS catheter. In the present case, the CS was not totally isolated from the atrium.

The previous study reported that AT developed in approximately 50% of patients with persistent AF who had undergone catheter ablation involving extensive ablation in the atria, in addition to PV isolation.<sup>6</sup> Additionally, mitral isthmus linear ablation in patients with persistent AF facilitated the development of PMAT.<sup>7</sup> In the present case, mitral isthmus ablation had been performed in the initial procedure to modify the AF substrate. PMAT developed despite the establishment of a bidirectional conduction block through the mitral isthmus line. Reconnection of the mitral isthmus line has been demonstrated in 44%–73% of patients who had undergone mitral isthmus ablation.<sup>8,9</sup> To prevent reconnection of the mitral isthmus line, facilitating the development of the PMAT, the bidirectional conduction block should be established in patients who have undergone this linear ablation.

## Appendix Supplementary data

Supplementary data associated with this article can be found in the online version at <https://doi.org/10.1016/j.hrcr.2018.11.006>.

## References

- Nademanee K, McKenzie J, Kosar E, Schwab M, Sunsaneewitayakul B, Vasavakul T, Khunnawat C, Ngarmukos T. A new approach for catheter ablation of atrial fibrillation: mapping of the electrophysiologic substrate. *J Am Coll Cardiol* 2004;43:2044–2053.
- Haïssaguerre M, Sanders P, Hocini M, et al. Catheter ablation of long-lasting persistent atrial fibrillation: critical structures for termination. *J Cardiovasc Electrophysiol* 2005;16:1125–1137.
- Matsuo S, Yamane T, Date T, et al. Substrate modification by pulmonary vein isolation and left atrial linear ablation in patients with persistent atrial fibrillation: its impact on complex-fractionated atrial electrograms. *J Cardiovasc Electrophysiol* 2012;23:962–970.
- Jais P, Matsuo S, Knecht S, Weerasooriya R, Hocini M, Sacher F, Wright M, Nault I, Lellouche N, Klein G, Clémenty J, Haïssaguerre M. A deductive mapping strategy for atrial tachycardia following atrial fibrillation ablation: importance of localized reentry. *J Cardiovasc Electrophysiol* 2009;20:480–491.
- Haïssaguerre M, Hocini M, Takahashi Y, et al. Impact of catheter ablation of the coronary sinus on paroxysmal or persistent atrial fibrillation. *J Cardiovasc Electrophysiol* 2007;18:378–386.
- O'Neill MD, Wright M, Knecht S, et al. Long-term follow-up of persistent atrial fibrillation ablation using termination as a procedural endpoint. *Eur Heart J* 2009;30:1105–1112.
- Matsuo S, Wright M, Knecht S, Nault I, Lellouche N, Lim KT, Arantes L, O'Neill MD, Hocini M, Jais P, Haïssaguerre M. Peri-mitral atrial flutter in patients with atrial fibrillation ablation. *Heart Rhythm* 2010;7:2–8.
- Sawhney N, Anand K, Robertson CE, Wurdeman T, Anousheh R, Feld GK. Recovery of mitral isthmus conduction leads to the development of macro-reentrant tachycardia after left atrial linear ablation for atrial fibrillation. *Circ Arrhythm Electrophysiol* 2011;4:832–837.
- Wong KC, Qureshi N, Jones M, Rajappan K, Bashir Y, Betts TR. Mitral isthmus ablation using steerable sheath and high ablation power: a single center experience. *J Cardiovasc Electrophysiol* 2012;23:1193–1200.