



Since January 2020 Elsevier has created a COVID-19 resource centre with free information in English and Mandarin on the novel coronavirus COVID-19. The COVID-19 resource centre is hosted on Elsevier Connect, the company's public news and information website.

Elsevier hereby grants permission to make all its COVID-19-related research that is available on the COVID-19 resource centre - including this research content - immediately available in PubMed Central and other publicly funded repositories, such as the WHO COVID database with rights for unrestricted research re-use and analyses in any form or by any means with acknowledgement of the original source. These permissions are granted for free by Elsevier for as long as the COVID-19 resource centre remains active.

(1270)

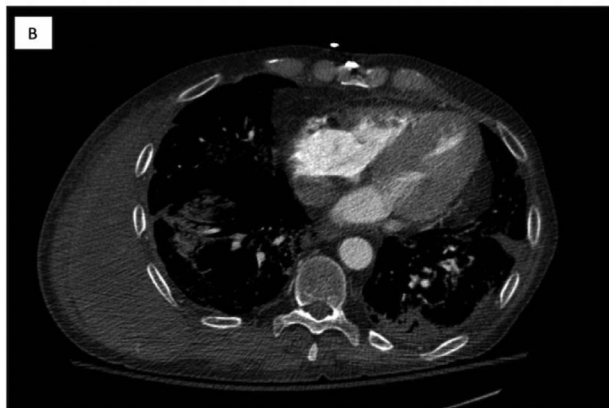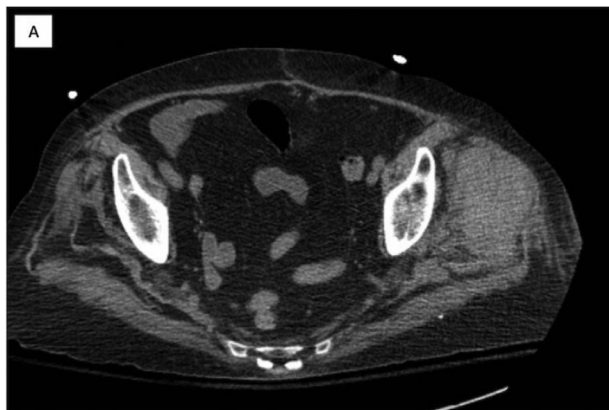
Two Cases of Spontaneous Bleeding in Lung Transplant Recipients Treated with Systemic Anticoagulation for COVID-19

M.T. Olson,¹ A. Omar,² S. Tokman,² J. Carigo,² R. Walia,² and A. Arjuna.² ¹University of Arizona College of Medicine - Phoenix, Phoenix, AZ; and the ²Norton Thoracic Institute, St. Joseph's Hospital and Medical Center, Phoenix, AZ.

Introduction: COVID-19 promotes inflammation and a hypercoagulable state. Antithrombotic therapies may be administered for thromboprophylaxis in those with severe infection requiring hospitalization. Spontaneous bleeding is an infrequent, yet life-threatening complication in patients receiving systemic anticoagulation.

Case Report: Two bilateral lung transplant recipients - 77-year-old female with idiopathic pulmonary fibrosis (patient A) and 69-year-old male with chronic obstructive pulmonary disease (patient B) - each presented with several days' history of dyspnea, cough, and fatigue at 29-months and 11-months post-transplant, respectively; RT-PCR was positive for SARS-CoV-2 infection in both. Over the course of the next few days, patient A rapidly deteriorated with need for intubation despite initial treatment with antibiotics and corticotherapy. Patient B experienced gradual worsening of respiratory symptoms, which required high-flow oxygen supplementation and IV antibiotics. Inflammatory markers were elevated in both patients, and CT of the chest was consistent with atypical pneumonia in each. Patient A received convalescent plasma as a rescue therapy, and patient B received remdesivir with convalescent plasma. Given the hypercoagulable state in each, patient A and B received enoxaparin and IV heparin, respectively. Slowly, hemoglobin and platelet counts dropped in both patients, with need for transfusion and hemodynamic support. CT of the abdomen revealed a left gluteal intramuscular hematoma in patient A; CT of the chest, abdomen, and pelvis revealed a spontaneous chest wall hematoma and small area of retroperitoneal bleeding in patient B (Figure 1A and B).

Summary: These cases raise awareness for the viral-induced hypercoagulable state observed during the disease course. Clinicians should be cautious to avoid any hemorrhagic complications associated with thromboprophylaxis in selected cases, particularly in at-risk immunosuppressed patients.



(1271)

Sars-CoV-2 Infection in Lung Transplant Patients - Single Center Experience in Portugal

C.L. Figueiredo,¹ A. Magalhães,¹ A.S. Santos,¹ J.E. Reis,² A. Borba,¹ L. Semedo,¹ P. Calvão,² J. Cardoso,¹ and J. Fragata.² ¹Pulmonology and Portuguese Lung Transplant Center, Hospital Santa Marta, CHULC, Lisboa, Portugal; and the ²Cardiothoracic Surgery and Portuguese Lung Transplant Center, Hospital Santa Marta, CHULC, Lisboa, Portugal.

Introduction: Lung transplant (LT) patients are immunosuppressed and it is yet to be determined if immunosuppression plays a role in SARS-CoV-2 infection. Due to this lack of information about COVID-19 in solid transplant patients, case series are of utmost importance. We report two cases of LT patients with COVID-19 at our LT center.

Case Report: We report a 60-year-old man submitted to a bilateral LT due to COPD in January 2020. Immunosuppression: basiliximab as induction and prednisolone, mycophenolate mofetil and tacrolimus as maintenance therapy. He was discharged 47 days post-operatively. Six months after LT, as routine screening to an elective endoscopy for previously controlled Barrett's esophagus, RT-PCR of naso-pharyngeal swabs detected SARS-CoV-2 RNA, assuming the diagnosis of COVID-19. He was hospitalized for monitoring despite being asymptomatic. Oxygen saturation was always higher than 97% at room air. Leukocyte was $5.730 \times 10^9/L$ (lymphopenia $530 \times 10^9/L$), D-dimer 1913 ug/L, C-reactive protein (CRP) 51,1 mg/l, ferritin 163,7 ng/mL and lactate dehydrogenase (LDH) 370 units/L. CT-scan excluded thromboembolism and active infection. He remain asymptomatic and was discharged. The second case was a 54-year-old man submitted to a bilateral LT due to COPD in June 2020. Immunosuppression: basiliximab as induction and prednisolone, mycophenolate mofetil and tacrolimus as maintenance therapy. He was discharged 76 days post-operatively due to post-infection anastomosis stenosis. Three months after LT, as routine screening to a bronchofibroscopy for reevaluation of stenosis, RT-PCR naso-pharyngeal swabs detected SARS-CoV-2 RNA, assuming the diagnosis of COVID-19. He revealed more dyspnea (mMRC 2) and cough than usual, with no other symptoms. Oxygen saturation was always higher than 96% at room air. Leukocyte $7.560 \times 10^9/L$, CRP 41,5 mg/l, LDH 566 units/L. He stayed at home in isolation with mild symptoms that improved in one week to his previous health status. Both patients had no travel history and no known contact with SARS-CoV-2 infected patient.

Summary: We report 2 cases among a total of 174 LT patients in follow-up at our center (1,1%), we underline that SARS-CoV-2 infection can present itself with mild or no symptoms in LT patients that theoretically are more vulnerable. Also we reinforce the importance of routine screening of these patients before any procedure.

(1272)

Four Cases of COVID-19 Infection in Lung Transplant Recipients

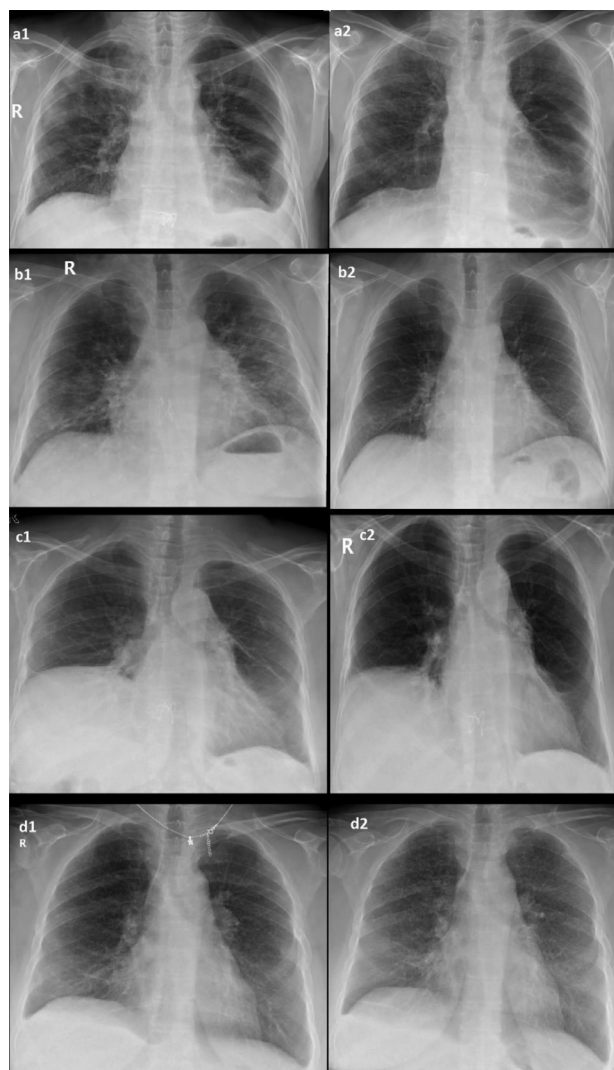
S. Türkan,¹ M.F. Sahin,¹ M.A. Beyoglu,¹ A. Yazicioglu,¹ Y.T. Tekce,² and E. Yekeler.¹ ¹Department of General Thoracic Surgery and Lung Transplantation, Ankara City Hospital, University of Health Sciences, Ankara, Turkey; and the ²Department of Infectious Diseases, Ankara City Hospital, University of Health Sciences, Ankara, Turkey.

Introduction: There are limited data about short and long-term problems caused by COVID-19 infection in lung transplant and other organ transplant recipients. We share the clinical, laboratory, radiological and treatment results of four lung transplant recipients after COVID-19 infection who were operated in our clinic.

Case Report: All patients had positive PCR tests for COVID-19, three of four patients had dyspnea and desaturation with ground glass areas on thorax CT. One patient only complained of impaired sense of smell. Three patients with signs of pneumonia were hospitalized and one patient was treated on an outpatient basis. While one of the patients received a combine therapy with favipiravir, hydroxychloroquine, azithromycin, 3 patients received only favipiravir treatment. Three consecutive days of 1000 mg/day methylprednisolone treatment were used in 3 patients with signs of pneumonia and dyspnea, because symptoms did not improve. Death was not observed in any of the cases. The complaint of the patient, who had

symptoms of impaired sense of smell, resolved within 5 days. Three patients with persistent dyspnea, desaturation, and radiological symptoms showed improvement in symptoms and radiological findings after pulse steroid therapy. In one of the cases, it was observed that the lesions caused interseptal thickening in the control tomography scan performed after three months.

Summary: There is limited data about the treatment and long-term results of Covid-19 infection. High dose steroid therapy may be a safe choice for the treatment of COVID-19 infection with signs of pneumonia in organ transplant recipients. However, further studies are needed to determine whether the disease leaves sequelae fibrotic areas in the lung or triggers /accelerates the CLAD process seen after lung transplantation.



(1273)

Bilateral Orthotopic Lung Transplantation after Resection of Benign Solitary Fibrous Tumor in the Donor Lung

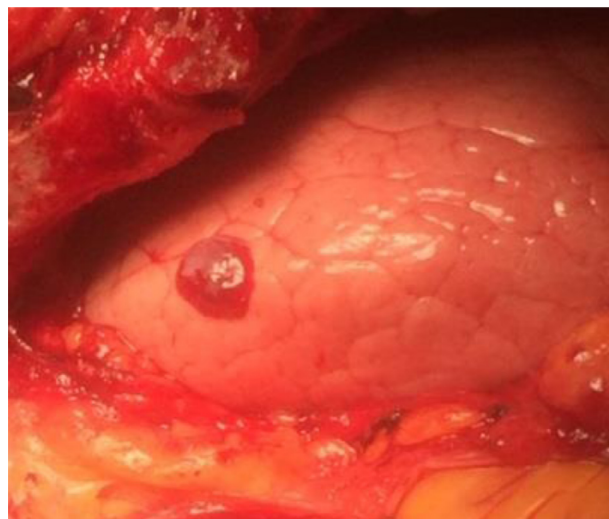
S. Balasubramanya,¹ D. Sayah,² and A. Ardehali.¹ ¹Cardiac Surgery, University of California Los Angeles (UCLA), Ronald Reagan UCLA Medical Center, Los Angeles, CA; and the ²Division of Pulmonology, University of California Los Angeles (UCLA), Ronald Reagan UCLA Medical Center, Los Angeles, CA.

Introduction: Solitary fibrous tumor (SFT) of the pleura is a rare soft tissue tumor of mesenchymal origin. Transplantation of donor lung with SFT

has not been reported in the literature. We report the first case of a bilateral orthotopic lung transplantation utilizing donor lung which had SFT in the left lung.

Case Report: The donor was a brain dead 25 year old male who suffered from subarachnoid hemorrhage. He had no other comorbidities. The recipient is a 59 year old male with end stage fibrosing interstitial lung disease consistent with usual interstitial pneumonia (UIP) who was listed for bilateral orthotopic lung transplantation. His other comorbidities included triple vessel coronary artery disease, hypertension and type 2 diabetes mellitus. During the lung harvest, it was noted that the left lung had a circumferential 1 centimeter reddish appearing nodule in the left upper lobe. A stapled wedge resection of this nodule was performed during back table dissection. Pathology showed benign solitary fibrous tumor with 1 centimeter negative margins. The recipient underwent BOLT and 3 vessel coronary artery bypass grafting (CABG) on cardiopulmonary bypass via a thoracosternotomy (Clamshell). Post-operative course was uneventful and the patient was discharged home on post operative day 15. He continues to do well and symptom free at 1 year follow up. He underwent chest computed tomography (CT) scan 6 months and 1 year and there were no lung lesions identified.

Summary: Bilateral Orthotopic Lung Transplantation can be successfully be performed when utilizing donor lungs with benign tumors like solitary fibrous tumor. Regular follow up with CT scans is a necessary surveillance study to ensure there is no tumor recurrence.



(1274)

Thoracoscopic Bilobectomy after Bilateral Single Sequential Lung Transplantation in a Cystic Fibrosis Patient with Post-Transplant Airway Stenosis

N. Mayer, P. Perikleous, G. Doukas, J. Finch, E. Beddow, V. Anikin and N. Asadi. Thoracic Surgery, Royal Brompton & Harefield Foundation Trust, Harefield, United Kingdom.

Introduction: Airway complications following lung transplantation are associated with significant morbidity and mortality; they can result to significant functional impairment, poor quality of life and frequent hospitalizations. Anastomotic stenosis remains the commonest post-transplant airway complication with an estimated incidence between 1.6-32%. Non-anastomotic bronchial stenosis is rare and is not reported frequently.

Case Report: We present the case of a 46-year-old female cystic fibrosis patient requiring right lower bilobectomy following bilateral sequential lung transplant in April 2018, which was complicated by stricture of the right main bronchus requiring serial dilatations. Recurrent chest infections related to chronic *Achromobacter xylosoxidans* lead to complete right