


# Obesity-induced vena cava compression syndrome: a case report of a rare precipitant of a type 2 myocardial infarction in a patient with critical aortic stenosis

Alexander M. Sellers <sup>1,2\*</sup>, Ferdous Alam<sup>2</sup>, Jayme S. Bennetts <sup>3,4</sup>, Sam J. Lehman<sup>5,4</sup>, and Ajay R. Sinhal<sup>5,4</sup>

<sup>1</sup>Department of Cardiology, Central Adelaide Local Health Network, Port Road, Adelaide, South Australia 5000, Australia; <sup>2</sup>Whyalla Hospital and Health Service, Wood Terrace, Whyalla, South Australia 5600, Australia; <sup>3</sup>Department of Cardiothoracic Surgery, Flinders Drive, Bedford Park, Adelaide, South Australia 5042, Australia; <sup>4</sup>College of Medicine and Public Health, Flinders University, Sturt Road, Bedford Park, South Australia 5042, Australia; and <sup>5</sup>Department of Cardiology, Southern Adelaide Local Health Network, Flinders Drive, Bedford Park, Adelaide, South Australia 5042, Australia

Received 1 May 2022; first decision 11 July 2022; accepted 29 November 2022; online publish-ahead-of-print 6 December 2022

## Background

Obesity is a global health problem of increasing prevalence with a broad range of multisystem complications. An under-recognized complication of severe obesity is the potential haemodynamic compromise that may arise due to pathological external compression of the inferior vena cava whilst lying in the supine position, a phenomenon known as obesity-induced vena cava compression syndrome.

## Case summary

A 56-year-old independent woman presented to a rural Australian hospital for routine dressing care for bilateral lymphoedema on a background of class III morbid obesity (weight 197 kg, body mass index 68.55 kg/m<sup>3</sup>) and aortic stenosis. Whilst laid in the supine position with both legs elevated to aid lower limb venous return, the patient developed angina with associated troponin rise (15 to 75 to 332 ng/L) and inferolateral territory ischaemic changes on electrocardiogram. The pain then resolved shortly after restoring the patient to the upright position. A transthoracic echocardiogram showed critical bicuspid aortic stenosis. Computerized tomography coronary angiogram showed no significant coronary artery disease. Following multidisciplinary discussions, a transcatheter aortic valve insertion was performed via a transfemoral approach. Post-procedure, she went into atrial fibrillation, she was cardioverted into a sinus rhythm with new left bundle branch block. There were no complications otherwise, and the patient was discharged home following a brief period of convalescence.

## Discussion

We describe a case of suspected obesity-induced vena cava compression syndrome precipitating a type 2 myocardial infarction in a pre-load dependent patient with critical bicuspid valve aortic stenosis. This case highlights a potential haemodynamic consequence of morbid obesity in the supine position.

## Keywords

Case report • TAVI • Aortic stenosis • Bicuspid aortic valve

## ESC curriculum

4.2 Aortic stenosis • 7.1 Haemodynamic instability • 4.10 Prosthetic valves

\* Corresponding author. Tel: +61 8 7074 0000, Email: [alexander.sellers@sa.gov.au](mailto:alexander.sellers@sa.gov.au)

Handling Editor: Sameh Shaheen

Peer-reviewers: Damiano regazzoli-Lancini; Claudio Montalto

Compliance Editor: Nikolaos Spinthakis

Supplementary Material Editor: Michael Waight

© The Author(s) 2022. Published by Oxford University Press on behalf of the European Society of Cardiology.

This is an Open Access article distributed under the terms of the Creative Commons Attribution-NonCommercial License (<https://creativecommons.org/licenses/by-nc/4.0/>), which permits non-commercial re-use, distribution, and reproduction in any medium, provided the original work is properly cited. For commercial re-use, please contact [journals.permissions@oup.com](mailto:journals.permissions@oup.com)

## Learning points

- Obesity-induced vena cava compression syndrome is a recognized phenomenon that can cause marked haemodynamic disturbance resulting in complications including type 2 non-ST elevation myocardial infarction.
- In patients with bicuspid aortic valve, in whom a surgical intervention presents a prohibitive risk, transcatheter aortic valve insertion may be a viable alternative treatment option.
- Clinicians should be mindful that critical aortic stenosis is a precarious haemodynamic state sensitive to any sudden changes in ventricular preload.

## Introduction

Obesity is a global health problem of increasing prevalence with a broad range of multisystem complications.<sup>1</sup> An under-recognized complication of severe obesity is the potential haemodynamic compromise that may arise due to lying in the supine position. In 1953, Howard *et al.*<sup>2</sup> first described a phenomenon known as supine hypotensive syndrome, a disorder seen in late pregnancy characterized by a drop in systemic blood pressure when the patient is laid in the supine position caused by the gravid uterus compressing the inferior vena cava, thus compromising venous return and reducing preload resulting in a reduction in cardiac output. Pathological external compression of the inferior vena cava has also been recognized as a complication of obesity, in a phenomenon known as obesity-induced vena cava compression syndrome.<sup>3,4</sup>

## Timeline

Day 0	Presented to rural hospital for elective dressing care for lymphoedema. Whilst laid in supine position develops a type II non-ST elevation myocardial infarction with troponin rise and inferolateral ischaemic changes
Day 4	Patient transferred to a tertiary centre. Transthoracic echocardiogram shows critical bicuspid aortic stenosis. Computerized tomography coronary angiogram shows no significant coronary artery disease
Day 12	Transcatheter aortic valve insertion performed via transfemoral approach using 26 mm Edwards Sapien 3 Ultra bioprosthetic aortic valve
Day 13	Patient successfully cardioverted using transoesophageal echo for atrial fibrillation that developed post procedure
Day 21	Discharged to local rural hospital for further convalescence
Day 23	Discharged home
Day 63	Episode of rapid atrial fibrillation that reverted to sinus rhythm with rate control alone
Day 64	Patient laid in the supine position post-correction of valvulopathy without developing angina. Electrocardiogram recorded showed no ischaemic changes

## Case presentation

A 56-year-old independent woman presented to a rural public South Australian hospital for elective dressing care for bilateral lower limb chronic lymphoedema. Her past medical history was significant for aortic stenosis (AS) due to a congenital bicuspid valve, class III morbid obesity [weight 197.8 kg, body mass index (BMI) 68.5 kg/m<sup>3</sup>], asthma, and

hypothyroidism. The severity of the AS prior to presentation was unknown as the patient had been lost to cardiology follow-up for several years. The emergency department medical officer advised the patient to lay supine in the Trendelenburg position with her legs elevated to aid venous return to reduce the lower limb oedema.

Within minutes after lying supine, the patient developed central chest pain that was characterized as 'like someone sitting on her chest' that radiated to her jaw and was associated with dyspnoea, diaphoresis, and nausea. The patient noted that she had a similar character chest pain experienced exclusively on exertion associated with dyspnoea in the 12 months prior to presentation.

On clinical examination, the patient had a grade 4 ejection systolic murmur auscultated loudest over the aortic valve with a soft second heart sound that radiated to the carotids.

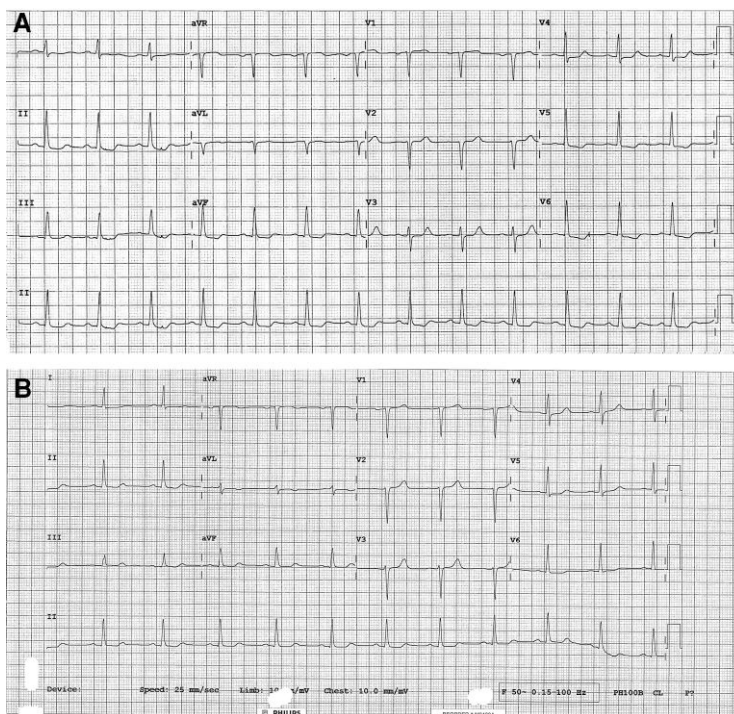
A 12-lead electrocardiogram (ECG) showed new dynamic ST depression in the inferolateral territory (*Figure 1A*). Sequential high sensitivity troponin assays increased from 15 (ng/L) to 75 (ng/L), to 332 ng/L (reference range  $\leq 12$  ng/L). Additional notable findings included a mild hypochromic microcytic anaemia (110 g/L, reference range 115–155 g/L) without any known history of overt bleeding symptoms. Upon returning the patient to the upright position, the patient's angina dissipated within minutes with resolution of ischaemic ECG changes (*Figure 1B*).

Initial diagnosis was non-ST elevation myocardial infarction (NSTEMI), either due to Type 2 myocardial oxygen demand and supply mismatch in the setting of AS or alternatively due to a Type 1 acute plaque rupture event. The patient was treated with therapeutic dose enoxaparin and dual antiplatelet therapy (DAPT) with aspirin and ticagrelor, before being up transferred to a tertiary centre in Adelaide for further investigation and management.

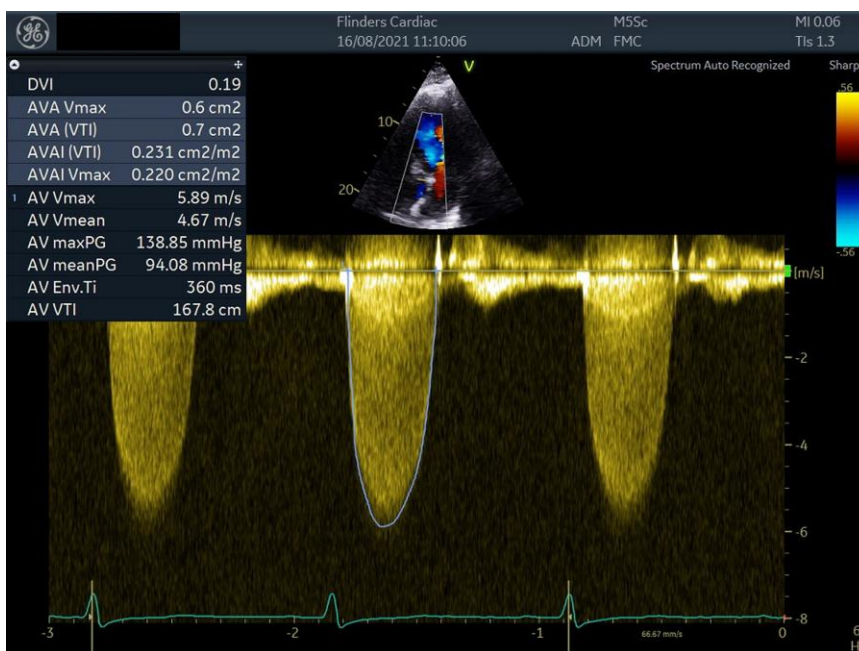
The transthoracic echocardiogram (TTE) demonstrated a bicuspid aortic valve with a mean pressure gradient 94 mmHg (*Figure 2*), peak aortic valve velocity ( $V_{max}$ ) 5.9 m/s, aortic valve area of 0.7, and dimensionless performance index of 0.19. A moderately dilated ascending aorta (4.8 cm diameter measured at the main body) was also noted. There were no regional wall motion abnormalities.

In light of the TTE finding of critical AS, a computerized tomography coronary angiogram (CTCA) was chosen as the first-line investigation, with the plan being that the patient would undergo an invasive coronary angiogram if obstructive coronary artery disease was found. The CTCA excluded the presence of significant obstructive coronary artery disease (*Figure 3A–C*), confirming the diagnosis of type 2 NSTEMI in the context of critical AS; therefore, an invasive coronary angiogram was not performed. Computerized tomography with transcatheter aortic valve insertion (CT TAVI) protocol confirmed bicuspid aortic valve and that the iliofemoral vessels were suitable for transfemoral transcatheter aortic valve insertion (TAVI) (*Figure 4*).

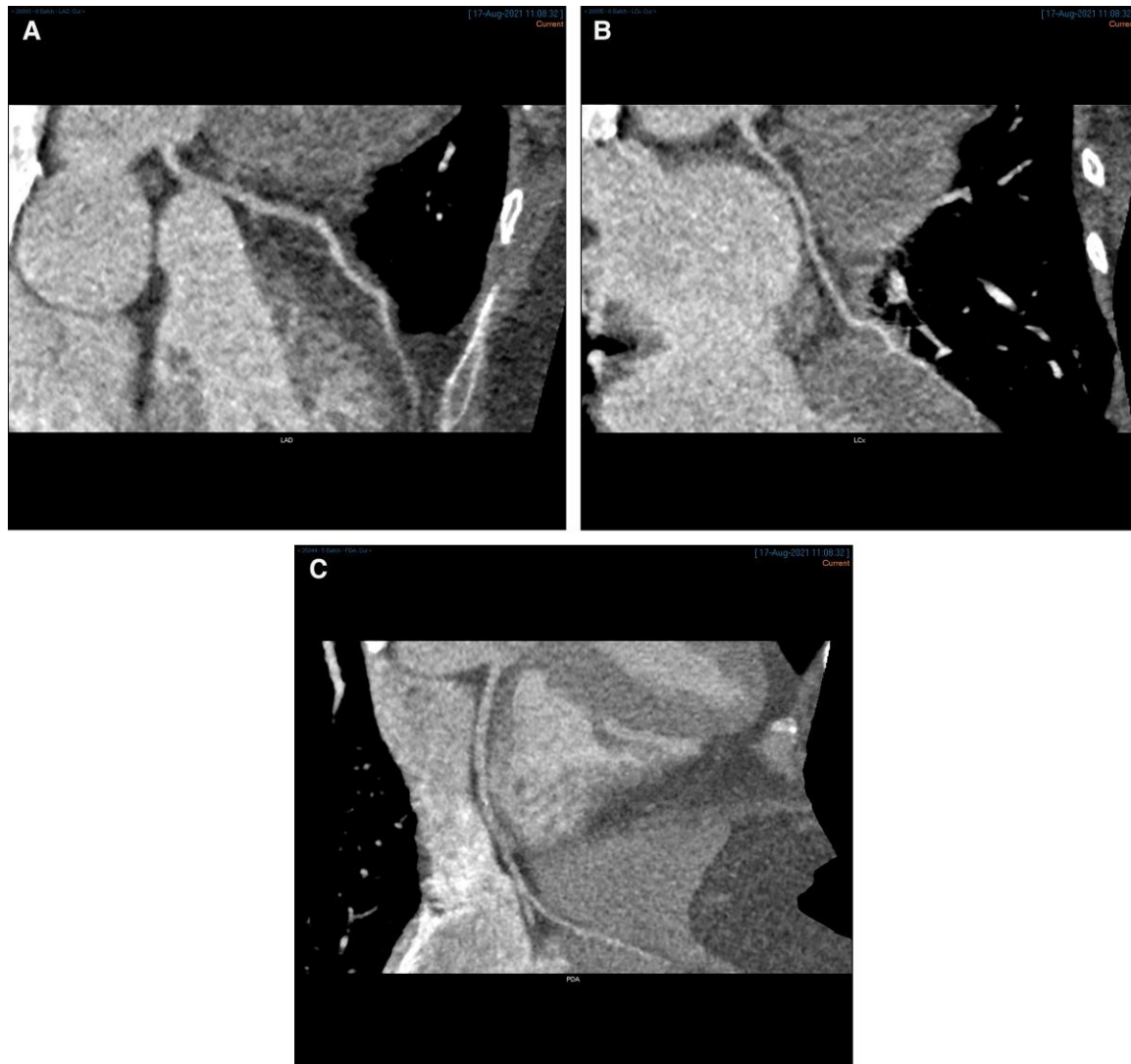
The patient's case was discussed at TAVI multidisciplinary meeting for options of TAVI vs. surgical aortic valve replacement (SAVR) or aortic root replacement. Due to her co-morbidities including class III morbid obesity, she was considered high risk for surgery. Despite bicuspid valve, the annular anatomy was thought to be suitable for TAVI with no significant asymmetric calcification. The right common femoral artery was thought to be the most favoured access with least risk associated



**Figure 1** (A) Electrocardiogram showing initial ischaemic changes with the patient lying supine. (B) Resolved ischaemic changes with the patient upright.



**Figure 2** Transthoracic echocardiogram pre-transcatheter aortic valve insertion aortic valve pressure gradient.



**Figure 3** (A) Computerized tomography coronary angiogram left anterior descending artery. (B) Computerized tomography coronary angiogram left circumflex artery. (C) Computerized tomography coronary angiogram posterior descending artery.

compared to alternatives. Her young age is a relative contraindication for TAVI; however, expectation was that post-TAVI, the patient may lose weight to be a potential candidate for surgical intervention in future.

The patient had an uneventful TAVI procedure via a transfemoral approach with a 26 mm Edwards Sapien 3 Ultra bioprosthetic aortic valve. The femoral access was obtained under ultrasound guidance with vascular surgery colleagues in attendance. Post-valve deployment, haemostasis was achieved with two Proglide® percutaneous lateral sutures (Abbott Laboratories, Chicago, IL, USA).

Postoperatively, the patient went into rapid atrial fibrillation (AF), for which the patient was cardioverted following exclusion of thrombus by transoesophageal echocardiogram. The patient also developed new left bundle branch block, likely secondary to mechanical stretch of the conduction system from valve implantation.

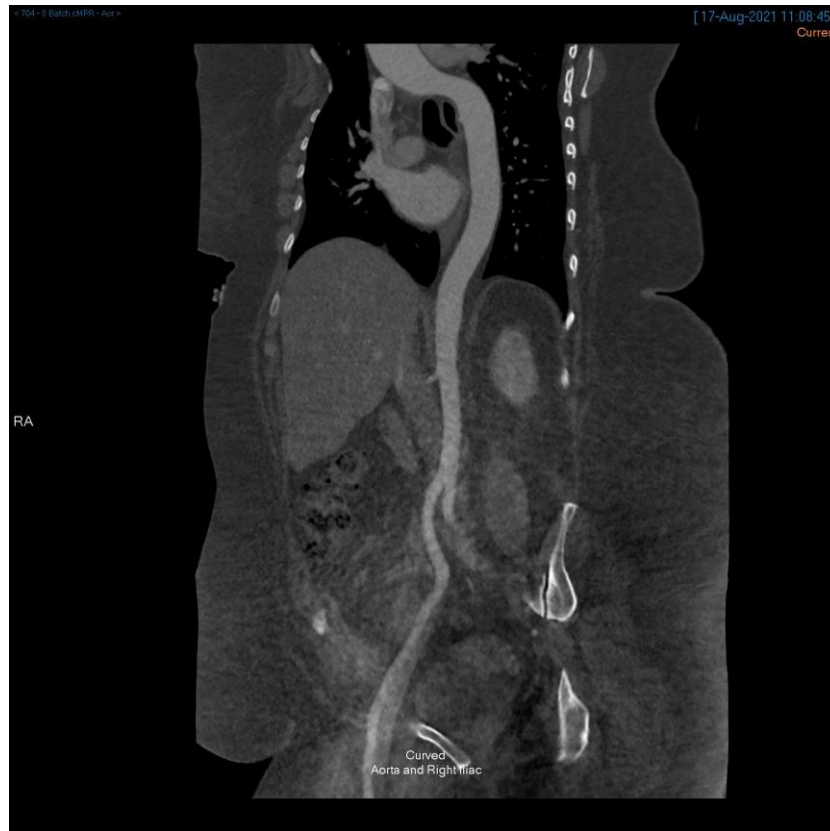The patient was discharged back to the rural public hospital for further convalescence before being discharged home. She was prescribed clopidogrel for antithrombotic therapy post-TAVI and Apixaban for AF. If there was no further AF after a month, the patient was to cease Apixaban and

to commence aspirin, with the plan being to remain on DAPT until 6 months post-TAVI, after which she would remain on lifelong aspirin.

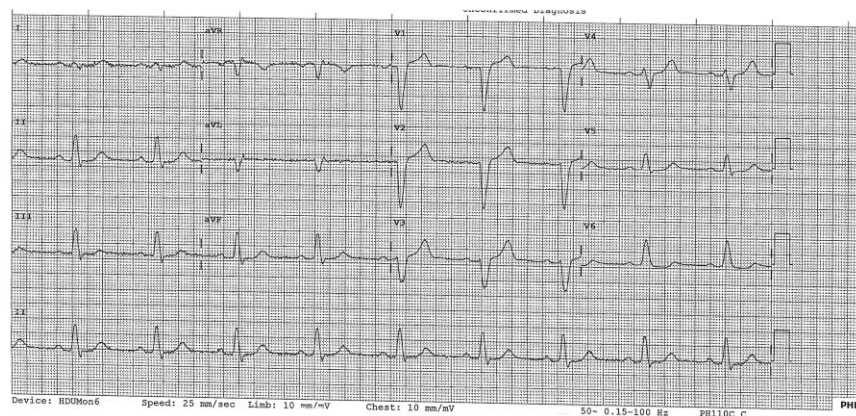
Fifty-two days post-procedure, the patient was seen again. She reported no further angina. The patient was laid in the supine position for a period and monitored on telemetry with no recurrence of angina after several minutes of observation. A repeat ECG (Figure 5) did not demonstrate any new ischaemic changes. TTE images showing the parasternal short axis window with the TAVI valve in-situ and the post-TAVI mean pressure gradient are shown below (Figure 6A and B).

## Discussion

We postulate that the mechanical effect of severe obesity in the supine position with both legs elevated resulted in compression of the inferior vena cava thereby compromising venous return. The resulting reduction of ventricular preload, in the setting of fixed afterload from critical AS, caused a decrement in coronary perfusion pressure with a mismatch in myocardial oxygen supply and demand, resulting in sub-



**Figure 4** Computerized tomography transcatheter aortic valve insertion protocol showing the right common femoral access site.

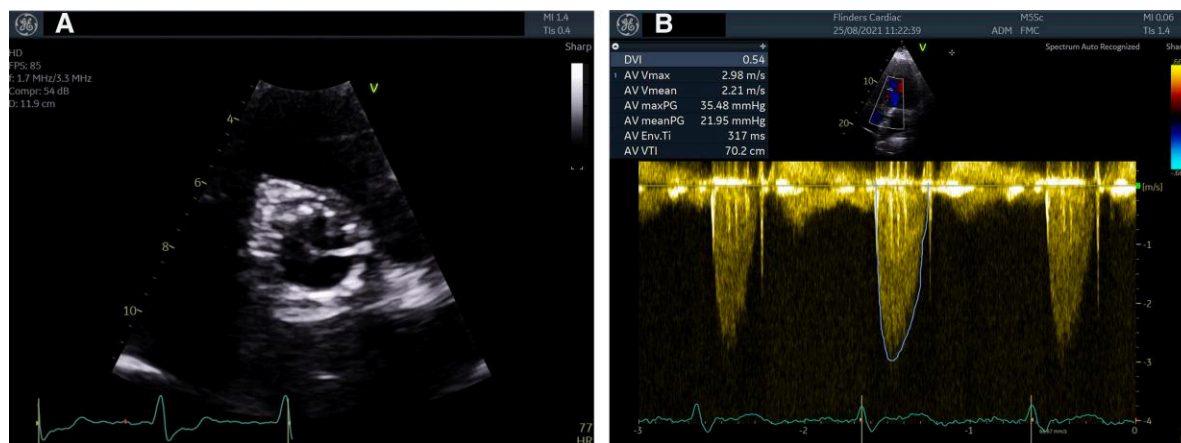


**Figure 5** Electrocardiogram 52 days post-transcatheter aortic valve insertion taken with the patient lying in the supine position that demonstrates nil new ischaemic changes. Left bundle branch block is a known post-procedure complication of transcatheter aortic valve insertion.

endocardial ischaemia and infarction. Overall, this presentation is consistent with a type 2 NSTEMI precipitated by supine obesity hypotensive syndrome on a background of critical AS.

The positioning-related physiologic consequences of obesity have previously been described in the literature. With the use of invasive cardiac

catheterization, Linicus *et al.*<sup>3</sup> demonstrated that there was a correlation between BMI and increased pressure gradients between thoracic and abdominal vena cava pressures in a cohort of 29 obese patients with a BMI above 30 who were laid in the supine position. Complications that may arise from inferior vena cava compression include thrombus formation,



**Figure 6** (A) Transthoracic echocardiogram image showing the parasternal short axis view of the 26 mm Edwards SAPIEN 3 ultra bioprosthetic aortic valve in-situ. (B) Transthoracic echocardiogram post-transcatheter aortic valve insertion aortic valve pressure gradients.

lower extremity oedema, hypotension, haemodynamic collapse, and cardiac arrest.<sup>4</sup> Chen et al.<sup>5</sup> reported a similar case in a 35-year-old pregnant female patient who presented for an elective caesarean section on a background of sub-valvular AS became markedly hypotensive when laid supine, resulting in cardiac arrest.

AS is the most prevalent valvular lesion in developed countries.<sup>6</sup> Since the advent of the TAVI procedure, there has been a huge paradigm shift within the management of AS over the past two decades, with a lifesaving intervention potentially being offered to patients in whom their comorbidities would present a prohibitive interventional risk for SAVR.<sup>7</sup> Multiple randomized controlled trials have validated efficacy and safety of TAVI procedure across the spectrum of surgical risk.<sup>8–10</sup> The early landmark trials demonstrating efficacy of TAVI, excluded patients with congenital bicuspid valves; however, there are multiple registries that have shown that TAVI can be utilized efficaciously in patients with bicuspid aortic valve, particularly in those with excessive surgical risk, where anatomic features are favourable.<sup>8–11</sup>

Given the age of the patient, and limited data available on the long-term durability of TAVI, future treatment interventions should be anticipated. Equally, a reduced life expectancy due to combined co-morbidities is also likely. A TAVI-in-TAVI or valve-in-valve implantation has been performed with positive clinical outcomes and may be a valid therapeutic option.<sup>12</sup> Overall, surgical intervention, if feasible, may be a preferable choice. Weight loss strategies were therefore strongly advocated as a reduction in BMI may permit future consideration of SAVR.

## Lead author biography



Alexander Sellers, MB BCH, BAO, MSc, is an Irish graduate of University College Dublin. He is a final year Basic Physician Trainee at the Royal Adelaide Hospital, Adelaide, South Australia. Upon completion of his Adult Internal Medicine residency, he will commence Advanced Training in cardiology at Flinders Medical Centre in Adelaide. He holds a Master of Science in Internal Medicine awarded with distinction by the University of Edinburgh and is an Associate Clinical Lecturer at the University of Adelaide.

## Supplementary material

Supplementary material is available at *European Heart Journal – Case Reports*.

## Acknowledgements

The authors wish to thank Kaylene Gluyas and Emilie Rasheed of Cardiac Ultrasound Department at Flinders Medical Centre for providing the TTE images used in the report and Dr Jean Engela from the Division of Medical Imaging at Flinders Medical Centre for providing the CTCA and CT TAVI images.

**Slide sets:** A fully edited slide set detailing this case and suitable for local presentation is available online as [Supplementary data](#).

**Consent:** The authors confirm that written consent has been obtained from the patient for the submission and publication of this report including images, in line with the COPE guidelines.

**Conflict of interest:** Ajay Sinhal is a proctor and advisory board member for Edwards Lifesciences. Jayme Bennetts is a proctor and advisory board member for Edwards Lifesciences.

**Funding:** None declared.

## Data availability

All available data is presented with the manuscript.

## References

1. Blüher M. Obesity: global epidemiology and pathogenesis. *Nat Rev Endocrinol* 2019;**15**:288–298.
2. Howard BK, Goodson JH, Mengert WF. Supine hypotensive syndrome in late pregnancy. *Obstet Gynecol* 1953;**1**:371–377.
3. Linicus Y, Kindermann I, Cremers B, Maack C, Schirmer S, Böhm M. Vena cava compression syndrome in patients with obesity presenting with edema and thrombosis. *Obesity (Silver Spring)* 2016;**24**:1648–1652.
4. Lawrensia S, Khan YS. Inferior vena cava syndrome [updated 2021 Aug 23]. In: *StatPearls [Internet]*. Treasure Island (FL): StatPearls Publishing; 2021. Available from: <https://www.ncbi.nlm.nih.gov/books/NBK560885/>
5. Chen S, Wu L, Jiang X. Aortocaval compression resulting in sudden loss of consciousness and severe bradycardia and hypotension during caesarean section in a patient with subvalvular aortic stenosis. *BMC Anesthesiol* 2019;**19**:116.
6. Nkomo VT, Gardin JM, Skelton TN, Gottdiener JS, Scott CG, Enrique-Sarano M. Burden of valvular heart diseases: a population-based study. *Lancet* 2006;**368**:1005–1011.

7. Liu Z, Kidney E, Bem D, Bramley G, Bayliss S, De Belder MA, et al. Transcatheter aortic valve implantation for aortic stenosis in high surgical risk patients: a systematic review and meta-analysis. *PLoS One* 2018;**13**:e0196877.
8. Smith CR, Leon MB, Mack MJ, Miller DC, Moses JW, Svensson LG, Tuzcu EM, Webb JG, Fontana GP, Makkar RR, Williams M, Dewey T, Kapadia S, Babaliaros V, Thourani VH, Corso P, Pichard AD, Bavaria JE, Herrmann HC, Akin JJ, Anderson WN, Wang D, Pocock SJ, PARTNER Trial Investigators. Transcatheter versus surgical aortic-valve replacement in high-risk patients. *N Engl J Med* 2011;**364**:2187–2198.
9. Leon MB, Smith CR, Mack MJ, Makkar RR, Svensson LG, Kodali SK, Thourani VH, Tuzcu EM, Miller DC, Herrmann HC, Doshi D, Cohen DJ, Pichard AD, Kapadia S, Dewey T, Babaliaros V, Szeto WY, Williams MR, Kereiakes D, Zajarias A, Greason KL, Whisenant BK, Hodson RW, Moses JW, Trento A, Brown DL, Fearon WF, Pibarot P, Hahn RT, Jaber WA, Anderson WN, Alu MC, Webb JG, PARTNER 2 Investigators. Transcatheter or surgical aortic-valve replacement in intermediate-risk patients. *N Engl J Med* 2016;**374**:1609–1620.
10. Mack MJ, Leon MB, Thourani VH, Makkar R, Kodali SK, Russo M, Kapadia SR, Malaisrie SC, Cohen DJ, Pibarot P, Leipsic J, Hahn RT, Blanke P, Williams MR, McCabe JM, Brown DL, Babaliaros V, Goldman S, Szeto WY, Genereux P, Pershad A, Pocock SJ, Alu MC, Webb JG, Smith CR, PARTNER 3 Investigators. Transcatheter aortic-valve replacement with a balloon-expandable valve in low-risk patients. *N Engl J Med* 2019;**380**:1695–1705.
11. Halim SA, Edwards FH, Dai D, Li Z, Mack MJ, Holmes DR, Tuzcu EM, Thourani VH, Harrison JK, Brennan JM. Outcomes of transcatheter aortic valve replacement in patients with bicuspid aortic valve disease. *Circulation* 2020;**141**:1071–1079.
12. Vrachatis DA, Vavuranakis M, Tsoukala S, Giotaki S, Papaioannou TG, Siasos G, Deftereos G, Giannopoulos G, Raisakis K, Tousoulis D, Deftereos S, Vavuranakis M. TAVI: valve in valve. A new field for structuralists? Literature review. *Hellenic J Cardiol* 2020;**61**:148–153.