

Ex vivo ultrasonographic and histological morphometry of small intestinal wall layers in horses

Alessia Diana  | Francesca Freccero | Fiorella Giancola | Nikolina Linta | Marco Pietra | Valeria Luca | Giulia Salamanca | Mario Cipone | Roberto Chiochetti

Department of Veterinary Medical Sciences,
University of Bologna, Ozzano Emilia, Italy

Correspondence

Francesca Freccero, Department of Veterinary
Medical Science, University of Bologna, Alma
Mater Studiorum, Via Tolara di Sopra 50, I-
40064 Ozzano Emilia, Bologna, Italy.
Email: francesca.freccero2@unibo.it

Previous presentation or publication disclosure: The authors have no relative presentations or publications to declare.

Equator network disclosure: An EQUATOR network checklist was not used.

[Correction added on 14 May 2022, after first online publication: CRUI funding statement has been added.]

Abstract

Ultrasonographic morphometry of wall layers is commonly used in veterinary patients with suspected small intestinal disease, however published studies comparing this method with histopathology in horses are limited. This prospective, methods comparison study compared the qualitative and quantitative characteristics of small intestinal wall layers using ex vivo high-frequency ultrasound versus histopathology in a sample of 16 horses. Transverse section images of duodenum, distal jejunum, and ileum were acquired with a high-frequency linear transducer (7–15 MHz). Transverse histological cryosections were obtained at the same level. Appearance and measurements of the intestinal wall layers were assessed on the ultrasonographic and histological images. High-frequency scanning with the probe in close contact with the serosal surface of the equine intestinal wall allowed a clear and detailed definition of wall layers. A hyper-echoic line was consistently detected within the *tunica muscularis* in all the intestinal tracts, corresponding histologically to the interface between its longitudinal and circular muscle layers. The overall trend of the values for wall layers thickness was comparable between ex vivo ultrasonography and histology. However, a poor agreement was found between the two methods for all layers. The ultrasonographic measurements were thicker compared to histological measurements, with the exception of the total wall and the muscular layer thicknesses. These layers were thinner on ultrasonography in the duodenum and in all the intestinal segments, respectively. Findings from the current study can be used as background for future ultrasonographic investigations of small intestinal diseases in horses.

KEYWORDS

bowel, equine, gastroenterology, sonogram

Abbreviations: CML, circular muscular layer; GI, gastrointestinal; LML, longitudinal muscular layer; US, ultrasonography

This is an open access article under the terms of the [Creative Commons Attribution-NonCommercial-NoDerivs](https://creativecommons.org/licenses/by-nc-nd/4.0/) License, which permits use and distribution in any medium, provided the original work is properly cited, the use is non-commercial and no modifications or adaptations are made.

© 2022 The Authors. *Veterinary Radiology & Ultrasound* published by Wiley Periodicals LLC on behalf of American College of Veterinary Radiology.

1 | INTRODUCTION

Ultrasonography (US) is one of the most commonly used non-invasive diagnostic tools in equine practice^{1,2} and can be particularly useful for the diagnosis of gastrointestinal disease. In fact, this technique allows the evaluation of intestinal diameter, wall thickness and layering, luminal contents, and motility.² These parameters can be altered during intestinal diseases.^{1,3} Intestinal wall thickness may increase in the setting of different inflammatory/infiltrative bowel diseases, strangulating intestinal lesions, or edema.^{1,2,4} On the other hand, the pathological thinning of the intestinal wall has not received specific consideration in horses so far. The normal US appearance and reference ranges of the overall intestinal wall thickness in the different GI tracts have been widely reported in horses.^{1,5} Based on previous publications in small animals,^{6,7} the equine ultrasonographic intestinal layers were assumed to correlate well with the histological layers (mucosa, submucosa, muscularis, and serosa), but few research have been performed on *ex vivo* equine intestine.^{8–10} More recently, only one study describes the ultrasonographic thickness of each small intestinal wall layer of the equine and its good correlation with histological measurements of any segment, except for the ileum.⁸ Furthermore, *ex vivo* ultrasonographic evaluation of the equine bowel allows a more detailed appearance of the wall layering compared with transabdominal ultrasonography providing a reference for clinical application of US in horses with gastrointestinal diseases.⁸ However, different settings (e.g., geographical areas, sample population), operative and technical factors (e.g., operators, ultrasound machines and technique, sample processing) might affect the diagnostic accuracy of US in discriminating intestinal wall layering and its alterations, as well as correlation with histology. Notably, it is also unknown how the sampling of different tracts of the long small intestine, in particular the jejunum, might affect US morphometric findings. With these considerations, care must be taken in generalizing or comparing findings among populations and studies.

This study aimed to assess wall layering and thickness of the different small intestinal segments by *ex vivo* high-resolution US, and to evaluate the agreement between ultrasonographic and histologic measurements of the individual layers and overall small intestinal wall in a sample of healthy horses. We hypothesized that wall thickness measurements obtained by this method at the different intestinal levels would agree with wall layering morphometry determined by histology as a reference method.

2 | MATERIALS AND METHODS

2.1 | Experimental design and sample collection procedures

The study was a prospective, methods comparison design. Twenty-three horses (14 males and 9 females), of various breeds, aged 1.5–24 years were initially recruited from a local abattoir (Emilia Romagna region, Italy) during the period of March–April 2019. No ethical

approval was required as all the horses were presented to the abattoir for reasons unrelated to the study. Horses were deemed free of gastrointestinal disease and included in the study on the basis of the veterinary inspection report at the abattoir, normal CBC and serum biochemistry, and absence of gross, ultrasonographic, and histological lesions at the different sections of the small intestine. Collected samples that did not fulfill all the inclusion criteria were excluded from the analysis.

Blood and tissue collections were performed by the veterinary personnel responsible for animals and meat inspection at the abattoir and by an equine internal medicine specialist (FF). Jugular blood samples were taken at the time of exsanguination and kept refrigerated till analysis (within 2 h). A complete blood count (CBC; Advia 2120, Siemens Healthcare Diagnostics, Tarrytown NY, USA) and routine serum biochemistry (U400, Olympus/BeckmanCoulter, Brea CA, USA) were performed. Two segments of the gastrointestinal tract were resected from each animal immediately (no longer than 30 min) after slaughtering. The first intestinal segment included the pyloric portion of the stomach to the junction between the duodenum and jejunum and the second the caudal portion of the jejunum to the ileocecal junction (ICJ), including the base of the cecum. The small intestinal samples consisted of 25 cm in length segments harvested from the descending duodenum (40 cm far from the pyloric sphincter), caudal jejunum (150 cm far from the ICJ), and ileum (20 cm far from the ICJ). The samples were immediately wrapped in moist towels and plastic for transport, hence ultrasound exam and processing were performed within two hours. The samples were coded and randomized for blinded ultrasonographic and histological evaluations.

2.2 | Ultrasonographic and histological image acquisition procedures

Each sample was washed with phosphate-buffered saline (PBS) (0.15 M sodium chloride [Merck KGaA, Darmstadt, Germany] in 0.01 M sodium phosphate buffer [sodium phosphate dibasic dihydrate and sodium phosphate monobasic monohydrate, Merck KGaA], pH 7.2) to remove any intraluminal content, then was placed in a PBS bath for the ultrasonographic examination. The extremities of the intestinal tract were occluded by two Klemmer forceps (Angelo Franceschini S.R.L., Bologna, Italy) and PBS was injected with a 50 ml syringe with the aim to gently distend the intestinal tract. An assistant held the sample by means of the forceps, taking care not to apply any traction or distortion on it. The intestinal sample was scanned while fully submerged in the PBS bath.

All ultrasound examinations were conducted by the same sonographer (AD), a veterinarian with more than 15 years of experience using a real-time ultrasound machine (Philips® IU22, Ultrasound System, Philips Healthcare, Monza, Italy) equipped with a high-frequency (7–15 MHz) linear transducer (L15-7io). The footprint of the transducer was placed in the same position for each sample, within the PBS bath, approximately 0.5 cm from the outer part of the intestinal sample, and was not in direct contact with the intestinal surface, to avoid applying pressure on the sample. All the intestinal samples were scanned on

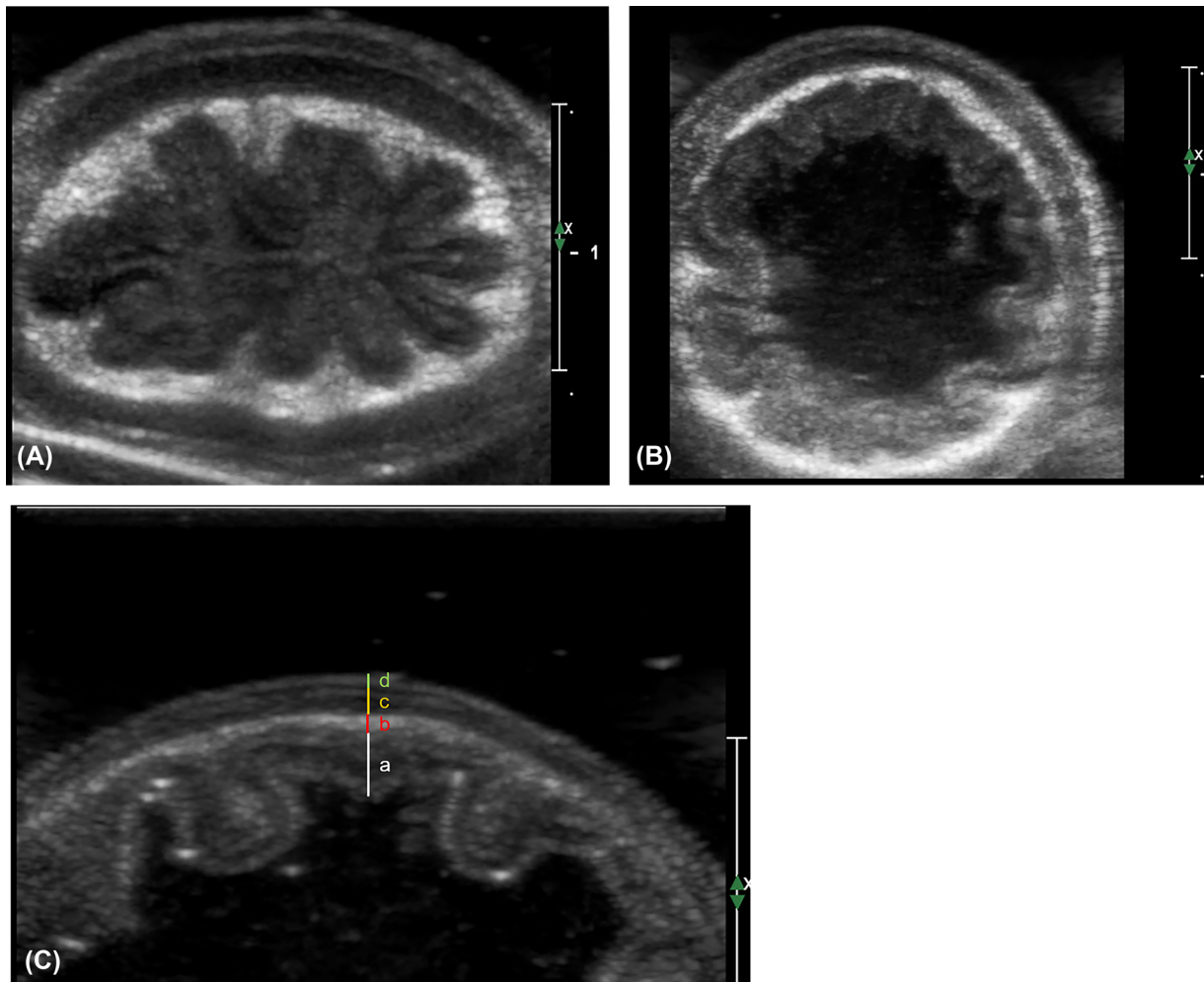


FIGURE 1 (A and B) Transverse ultrasonographic images of an ex vivo distal jejunal loop of a mixed breed horse acquired with a high-frequency linear transducer (7–15 MHz). (A) The loop is empty and the folds are prominent. (B) The loop was filled using a phosphate-buffered saline (PBS) to obtain a moderate distension of the intestinal lumen. (C) Close up of a transverse ultrasonographic image of an ex vivo phosphate-buffered saline-filled duodenal loop of the same horse depicting the intestinal wall layering. White line (a): mucosal layer; red line (b): submucosal layer; orange line (c): muscular layer; green line (d) serosal layer [Color figure can be viewed at wileyonlinelibrary.com]

transverse sections approximately in the middle of each sample (Figure 1A,B). The US focus was set at the level of the intestinal lumen and the same ultrasonographic parameters were used for all samples. Altered small intestinal US appearance was judged based on abnormal echogenicity of each wall layer as previously reported.^{2–3,6,8} An indelible marker (Marker pen, Phoenix Contact, Cusano Milanino, Italy) was used to mark the site where the transverse images were obtained as a guide for the histological transverse sections. Still frame images were obtained for each intestinal segment both empty and distended and recorded in DICOM format.

After ultrasonography, intestinal specimens were prepared by a veterinary anatomic specialist (R.C.) as follows. The same segment of duodenum, jejunum, and ileum was longitudinally cut open along the mesenteric border, gently distended, and pinned with brass pins on balsa wood and immersed in the fixative (2% paraformaldehyde containing 0.2% picric acid in 0.1 M sodium phosphate buffer, pH 7.0) at 4°C for 48 h. After rinsing in PBS, the tissues were stored in PBS

containing 30% sucrose and 0.1% sodium azide (pH 7.4) at +4°C. Pieces of tissues (2 cm × 1 cm) were subsequently cut, transferred to a mixture of PBS-sucrose-azide and Optimal Cutting Temperature (OCT) compound (Tissue Tek®, Sakura Finetek Europe, Alphen aan den Rijn, the Netherlands) at a ratio of 1:1 (overnight) and then embedded in 100% OCT. The tissues were mounted in OCT (Tissue Tek®) mounting medium, frozen in isopentane cooled in liquid nitrogen, and sectioned at 14–16 μm on a cryostat. The sections were collected on gelatin-coated slides. Cryosections were washed in PBS and processed for staining. To identify the different layers of the intestinal wall, we performed 20 min of incubation in a humid chamber with green fluorescent Nissl stain solution (NeuroTrace®, 1:200, 500/525, code N21480, Thermo Fisher Scientific, Waltham, MA USA 02451). This marker labels the cytoplasm and the nucleoli of the neurons and the nuclei of other cells including smooth muscle cells. The cryosections were then washed in PBS (3 × 10 min) and mounted in buffered glycerol at pH 8.6.

2.3 | Evaluation and measurements of ultrasonographic images

The DICOM images were transferred to a computer workstation (Imac, macOS Monterey version 12.0.1, Cupertino CA). Open-source image analysis software (OsiriX Imaging, Trillium Technology, Ann Arbor, MI) was used for subsequent image analyses. The images were displayed on a calibrated, 2-megapixel high-brightness monitor (Eizo RX240; Cusano). All images were assessed by the same investigator who had previously acquired the sonographic images (AD), without knowledge of histological measurements. In all images, the overall ultrasonographic wall layering was subjectively assessed along with measurements of the total wall and layer thicknesses.

Electronic calipers were placed at the outside edge of each individual intestinal layer and leading edge-to-leading edge measurements were made from the serosal interface to the luminal interface of the mucosa (Figure 1C). Three consecutive measurements of mucosal, submucosal, muscularis, serosal, and total intestinal wall thickness between the intestinal folds were obtained from the images of PBS-filled duodenum, jejunum, and ileum. Repeated measurements of the individual layers and of the total intestinal wall were subsequently averaged.

2.4 | Evaluation and measurements of histological images

Preparations were examined using fluorescence microscopy by the veterinary anatomic specialist (R.C.), who was unaware of ultrasonographic measurements. A fluorescent microscope (Nikon Eclipse Ni; Nikon Instruments Europe BV, Amsterdam, Netherlands) equipped with the appropriate filter cubes was used. The images were recorded with a digital camera (Nikon DS-Qi1Nc and Nikon NIS Elements software BR 4.20.01). To obtain large images, single fields were scanned automatically by using a motorized XY stage with auto-focus capability and then stitched by the software. Slight adjustments to contrast and brightness were made using and the figure panels were prepared using a software program for editing vector graphics (CorelDRAW, graphic suite SE 2021, Ottawa, ON, Canada).

Morphometric measurements of the intestinal layers were performed on histological images by using the digital camera's software (Nikon NIS Elements software BR 4.20.01). At this stage, histological diagnosis of presence or absence of intestinal pathology was reached for inclusion of the sample and following measurements. Each layer (mucosa, submucosa, *tunica muscularis* [circular muscle layer, CML, and longitudinal muscle layer, LML], and serosa) was measured at different points considering the variability of its thickness. For each intestinal segment and for each individual layer and total wall thickness, three measurements were taken, namely at the two ends and at the center of the considered field, and averaged (Figure 2).

2.5 | Statistical analysis

Only samples matching all inclusion criteria underwent the subsequent analysis, and measurements by the two methods were paired. Statistical tests were performed by an observer with 20 years of expertise in statistics using a commercial software (MedCalc Statistical Software version 12.2.10, MedCalc Software Ltd, Ostend, Belgium <https://www.medcalc.org/features/statistics.php>). Data distribution was assessed by a D'Agostino-Pearson's test. Data were analyzed using descriptive statistics and expressed as mean \pm standard deviation or median and range (minimum–maximum) as appropriate. The relative thickness of each individual intestinal layer was expressed as an absolute measure and a percentage of the total wall thickness in all the intestinal segments, for both US and histology. The comparison of the ultrasonographic measurements of the intestinal total thickness and of each intestinal layer among the different intestinal segments was carried out using ANOVA for repeated measures with post hoc Bonferroni tests or Friedman's test with post hoc Dunn's test for normally or not normally distributed data, respectively. The agreement between the ultrasonographic and histological measurement of the total intestinal thickness and the different intestinal layers was assessed using the Bland Altman test. Concordance Correlation Coefficient (ρ_c) were performed and values of ρ_c were interpreted according to McBride (2005)¹¹ descriptive scale of the strength of agreement ($\rho_c < 0.90$: poor; 0.90 to 0.95: moderate; 0.95 to 0.99: substantial; > 0.99 almost perfect). For all statistical analyses, a value of $P < 0.05$ was considered significant.

3 | RESULTS

The study included 16 (9 males and 7 females) of 23 horses recruited at the abattoir. Horses represented various breeds including six Polish, seven mixed-breed, two French, and one Draft Horse. Horses' age ranged from 1.5 to 22 years (mean 9.3 ± 8.6) with a bodyweight ranging from 300 to 600 kg. A total of 43 intestinal samples (14 duodenum, 14 jejunum, and 15 ileum) were included in the analysis.

3.1 | Subjective evaluation of ultrasonographic and histological images

Ultrasonographic evaluation showed a typical layering of the intestinal wall, in which five layers were easily identified from outside to inside in both the empty and distended intestine: serosa (hyperechoic), muscularis (hypoechoic), submucosa (hyperechoic), mucosa (hypoechoic), and mucosal surface (hyperechoic) (Figure 1). Furthermore, all intestinal samples showed an additional hyperechoic thin line parallel to the submucosa and serosa, in the outer aspect of the ultrasonographic muscular layer (Figure 3A). On histology, no morphological abnormalities and the characteristic layered stratigraphy were found in all the samples.

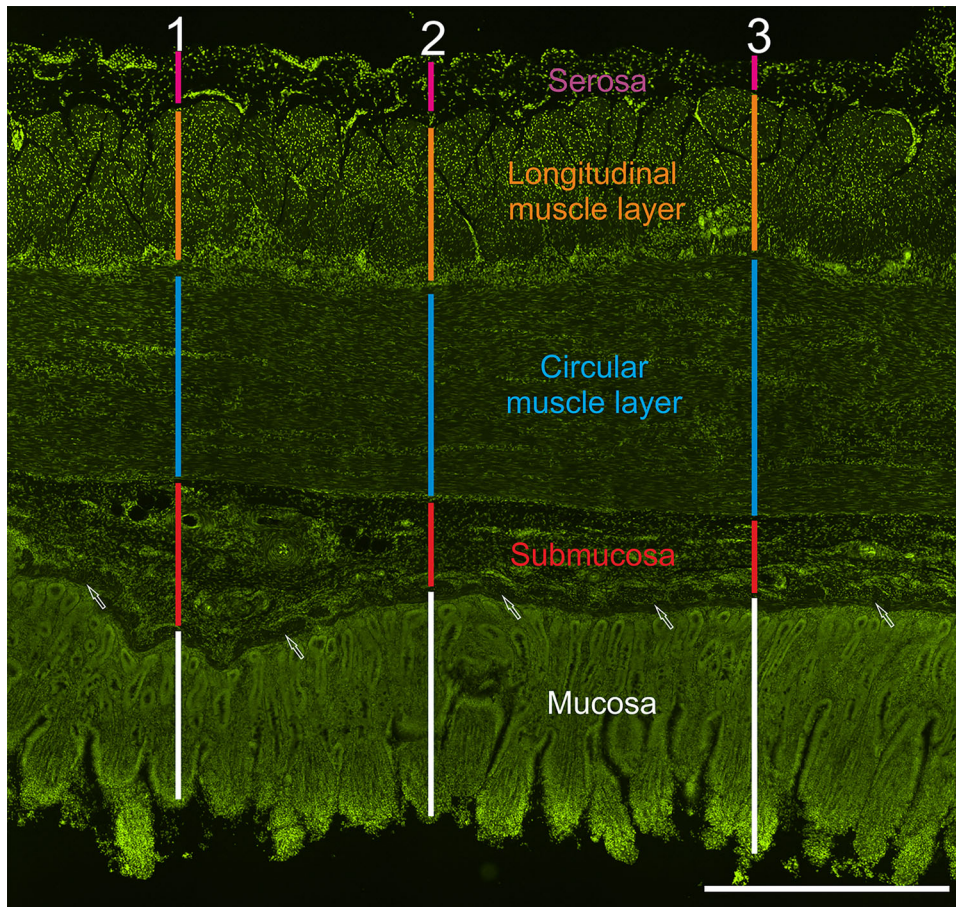


FIGURE 2 Photomicrograph of a transverse cryosection of a segment of distal jejunum of a mixed breed horse showing three repeated measurements of each wall layer. The white arrows indicate the *muscularis mucosae*. Bar: 1000 μm [Color figure can be viewed at wileyonlinelibrary.com]

The additional ultrasonographic line was consistent with fibrous tissue in the myenteric plexus present between the inner circular and outer longitudinal components of the *tunica muscularis*. In the space between the CML and LML, in addition to the connective tissue, there are the neuronal and the glial cells of the myenteric plexus and a rich network of intrinsic and extrinsic nerve fibers (Figure 3B). On the inner side, intraluminal folds involving the mucosa and submucosa were ultrasonographically evident in all the sections of the small intestinal segments. This folding was particularly prominent at the ileum.

In the outer part of the *tunica mucosa*, only histology displayed a further layer corresponding to the *muscularis mucosae*, which was composed itself by a longitudinal outer layer and an inner circular layer (Figure 4A–C). In three duodenal and two ileal samples, the *tunica mucosa* appeared poorly defined, without a clear-cut distinction from the underlying *tela submucosa*. At duodenal level, most of the submucosa was occupied by Brunner's glands, which were also visible in the jejunum, where however they were organized in small glandular clusters. In the ileum of younger (<3 years old) subjects, the presence of large aggregates of lymphatic nodules (Peyer's patches) extending

in both layers, caused the discontinuity of the *muscularis mucosae* (Figure 4A–C).

3.2 | Ultrasonographic and histological measurements and agreement

Results of the ultrasonographic and histological measurements of the total wall thickness and individual wall layers in the different intestinal segments as well as of comparisons of the US measurements between the different segments are reported in Table 1. The relative contribution (%) of each individual wall layer to the total wall thickness was consistent between US and histology and among the three intestinal segments, and was represented in such decreasing order: muscularis, mucosa, submucosa, and serosa (Table 2).

A significant difference was found in the ultrasonographic measurement of the total intestinal wall and that of the serosa, submucosal, and muscular layer in the three different segments (overall $P < 0.001$, $P = 0.019$, $P = 0.003$, and $P < 0.001$, respectively), whereas no difference was found for the mucosa ($P = 0.305$; Figure 5). In particular, the

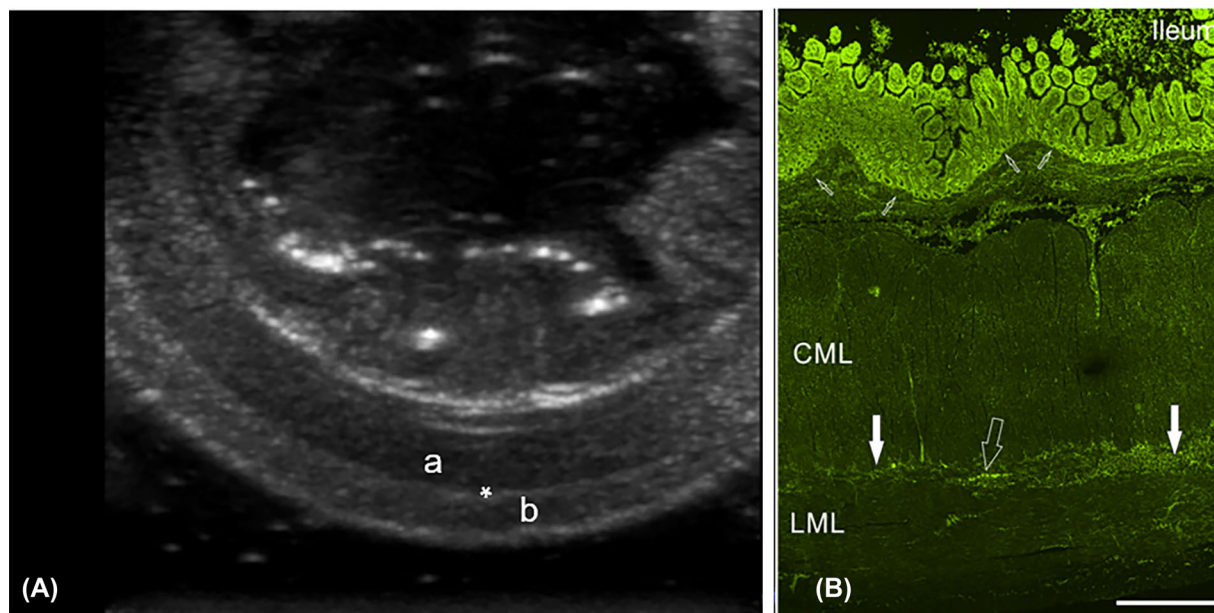


FIGURE 3 (A) Close up of a transverse ultrasonographic images of an ex vivo ileal loop of a mixed breed horse acquired with a high-frequency linear transducer (7–15 MHz). A hyperechoic line (*) is visible at the interface between the internal circular (a) and the external longitudinal (b) muscle layers. (B) Micrographs showing cryosections of the ileum labeled with NeuroTrace. The white arrows indicate the space between the longitudinal muscle layer (LML) and circular muscle layer (CML), occupied by nerve fibers and connective tissue. The empty arrows indicate myenteric plexus neurons. The small white arrows indicate the *muscularis mucosae*. Bars: 1000 μm [Color figure can be viewed at wileyonlinelibrary.com]

TABLE 1 Ultrasonographic and histological measurements of duodenal, distal jejunal, and ileal total wall and layers thickness in ex vivo samples from 16 horses without gastrointestinal disease. Normal and not normally distributed data are presented as mean \pm standard deviation (SD) or median and range (minimum-maximum), respectively

	Duodenum		Jejunum		Ileum	
	US (μm)	Histo (μm)	US (μm)	Histo (μm)	US (μm)	Histo (μm)
Wall	3632 (3080-5673)	3830 \pm 758	3988 (3133-5717)	3774 \pm 586	6264 \pm 955	5667 \pm 1098
Mucosa	1328 \pm 363	777 \pm 152	1298 \pm 229	772 \pm 160	1452 \pm 275	848 \pm 156
Submucosa	740 (590-1160)	717 (513-2184)	821 \pm 117	497 (278-1804)	946 \pm 126	602 \pm 286
Muscularis	1320 (917-2857)	1909 \pm 519	1565 \pm 431	2118 \pm 435	3512 \pm 817	4500 \pm 1037
Serosa	294 \pm 49	237 \pm 84	335 \pm 78	294 \pm 79	354 \pm 57	212 \pm 58

TABLE 2 Relative ultrasonographic and histological thickness of each individual layer expressed as a percentage of the total wall thickness in ex vivo small intestinal samples from 16 horses without gastrointestinal disease

	Duodenum		Jejunum		Ileum	
	US %	Histo %	US %	Histo %	US %	Histo %
Mucosa	34.8	23.7	32.4	20.5	23.2	15.0
Submucosa	20.2	20.3	20.4	16.6	15.1	10.6
Muscularis	37.3	49.8	38.9	56.1	56.1	70.7
Serosa	7.7	6.2	8.3	7.8	5.6	3.7

total wall thickness of the ileum was higher compared to that of the duodenum and jejunum ($P < 0.01$ for both comparisons). Furthermore, the serosal and submucosal layers of the ileum were higher compared to that of the duodenum ($P < 0.05$ and $P < 0.01$, respectively), and the ileum muscular layer was higher compared to that of the duodenum and jejunum ($P < 0.001$ and $P < 0.01$, respectively).

The agreement between ultrasonography and histology was poor for all the measurements of both the total intestinal wall and each layer thickness in the three intestinal segments (Supporting Information 1). In particular, the ultrasonographic measurements were all thicker compared to the histological ones, with the exception of the total wall and

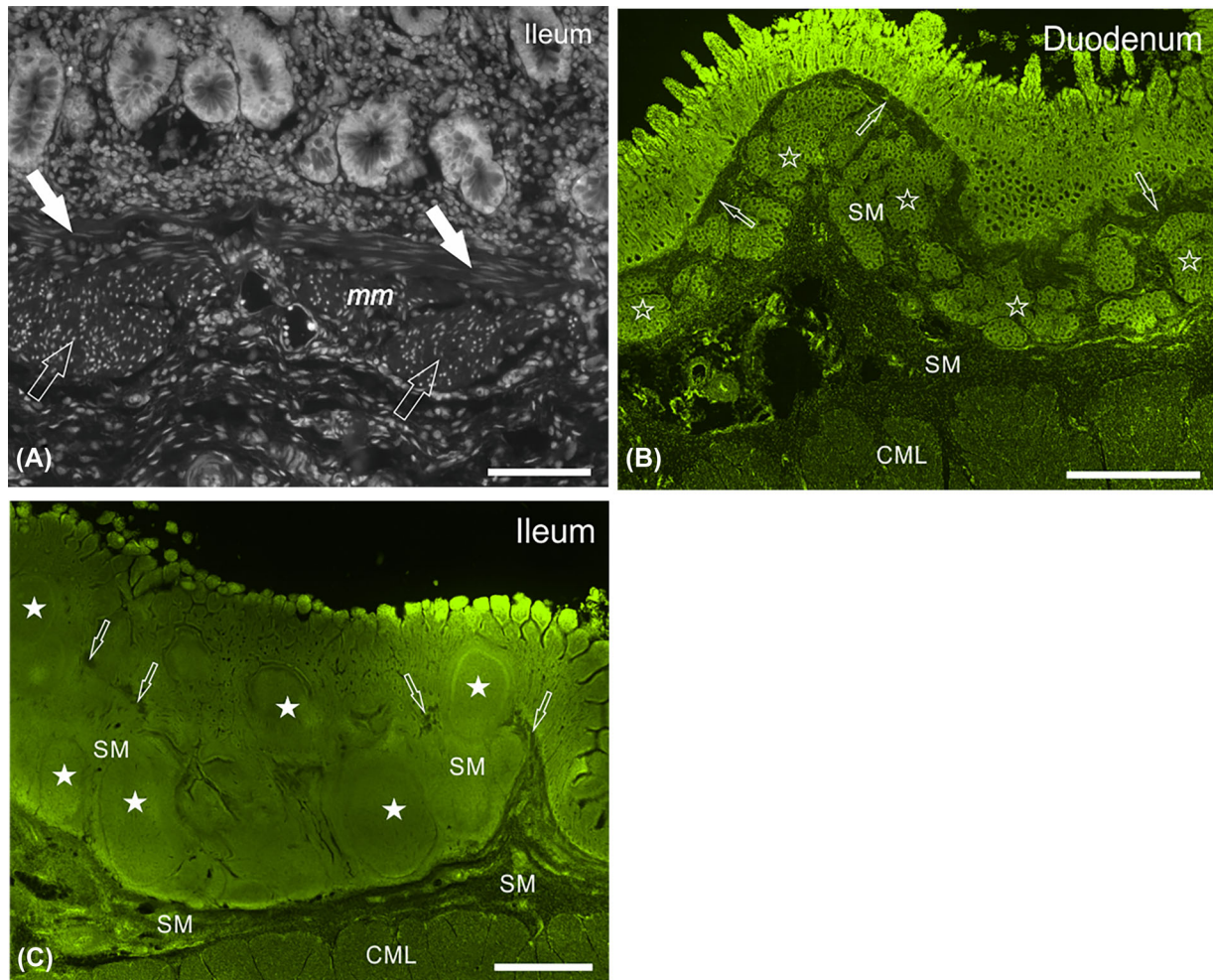


FIGURE 4 (A) Micrograph showing the organization of the *muscularis mucosae* (*mm*) observed in transverse cryosection of the horse ileum. White arrows indicate the inner circular layer of the *mm*, whereas the empty arrows indicate its outer longitudinal layer. (B, C) Micrographs showing the distribution of the Brunner's glands (empty stars) in the submucosa (SM) of the duodenum (B) and the organization of the lymphatic nodules of the Peyer's patches (stars) in the SM and mucosa of the ileum (C). CML, circular muscular layer. Arrows indicate portions of the discontinued *muscularis mucosae*. Bars: A, 100 μm ; B and C, 1000 μm [Color figure can be viewed at wileyonlinelibrary.com]

the muscular layer, which was thinner on US in the duodenum and in all the intestinal segments respectively. In the Bland–Altman analysis, these resulted in all negative mean differences between methods for the muscular layer. The mean difference was positive for the remaining layers in the jejunum and ileum, whereas a negative mean difference was found for the total wall and submucosal layer in the duodenum (Supporting Information 2).

4 | DISCUSSION

The intention of the current study was to compare *ex vivo* ultrasonographic and histologic characteristics of small intestine layers in a sample of clinically normal horses. The *ex vivo* ultrasonographic appearance of the five wall layers (serosa, muscularis, submucosa, mucosa, and mucosal surface) of the equine small intestine in the

current study was consistent with findings from previously published descriptions.^{3–4,9,12} In those previous studies, transducer frequencies ranging from 2.5 MHz to 7.5 MHz were employed. The use of a high-frequency transducer allowed to achieve a higher resolution of the wall layering. In particular, a further thin hyperechoic line within the muscular layer, representing the interface between the inner and outer parts of the *tunica muscularis*, was observed along all the equine small intestine as also described in humans^{13–15} and dogs.⁵ Worth¹⁰ already described this line by *ex vivo* US in the wall of the ileum, while more recently it was found also in the other small and large intestinal tracts, albeit not consistently, by means of a high-frequency transducer.⁸ Histologically, such additional ultrasonographic line was consistent with connective and nerve tissues of the myenteric plexus and intrinsic and extrinsic nerve fibers, interposed between the LML and CML of the *tunica muscularis*.^{16–18} Overall, on histological assessment, our findings (i.e., *muscularis mucosae*, Peyer's patches, and myenteric plexus) agreed

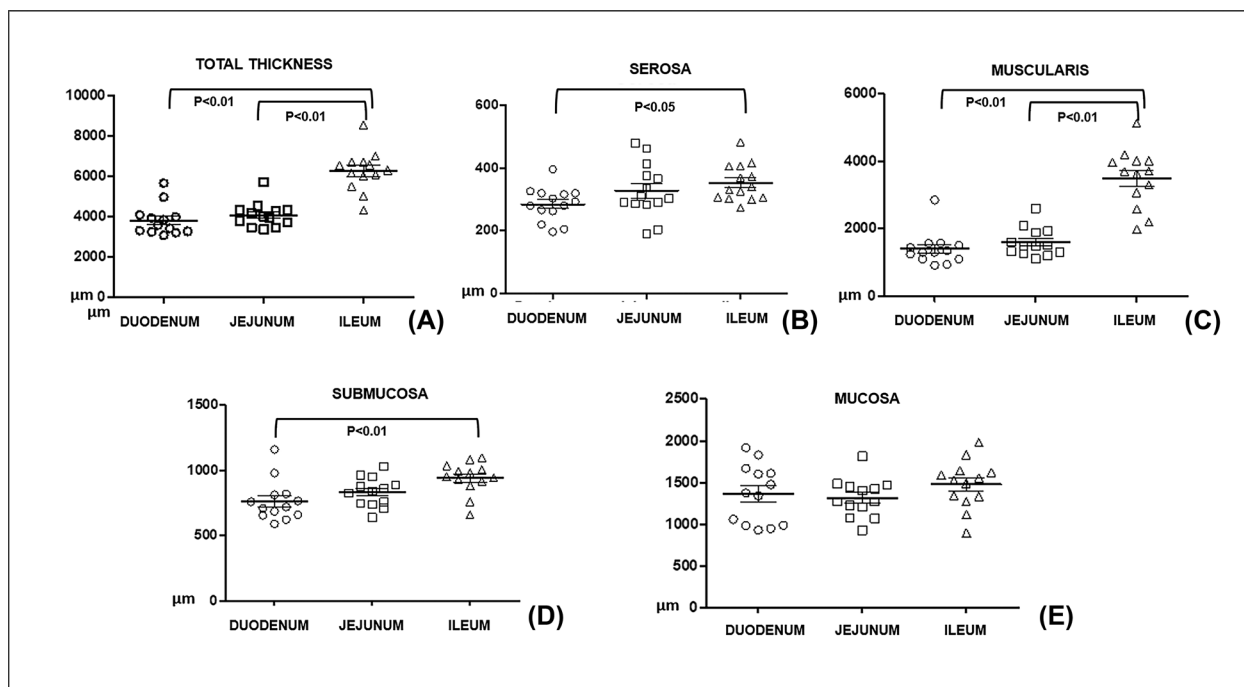


FIGURE 5 Ultrasonographic thickness (A, total wall; B, serosa; C, muscularis; D, submucosa; E, mucosa) measured from the images of PBS-filled duodenum, distal jejunum, and ileum (mean with SEM). Significant p values are reported in the image. No significant statistical differences were observed ($p = 0.305$) for the thickness of mucosa among the different intestinal tract

with morphological data of the equine small intestinal wall reported in the literature.^{19–21} Some morphologically important details were not detected on ultrasound images. In the outer part of the *tunica mucosa*, an additional layer, corresponding to the *muscularis mucosae* with its characteristic double layering, was observed. The *muscularis mucosae* is crossed by lymphatic components of the Peyer's patches in the ileum, being at times even disrupted in its continuity. This appearance was especially prominent in the younger subjects, as previously described in the literature.^{22,23} Anatomical structures such as the *muscularis mucosae*, are in the order of hundreds of micrometers thick and are unlikely to produce sonographically evident layers with a range of resolution commonly used in equine practice. However, Peyer's patches have been recently visualized in the submucosa of the distal part of the jejunum and ileum in young cats, using a US frequency of 18 MHz; an axial resolution of 0.09 mm allowed detecting such 1 mm-thick structures as characterized on histology.²⁴ In the present study, the maximal transducer frequency was lower (15 MHz) and the axial resolution was 0.1 mm.

With regard to US measurements, in the present study, the small intestinal wall thickness was at the higher limit or slightly over compared to previous reports using low to medium frequency probes.^{1,3–5,10,11,25,26} Transabdominal and transrectal US in horses encounter many anatomical and technical limitations to intestinal walls' imaging quality (e.g., size of the abdomen, distance of the viscera from the contact surface, low-frequency probes). A thinner small intestinal wall compared to the present findings has been reported scanning ex vivo intestine using a 7.5 MHz probe,⁹ and also a high fre-

quency (10–18 MHz) probe.⁸ Noteworthy, in the present study, the thicker US measurement was in line with a thicker histological measurement of the wall, compared to the findings previously reported by Freeman et al. (i.e., small intestinal total wall thickness 2.43 ± 0.25 mm)⁹ and Bevenino et al. (total wall thickness 2.08 ± 0.71 mm, 1.61 ± 0.99 mm, and 3.94 ± 1.7 mm for duodenum, jejunum, and ileum, respectively).⁸

The degree of organ distension might affect wall thickness,¹ albeit this has been reported inconsistently in other species.^{27,28} A few differences in wall layers thickness between empty and moderately distended intestine was documented.¹⁰ Similar to Bevenino et al.,⁸ in order to resemble a normal in vivo condition, where the gut wall is usually measured with some content, we measured the thickness after a moderate distension of the intestinal segments and such effect was not addressed. However, the degree of distension between studies is not standardized and may play a role in wall thickness measurements and possibly justify some discrepancy. For instance, in the present study mucosal folds were rather prominent yet after distension. Moreover, different times between euthanasia, sample collection, and US and histological image acquisition associated also with the different types of slaughter of the horses between our study and that of Bevenino et al.⁸ could have influenced the hydration of the intestinal sample and consequently the thickness of the wall.

Comparing US measurements of the different intestinal segments, the overall wall thickness of the ileum resulted thicker than the more proximal ones. There are no in vivo US reference ranges specifically referred to the ileum for direct comparison, likely reflecting that it is

limitedly accessible for measurement *in vivo*. However, our finding was in line with a previous *ex vivo* study⁹ and with the recent study by Bevevino et al.⁸

Along with the above-mentioned technical factors, sampling at the level of the distal jejunum versus more proximal jejunal sites is most likely key in justifying the relatively higher wall thickness of the jejunum compared to duodenum recorded in the current study but not by Bevevino et al.⁸ This is mainly reflected by a thicker muscular layer present at a distal level, gradually nearing to resemble the wall stratigraphy of the ileum. This is particularly evident in histology (Supporting Information 3), and also renders reason for the less usual US appearance of the jejunum showed in the current study (Figure 1). While the clinical relevance of this difference is undefined, we should be aware that such differences in jejunal wall morphometry and appearance could be encountered during a US assessment of the small intestine, especially in optimal conditions. Thickness ranges for the individual wall layers were recently provided at the level of duodenum, jejunum, and ileum by high-frequency US.⁸ In the present study, among the different segments, the US muscular layer of the ileum was significantly thicker than in the other tracts; despite a distinction being visible, the two muscular layers could not be separately measured with accuracy. The same finding was reported only at the level of the distal ileum in dogs and cats.^{7,29} Differently, Worth¹⁰ did not report a prominence of this layer with respect to the others in the distended viscus. Consistently, the *tunica muscularis* was the most developed in the ileum by histology. This is consistent with the functional specialization of this trait in overcoming the resistance of the ileocecal valve and generating vigorous peristaltic movements.³⁰

In their relative contribution to the ultrasonographic wall thickness, the muscular layer was followed by the mucosal, then the submucosal, and last the serosal one, and this pattern was consistent along the different intestinal segments. On the contrary, differences in the thickness of individual layers between segments have been reported in small animals by US.^{7,29,31,32} Submucosal layer of the ileum was higher compared to that of the duodenum. The findings were mainly attributed to a major contribution of villi and Brunner's glands, and of Peyer's patches, in duodenum and ileum, respectively. Such structures were similarly represented in our samples, albeit did not affect the relative thickness between tracts. Nevertheless, in histological samples from the younger horses, the large Peyer's patches in the ileal mucosa and submucosa were occasionally themselves.

Despite the overall trend of the variables being consistent between the two methods, there was a poor agreement between US and histologic measurements for the total wall and individual layers in all the segments. In contrast to our results, a good agreement between *ex vivo* US and histologic measurements of the wall thickness and different layers of the small and large intestinal segments, except for the ileum, has been reported in horses.⁸ However, differences in the setting and methods, both operative and analytic (e.g., statistical setting) between the two studies have to be considered for the discrepancy. Overall, although we were not able to statistically support our hypothesis, the clinical relevance of the discrepancy is uncertain as morphology and trends were consistent between methods. Nevertheless, sim-

ilar to our findings, the ultrasonographic intestinal layers have been reported to not directly correspond to the histological intestinal layers in human literature.^{13,33} The lack of correlation has been predominantly attributed to three factors. First, during histological processing, tissue may lose its original size, which may be somehow layer dependent. Fixation and paraffin embedding cause a considerable retraction/shrinkage of the intestine.³⁴ In the present study, we were not able to avoid tissue retraction due to the fixation, but cryosectioning spared the tissues from further shrinkage due to paraffin embedding.

To note, the larger difference in measurements between US and histology occurred for the mucosa in all segments. In a similar study in cats, it has been previously hypothesized that, due to its composition, tissue shrinkage and protein coagulation due to alcohol-based fixatives could be more pronounced at the mucosal level.⁶ However, we employed a non-alcohol-based fixative, so it is unknown whether this could be similarly a critical factor in our study. As a second factor, echogenic bands are generated by an interface between structures of different acoustic impedance (e.g., gastrointestinal wall layers) and should not be considered to necessarily correspond to an anatomical layer.³³ Moreover, the ultrasonographic axial resolution, which is mainly limited by the spatial pulse length (SPL) of the instrument, should be considered. As a result, even though the interface between two intestinal layers may have no histological thickness, the hyperechoic interface produced between them will be at least the same thickness as the SPL.^{13,33,35}

Interestingly, all ultrasonographic measurements were thicker than the histological ones in all the intestinal segments, except for the total wall of the duodenum and the muscular layer of all segments, where the opposite occurred. The same finding was reported for the muscular layer at the level of the distal ileum in cats, being only this layer thicker by histology than by US.⁶ Martinez et al⁶ hypothesized that the thickness of the muscular layer on US is generated by the thickness of the *tunica muscularis* minus the interface between the submucosa and the *tunica muscularis* (which would be added to the submucosa instead), explaining a thinner muscularis layer by US than by histology. Thus, this process would play in favor in the case of the mucosa, submucosa, and likely the serosa, with their relative external and internal interfaces, potentially contributing to the greater ultrasonographic than histologic thickness of these layers, and to their poor agreement.

On the other hand, taking measurements on enlarged microphotograph of appropriately labeled tissue sections allowed the accurate defining of the thickness of all individual layers. For instance, NeuroTrace labeling permitted an accurate definition of the thickness of the mucosa and in particular the outer limit of the *muscularis mucosae*. Another issue that might be considered is the impossibility to reproduce the same section plane by US and histology. Furthermore, with regard to the mucosa, it is very difficult to constantly obtain a histologic section parallel to the villi, which will represent the full height of this layer. Last, while a circular section of the organ is measured by US, the section is plane on histology, employing a degree of stretching and flattening of the surface.

The study has several limitations. The study setting did not allow collecting a complete history and clinical picture of the horses; however,

in the authors' opinion the US, gross and histologic assessment of the small intestine were adequate to the study purpose. The overall sample size was limited and could not be stratified by age, body weight, breed, or management in relation to the US and histological morphometric findings. In the authors' opinion, all subjects may be considered as presenting a fully developed digestive system. This might be worth of future insights in view of a diagnostic or prognostic application. Despite our effort to minimize the time between samples collection and processing, at least 90 min were needed to complete the procedure, and some lag occurred between the first and the last sample, which could potentially contribute to variability in wall thickness. No post-mortem effect on equine small intestinal length within a few hours has been reported.³⁶ However, dehydration of the mucosa, which induced loss of turgidity, stiffness, and a thinning of intestinal villi, was reported after 40 min in rats.³⁷

In conclusion, the findings of the current study partially supported those reported in a recent publication on a similar topic.⁸ High-frequency US with the probe in direct contact with the intestinal wall provided detailed visualization of wall layering that was comparable to qualitative histological features. However, in our study, the agreement between methods for most quantitative measures of wall thickness was not statistically significant, likely due to histological preparation factors such as the degree of bowel distension and sample processing. The possibility to use high-frequency transducers equipped with small footprint in direct contact with the intestinal surface either intraoperatively (e.g. during laparotomy or laparoscopy) or transrectally represent a potential area of a future clinical application in the setting of different equine intestinal disorders.

LIST OF AUTHOR CONTRIBUTIONS

Category 1

- (a) Conception and Design: Diana, Luca, Chiocchetti
- (b) Acquisition of Data: Diana, Luca, Chiocchetti, Freccero, Linta
- (c) Analysis and Interpretation of Data: Diana, Linta, Giancola, Chiocchetti, Cipone, Salamanca, Pietra

Category 2

- (a) Drafting the Article: Freccero, Linta, Chiocchetti
- (b) Revising Article for Intellectual Content: Diana, Cipone, Giancola, Freccero, Salamanca, Luca, Chiocchetti, Pietra

Category 3

- (a) Final Approval of the Completed Article: Diana, Freccero, Giancola, Linta, Pietra, Luca, Salamanca, Cipone, Chiocchetti

Category 4

- (a) Agreement to be accountable for all aspects of the work in ensuring that questions related to the accuracy or integrity of any part of the work are appropriately investigated and resolved: Diana, Freccero, Giancola, Linta, Pietra, Luca, Salamanca, Cipone, Chiocchetti.

ACKNOWLEDGEMENT

Open Access Funding provided by Universita degli Studi di Bologna.

CONFLICT OF INTEREST

The authors declare no conflict of interest.

ORCID

Alessia Diana  <https://orcid.org/0000-0003-1709-3920>

REFERENCES

1. Bithell S, Habershon-Butcher JL, Bowen IM, Hallowell GD. Repeatability and reproducibility of transabdominal ultrasonographic intestinal wall thickness measurements in thoroughbred horses. *Vet Radiol Ultrasound*. 2010;151:647-651.
2. Cribb NC, Arroyo LG. Techniques and Accuracy of Abdominal Ultrasound in Gastrointestinal Diseases of Horses and Foals. *Vet Clin Equine*. 2018;34:25.
3. Kirberger RM, Van den Berg JS, Gottschalk RD, Guthrie AJ. Duodenal ultrasonography in the normal adult horse. *Vet Radiol Ultrasound*. 1995;36:50-56.
4. Freeman SL. Diagnostic ultrasonography of the mature equine abdomen. *Equine Vet Educ*. 2003;15:319-330.
5. Epstein K, Short D, Parente E, Reef V, Southwood L. Gastrointestinal ultrasonography in normal adult ponies. *Vet Radiol Ultrasound*. 2008;49:282-286.
6. Le Roux AB, Granger LA, Wakamatsu N, Kearney MT, Gaschen L. Ex vivo correlation of ultrasonographic small intestinal wall layering with histology in dogs. *Vet Radiol Ultrasound*. 2016;57:534-545.
7. Martinez M, Pallares FJ, Soler M, Agut A. Relationship between ultrasonographic and histopathological measurements of small intestinal wall layers in fresh cat cadavers. *Vet J*. 2018;237:1-8.
8. Bevevino KE, Edwards JF, Cohen ND, de Solis CN. Ex vivo comparison of ultrasonographic intestinal wall layering with histology in horses: a feasibility study. *Vet Radiol Ultrasound*. 2020; <https://doi.org/10.1111/vru.12946>. Dec 27
9. Freeman SL, Mason PJ, Staley C. Comparison of ultrasonographic and histologic assessment of normal and strangulating intestine in the horse. *Eur J Ultrasound*. 2001;13(Suppl): S5.
10. Worth LT. Ultrasonography of the normal equine small intestine. *Vet Radiol Ultrasound*. 1995;36:355.
11. McBride GB. A Proposal for Strength-of-Agreement Criteria for Lin'S Concordance Correlation Coefficient. National Institute of Water & Atmospheric Research; 2005; <http://www.medcalc.org/download/pdf/McBride2005.pdf>. May
12. Reef VB. *Equine diagnostic ultrasound*. Saunders Company; 1998; 273. p.
13. Wiersema MJ, Wiersema LM. High-resolution 25-megahertz ultrasonography of the gastrointestinal wall: histologic correlates. *Gastrointest Endosc*. 1993;39:499-504.
14. Byrne MF, Jowell PS. Gastrointestinal imaging: endoscopic ultrasound. *Gastroenterology*. 2002;122:1631-1648.
15. Ødegaard S, Nesje LB, Lærum OD, Kimmey MB. High-frequency ultrasonographic imaging of the gastrointestinal wall. *Expert Rev Med Devices*. 2012;9:263-273.
16. Chiocchetti R, Bombardi C, Mongardi-Fantaguzzi C, et al. Intrinsic innervation of the horse ileum. *Res Vet Sci*. 2009;87:177-185.
17. Chiocchetti R, Giancola F, Mazzoni M, Sorteni C, Romagnoli N, Pietra M. Excitatory and inhibitory enteric innervation of horse lower esophageal sphincter. *Histochem Cell Biol*. 2015;143:625-635.
18. Giancola F, Rambaldi AM, Bianco F, et al. Localization of the 5-hydroxytryptamine 4 receptor in equine enteric neurons and extrinsic sensory fibers. *Neurogastroenterol Motil*. 2017;29:e13045.

19. Barone R. *Anatomia comparata dei mammiferi domestici*. Edizioni Edagricole; 2006; 238 p.
20. Bertone AL, Cockerell GL, Lee RE, Stashak TS. Correlative morphometry and morphology of normal equine intestinal mucosa and comparison after adaptation to extensive large colon resection. *Equine Vet J Suppl*. 1989; (7): 46-51.
21. Gartner LP, Hiatt JL. *Istologia. Napoli: Edizioni SES srl*. 2009; 401. p.
22. Lowden S, Heath T. Lymphoid tissues of the ileum in young horses: distribution, structure, and epithelium. *Anat embryol*. 1995;192: 171-179.
23. Lowden S, Heath T. Lymph pathways associated with three types of follicle structure found in gut-associated lymphoid tissue of horse ileum. *Anat embryol*. 1996;193:175-179.
24. Nielsen T, Lindström L, Ingman J, Uhlhorn M, Hansson K. High-frequency ultrasound of Peyer's patches in the small intestine of young cats. *J Feline Med Surg*. 2016;18:303-309.
25. Kidd J, Lu KG, Frazer ML. *Atlas of Equine Ultrasonography*. John Wiley & Sons, Ltd; 2014; 427. p.
26. Whitcomb MB. Equine abdominal ultrasound. Proceedings of the 24th Annual ACVIM Forum; May 31–June 3, 2006; Louisville, KY.
27. Penninck DG, Nyland TG, Fisher PE, Kerr LY. Ultrasonography of the Normal Canine Gastrointestinal Tract. *Vet Radiol Ultrasound*. 1989;30:272-276.
28. Braun U, Marmier O. Ultrasonographic examination of the small intestine of cows. *Vet Rec*. 1995;136:239-244.
29. Sarriá R, Latorre R, Henroteaux M, et al. Morphometric study of the layers of the canine small intestine at five sampling sites. *Vet J*. 2012;192:498-502.
30. Russo D, Bombardi C, Grandis A, et al. Sympathetic innervation of the ileocecal junction in horses. *J Comp Neurol*. 2010;518:4046-4066.
31. Di Donato P, Penninck D, Pietra M, Cipone M, Diana A. Ultrasonographic measurement of the relative thickness of intestinal wall layers in clinically healthy cats. *J Feline Med Surg*. 2014;16:333-339.
32. Gladwin NE, Penninck DG, Webster CRL. Ultrasonographic evaluation of the thickness of the wall layers in the intestinal tract of dogs. *Am J Vet Res*. 2014;75:349-353.
33. Kimmey MB, Martin RW, Haggitt RC, Wang KY, Franklin DW, Silverstein FE. Histologic correlates of gastrointestinal ultrasound images. *Gastroenterology*. 1989;96:433-441.
34. Clarke BS, Banks TA, Findji L. Quantification of tissue shrinkage in canine small intestinal specimens after resection and fixation. *Can J Vet Res*. 2014;78:46-49.
35. Rault DN, Besso JG, Boulouha L, Begon D, Ruel Y. Significance of a common extended mucosal interface observed in transverse small intestine sonograms. *Vet Radiol Ultrasound*. 2004;45:177-179.
36. Smyth GB. Effects of age, sex, and post mortem interval on intestinal lengths of horses during development. *Equine Vet J*. 1998;20:104-108.
37. Hernández F, Kozuka Y. Cambios post mortem en mucosa intestinal y tejido pulmonar de *Mus musculus*, observados al microscopio electrónico de barrido. *Rev Biol Trop*. 1981;29:265-272. <https://www.deeppl.com/it/translator>. English translation available at

SUPPORTING INFORMATION

Additional supporting information may be found in the online version of the article at the publisher's website.

How to cite this article: Diana A, Freccero F, Giancola F, et al. Ex vivo ultrasonographic and histological morphometry of small intestinal wall layers in horses. *Vet Radiol Ultrasound*. 2022;63:353–363. <https://doi.org/10.1111/vru.13059>