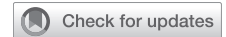

A primer for the student joining the general thoracic surgery service tomorrow: Primer 2 of 7



Colin C. Yost, MD,^a Rohun Bhagat, MD,^b David Blitzer, MD,^c Clauden Louis, MD,^d Jason Han, MD,^e Fatima G. Wilder, MD, MSc,^f and Robert A. Meguid, MD, MPH, FACS,^g Philadelphia, Pa; Cleveland, Ohio; New York, NY; Boston, Mass; and Aurora, Colo

From the ^aSidney Kimmel Medical College, Thomas Jefferson University, Philadelphia, Pa; ^bDepartment of Thoracic and Cardiovascular Surgery, Cleveland Clinic, Cleveland, Ohio; ^cDivision of Cardiovascular Surgery, Columbia University, New York, NY; ^dDivision of Cardiothoracic Surgery, Brigham and Women's Hospital, Boston, Mass; ^eDivision of Cardiothoracic Surgery, University of Pennsylvania, Philadelphia, Pa; ^fDivision of Thoracic Surgery, Brigham and Women's Hospital, Boston, Mass; and ^gDivision of Cardiothoracic Surgery, Department of Surgery, University of Colorado School of Medicine, Aurora, Colo.

Disclosures: The authors reported no conflicts of interest.

The *Journal* policy requires editors and reviewers to disclose conflicts of interest and to decline handling or reviewing manuscripts for which they may have a conflict of interest. The editors and reviewers of this article have no conflicts of interest.

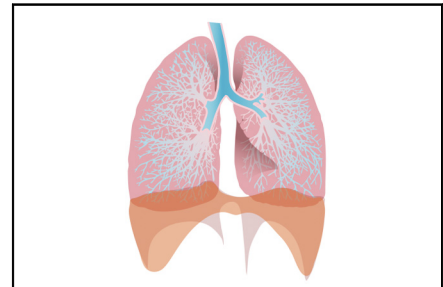
Received for publication Feb 19, 2023; revisions received April 2, 2023; accepted for publication April 8, 2023; available ahead of print April 18, 2023.

Address for reprints: Rohun Bhagat, MD, Department of Thoracic and Cardiovascular Surgery, Heart, Vascular & Thoracic Institute, Cleveland Clinic, 9500 Euclid Ave, Cleveland, OH 44195 (E-mail: rohun.bhagat@gmail.com).

JTCVS Open 2023;14:293-313
2666-2736

Copyright © 2023 The Author(s). Published by Elsevier Inc. on behalf of The American Association for Thoracic Surgery. This is an open access article under the CC BY-NC-ND license (<http://creativecommons.org/licenses/by-nc-nd/4.0/>).

<https://doi.org/10.1016/j.xjon.2023.04.001>



This medical student primer discusses the phases of care in general thoracic surgery.

CENTRAL MESSAGE

This medical student primer discusses general thoracic surgery, which involves treating pathologies involving all structures in the thorax except the heart, thoracic aorta, great vessels, and spine.

General thoracic surgery involves the treatment of pathologies involving the following structures in the thorax: the lungs, pleura, trachea, esophagus, mediastinum (thymus and mediastinal lymph nodes), chest wall, and diaphragm. It excludes the heart, thoracic aorta, great vessels, and spine. Many patients require surgery to remove early-stage malignancies involving thoracic organs (lungs and esophagus) or treat chronic conditions that are refractory to medical management (eg, gastroesophageal reflux disease [GERD] and hiatal hernia). Although these procedures are generally well-tolerated and highly effective, they are part of a nuanced treatment strategy that requires a comprehensive understanding of the patient population and their disease processes. This primer is intended for medical students and other trainees rotating on the thoracic surgery service and is separated into 3 phases of care: preoperative (clinic and consults), perioperative, and postoperative (patient management). It is not a comprehensive review of general thoracic surgery or intended to replace structured study of the discipline.

BASIC SCHEDULE

To follow is a brief outline of a typical day on the general thoracic surgery service. In addition to the activities listed, it is important for students to attend tumor boards and

multidisciplinary conferences when possible. This will vary by institution, so be sure to check with the residents, fellows, and/or attendings.

5:00 to 6:00 AM: Pre-round (as needed, policy varies by medical school and service).

6 to 6:45 AM: Rounding begins with students, residents, and fellows (if applicable). Consent and mark patients in preoperative ward (if it is done the same day at the institution).

7:30 AM: Operating room (OR) cases begin or outpatient clinic begins.

Between cases: Use toilet and eat, read up on the next case, help move along cases with OR turnover as much as appropriate, follow up on plans for the day such as imaging studies, see consults. As appropriate, check in with team including advanced practice providers regarding assistance with floor duties (eg, chest tube or drain removal, updating patients, contacting family members).

3:00 to 6:00 PM: Elective cases end.

6:00 PM: Afternoon rounds and sign out to the night coverage.

PREOPERATIVE (CLINIC AND CONSULTS)

Clinic

General thoracic surgery clinic, like most surgical clinics, includes 3 main types of visits: preoperative evaluations, postoperative follow-ups, and established patient visits. When evaluating a patient's candidacy for surgery, the first step is to determine which of the patient's condition(s) could necessitate surgical intervention (see the section "Case Descriptions" to follow). Obtaining a focused history and physical examination (H&P) and reviewing preoperative imaging will help with this process. If longitudinal preoperative imaging is available, it is important to identify changes in the pathology of interest over time. Next, evaluate whether the patient is healthy enough to undergo surgery and will benefit from having surgery or has contraindications to surgery necessitating further optimization or pursuit of nonsurgical treatment options. A variety of standardized tools (such as the Revised Cardiac Risk Index, Surgical Risk Preoperative Assessment System, and the American College of Surgeons National Surgical Quality Improvement Program Risk Calculator) are available to help with preoperative risk stratification.^{1,2}

Postoperative visits focus on assessing patient's recovery from surgery including symptoms related to the surgical pathology, basic postoperative milestones (ie, wound healing, ambulation, dyspnea, diet, bowel and bladder function, resolution of need for pain medication), and follow-up of pathology reports as appropriate.

Established patient visits are usually for long-term surveillance of cancer or noncancerous conditions. This typically entails obtaining an updated H&P and reviewing new imaging.

Consults

The general thoracic surgery team will often be consulted on patients with acute pathologies affecting the thoracic cavity. First, evaluate the patient's clinical status and vital signs to determine whether the patient is acutely unstable or not, which will inform whether or not there is time for a full H&P. If time permits, it is helpful to ask questions that point toward specific organ system involvement (eg, dysphagia, dyspnea, muscle weakness, and productive cough could point toward esophageal, diaphragmatic, or lung parenchymal involvement) and assess for other factors (eg, occupational exposures, medication adverse effects, or complications of previous interventions) that could be crucial to identifying the underlying diagnosis.

When gathering objective data, perform a thorough physical examination. For example, when examining a patient's lungs, it is important to assess respiratory effort and assess accessory muscle use in addition to lung sounds.

It is also important to consider objective data from laboratory studies, imaging studies, microbiology, and pathology when working up a consult.

When developing the assessment and plan, create a differential diagnosis that incorporates H&P findings as well as the patient's acuity. Although multiple diagnoses may have a similar presentation, a patient's vital signs can help identify the need to pursue further diagnostic workup or immediate intervention. For example, shortness of breath and hyperresonance to percussion over the left lung fields indicates a left pneumothorax, but management priorities depend on the patient's hemodynamic and respiratory status. In this example, tension pneumothoraces require immediate needle decompression and chest tube placement. Finally, remember that surgical patients are at risk of developing acute pathologies that cause them to rapidly decompensate. If alone in a patient's room when they develop unstable vital signs or become nonresponsive, get help immediately/initiate a code. [Table 1](#) (which includes [Figures 1](#) and [2](#)) describes important parameters for clinic and consults.

After gathering the pertinent information and meeting with and examining the patient, it is time to present to a resident/fellow or attending. The goal when presenting a patient on a surgical service is to convey the pertinent information while maintaining focus and brevity. Although residents may present informally, it is best for students to present succinctly in the format of a written H&P (unless directed otherwise), as this style is typically the most straightforward for listeners. Starting the presentation with a one-liner that states the problem or reason for consultation can also help orient the listener. It can be helpful to review the case and rehearse the presentation with residents before speaking with attending surgeons. Certain key clinical terms can concisely convey critical information such as acuity or severity. An example is provided to follow.

This consult is for a solitary lung nodule. Ms. Jones is a 75-year-old female with a 35 pack-year smoking history, quit 1 year ago, who presents for workup of a lung nodule. A 4-mm left lower lobe nodule was discovered incidentally 1 year ago on computed tomography (CT) during workup of diverticulitis. Since then, she has been followed by pulmonology with CT scans every 6 months, with the most recent showing nodule growth to 9 mm with spiculation and adjacent ground glass opacification. A CT-guided biopsy last month showed poorly differentiated adenocarcinoma. She has no respiratory symptoms or B symptoms. Ms. Jones' pulmonologist, Dr Brown, referred her to our clinic for consideration of surgical management.

Ms Jones understands that her nodule is cancer and is interested in learning more about surgical treatment options. She has no medical history that raises her revised

cardiac risk index and is highly active at baseline. She has stopped smoking since the nodule was discovered and takes no anticoagulant or antiplatelet medications. Pulmonary function tests showed forced expiratory volume in 1 second of 1.6 L, 86% predicted and diffusing capacity for carbon monoxide/alveolar volume of 63% predicted.

In terms of assessment and plan, given Ms Jones's tobacco use history, the size and growth of her nodule,

and her generally low surgical risk, I believe it is appropriate to proceed with mediastinal lymph node staging, minimally invasive left upper lobectomy, or possibly apicoposterior anterior trisegmentectomy and mediastinal lymph node dissection.

Lastly, look at the "Final Steps" portion of [Table 1](#) to see examples of orders that will be placed before the clinic visit or consult is complete.

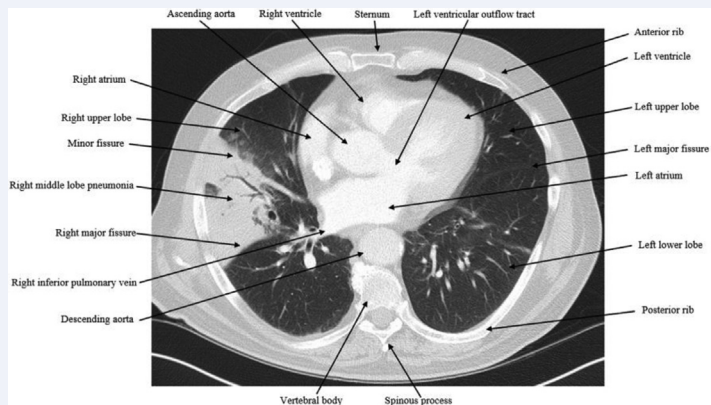
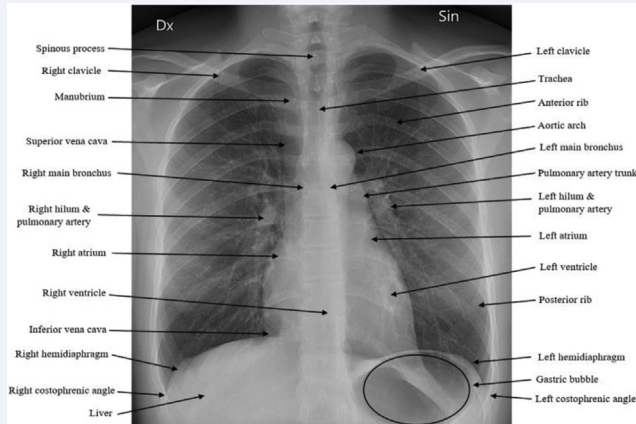
TABLE 1. Clinic and consult important parameters

Parameter	Abbreviation	Notes
Before seeing the patient		
Referring physician	–	Often, an attending thoracic surgeon will want to know which primary care/pulmonologist/gastroenterologist physician referred the patient to the outpatient clinic.
History of present illness	HPI	A focused history on when/why the disease was discovered, follow-up since discovery, and relevant symptoms (including progression of symptoms). (More about common pathologies and presentations can be found in the "Case Descriptions" portion of this text.)
Past medical history	PMH	Consider comorbidities that relate to pulmonary/esophageal pathology or increased surgical risk. Include factors that increase the Revised Cardiac Risk Index* (ischemic heart disease, type 2 diabetes mellitus on insulin, chronic kidney disease, cerebral vascular accident, congestive heart failure), previous environmental or toxic exposures (tobacco, military exposures, etc), as well as previous cancer treatment (especially mediastinal radiation), sleep apnea, and issues with anesthesia.
Past surgical history	PSH	It is important to review any relevant PSH, including any history of previous chest/abdominal instrumentation, previous pulmonary/abdominal surgery (for which previous operative notes should be obtained), and previous pulmonary/gastrointestinal procedures (such as lung biopsies or esophageal dilations)
Current medications	Meds	List current medications and obtain a detailed history of any antiplatelet/anticoagulation medications that may need to be stopped prior to surgery. For patients with gastroesophageal reflux disease (GERD)/hiatal hernia, it is important to note which medical therapies the patient has attempted and whether they provided adequate symptom relief. Of note, what is listed in the chart may differ from what the patient is actually taking or how frequently they are taking it. For preoperative review of medications, it is important to ask about herbal medications that may increase the patient's bleeding risk.
Laboratory tests	–	Review laboratory tests with a focus on CBC, BMP/CMP, coagulation studies, ABGs, etc.
Pulmonary function tests	PFTs	PFTs are crucial before lung resection surgery to determine a patient's pulmonary reserve (ie, whether they have sufficient and appropriate quality lung parenchyma to tolerate a segmentectomy, lobectomy, or pneumonectomy). The impact of preoperative PFTs on proceeding with lobectomy vs segmentectomy is discussed in the "Case Descriptions" section of this text.
Chest radiograph	CXR	Most thoracic surgery patients will have CXRs. CXRs can detect disease of thoracic structures (lung, heart, pleura, spine, diaphragm, etc) and are often standard practice before most operations. In preoperative visits, it is important to compare the evolution of the pathology of interest over time on CXR. In postoperative visits or consults, it is important to compare the preoperative and immediate postoperative CXR to assess placement of catheters, drains, endotracheal tubes, and the lung parenchyma. Additionally, one can assess for injury to other structures that has occurred (eg, phrenic nerve paralysis resulting in hemidiaphragm elevation). It is important to develop a systematic approach to interpreting CXRs to ensure consistent identification of the key elements of a pathologic process. For example, recognizing not only air space hyperlucency but also an accompanying mediastinal shift is crucial to recognizing signs of a tension pneumothorax on CXR. A labeled normal posteroanterior CXR is provided in Figure 1 .

(Continued)

TABLE 1. Continued

Parameter	Abbreviation	Notes
Computed tomography	CT	<p>CT scans are helpful for identifying and tracking the growth of lung/gastrointestinal pathologies (eg, lung nodule/mass, hiatal hernia). For patients in which malignancy is of concern, a CT and/or positron emission tomography (PET-CT; see below) can also be used to screen for distant metastases, which carries a worse prognosis and is often a contraindication to surgical intervention. A labeled CT scan (axial) showing lobar pneumonia of the right middle lobe is provided in Figure 2.</p>
Positron emission tomography scan	PET scan or PET/CT scan	<p>A PET scan uses a radioactive tracer combined with a CT scan to identify areas of increased metabolic activity. While identifying malignancy is the primary goal of this scan in the context of general thoracic surgery, it is important to be aware of benign processes that cause increased metabolic activity (eg, infection or inflammation) and result in areas of increased activity on a PET scan. In the context of lung pathology, a standardized uptake value greater than 2.5 or background pooled blood is generally considered abnormal.⁴</p>
Esophagogram	–	<p>Esophagograms are the bedrock of the preoperative workup for hiatal hernia repairs, as they allow for identification of hernia characteristics (ie, size and location, sliding) and can identify accompanying esophageal pathologies related to GERD (ie, dysmotility and strictures). For</p>



(Continued)

TABLE 1. Continued

Parameter	Abbreviation	Notes
Esophageal manometry	–	example, the “bird’s beak” sign (esophagus dilated proximally and tapered distally) on esophagogram is pathognomonic for achalasia. They are also helpful for ruling in or out esophageal perforation and guiding surgical or endoluminal intervention by demonstrating location and magnitude of leak. Esophageal manometry is used to obtain a detailed analysis of esophageal motility and is useful for identifying pathologies that affect lower esophageal sphincter tone (eg, increased in some types of achalasia) or esophageal contractility (eg, decreased in prolonged acid reflux and systemic scleroderma).
CT-guided biopsy	–	A CT-guided lung biopsy is used to diagnose suspected lung malignancy in locations that are anatomically accessible via needle biopsy through the chest wall.
Endobronchial ultrasound and Endobronchial biopsy	EBUS	An EBUS is used to allow for visualization of the central airways and nearby structures. In the context of lung malignancy diagnosis and staging, it is a useful tool to perform endobronchial biopsy of airway masses and/or paratracheal lymph nodes.
Esophagogastroduodenoscopy	EGD	EGD allows for direct visualization and biopsy of esophageal, gastric, and duodenal mucosal pathologies such as suspected malignancy or complications of chronic GERD (eg, ulcers, Barrett esophagus, and erosive esophagitis).
Electrocardiogram	EKG/ECG	Review for irregularities. The cardiology official report on the ECG (if available) can be helpful for particularly challenging ECGs.
Echocardiography	Echo	Echocardiography is a key dynamic imaging tool to assess global cardiac function, identify valvular pathology, and plan for surgical intervention. This modality depicts how the heart is functioning in every chamber (including valves) and measures overall left and right heart function (ejection fraction). Various measurements including heart size, degree of valvular regurgitation or stenosis, and heart function can be obtained quantitatively and qualitatively. The official report is helpful to obtain a clear understanding of how each part of the heart is functioning. Surgeons may obtain an echocardiogram before thoracic surgery to assess a patient’s baseline cardiac function if they routinely use antiarrhythmic medications for prophylaxis of postoperative atrial fibrillation or if pulmonary hypertension is of concern.
Transesophageal Echocardiography	TEE	
Transthoracic Echocardiography	TTE	
After assessing the aforementioned information, it is often possible to piece together most of the assessment and plan. It is ideal to know as much as possible about a patient and formulate a potential plan for treatment before speaking with them. The next step is to speak with the patient.		
Talking to the patient		
Chief complaint	CC	Consider why the patient has come to clinic (this is often due to a symptom). Common examples for lung malignancy include shortness of breath, cough, dyspnea on exertion, unexpected weight loss, fevers/chills, and fatigue. Common examples for hiatal hernia/GERD include postprandial nausea/vomiting, regurgitation/bubbling, reflux symptoms (heartburn), early satiety, postprandial shortness of breath, and unexpected weight loss.
Acquire HPI, PMH, meds	–	As stated previously, be sure to review the information in the chart and correlate it with information obtained while interviewing the patient/historian.
Review of systems	ROS	This is often part of the HPI. However, it can be expanded into its own section if the patient describes many symptoms that are likely unrelated to the presenting pathology (eg, chronic eczema).
Surgical history	PSH	Any history of previous surgeries. In particular, chest and abdominal surgery history may influence the thoracic surgical plan and must be considered. It is important to acquire original operative reports and CT imaging to define anatomy, given the patient’s previous surgery.
Family history	FH	Family history of respiratory/gastrointestinal disease, cancer, or anesthesia complications in the past (eg, malignant hyperthermia)
Social and occupational history	SH	Inquire as to what the patient does on a daily basis and how is this disease pathology is impacting their daily life. It is important for surgeons to consider how surgery will affect the patient’s quality or length of life. Ascertain tobacco, alcohol, and other drug use. Be specific with tobacco use history (duration and amount), as it plays a role in the decision-making for lung nodules/malignancies. Calculate pack years of smoking history (number of packs smoked per day × number of years smoked) and know the date a patient quit smoking.

(Continued)

TABLE 1. Continued

Parameter	Abbreviation	Notes
Other questions to ask	–	Determine whether there are risk factors in the patient’s occupation which may increase their risk for malignancy (eg, asbestos and radon exposure). Find out who is at home to help take care of the patient after surgery if needed. - Gauge the patient’s understanding of their disease process and treatment options. - Determine their openness to surgical intervention. - Assess the patient’s knowledge of their diagnosis. Of note, medical students should avoid disclosure of a new pathology result without explicit permission and supervision from an attending.
Physical examination		This physical examination is primarily focused on the chest and foregut.
Overall		Assess whether the patient looks comfortable, uncomfortable, or in significant distress.
Head, ears, eyes, nose, throat		Assess for head/neck/axillary lymphadenopathy and signs of mediastinal vascular obstruction such as cervical venous collateralization.
Respiratory		Auscultate and assess for breath sounds and any additional findings that could suggest pulmonary edema or pleural effusions, such as crackles. Auscultate the trachea if concern exists for tracheal stenosis.
Gastrointestinal		Inspect, auscultate, and palpate the abdomen.
Skin		Look for evidence of lower extremity edema (heart failure), signs of previous surgery (scars), etc.
The following examinations are important but should be performed in a concise format (eg, it is unnecessary to conduct a complete neurologic exam in most patients).		
Cardiac		Auscultate cardiac listening areas and assess for murmurs. Assess distal pulses for discrepancy that might suggest peripheral vascular disease.
Neurologic		Determine if the patient is alert and oriented, if there are any gross deficiencies of strength or facial drooping, or if there are any signs of previous stroke or transient ischemic attack.
Musculoskeletal		Check for any gross motor abnormalities or peripheral edema.
Assessment and plan		Combine the information above to decide what treatment options are most appropriate for the patient. It is important to look at the formal indications and contraindications for an operation. Formal indications are more comprehensively covered in the “Case Descriptions” portion of this text.
Presentation to resident/attending surgeon		See example presentation to follow the table.
Final steps		Patient is not having surgery: Determine if there is a need for additional treatment or referrals. Schedule follow-up as indicated. Should additional testing or surveillance be indicated, appropriate follow-up with thoracic surgery, pulmonology, gastroenterology, and/or the primary care physician should be set up in advance. Patient is having surgery: Complete any of the following which have not been completed (this is institution specific, but an example workup is provided below). It is important for students to review all pertinent imaging on their own before discussing it with the resident/fellow/attending. Making a habit of looking at the imaging helps build an understanding of, and comfort with, identifying key and concerning findings.
CXR		Obtain if not already obtained. Relevance discussed previously in table.
CT		Obtain if not already obtained. Relevance discussed previously in table.
PFTs		Obtain if not already obtained. Relevance discussed previously in table.
Echocardiogram		Surgeons may obtain before thoracic surgery in greater cardiac risk patients to assess a patient’s baseline cardiac function, as described previously.
Laboratory studies		CBC (with differential if concern for infection at admission) CMP (includes glucose, Ca, Na, K, HCO ₃ , Cl, albumin, protein, alkaline phosphatase, alanine/aspartate aminotransferase, bilirubin, blood urea nitrogen, and creatinine)

(Continued)

TABLE 1. Continued

Parameter	Abbreviation	Notes
		Coagulation studies (often includes platelets [in CBC], prothrombin time, international normalized ratio, partial thromboplastin time, and fibrinogen)
		Urinalysis
		Methicillin-resistant <i>Staphylococcus aureus</i> swab
Medication changes		The patient may be asked to discontinue (“hold”) certain medications the day of surgery and/or days prior to surgery. Common examples follow: Discontinue 7 days before surgery: prasugrel Discontinue 5 days before surgery: clopidogrel, ticagrelor, warfarin Discontinue 60 hours before surgery: fondaparinux Discontinue 48 hours before surgery: novel oral anticoagulants (dabigatran, apixaban, rivaroxaban, edoxaban) Discontinue 24 hours before surgery: Abciximab, low molecular weight heparin, angiotensin-converting enzyme inhibitors/angiotensin receptor blockers (refractory hypotension/vasoplegia) Discontinue 4 hours before surgery: unfractionated heparin, tirofiban, eptifibatide Discontinue 1-2 hours before surgery: bivalirudin Discontinue morning of surgery: diabetic medications, diuretics

CBC, Complete blood count; BMP/CMP, basic/comprehensive metabolic panel; ABG, arterial blood gas. *Ford and colleagues.¹

POSTOPERATIVE MANAGEMENT

Pre-Rounding and Writing Notes

Students on a thoracic surgical service are often expected to round on the patients each morning with the team. The patient list will consist of patients who either require preoperative management, postoperative management, or medical management of conditions without operative options. Although postoperative patients on the general thoracic surgery service are typically managed on a

telemetry floor, patients with more complex postoperative requirements may be managed in the intensive care unit.

The first step is to ask whether there is a note template that is commonly used. If not, it is appropriate to type the below sections into history of present illness, laboratory tests, physical examination, etc. It may be easiest to document initial findings in a note format rather than gathering the data in one place and having to translate it to a note later.

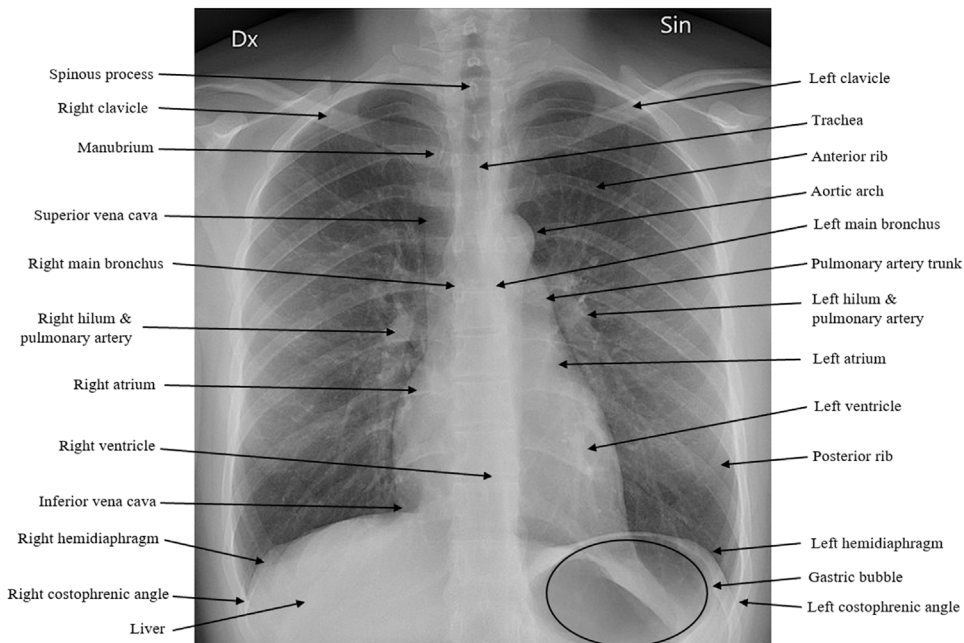


FIGURE 1. Labeled normal posteroanterior radiograph of the chest.

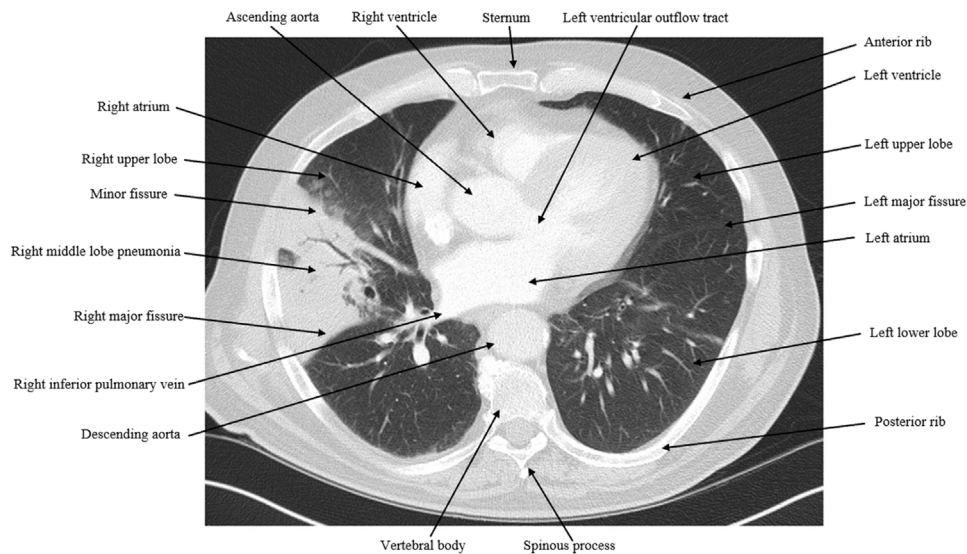


FIGURE 2. Labeled computed tomography scan (axial) showing lobar pneumonia of the right middle lobe.

Table 2 lists clinical data and information that is important to consider in every patient. Although it is important to check all of the patient’s clinical data, the thoracic surgery service will tend to place more emphasis on the following parameters.

Presentations and Rounding

The ideal presentation concisely highlights all pertinent information. There is no need to report all laboratory values; instead, highlight anything abnormal and notable trends. Try to develop a detailed understanding of a patient’s expected postoperative milestones, which will help to temporally highlight the presence or the absence of certain findings. Presentations are typically given using a SOAP format (Subjective, Objective, Assessment, and Plan) with an emphasis on the following factors:

- postoperative day;
- overnight events and subjective symptoms: focused on barriers to discharge (eg, pain, breathing, oral intake, and ambulation);
- abnormal versus normal vitals: focused on trends;
- intake and output: typically focused on output; and
- assessment and plan: includes a solution for any problem mentioned in the presentation.

The example that follows would take approximately 2 minutes to present but is fairly comprehensive.

Ms Doe is a 35-year-old female who is postoperative day 1 from a robotic left upper lobectomy and mediastinal lymph node dissection. She had no acute events overnight. Today, she endorses pain around her chest tube site that is not controlled with an epidural and oral analgesia. She

has a mild, nonproductive cough and no dyspnea. She is tolerating a clear liquid diet without nausea or vomiting, has passed flatus, and is voiding via Foley catheter. She is pulling 1000 mL on incentive spirometry but has not yet ambulated.

Overnight she was afebrile, hemodynamically stable with heart rates in 80s and blood pressure 120 to 130s/70s to 80s. Oxygen saturation was in the mid-to-high 90s on 4 L of nasal cannula. For intake and output overnight, she took in 500 mL of clear liquids and made 1 L of clear yellow urine. The chest tube output overnight was 20 mL of serosanguinous discharge and shows no air leak at rest or with Valsalva. On physical examination, incision sites were intact with mild erythema, no induration, and minimal dried serosanguinous discharge on bandages. There are crackles on auscultation of the lungs anteriorly in the lower lobes. Her abdomen was soft, nontender, and nondistended. Her basic metabolic panel was unremarkable. White blood cell count is 8.2 from 8.3, hemoglobin is 8.5 from 9.0, and platelets are stable at 214. Radiograph of the chest showed an interval resolution of a left apical pneumothorax compared with postoperative day 0; chest tubes in proper position; and no pulmonary vascular congestion, infiltrate, or consolidation.

For assessment and plan, we can remove her chest tube with a follow-up radiograph of the chest post-pull and increase her dose of oxycodone. Her nasal cannula oxygen can also be weaned as tolerated. Maintenance fluids and Foley can be discontinued, given adequate urine output. Diet can be advanced to regular as tolerated. We should also encourage ambulation and can consider discharge to home today if she has adequate pain control with oral

TABLE 2. Important parameters in postoperative management of the general thoracic surgery patient

Parameter	Abbreviation	Normal values	Notes
General/vitals			
Postoperative day	POD	–	Know what day the patient is postoperatively (POD 0 is the day of surgery, POD 1 is the day after surgery, etc)
Blood pressure	BP	90-120/60-80 mm Hg (highly variable) ⁵	Know if the patient is on any vasoactive/inotropic medications (eg, epinephrine, norepinephrine, milrinone, phenylephrine). Any patient on these medications generally should have an arterial line for continuous BP monitoring.
Heart rate	HR	60-100 beats per minute ⁶	In addition to reporting the heart rate itself, check the electrocardiogram (ECG/EKG) and compare it with previous studies to assess for arrhythmias, new ST elevations, bundle branch blocks, or evidence of repolarization abnormalities. Esophageal operations: Tachycardia can be one of the first signs of esophageal anastomotic leak. Given anastomotic leak requires urgent intervention (as described to follow), it is important to monitor for persistent tachycardia that is not clearly attributable to another cause in esophageal postoperative patients.
Respiratory rate (RR)/oxygen saturation	RR/Spo ₂	12-20 breaths per minute ⁶ Spo ₂ >95% ⁷	Depending on their underlying lung function, patients may require supplementary oxygen after lung resection. Desaturation episodes may also indicate postoperative complications such as hemothorax, pneumothorax, pleural effusion, pulmonary edema, mucous plugging, and pneumonia. Be sure to report the patient’s supplemental O ₂ requirements (eg, how many liters of oxygen the patient is on if they are using a nasal cannula) and a plan to wean them. It is important to note if a patient is on oxygen at baseline. Additionally, some postoperative patients may require a temporary use of oxygen at home at the time of discharge. This is typically weaned in the weeks following surgery.
Ventilator	Vent		Know if the patient is on a ventilator and, if so, what the settings are: ventilation mode, FiO ₂ , PEEP, PS, V _t , and RR. Alter Pao ₂ : Reduce Pao ₂ via reducing FiO ₂ or PEEP. Increase Pao ₂ via increasing FiO ₂ or PEEP. Alter PaCo ₂ : Reduce PaCo ₂ via increasing RR or V _t . Increase PaCo ₂ via reducing RR or V _t . Providers in the ICU will often discuss weaning patients off ventilators in multiple ways. “Spontaneous breathing trials” test whether the patient is able to breathe with minimal vent support. This could be in the form of PS or CPAP among others. When PS is used, the patient triggers each breath, and the ventilator delivers minimal positive pressure (PEEP 5-8) to ease the work of breathing. “Trach Collar” means that the patient is disconnected from the ventilator and allowed to breathe either room air or supplemental oxygen through a tracheostomy for a certain amount of time without ventilator support. If the patient continues on Trach Collar indefinitely while maintaining an appropriate oxygenation status, they have been weaned off the ventilator. The team may opt to support the Trach Collar with increased FiO ₂ . The RSBI is the ratio of respiratory frequency to tidal volume. An RSBI of ≥105 breaths/min/L has been found to predict ventilator weaning trial failure. ⁸
Infection/inflammation			
Temperature	Temp	36.5-37.5 °C ⁷	Temperature can be indicative of inflammation or infection. It is important to note that patients may not mount a pathologically elevated temperature in the setting of ECMO or CRRT, so it is important to investigate other infection/inflammation parameters. Other noninfectious causes of hyperthermia should be kept in mind.
White blood cell count	WBC	4.5-11 × 10 ⁹ cells/L ⁹	Elevation in WBCs can point to inflammation or infection. It is important to note medications such as steroids that may represent as a non-infectious cause of elevated WBC count. Other noninfectious causes of leukocytosis should be kept in mind.

(Continued)

TABLE 2. Continued

Parameter	Abbreviation	Normal values	Notes
Procalcitonin	Procal	<0.1 ng/mL ¹⁰	Use caution when interpreting procalcitonin, as it does not differentiate well between disease processes. Often, clinicians will use it in the setting of suspected infection to assess if the causative agent is likely viral (normal Procal) or bacterial (elevated Procal; >0.25 ng/mL). ¹⁰
Blood cultures	BCx	–	If blood cultures are drawn for a patient, review closely for the gram stain, which may come earlier than speciation and sensitivity testing. Check to see if the gram stain is positive or negative and if sensitivities to antibiotics/antifungals are available.
Postoperative antibiotics	Postop Abx	–	Postoperative antibiotic regimens are typically institution-specific based on an institution's antibiogram.
Hematologic			
Hemoglobin (Hb)/ Hematocrit (Hct)	H/H or H&H	Hb: 14-17 g/dL (male), 12-16 g/dL (female) Hct: 41%-51% (male), 36%-47% (female) ⁹	Most hospitals will transfuse red packed red blood cells to the patient if their Hb is below 7 and/or Hct is below 21. Restrictive transfusion strategies have been shown to be beneficial and non-inferior to liberal thresholds. ¹¹
Platelets	Plts	150-350 × 10 ⁹ /L ⁹	Platelet count is helpful to understand risk of bleeding, heparin-induced thrombocytopenia, and inflammation (remember that platelets are an acute phase reactant).
Prothrombin time/ international normalized ratio	PT/INR	PT: 11-13 s Therapeutic INR: 2.0-3.0 ⁹	PT/INR tests for extrinsic pathway clotting cascade function. Warfarin primarily impacts this pathway; hence, INR is checked to assess the function/effect of warfarin.
Activated partial thromboplastin time	aPTT	25-35 s ⁹	aPTT tests for intrinsic pathway clotting cascade function and can be used to monitor heparin or bivalirudin function and adjust the infusion parameters accordingly in the ICU.
End-organ perfusion			
Lactate	-	Venous: 0.5- 2.2 mmol/L Arterial: 0.5- 1.6 mmol/L ¹²	A rising lactate can help clinicians understand and trend end-organ perfusion.
Creatinine	Cr	0.7-1.2 mg/dL (male) 0.5-1.0 mg/dL (female) ⁹	Creatinine is helpful to determine if the patient has a history of chronic renal insufficiency or is having AKI and is an important marker for renal function.
Urine output	UOP	0.5-1.5 mL/kg/h ¹³	Urine output may decrease in the immediate postoperative period due to increases in ADH and aldosterone from the insults of surgery. Postoperative fluid management after general thoracic procedures differs from that of other procedures (such as open abdominal surgery) because excess intravenous fluids can cause significant pulmonary edema. Check with the thoracic surgery resident/advanced practice provider before placing orders for continuous intravenous fluids.
Arterial blood gas	ABG	pH: 7.35-7.45 pCO ₂ : 35-45 mm Hg HCO ₃ : 22-26 mmol/L pO ₂ : 75-100 mm Hg SaO ₂ : >95% ¹⁴	Acid/base status is best understood through an ABG. pO ₂ can be helpful in assessing the efficacy of the lungs to oxygenate the blood. ABGs also provide an arterial lactate (more useful than a venous lactate). Whole blood ABG also provides measurements of Hb, sodium, potassium, and glucose.
Venous blood gas	VBG	pH: 7.32-7.43 pCO ₂ : 36-49 mm Hg (male); 39-52 (female) pO ₂ : 43-68 mm Hg ¹⁵	A VBG helps in assessment of a patient's acid/base status, as it provides an accurate assessment of pCO ₂ . It also provides a measurement of lactate, although arterial lactate is more sensitive to end organ perfusion.
Electrolytes	Review comprehensive/basic metabolic panel (CMP/BMP) for abnormal findings.		

(Continued)

TABLE 2. Continued

Parameter	Abbreviation	Normal values	Notes
Imaging	–	It is important to check for any new imaging (chest and abdominal radiographs, CT, MRI, echocardiography, etc). Many thoracic surgery patients will have daily postoperative CXRs. Be sure to report any changes from days prior (eg, pulmonary edema, pulmonary effusions, pneumothoraces) and check that chest tubes and drains have not migrated. Practices regarding post-chest tube removal chest radiographs (to monitor for pneumothorax development) vary by attending surgeon and institution. A more complete explanation of imaging interpretation and common findings can be found elsewhere in this primer series.	
Patient interview			
Overnight		Talk with the overnight team and the patient’s nurse(s), as they are invaluable resources in determining whether any major events occurred overnight.	
Overall condition		Assess how the patient feels at the time of interview and relative to the day before.	
Pain		Most inpatients on the thoracic surgery service will have undergone a thoracic operation via an open or minimally invasive approach. Thoracic surgery can be painful due to reasons such as traumatization of intercostal nerves, division of muscles of respiration, and use of chest tubes. Pain may be exacerbated with deep inspiration, coughing, or some movements. Many surgeons employ a perioperative multimodal pain management strategy using a combination of medications (eg, narcotics, pregabalin, acetaminophen), localized nerve blocks (eg, liposomal bupivacaine, epidural), and topical medications (transdermal lidocaine ointment or patches). Poorly controlled pain can impede postoperative recovery and increase risk of atelectasis and pneumonia.	
Breathing		Patients may take shallow breaths due to chest wall, pleuritic, and abdominal pain. It is often advantageous to encourage them to take bigger breaths to help prevent pneumonia. This is achieved by walking, sitting upright, and using an incentive spirometer. The latter helps quantify the volume of inspiration patients can achieve. Encouraging incentive spirometer use is key for any postoperative patient but is especially crucial after lung surgery. An effective way to achieve this is to counsel patients to take 10 breaths on the incentive spirometer every hour while awake.	
Cough		Coughing is critical to help clear secretions and expand the lung postoperatively. It is important to counsel patients not to avoid coughing due to the fear of pain or causing injury. An inability to cough effectively suggests a need for improved pain control.	
Ambulation		Assess whether the patient is getting out of bed (even to use the bathroom, etc). If the patient is ambulating, identify how many times, how far, and whether they required supplemental oxygen.	
Gastrointestinal, genitourinary (GU)		Assess whether the patient passed gas or had a bowel movement. Identify whether the patient is voiding independently or using an indwelling Foley catheter.	
Diet		Assess whether the patient been eating/drinking. If so, check whether they had dysphagia, nausea, and/or vomiting.	
Special considerations for management of esophageal operations		It is important to adequately control postoperative nausea with antiemetics (eg, ondansetron) to reduce the risk of vomiting and subsequent esophageal complications (eg, aspiration, pain). These complications require urgent treatment with broad spectrum antibiotics and, sometimes, re-intervention. Thoracic operations also pose a risk of recurrent laryngeal nerve damage, which typically manifests as voice hoarseness or an inability to cough. If a patient experiences voice hoarseness, it is important to distinguish between a sore throat limiting speech production (which is common postoperatively), and the inability to speak clearly despite maximal effort, which could indicate recurrent laryngeal nerve injury.	
Physical examination			
Overall		How the patient looks overall (eg, unstable, acute pain, calm, resting in bed, etc).	
Neurologic		Mental status should be assessed initially through basic interaction and communication with the patient. If there is concern for altered mental status, assess this through a more focused evaluation such as a Mini-Mental Status Examination. Stroke should always be assessed for via cranial nerve exam, assessment of communication, and motor strength in all extremities compared to baseline.	
Cardiac		Assess the patient’s heart rate and rhythm. Atrial fibrillation is common after anatomic lung resection and esophagectomy. Assess for other arrhythmias, new pericardial effusion, or murmur.	
Respiratory		If the patient is on a ventilator, assess ventilation settings and listen for bilateral breath sounds. If they are not on a ventilator, auscultate both sides anteriorly and posteriorly. Check how often the patient is using the incentive spirometer (also watch the patient use it to ensure they are using it correctly). Ask the patient’s nurse or medical assistant for help when repositioning a patient.	
Skin		Incision(s): integrity + erythema + induration + drainage - Integrity: It is important to ensure that the incision remains intact, as an open incision increases the risk of wound infection and dehiscence.	

(Continued)

TABLE 2. Continued

Parameter	Abbreviation	Normal values	Notes
Drains			<ul style="list-style-type: none"> - Erythema: While some erythema around the borders of the incision is expected for days to weeks postoperatively, substantial erythema spreading out beyond the borders of the incision is concerning for wound infection. - Induration: Areas of induration around the incision site(s) are also concerning for subcutaneous infections. - Drainage: A minimal amount of serous or sanguineous discharge may be noted for a few days postoperatively. However, copious drainage can be a sign of wound dehiscence, and seropurulent or purulent drainage can be a sign of wound infection. Persistent blood may indicate a subcutaneous bleed or an internal bleed. <p>Check with the nurse/resident prior to removing any dressings and ask for help in removing and replacing dressings. Typically, surgical site dressings are removed on POD 2 during rounds.</p> <p>Note the output volume, color, and turbidity of drain contents. Assess for air leak from chest tubes while breathing at rest, while speaking, and while using provocative measures (Valsalva, cough).</p> <p>Color: The output can be serous, sanguineous, seropurulent, or purulent. Depending on the clinical context, certain types and amounts of output are expected or not expected. It is important to characterize this information accurately to the team. A small amount of postoperative bleeding is expected, but the volume should downtrend and the characteristic should become increasingly serous.</p> <p>Air leak: Air leak from the chest tube indicates that air is leaking from the bronchial tree/lung parenchyma into the thoracic cavity. A small postoperative air leak is not uncommon after lung resection and typically resolves in hours to days. It is important to await resolution of an air leak before the chest tube is removed to avoid a tension pneumothorax developing.</p> <p>Provocative measures: These maneuvers transiently increase intrathoracic pressure with the goal of unmasking an air leak that may not be detected with normal respiration. Instruct patients to cough, bear down as if they are having a bowel movement, or blow air into their thumb as if they are inflating a balloon (Valsalva).</p> <p>Tidaling: The water level in the fluid column fluctuates throughout the respiratory cycle. This process is called tidaling and can only be observed when the chest tube is disconnected from suction. The water level should rise with negative intrathoracic pressure and fall with positive intrathoracic pressure. Tidaling is an important indicator that the chest tube is positioned and working properly. Lack of tidaling can indicate chest tube occlusion or complete lung re-expansion. Fluid in the drain tubing can be observed to assess for tidaling and tube patency.</p> <p>Water seal chest drain: The chest tube water seal chest drain is a commonly utilized chest tube drainage system that creates a one-way valve system by utilizing the principle that gas can only float to the top in a solution. It has multiple components including dry suction control; a fluid column, which creates a water seal; and a collection chamber to measure chest tube output. The dry suction control allows for manipulation of the suction pressure applied to the chest tube (typically this is set to -20 mm Hg). When suction is removed, the fluid column allows for maintenance of a water seal (typically -8 mm Hg), quantification of air leak based on the number of columns with bubbles, and identification of tidaling (described previously). After connecting a chest tube, the water seal chest drain should never be placed higher than the level of the patient and should be secured to the bed so that it remains upright. These measures prevent retrograde flow of chest tube drainage into the thoracic cavity.</p> <p>It is important to inspect the chest tube and all connected tubing (from the patient to the collection system) to ensure that nothing is disconnected or kinked. The chest tube insertion site should be examined to ensure there is no air leaking around the tube, which may contribute to the appearance of an air leak.</p>
Abdominal			<p>Palpate while checking for tenderness, distention, or bloating, which could be indicative of ileus or bowel obstruction. Auscultate to help discern bowel function.</p>
Assessment and plan			
Neurologic/pain			Discuss the neurologic status of the patient and note any plans for neurological intervention or specific monitoring. Additionally, discuss the patient's pain medications and any changes that are needed.
Cardiovascular			Discuss vasoactive/inotropic infusions and the plan to maintain or wean these. Other medications, pacing, etc may also be discussed here.
Respiratory			The patient may need pulmonary hygiene (eg, nasal suctioning, chest physiotherapy, therapeutic bronchoscopy), extubation, weaning of nasal cannula, etc.
Renal			State creatinine and urine output. If starting or changing diuresis is needed, note this here. List relevant laboratory values to monitor, such as BMP/CMP.
Gastrointestinal/nutrition			Discuss diet advancement, bowel regimen, liver function, etc. <p>Esophageal operations: The delicate nature of the esophageal anastomosis requires patients to be advanced gradually back to a regular diet in the postoperative period. While the specific nutrition protocol varies by institution and surgeon preference, it generally begins with enteral feeding via jejunal feeding tubes on POD 1 or POD 2. An esophagogram around POD 5-7 can be used to assess the integrity of the esophageal anastomosis. This assessment, timing of NG tube</p>

(Continued)

TABLE 2. Continued

Parameter	Abbreviation	Normal values	Notes
Infectious disease			removal, and dietary advancement are highly institution- and attending-specific, so it is appropriate to check with our team.
Hematologic			State the patient’s most recent temperature, current antibiotics, and plan for antibiotics/infectious workup, as necessary. State the patient’s hemoglobin/hematocrit, platelet count, and transfusion criteria. List relevant labs to monitor, such as a CBC. Discuss the need for VTE prophylaxis and the need to start or restart systemic anticoagulation or antiplatelet medication based on prior history of use or new findings indicating it (eg, new-onset atrial fibrillation for greater than 48 hours).
Endocrine			Discuss the patient’s insulin/diabetes management, as needed.
Skin			Discuss the patient’s incision and any major skin breakdown/physical exam findings indicative of infection or indicating need for further intervention.
Lines/tubes/drains			Discuss which of the patient’s lines/tubes/drains will remain and which will come out (if applicable). Chest tube management: chest tube management primarily involves determining if the chest tube is ready to be removed, and, if it needs to stay in, deciding whether to maintain suction (typically –20 mm Hg) or water seal (–8 mm Hg) postoperatively. Once a chest tube has no air leak and a patient has no/minimal pneumothorax on CXR, their chest tube can be removed (see Chest Tube Removal Technique below). Some centers obtain follow-up CXRs after chest tube removal to check for pneumothorax, but small stable pneumothoraces tend to be clinically inconsequential and may not need to delay discharge.
Disposition			Disposition is the location that the patient likely to go today (stay in ICU, transfer to floor, discharge to rehab, discharge home, etc). Home oxygen: Patients may require home supplemental oxygen if their SpO ₂ drops while ambulating postoperatively or if they used home supplemental oxygen at baseline prior to surgery. Typical guidelines include maintaining SpO ₂ ≥90% at rest or ≥88% with ambulation. Home physical therapy/occupational therapy: Patients who have difficulties with ambulation and/or activities of daily living during the initial postoperative period may require inpatient or home support services. In this case, a formal consult to physical therapy/occupational therapy is typically required before discharge.

POD, Postoperative day; ST, segment; SpO₂, oxygen saturation; Fio₂, inspired oxygen fraction; PEEP, positive end expiratory pressure; PS, pressure support; Vt, tidal volume; ICU, intensive care unit; CPAP, continuous positive airway pressure; RSBI, rapid shallow breathing index; ECMO, extracorporeal membrane oxygenation; CRRT, continuous renal-replacement therapy; AKI, acute kidney injury; ADH, antidiuretic hormone; CT, computed tomography; MRI, magnetic resonance imaging; CXR, chest radiograph; VTE, venous thromboembolism.

medications, a stable post-pull radiograph of the chest, and is able to be weaned from supplemental oxygen requirements (including during ambulation).

Hand-Offs and Sign-Out

When aiding in hand-offs between shifts, several key details must be included. These include plans for pain control, chest tube management (eg, settings), fluid resuscitation, and potential escalation of care. Postoperative fluid management after general thoracic procedures differs from that of other procedures (such as open abdominal surgery) because excess intravenous fluids can cause significant pulmonary edema. Specific instructions for maintenance fluid adjustment and/or boluses can help to avoid this complication.

For hand-offs on or after postoperative 1, it is important to briefly summarize the patient’s pertinent history, overall care, and provide a plan for sudden changes in patient status that would require urgent or emergent evaluation and management. Also note specific parameters that the team is particularly concerned about (eg, oxygen requirement, laboratory values pending, chest imaging, chest tube output, etc). For example:

Good hand-off: “Monitor for tachycardia”

Great hand-off: “Monitor for persistent tachycardia, which is often the first sign of esophageal anastomotic leak. If noted, order an electrocardiogram and contact the thoracic surgery team for review, further work up, and escalation of care.”

For morning sign-out, try to pre-round on the assigned patients before sign-out so new information/updates from the night team may be readily incorporated. For afternoon sign-out, make sure “to-do” lists for the day have been completed and updated results reviewed. The day team should minimize the number of residual day-time tasks that are passed on to the night team. This may include making sure all consults and orders are placed and tubes/drains pulled. A template for hand-off to the night team is provided in Appendix 1, A.

**PERIOPERATIVE
Preparing for Cases**

For any surgical rotation, it is important to look up in advance (typically the night before) the patient’s general history and indication for the operation, any relevant preoperative imaging, and the basic steps of the procedure. For

general thoracic surgery specifically, be sure to view any preoperative imaging and review the patient's pulmonary function tests and other pertinent studies. Watch videos of video-assisted thoracoscopic surgery (VATS) or robot-assisted operations to help identify anatomic landmarks (JTCVS Techniques video atlas articles are a useful resource).¹⁶ Students are generally not expected to know the detailed steps of an operation but may be asked about relevant anatomy. Residents can often help direct students to appropriate resources for targeted pre-reading. Before their procedure, the patient must be consented, and the surgical site or side must be marked by a provider on the surgical team (policies for specific personnel able to consent and mark patients vary by institution).

In the OR

Before the patient is in the OR, trainees should introduce themselves to the OR staff, write down their name/and or training to help the nursing team document their participation, and discuss with the OR staff how to assist in preparation for the case. Once the patient is in the room and anesthesia is induced, students may help with urinary catheter placement if indicated, electrocautery pad placement, and patient positioning. All of this should be as directed by the nursing team and residents. Expectations in the sterile environment vary by institution, surgeon, and operative approach. Regardless of the approach, students are typically expected to help close the skin at the end of the case. When comfortable with the team, be sure to ask for the opportunity to help with closure at the end of the case, if appropriate. This will typically involve an interrupted or running subcuticular stitch. A suture kit and online instructional videos are helpful tools to practice these techniques at home before the operation (The Modern Surgeon is a useful trainee-oriented resource).¹⁷

For open operations, students will typically be expected to assist with retraction and suctioning. For VATS cases, students will typically hold the endoscopic camera. Prepare for this responsibility by looking up the function of the camera buttons and videos that demonstrate how external movements correlate to changes in the camera's field of vision. For robot-assisted cases, students may be expected to work with or as the bedside assistant. Specific instructions will be provided by the attending surgeon and residents on a case-by-case basis.

General guiding principles for serving as a bedside assistant:

- Clarify with the scrub nurse or technician that it is okay before touching or taking anything off the Mayo stand. This is not only proper OR etiquette but also a safety precaution, as there are often sharps on the mayo stand.
- Practice closed-loop communication. For instance, surgeons can only see inside the body cavity when controlling the surgical robot. Therefore, they rely on the bedside assistant verbalizing their actions to confirm that any instructions they gave were heard and carried out. Every instrument exchange should be announced out loud. For example, "Removing tips-up from arm 4, introducing long bipolar grasper."
- When assisting robotic surgery, always look at the screen and move instruments into or out of the patient slowly. After inserting the instrument in the port, do not advance until the attending surgeon is able to visualize it on the screen. It is important to remain in control and aware of the position of the robotic instruments to avoid accidental injury. Ask the team to explain "guided instrument exchange," which can speed up the safe exchange of instruments.

Handing Off Patients to the Postanesthesia Care Unit (PACU) Team After the OR

Surgical teams may ask medical students to give a postoperative presentation of the patient's case to the PACU team as a hand-off. A template for OR to PACU hand-off is provided in [Appendix 1, B](#).

Case Descriptions (Types, Indications, and Steps)

This section describes common operations performed on the general thoracic service. Although this text discusses broad indications for each procedure, detailed discussions of cancer staging and treatment guidelines are beyond the scope of this text. The first citation in each procedure description provides illustrations that students may reference to reinforce relevant anatomy.

Note: Students should be aware that each operation can be performed in a variety of ways, and there is considerable variability across surgeons and institutions (especially in the approach to exposure). This text depicts one possible way to perform each procedure.

Lung resection (wedge resection, segmentectomy, lobectomy). Lung resection¹⁸ is indicated when empirical evidence has demonstrated a clear benefit to surgical management of malignant or benign processes. Most commonly, diseased parts of the lung are removed by lobectomy, segmentectomy, or wedge resection with disease-free margins. Segmentectomies and wedge resections may be considered when a patient lacks sufficient pulmonary reserve to tolerate a lobectomy (predicted postoperative forced expiratory volume in 1 second <1.5 L or 40% and diffusing capacity for carbon monoxide/alveolar volume <40%).¹⁹ The specific anatomic considerations and operative conduct during lung resection (ie, order of artery, vein, and bronchial dissection and ligation) depends on which

lobe or segment is being considered for resection and are beyond the scope of this chapter.

Indications For Lung Resection

- Lung malignancy²⁰
 - Tumor, node, metastasis (TNM) staging: See National Comprehensive Cancer Network website²⁰
 - Stage I and II non–small cell lung cancer (NSCLC) is treated with surgical resection
 - Stage IIIa NSCLC treatment is multimodal and can involve surgical resection
 - Stage IIIb and IV NSCLC is generally not treated definitively with surgery
- Lung nodules with features concerning for malignancy²¹
 - Increasing size
 - Spiculation
 - Part solid/part ground-glass characteristics
 - Significant malignancy risk factors (eg, extensive tobacco use, family history of lung cancer)
- Pulmonary blebs/bullae; recurrent pneumothoraces²²
- Infectious lung disease with focal disease and appropriate multimodal therapy²³

Operative Sequence

1. Intubate with dual-lumen endotracheal tube (ETT) (allows for the operative lung to be deflated while ventilating patient's contralateral lung, improving visualization and access to key structures).
2. Bronchoscopy at time of intubation (ensure ETT placement, perform a final inspection of the airways before surgery to ensure no intraluminal lesions).
3. Positioning: lateral decubitus position with the operative side facing up.
 - a. Pay careful attention to limb placement (to avoid compression or nerve injuries).
 - b. Maximally flex OR bed at the level of the patient's anterior superior iliac crest (ASIC).
4. Exposure: thoracotomy, VATS, or robotic approach.
5. Resection: Dissect and ligate the corresponding arteries, veins, and bronchi to segment/lobe/lung of interest.
 - a. Wedge resections: a small, nonanatomic portion of the lung is stapled off without ligation of corresponding small arteries, veins, and bronchi.
6. Mediastinal lymphadenectomy (remove surrounding lymph nodes for cancer staging—see Mountain lymph node staging for thoracic lymph node map²⁴).
7. Place chest tubes (to adequately drain air, pleural fluid, and blood postoperatively).
8. Reinflate lungs under visualization (to avoid torsion).

Notes

- Nonanatomic wedge resections are indicated for: resection of lung nodules for diagnosis and treatment (eg, colorectal cancer metastasis resection) and diagnosis of infiltrates.
- Chemotherapy, immunotherapy, and/or radiation therapy may also be used in combination with surgical resection depending on the TNM stage.

Bronchial sleeve resection. Bronchial sleeve resection²⁵ is indicated when a lung tumor extends into the central airways, which may occur with carcinoid tumors²⁶ and NSCLC.²⁷

Operative Sequence

1. Intubate with single-lumen ETT or laryngeal mask airway to facilitate bronchoscopy.
2. Bronchoscopy to visualize bronchial anatomy and assess for extent of disease.
3. Reintubate with dual-lumen ETT (allows for the operative lung to be deflated, improving visualization and access to key structures).
4. Positioning: lateral decubitus position with the operative side facing up.
 - a. Pay careful attention to limb placement (to avoid compression or nerve injuries).
 - b. Maximally flex OR bed at the level of the patient's ASIC.
5. Exposure: thoracotomy, VATS, or robotic approach.
 - a. If thoracotomy: can consider muscle-sparing approach.
6. Harvest intercostal muscle flap (surgeons may elect to use flap to cover anastomosis).
7. Resect lung tumor or lesion.
8. Send bronchial margin tissue for frozen section (confirm remaining ends of bronchus are disease-free).
9. End-to-end anastomosis (connect the disease-free ends of the bronchus back together).
10. Mediastinal lymphadenectomy (remove surrounding lymph nodes for cancer staging).
11. Reinforce anastomosis with vascularized tissue (eg, intercostal muscle flap, pericardial fat pad, or thymic fat wrap), assess for leak.
12. Bronchoscopy (evaluate integrity of anastomosis and remove pulmonary secretions).
13. Place chest tubes (to adequately drain air, pleural fluid, and blood postoperatively).
14. Reinflate lungs under visualization (to avoid lung torsion and evaluate for kinking or rotation of airway).
15. Exchange dual-lumen ETT for single-lumen ETT and repeat bronchoscopy to assess anastomosis and suction

out any secretions before awakening and extubating the patient.

Notes

- Maintain airway orientation by using traction sutures at the junction of the membranous and cartilaginous airways.
- The risk of a bronchial fistula or anastomotic leak can be reduced by decreasing tension with a hilar release and protecting the anastomosis with vascularized autologous tissue flap.
- Postoperative bronchial stenosis can be treated with dilation or stenting.

Hiatal hernia repair. Surgical treatment of a hiatal hernia is indicated for symptomatic paraesophageal hernias, sliding hiatal hernias with GERD symptoms refractory to lifestyle changes and medical therapy (eg, dietary changes, head of bed elevation, proton pump inhibitors), and hiatal hernias complicated by gastric volvulus, a surgical emergency in which the stomach twists on itself.^{28,29}

Operative Sequence

1. Place a nasogastric tube (to decompress stomach before entry).
2. Positioning: supine with OR table in approximately 30° of reverse Trendelenburg.
 - a. Place a footboard at the bottom of the bed to prevent the patient from sliding downward due to the steep angle. Pad and secure feet to bed.
3. Exposure: transabdominal via laparotomy, laparoscopy, or robotic approach.
4. Dissect the hiatus (allow access to the hernia).
5. Excise hernia sac.
6. Mobilize the distal esophagus, divide the gastrohepatic ligament and divide the short gastric vessels to mobilize the fundus of the stomach.
 - a. Be sure to preserve the left gastric and right gastroepiploic arteries.
7. Repair of diaphragm crura: close the defect made by hiatal dissection with sutures.
8. Fundoplication: wrap the fundus of the stomach around the distal esophagus while a bougie is in place within the esophagus (“shoe shine maneuver”).
 - a. This step is also used as a treatment for severe GERD refractory to lifestyle changes and medical therapy.³⁰
 - b. It is important to ensure that there are at least 2 to 3 cm of intra-abdominal esophagus without tension.
 - c. Fundoplication techniques
 - i. Complete (Nissen): Fundus is wrapped 360° around the gastroesophageal junction (GEJ).
 - ii. Partial: Fundus is wrapped 90° anteriorly (Dor) or 180 to 250° posteriorly (Toupet) around the GEJ.
9. Anterior gastropexy: secure the stomach to the abdominal wall to reduce the risk of a recurrent hernia. Placement of a gastrostomy tube can also achieve this.

Notes

- The gastrohepatic ligament may contain an aberrant left hepatic artery.
- As key steps are performed, consider the nearby anatomy to understand potential complications:
 - Dissection too close to stomach → places greater curve at risk for necrosis/leak.
 - Dissection along the greater curvature of the stomach → can lead to splenic injury.
 - Dissection behind the stomach → pancreas at risk for injury.
 - Closure of the hiatus → aorta and inferior vena cava at risk for injury (if sutures are placed too deep).
 - Wrap is too tight → dysphagia.
 - Vagal nerve injury → gastroparesis.

Esophagectomy

Esophageal malignancy (typically adenocarcinoma or squamous cell carcinoma) of the middle to distal third of the esophagus and GEJ are common indications for esophagectomy.^{31,32} As with lung malignancy, esophageal malignancies are assigned a TNM stage and generally considered resectable if there is limited spread of disease.²⁰ Esophagectomy may also be indicated in the setting of Barrett esophagus with high-grade dysplasia, given the high risk of progression to esophageal adenocarcinoma.³³ If the preoperative workup reveals that the patient does not have a viable gastric conduit (eg, gastric caustic injury, poor vascular supply, gastric spread of esophageal malignancy), alternative sources including the jejunum and colon should be considered.³⁴ Ideally, this should be determined before surgery to ensure appropriate workup has been performed and the patient is informed appropriately.

There are a variety of approaches to esophageal resection, including the Ivor Lewis (resection of distal two-thirds of esophagus with intrathoracic esophagogastric anastomosis via laparotomy and right thoracotomy or minimally invasive abdominal and

right chest approach), McKeown (resection of intrathoracic esophagus with cervical esophagogastric anastomosis via right thoracotomy, laparotomy, left neck incision, or minimally invasive abdominal and right chest and open neck approach), and transhiatal (resection of intrathoracic esophagus with cervical esophagogastric anastomosis via laparotomy or minimally invasive abdominal and open left neck incision) techniques.³¹ The patient's position varies depending on the operation performed. Generally, patients are placed in the left lateral decubitus position for steps involving transthoracic access. Patients are typically placed in the supine position for steps involving transabdominal access and left neck incision. Each of the major steps listed below can be performed by gaining exposure through an open or minimally invasive (laparoscopic/thoracoscopic or robot-assisted) approach. The main goals of an esophagectomy are to remove the malignant portions of the esophagus and to provide a viable replacement conduit to enable resumption of oral intake.

Operative Sequence

Abdominal phase of Ivor Lewis or minimally invasive esophagectomy (laparotomy or minimally invasive approach)

1. Dissect the hiatus: separate the GEJ from the diaphragm and dissect the lesser curvature of the stomach.
 - a. Gastric lymphadenectomy (if necessary for cancer staging).
2. Mobilize the stomach: dissect the greater curvature of the stomach preserving the gastroepiploic artery.
 - a. \pm Omental flap harvesting (per surgeon preference): pedicle a piece of the omentum off of the proximal fundus, which will later be used to wrap the anastomosis.
3. Create gastric conduit: staple the stomach along the lesser curve to create a straight conduit that will eventually replace the esophagus, dividing the left gastric artery.
 - a. \pm Pyloric drainage procedure (per surgeon preference): Botox injection, pyloroplasty, or pyloromyotomy (strategy to facilitate adequate conduit emptying).
4. Place a feeding jejunostomy tube.

Thoracic phase (right thoracotomy or right minimally invasive approach)
5. Mobilize the esophagus from the mediastinum: dissect the neurovascular supply to the esophagus.
 - a. Mediastinal lymphadenectomy (if necessary for cancer staging).
6. Resect the esophagus: divide the proximal end of the esophagus.
7. Send esophageal margin tissue for frozen section: confirm remaining ends of the esophagus is free of malignancy and Barrett disease.
8. Esophagogastric anastomosis: connect the disease-free ends together in the chest above the level of the azygous vein. Then complete division of the stomach along the lesser curve. Send resulting distal esophagus and proximal stomach for pathology evaluation.
 - a. \pm Omental flap (per surgeon preference): wrap the anastomosis in a flap of tissue for extra reinforcement.
9. Drain chest with chest tube.

Notes

Potential complications.

- Excessive dissection along the gastroepiploic arcade can result in impaired gastric blood supply, requiring an alternate conduit.
- Loss of proper orientation of the conduit (spiraling) can occur as the conduit is brought into the chest causing outlet obstruction of gastric conduit.
- Airway injury can occur, especially with dissection or energy source along the membranous wall of the right and left mainstem bronchi and trachea.
- Anastomotic leak is a major postoperative complication—management varies depending on the patient's presentation, location of anastomotic leak, and magnitude of leak.

First rib resection. First rib resection³⁵ is used as a last resort in the multimodal treatment regimen for patients with neurovascular symptoms from thoracic outlet syndrome or due to vascular complications.³⁶ Compression of the nerves (most common), artery, and vein can occur inside of the triangle formed by the first rib, clavicle, and scalene muscles. Nonsurgical treatments for thoracic outlet syndrome such as physical therapy³⁷ and ultrasound-guided botulinum toxin injection³⁸ should be attempted before surgical intervention given the risk of neurovascular injury during first rib resection.

The patient's position varies with the operation performed but typically involves placing the patient in the supine position and elevating the operative shoulder with a small pad or folded blanket to maximize exposure.^{35,39} Additionally, there are several approaches to first rib resection including supra- and infraclavicular, transaxillary, and minimally invasive video-assisted techniques.⁴⁰ The broad steps of the procedure are listed below. It is important for the student

to review the anatomy prior to the case since the exposure can be limited and the anatomy can be unfamiliar.

Operative Sequence (After Positioning and Exposure)

1. Exposure of central portion of first rib via axillary incision.
2. Division of the attachments to the first rib (listed to follow):
 - a. Inferior: mediastinal pleura
 - b. Superior: anterior and middle scalene muscles, subclavius muscle, costoclavicular ligament
 - c. Anterior: first intercostal muscle, serratus anterior muscle
 - d. Posterior: suprapleural membrane
3. Divide anterior (costal cartilage) and posterior ends of the first rib.
4. Remove first rib from chest cavity.

Notes

- It is important to be meticulous with dissection to avoid nerve injury or bleeding during this operation. The phrenic nerve lies on the anterior surface of the anterior scalene muscle. The long thoracic nerve lies along the chest wall. The brachial plexus passes through the thoracic outlet.
- Perform physical examination including bilateral hand and arm sensory/motor evaluations before and after surgery.

Thymectomy. Thymectomy⁴¹ is the mainstay treatment for thymic epithelial tumors (eg, thymoma and thymic carcinoma), which are staged using a TNM system.^{20,42} Thymectomy is also an aspect of a multimodal treatment approach for myasthenia gravis, which includes anticholinesterase inhibitors (eg, pyridostigmine) and immunosuppressive treatment (eg, corticosteroids, azathioprine, cyclosporine).⁴³ The operation may be performed via open approach through a sternotomy or partial sternotomy, via minimally invasive thoracoscopic or robotic approaches from either the left or the right chest, or via a cervical approach. Choice in approach depends on the patient's disease type, extent of disease, and surgeon preference.

Operative Sequence

1. Place a double-lumen ETT for single-lung ventilation.
2. Positioning: supine
 - a. Depending on surgeon preference, the right or left shoulder may be elevated with a small pad or folded blanket; or, a standard shoulder roll may be placed for a sternotomy approach.

3. Exposure: median sternotomy, VATS, robot-assisted, or cervical approach.
4. Access the anterior mediastinum and perform thymic dissection.
 - a. Generally, begin inferiorly at the diaphragm.
 - b. Extend to the innominate vein superiorly and just medial to phrenic nerves bilaterally.
 - c. It is important that one completely remove the horns of the thymus (cephalad) to ensure a complete resection for both treatment of myasthenia gravis and thymectomy due to possible residual tumor cell nests persisting in remnant thymic tissue.
5. Drain chest with chest tube.
6. Reapproximate sternum or close chest.

Notes

- Hemodynamic compromise may occur with dissection along the anterior aspect of the heart.
- Potential damage to nearby structures includes vascular injury and injury to/division of the phrenic nerve.
- Inadequate resection occurs when residual thymic tissue is left in the chest.

Lung transplantation. The selection of candidates for lung transplantation⁴⁴ is a multidisciplinary process that involves evaluation of medical, psychosocial, and surgical candidacy for transplantation, the details of which are beyond the scope of this primer.⁴⁵ According to the most recent guidelines from the International Society for Heart and Lung Transplantation (ISHLT),⁴⁶ lung transplantation is indicated in adults with lung disease who meet the criteria listed to follow.

ISHLT Criteria For Lung Transplantation in Adults With Lung Disease⁴⁶

1. High (>50%) risk of death from lung disease within 2 years if lung transplantation is not performed.
2. High (>80%) likelihood of surviving at least 90 days after lung transplant.
3. High (>80%) likelihood of 5-year posttransplant survival from a general medical perspective provided there is adequate graft function.

The most common indications for lung transplants based on the ISHLT registry from 1995 to 2015 are chronic obstructive pulmonary disease, interstitial lung disease, bronchiectasis, and pulmonary arterial hypertension.⁴⁷ The Organ Procurement Transplantation Network optimizes match between donors and recipients to optimize lung allocation nationally through a process called Lung Continuous Distribution.⁴⁸ Median survival after lung transplantation based on the ISHLT registry from 1990 to 2014 is 5.8 years.⁴⁹ Use of single-lung and

double-lung transplantation is based on optimizing patient outcome and based on recipient factors such as disease process and age. Certain patients may require, and are candidates for, combined heart-lung transplantation. Additionally, the use of extracorporeal circulatory support (eg, venovenous or venoarterial extracorporeal membrane oxygenation and full cardiopulmonary bypass) varies based on patient circumstance and institutional practice.⁴⁴

Operative Sequence

1. Intubate with a dual-lumen ETT (with subsequent confirmatory bronchoscopy) to allow for isolated single-lung ventilation.
2. Positioning: varies with institution/surgeon preference as well as incision/operative approach.
 - a. Supine with arms abducted and attached to support pad above the head (to maximize exposure to the chest).
 - b. Supine with arms adducted and tucked.
3. Approach: Posterolateral thoracotomy, median sternotomy, bilateral anterior thoracotomy, or clamshell (ie, bilateral anterior thoracotomy with transverse sternotomy) incisions.
4. Perform native lung pneumonectomy one side at a time: proceed circumferentially around the hilum while avoiding the phrenic, vagus, and recurrent laryngeal nerves.
5. Sequentially ligate the pulmonary artery (PA), pulmonary vein, and main bronchus.
 - a. ±Extracorporeal circulatory support for excessive PA pressure rise and/or signs of cardiovascular collapse.
6. Prepare the donor lung allograft for transplantation (ie, “back table preparation” of the lung allograft).
 - a. Perform back-table retrograde flush of pulmonary veins using lung preservative solution.
 - b. Inspect for procurement injury and residual thrombus in pulmonary vasculature.
 - c. Dissect the hilar structures preserving a common cuff of the superior and inferior pulmonary veins, mobilize the pulmonary artery, and divide the stapled off bronchus to be a few rings above the secondary carina. Suction out the allograft to evacuate mucus.
 - d. Augment the PA, pulmonary vein, and main bronchus as necessary.
7. Hilar anastomosis: perform in a posterior-to-anterior sequence.
 - a. Anastomose lung allograft bronchus and recipient bronchus.
 - b. Anastomose lung allograft pulmonary vein cuff to recipient left atrial cuff.
 - c. Anastomose lung allograft PA and recipient PA.
8. Ventilate and reperfuse the newly implanted graft.
9. Perform contralateral lung transplant if performing double lung transplant.
10. ±Wean cardiopulmonary bypass and decannulate (if applicable).
11. Place chest tubes and perform bronchoscopy (to evaluate integrity of anastomosis and remove pulmonary secretions).

Notes

- It is important to be aware of potential complications after lung transplant,⁵⁰ which include the following:
 - Primary graft dysfunction: acute lung injury with presentation similar to acute respiratory distress syndrome within the first 72 hours after lung transplantation.⁵¹
 - Acute and chronic lung transplant rejection.
 - Airway and vascular anastomotic complications such as dehiscence or stenosis.
 - Pleural complications (eg, postoperative hemorrhage, effusions, pneumothorax, bronchopleural fistula, etc).
 - Nerve injury during hilar dissection.
 - Phrenic nerve injury → diaphragmatic dysfunction.
 - Vagus nerve injury → gastroparesis.
 - Recurrent laryngeal nerve injury → voice hoarseness, high risk of aspiration.
 - Bacterial, fungal, and viral infection.
 - Size mismatch: If the lung graft is oversized, an anatomic lung resection can be performed on the back table. If appreciated after implantation, a wedge resection can be performed with focus on the lingula and right middle lobes.

References

1. Ford MK, Beattie WS, Wijeyesundera DN. Systematic review: prediction of perioperative cardiac complications and mortality by the revised cardiac risk index. *Ann Intern Med.* 2010;152:26-35. <https://doi.org/10.7326/0003-4819-152-1-201001050-00007>
2. Khaneki S, Bronsert MR, Henderson WG, Yazdanfar M, Lambert-Kerzner A, Hammermeister KE, et al. Comparison of accuracy of prediction of postoperative mortality and morbidity between a new, parsimonious risk calculator (SURPAS) and the ACS Surgical Risk Calculator. *Am J Surg.* 2020;219:1065-72. <https://doi.org/10.1016/j.amjsurg.2019.07.036>
3. US Preventive Services Task Force. Screening for lung cancer: US preventive services task force recommendation statement. *JAMA.* 2021;325:962-70.
4. Kinahan PE, Fletcher JW. Positron emission tomography-computed tomography standardized uptake values in clinical practice and assessing response to therapy. *Semin Ultrasound CT MR.* 2010;31:496-505. <https://doi.org/10.1053/j.sult.2010.10.001>
5. Sharma S, Hashmi MF, Bhattacharya PT. Hypotension. In: StatPearls [internet]. StatPearls Publishing; 2022.
6. Sapra A, Malik A, Bhandari P. Vital sign assessment. In: StatPearls [internet]. StatPearls Publishing; 2022.
7. Hafen BB, Sharma S. Oxygen saturation. In: StatPearls [internet]. StatPearls Publishing; 2022.

8. Yang KL, Tobin MJ. A prospective study of indexes predicting the outcome of trials of weaning from mechanical ventilation. *N Engl J Med.* 1991;324:1445-50. <https://doi.org/10.1056/NEJM199105233242101>
9. Merck Manuals. Global medical knowledge; 2022. <https://www.merckmanuals.com/professional/resources/global-medical-knowledge>
10. Covington EW, Roberts MZ, Dong J. Procalcitonin monitoring as a guide for antimicrobial therapy: a review of current literature. *Pharmacotherapy.* 2018; 38:569-81. <https://doi.org/10.1002/phar.2112>
11. Hébert PC, Wells G, Blajchman MA, et al. A multicenter, randomized, controlled clinical trial of transfusion requirements in critical care. Transfusion Requirements in Critical Care Investigators, Canadian Critical Care Trials Group [published correction appears in *N Engl J Med.* 1999;340:1056]. *N Engl J Med.* 1999;340:409-17. <https://doi.org/10.1056/NEJM199902113400601>
12. Antinone RN, Kress T. Measuring serum lactate. *Nursing Crit Care.* 2009;4:56.
13. Centers for Disease Control and Intervention. Hydration status; 2022. https://www.cdc.gov/dengue/training/cme/ccm/Hydration%20Status_F.pdf
14. Castro D, Patil SM, Keenaghan M. Arterial blood gas. In: StatPearls [Internet]. StatPearls Publishing; 2022.
15. Ress KL, Koerbin G, Li L, Chesher D, Bwititi P, Horvath AR. Reference intervals for venous blood gas measurement in adults. *Clin Chem Lab Med.* 2020;59:947-54. <https://doi.org/10.1515/ccml-2020-1224>
16. JTCVS Techniques. Accessed April 1, 2023. <https://www.jtcvstechniques.org/>
17. Skills. The Modern Surgeon; 2022. Accessed April 1, 2023. <https://www.themodernsurgeon.org/>
18. Yan TD. Surgical atlas of thoracoscopic lobectomy and segmentectomy. *Ann Cardiothorac Surg.* 2014;3:183-91. <https://doi.org/10.3978/j.issn.2225-319X.2014.03.11>
19. Roy P. Preoperative pulmonary evaluation for lung resection. *J Anaesthesiol Clin Pharmacol.* 2018;34:296-300. https://doi.org/10.4103/joacp.JOACP_89_17
20. National Comprehensive Cancer Network; 2023. Accessed April 1, 2023. <https://www.nccn.org/>
21. Vlahos I, Stefanidis K, Sheard S, Nair A, Sayer C, Moser J. Lung cancer screening: nodule identification and characterization. *Transl Lung Cancer Res.* 2018;7:288-303. <https://doi.org/10.21037/tlcr.2018.05.02>
22. Luh SP. Diagnosis and treatment of primary spontaneous pneumothorax. *J Zhejiang Univ Sci B.* 2010;11:735-44. <https://doi.org/10.1631/jzus.B1000131>
23. Mitchell JD. Surgical treatment of pulmonary nontuberculous mycobacterial infections. *Thorac Surg Clin.* 2019;29:77-83. <https://doi.org/10.1016/j.thorsurg.2018.09.011>
24. Mountain CF, Dresler CM. Regional lymph node classification for lung cancer staging. *Chest.* 1997;111:1718-23. <https://doi.org/10.1378/chest.111.6.1718>
25. Duan J, Cai H, Huang W, Lin L, Wu L, Fan J. Bronchial sleeve resection with complete pulmonary preservation: a single-center experience. *Cancer Manag Res.* 2020;12:12975-82. <https://doi.org/10.2147/CMAR.S286934>
26. Maurizi G, Ibrahim M, Andreotti C, D'Andrilli A, Ciccone AM, Pomes LM, et al. Long-term results after resection of bronchial carcinoid tumour: evaluation of survival and prognostic factors. *Interact Cardiovasc Thorac Surg.* 2014;19:239-44. <https://doi.org/10.1093/icvts/ivv109>
27. Maurizi G, D'Andrilli A, Venuta F, Rendina EA. Bronchial and arterial sleeve resection for centrally-located lung cancers. *J Thorac Dis.* 2016;8:S872-81. <https://doi.org/10.21037/jtd.2016.06.48>
28. Petrov RV, Su S, Bakhos CT, Abbas AES. Surgical anatomy of paraesophageal hernias. *Thorac Surg Clin.* 2019;29:359-68. <https://doi.org/10.1016/j.thorsurg.2019.07.008>
29. Sfara A, Dumitraşcu DL. The management of hiatal hernia: an update on diagnosis and treatment. *Med Pharm Rep.* 2019;92:321-5. <https://doi.org/10.15386/mpr-1323>
30. Frazzoni M, Piccoli M, Conigliaro R, Frazzoni L, Melotti G. Laparoscopic fundoplication for gastroesophageal reflux disease. *World J Gastroenterol.* 2014;20:14272-9. <https://doi.org/10.3748/wjg.v20.i39.14272>
31. Flanagan JC, Batz R, Saboo SS, Nordeck SM, Abbara S, Kernstine K, et al. Esophagectomy and gastric pull-through procedures: surgical techniques, imaging features, and potential complications. *Radiographics.* 2016;36:107-21. <https://doi.org/10.1148/rg.2016150126>
32. Patel AN, Preskitt JT, Kuhn JA, Hebel RF, Wood RE, Urschel HC. Surgical management of esophageal carcinoma. *Proc (Bayl Univ Med Cent).* 2003;16:280-4. <https://doi.org/10.1080/08998280.2003.11927914>
33. Lekakos L, Karidis NP, Dimitroulis D, Tsigris C, Kouraklis G, Nikiteas N. Barrett's esophagus with high-grade dysplasia: focus on current treatment options. *World J Gastroenterol.* 2011;17:4174-83. <https://doi.org/10.3748/wjg.v17.i37.4174>
34. Bakshi A, Sugarbaker DJ, Burt BM. Alternative conduits for esophageal replacement. *Ann Cardiothorac Surg.* 2017;6:137-43. <https://doi.org/10.21037/acs.2017.03.07>
35. Donahue DM. Supraclavicular first rib resection. *Operat Tech Thorac Cardiovasc Surg.* 2011;16:252-66. <https://doi.org/10.1053/j.otechstcvs.2012.02.001>
36. Ciampi P, Scotti C, Gerevini S, De Cobelli F, Chiesa R, Fracchini G, et al. Surgical treatment of thoracic outlet syndrome in young adults: single centre experience with minimum three-year follow-up. *Int Orthop.* 2011;35:1179-86. <https://doi.org/10.1007/s00264-010-1179-1>
37. Levine N, Rigby B. Thoracic outlet syndrome: biomechanical and exercise considerations. *Healthcare (Basel).* 2018;6:68. <https://doi.org/10.3390/healthcare6020068>
38. Torriani M, Gupta R, Donahue DM. Botulinum toxin injection in neurogenic thoracic outlet syndrome: results and experience using an ultrasound-guided approach. *Skeletal Radiol.* 2010;39:973-80. <https://doi.org/10.1007/s00256-010-0897-1>
39. Rehemutula A, Zhang L, Yu C, Chen L, Gu Y. Thoracoscopy-assisted first rib resection for the treatment of thoracic outlet syndrome caused by fibrous dysplasia: a report of two cases. *Exp Ther Med.* 2015;9:2241-4. <https://doi.org/10.3892/etm.2015.2371>
40. Serna-Gallegos D, Soukiasian HJ. Minimally invasive first rib resection: a technique that is here to stay. *J Thorac Dis.* 2017;9:E91-2. <https://doi.org/10.21037/jtd.2017.01.39>
41. Remien K, Jan A. Anatomy, head and neck, thymus. In: StatPearls. StatPearls Publishing; 2022.
42. Funaki S, Shintani Y, Fukui E, Kanzaki R, Kanou T, Ose N, et al. Surgical treatment strategies for invasive thymoma. *J Thorac Dis.* 2020;12:7619-25. <https://doi.org/10.21037/jtd-19-3045>
43. Aydin Y, Ulas AB, Mutlu V, Colak A, Eroglu A. Thymectomy in myasthenia gravis. *Eurasian J Med.* 2017;49:48-52. <https://doi.org/10.5152/eurasianjmed.2017.17009>
44. Hayanga JWA, D'Cunha J. The surgical technique of bilateral sequential lung transplantation. *J Thorac Dis.* 2014;6:1063-9. <https://doi.org/10.3978/j.issn.2072-1439.2014.07.02>
45. Weill D. Lung transplantation: indications and contraindications. *J Thorac Dis.* 2018;10:4574-87. <https://doi.org/10.21037/jtd.2018.06.141>
46. Weill D, Benden C, Corris PA, Dark JH, Davis RD, Keshavjee S, et al. A consensus document for the selection of lung transplant candidates: 2014—an update from the Pulmonary Transplantation Council of the International Society for Heart and Lung Transplantation. *J Heart Lung Transplant.* 2015;34:1-15. <https://doi.org/10.1016/j.healun.2014.06.014>
47. Shweish O, Dronavalli G. Indications for lung transplant referral and listing. *J Thorac Dis.* 2019;11:S1708-20. <https://doi.org/10.21037/jtd.2019.05.09>
48. OPTN Lung Transplantation Committee. Establish continuous distribution of lungs; 2021. Accessed April 1, 2023. https://optn.transplant.hrsa.gov/media/4772/continuous_distribution_of_lungs-public_comment.pdf
49. Thabut G, Mal H. Outcomes after lung transplantation. *J Thorac Dis.* 2017;9:2684-91. <https://doi.org/10.21037/jtd.2017.07.85>
50. Garrido G, Dhillon GS. Medical course and complications after lung transplantation. In: Sher Y, Maldonado JR, eds. *Psychosocial Care of End-Stage Organ Disease and Transplant Patients.* Springer International Publishing; 2019:279-88.
51. Lee JC, Christie JD. Primary graft dysfunction. *Clin Chest Med.* 2011;32:279-93. <https://doi.org/10.1016/j.ccm.2011.02.007>

APPENDIX 1. HAND-OFF TEMPLATES

A. Template: Hand-Off to the Night Team

- One liner: [Name] is a [X] month/y old [sex] who underwent [operation], postoperative day #X.
- Any significant events during the day that could influence further management.
- Anticipatory guidance: If [X] happens, page [this team/fellow/attending], and order [labs/imaging/meds].
- Specific tasks to follow up on: wean nasal cannula to X, follow up hemoglobin overnight, etc.

B. Template: Operating Room (OR) to Postanesthesia Care Unit (PACU) Hand-Off

- One liner: [Name] is a [X] month/y old [sex] who underwent [procedure]

- Intraoperative findings, complications, significant events: [if relevant]
- Lines/drains
- Chest tubes + locations
- Number of incisions + manner in which they are closed (primarily, secondary intention, left open, etc)
- Labs/imaging needed in the PACU prior [if relevant]
- (Advanced) Specific things for the PACU team to watch out for, with suggested plans. Examples below:
 - (After first rib resection) Keep an eye out for neurologic deficits/severe pain in upper extremity, notify team if present
- Plan for the next phase of care (eg, patient going to the floor with telemetry monitoring, ability to transport the patient with the chest tube off suction)