

Received: 2014.01.13
Accepted: 2014.01.14
Published: 2014.04.08

Prediction of axillary lymph node metastases in breast cancer patients based on pathologic information of the primary tumor

Authors' Contribution:
Study Design A
Data Collection B
Statistical Analysis C
Data Interpretation D
Manuscript Preparation E
Literature Search F
Funds Collection G

ABDE 1,2 **Jia-Long Wu***
BCDE 1,2,3 **Hsin-Shun Tseng***
ABCF 2 **Li-Heng Yang**
ABCD 4 **Hwa-Koon Wu**
ABCD 1,2,5 **Shou-Jen Kuo**
BCD 1,2 **Shou-Tung Chen**
ABDE 1,2,3,5 **Dar-Ren Chen**

1 Comprehensive Breast Cancer Center, Changhua Christian Hospital, Changhua, Taiwan
2 Department of Surgery, Changhua Christian Hospital, Changhua, Taiwan
3 Department of Medical Research, Changhua Christian Hospital, Changhua, Taiwan
4 Department of Medical Imaging, Changhua Christian Hospital, Changhua, Taiwan
5 School of Medicine, Chung Shan Medical University, Taichung City, Taiwan

* Equal contribution

Corresponding Author: Dar-Ren Chen, e-mail: darren_chen@cch.org.tw
Source of support: Self financing

Background: Axillary lymph nodes (ALN) are the most commonly involved site of disease in breast cancer that has spread outside the primary lesion. Although sentinel node biopsy is a reliable way to manage ALN, there are still no good methods of predicting ALN status before surgery. Since morbidity in breast cancer surgery is predominantly related to ALN dissection, predictive models for lymph node involvement may provide a way to alert the surgeon in subgroups of patients.





Material/Methods: A total of 1325 invasive breast cancer patients were analyzed using tumor biological parameters that included age, tumor size, grade, estrogen receptor, progesterone receptor, lymphovascular invasion, and HER2, to test their ability to predict ALN involvement. A support vector machine (SVM) was used as a classification model. The SVM is a machine-learning system developed using statistical learning theories to classify data points into 2 classes. Notably, SVM models have been applied in bioinformatics.

Results: The SVM model correctly predicted ALN metastases in 74.7% of patients using tumor biological parameters. The predictive ability of luminal A, luminal B, triple negative, and HER2 subtypes using subgroup analysis showed no difference, and this predictive performance was inferior, with only 60% accuracy.

Conclusions: With an SVM model based on clinical pathologic parameters obtained in the primary tumor, it is possible to predict ALN status in order to alert the surgeon about breast cancer counseling and in decision-making for ALN management.

MeSH Keywords: **Metastasis, Lymphatic • Breast Carcinoma • Support Vector Machine • Lymph Node • Sentinel Lymph Node Biopsy**

Full-text PDF: <http://www.medscimonit.com/download/index/idArt/890345>

 1423  3  1  35

Background

Axillary lymph nodes (ALN) are the most commonly involved site of disease in breast cancer that has spread outside the primary lesion. ALN status plays an important prognostic role in female invasive breast cancer [1–4]. For tumor staging and treatment, complete ALN dissection (ALND) was a standard surgical approach in the early 20th century. However, ALND was accompanied with some troublesome clinical problems; morbidities including lymphedema, paresthesias, and major nerve and vessel injury are well-documented [5–7]. These problems led physicians to seek alternative approaches in the assessment of ALN status.

The sentinel lymph node is the primary site of ALN metastasis (ALNM) from breast cancer. The concept of the sentinel lymph node was applied in penile carcinoma in the 1970's [8], and was soon applied to breast cancer. Patients gained benefit from sentinel lymph node biopsy (SLNB) in terms of surgical morbidities and accurate tumor staging [9]. Today, SLNB is a reliable and standard method in the assessment of axillary status in early invasive breast cancer [10]. However, there are still no good methods to predict ALN status before surgery. Since morbidity in breast cancer surgery is predominantly related to ALND, predictive models for lymph node involvement may provide a way to alert the surgeon in subgroups of patients. The primary aim of this study was to determinate the predictive factors of ALN metastasis using pathologic information.

Material and Methods

Patient population, data collection, and definition of cases

This was a retrospective study of female patients with invasive breast cancer at Changhua Christian Hospital between January 2004 and January 2010. The clinical data and tumor characteristics for all invasive breast cancers had been collected in our breast cancer database. This study was approved by the institutional review board and ethics committee of Changhua Christian Hospital. Breast cancer patients who had undergone surgery were identified. The exclusion criteria were: 1) ductal carcinoma *in situ*; 2) neoadjuvant therapy; 3) bilateral invasive breast cancer; and 4) patients without breast-conserving surgery with ALND or sentinel lymph node sampling or modified radical mastectomy.

The clinical characteristics assessed were age at diagnosis, tumor size, positive lymph node, histology grade, estrogen receptor (ER) status, progesterone receptor (PR) status, human epidermal growth factor receptor 2 (HER2) status, and the presence of lymphovascular invasion (LVI). All information was retrospectively analyzed so as to identify patients who might have had a risk of ALN metastasis pre-operatively.

Statistical analysis

The support vector machine (SVM) is a statistical learning theory developed to classify data points into 2 classes [11,12]. SVMs are powerful statistical methods in classification. This study utilized the SVM system to classify the axillary status of breast cancer. The pathologic features of a primary breast tumor were formed into a multi-dimensional feature vector, and then used as the input signals for the SVM classifier. When the output value of a patient was greater than or equal to zero, the CAD system would diagnose the patient as having positive ALNM. Conversely, when the output value was smaller than zero, the case would be classified as negative ALNM. The performance measure, which was the receiver operating characteristic curve (ROC) analysis, was used to estimate the performance of the proposed system. The Az value (area under the ROC) was used to evaluate the significance of each clinical feature.

Results

A total of 1325 patients with a mean age of 51 years (SD=11.2) were included in this study. Of these, 742 patients had positive ALNM. The mean tumor size was 24.4 mm (SD=1.5); 39% of the patients had T1 tumors (< 20 mm), followed by 54% with T2 tumors and 7% with T3 tumors. The histology grade was predominantly grade II (55%), with 28% grade III and 17% grade I tumors. Lymphovascular invasion was found in 573 patients (43%). The ER/PR/HER2 profile showed 847 patients (63.9%) had luminal A type tumors, followed by 16.1% with triple-negative tumors, 13.1% with luminal B type tumors, and 6.9% with HER2-positive tumors. Relevant details of this study population are listed in Table 1.

Table 2 presents the observed results of SVM classification. Discordant results were noted between SVM and pathology reports in 341 cases; 141 out of 583 patients were positive for ALNM but were classified as negative, and 200 out of 742 negative ALNM patients were classified as positive for ALNM by SVM. The sensitivity and specificity were 76% and 73%, respectively. The positive predictive value was 69% and negative predictive value was 79%. The accuracy rate was 74% (Table 3).

ROC curves were used to analyze the diagnostic performance of the SVM by clinical pathology features. The cutoff value to balance sensitivity and specificity was 0.000325182. If the output of SVM was smaller than 0.000325182, then it was defined as negative for ALNM, and values greater than or equal to 0.000325182 were classified as positive axillary nodal status. A higher Az value indicated a better diagnostic performance. The Az value of this study was 0.7682 by SVM (Figure 1).

Table 1. Characteristics and tumor features of breast cancer patients.

Variables	Axillary lymph node metastases					
	Negative (N=742)		Positive (N=583)		Total (N=1,325)	
Age, mean (SD)	51.12	(11.06)	51.43	(11.38)	51.25	(11.20)
Clinical factors						
Tumor size, mean (SD)	2.08	(1.164)	2.91	(1.659)	24.44	(1.461)
<2 cm	356	(47.98)	159	(27.27)	515	(38.87)
2–5 cm	356	(47.98)	360	(61.75)	716	(54.04)
≥5 cm	30	(4.04)	64	(10.98)	94	(7.09)
Grade						
1	143	(19.27)	72	(12.35)	215	(16.23)
2	415	(55.93)	320	(54.89)	735	(55.47)
3	184	(24.80)	191	(32.76)	375	(28.30)
Pathological factors						
Estrogen receptor						
Negative	256	(34.50)	177	(30.36)	433	(32.68)
Positive	486	(65.50)	406	(69.64)	892	(67.32)
Progesterone receptor						
Negative	291	(39.22)	183	(31.39)	474	(35.77)
Positive	451	(60.78)	400	(68.61)	851	(64.23)
HER2						
Negative	616	(83.02)	444	(76.16)	1,060	(80.00)
Positive	126	(16.98)	139	(23.84)	265	(20.00)
ER/PR/Her2 profile						
Triple negative						
No	598	(80.59)	514	(88.16)	1112	
Yes	144	(19.41)	69	(11.84)	213	
HER2-positive						
No	692		542		1234	
Yes	50		41		91	
Luminal A						
No	270		208		478	
Yes	472		375		847	
Luminal B						
No	666		485		1151	
Yes	76		98		174	
Lymphovascular invasion (LVI)						
No	585	(78.84)	167	(28.64)	752	(56.75)
Yes	157	(21.16)	416	(71.36)	573	(43.25)

Table 2. Observed results in this study.

		Axillary lymph node metastases		
		Positive	Negative	Total
SVM	Positive	442	200	642
	Negative	141	542	683
	Total	583	742	1325

Table 3. SVM results.

	%	95% CI	
Sensitivity	75.81	0.72338798	0.792907046
Specificity	73.05	0.698530725	0.762385717
Positive predictive value	68.85	0.65264906	0.724297981
Negative predictive value	79.36	0.763202555	0.823913111
Accuracy	74.26	0.71910148	0.766181538

Discussion

Complete ALND is an important procedure in cancer staging and local control of disease. However, ALND has some unfavorable complications, including numbness, lymphedema, and major vessel and nerve injury [13–15]. Nowadays, SLNB plays an important role in evaluating axillary nodal status. The greatest benefits of SLNB are its effectiveness and low number of operative complications. Patients with a small tumor might benefit from SLNB. In fact, SLNB is routinely performed in clinically axillary nodal-negative patients.

Primary pathologic characteristics and clinical features are useful in the assessment of axillary nodal involvement [14–16]. Our objective was to clarify the relationship between pathologic characteristics and ALNM. Based on our previous research [17–19], the SVM has been found to be a useful diagnostic tool in dealing with binominal data. In this study, we constructed a powerful statistical method with pathologic features, including tumor size, LVI and histology grade, and ER, PR, and HER2 status. The output of SVM in our study was analyzed using the ROC curve, and the diagnostic performance (Az value=0.7682) was acceptable.

There remains much debate about the relationship between pathologic characteristics and ALNM. Barth et al. found that tumor size, LVI, and histology grade were important factors in predicting ALNM [20]. The definition of LVI is the presence of an invasion of cancer cells into the blood vessels or lymphatic channels. Positive LVI is correlated with aggressive tumor

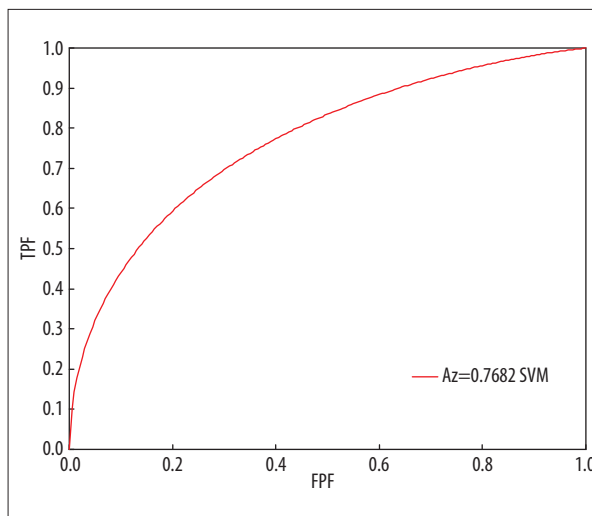


Figure 1. Diagnostic performance of SVM using the ROC curve.

behavior and metastatic ability [21]. LVI has been consistently shown to be predictive of ALNM in many studies [20–29]. The odds ratio (LVI presence vs. negative) is high in extensive axillary nodal involvement. In small invasive breast cancer with negative LVI, the incidence of ALNM is low [22]. The LVI also increases the incidence of non-sentinel lymph node metastases and isolated tumor cells in the sentinel lymph node [29,30]. The presence of LVI as the most important predictor is well accepted. Our study also confirms LVI is the strongest single predictor in ALNM.

Histology grade and tumor size are also important predictors of ALNM. The probability of ALNM is high if a patient has a large tumor and high histology grade. Our data presented in Table 1 reveal that patients with a large tumor (more than 5 centimeters in size) and a high histology grade are more likely to have ALNM, a finding that is consistent with those of previous studies [20,31–33]. Patients with small invasive breast cancer might benefit from SLNB [34]. Our study showed that patients with a tumor less than 2 centimeters in size and a low-to-medium histology grade are good candidates for SLNB.

Regional lymph node status is necessary for tumor staging and surgical planning. Previous studies have found some important factors in predicting ALNM, but the predictive power was not acceptable. With the advances in surgical technique, SLNB is now widely used in early breast cancer and is becoming a standard procedure in clinical ALN-negative patients. The benefits of SLNB are fewer surgical complications than complete ALND and the efficacy and accuracy after long-term follow-up [35]. The importance of SLNB is clear. In this study, the clinical pathologic characteristics were found to be useful in predicting cancer prognosis. We thus offer an auxiliary method in the assessment of axillary status pre-operatively, but not to replace SLNB.

Conclusions

With a model based only on clinical routine pathologic parameters obtained from the primary tumor, it is possible to predict ALN status. This may help the surgeon in breast cancer counseling and decision-making for ALN management.

References:

1. Fisher B, Bauer M, Wickerham DL et al: Relation of number of positive axillary nodes to the prognosis of patients with primary breast cancer. An NSABP update. *Cancer*, 1983; 52: 1551–57
2. NIH consensus conference. Treatment of early-stage breast cancer. *JAMA*, 1991; 265: 391–95
3. Consensus statement: treatment of early-stage breast cancer. National Institutes of Health Consensus Development Panel. *J Natl Cancer Inst Monogr*, 1992; 1–5
4. Silverstein MJ, Gierson ED, Waisman JR et al: Axillary lymph node dissection for T1a breast carcinoma. Is it indicated? *Cancer*, 1994; 73: 664–67
5. Lotze MT, Duncan MA, Gerber LH et al: Early versus delayed shoulder motion following axillary dissection: a randomized prospective study. *Ann Surg*, 1981; 193: 288–95
6. Yeoh EK, Denham JW, Davies SA, Spittle MF: Primary breast cancer. Complications of axillary management. *Acta Radiol Oncol*, 1986; 25: 105–8
7. Ivens D, Hoe AL, Podd TJ et al: Assessment of morbidity from complete axillary dissection. *Br J Cancer*, 1992; 66: 136–38
8. Cabanas RM: An approach for the treatment of penile carcinoma. *Cancer*, 1977; 39: 456–66
9. Lucci A, McCall LM, Beitsch PD et al: Surgical complications associated with sentinel lymph node dissection (SLND) plus axillary lymph node dissection compared with SLND alone in the American College of Surgeons Oncology Group Trial Z0011. *J Clin Oncol*, 2007; 25: 3657–63
10. American Joint Committee on Cancer (2010) *AJCC Cancer Staging Manual*. 7th ed. Springer, New York, NY
11. Kwang In K, Keechul J, Se Hyun P, Hang Joon K: Support vector machines for texture classification. *Pattern Analysis and Machine Intelligence, IEEE Transactions on*, 2002; 24: 1542–50
12. Qing S, Wenjie H, Wenfang X: Robust support vector machine with bullet hole image classification. *Systems, Man, and Cybernetics, Part C: Applications and Reviews, IEEE Transactions on*, 2002; 32: 440–48
13. Silberman AW, McVay C, Cohen JS et al: Comparative morbidity of axillary lymph node dissection and the sentinel lymph node technique: implications for patients with breast cancer. *Ann Surg*, 2004; 240: 1–6
14. Arana S, Vazquez-Del-Aguila J, Espinosa M et al: Lymphatic mapping could not be impaired in the presence of breast carcinoma and coexisting small lymphocytic lymphoma. *Am J Case Rep*, 2013; 14: 322–25
15. Bhosale SJ, Kshirsagar AY, Sulhyan SR, Jagtap SV: Matrix-producing metastatic breast carcinoma - a rare malignancy. *Am J Case Rep*, 2013; 14: 213–15
16. Testori A, Meroni S, Moscovici OC et al: Surgical sentinel lymph node biopsy in early breast cancer. Could it be avoided by performing a preoperative staging procedure? A pilot study. *Med Sci Monit*, 2012; 18(9): CR543–49
17. Chen ST, Hsiao YH, Huang YL et al: Comparative analysis of logistic regression, support vector machine and artificial neural network for the differential diagnosis of benign and malignant solid breast tumors by the use of three-dimensional power Doppler imaging. *Korean J Radiol*, 2009; 10: 464–71
18. Huang YL, Chen DR, Jiang YR et al: Computer-aided diagnosis using morphological features for classifying breast lesions on ultrasound. *Ultrasound Obstet Gynecol*, 2008; 32: 565–72
19. Huang YL, Chen DR: Support vector machines in sonography: application to decision making in the diagnosis of breast cancer. *Clin Imaging*, 2005; 29: 179–84
20. Barth A, Craig PH, Silverstein MJ: Predictors of axillary lymph node metastases in patients with T1 breast carcinoma. *Cancer*, 1997; 79: 1918–22
21. Gurleyik G, Gurleyik E, Aker F et al: Lymphovascular invasion, as a prognostic marker in patients with invasive breast cancer. *Acta Chir Belg*, 2007; 107: 284–87
22. Wong JS, O'Neill A, Recht A et al: The relationship between lymphatic vessel invasion, tumor size, and pathologic nodal status: can we predict who can avoid a third field in the absence of axillary dissection? *Int J Radiat Oncol Biol Phys*, 2000; 48: 133–37
23. Ravdin PM, De Laurentiis M, Vendely T, Clark GM: Prediction of axillary lymph node status in breast cancer patients by use of prognostic indicators. *J Natl Cancer Inst*, 1994; 86: 1771–75
24. Davis BW, Gelber R, Goldhirsch A et al: Prognostic significance of peritumoral vessel invasion in clinical trials of adjuvant therapy for breast cancer with axillary lymph node metastasis. *Hum Pathol*, 1985; 16: 1212–18
25. Tan YY, Wu CT, Fan YG et al: Primary tumor characteristics predict sentinel lymph node macrometastasis in breast cancer. *Breast J*, 2005; 11: 338–43
26. Weiser MR, Montgomery LL, Tan LK et al: Lymphovascular invasion enhances the prediction of non-sentinel node metastases in breast cancer patients with positive sentinel nodes. *Ann Surg Oncol*, 2001; 8: 145–49
27. Turner RR, Chu KU, Qi K et al: Pathologic features associated with nonsentinel lymph node metastases in patients with metastatic breast carcinoma in a sentinel lymph node. *Cancer*, 2000; 89: 574–81
28. Nos C, Harding-MacKean C, Freneau P et al: Prediction of tumour involvement in remaining axillary lymph nodes when the sentinel node in a woman with breast cancer contains metastases. *Br J Surg*, 2003; 90: 1354–60
29. Hwang RF, Krishnamurthy S, Hunt KK et al: Clinicopathologic factors predicting involvement of nonsentinel axillary nodes in women with breast cancer. *Ann Surg Oncol*, 2003; 10: 248–54
30. Mittendorf EA, Sahin AA, Tucker SL et al: Lymphovascular invasion and lobular histology are associated with increased incidence of isolated tumor cells in sentinel lymph nodes from early-stage breast cancer patients. *Ann Surg Oncol*, 2008; 15: 3369–77
31. Rivadeneira DE, Simmons RM, Christos PJ et al: Predictive factors associated with axillary lymph node metastases in T1a and T1b breast carcinomas: analysis in more than 900 patients. *J Am Coll Surg*, 2000; 191: 1–6; discussion 6–8
32. Nixon AJ, Schnitt SJ, Gelman R et al: Relationship of tumor grade to other pathologic features and to treatment outcome of patients with early stage breast carcinoma treated with breast-conserving therapy. *Cancer*, 1996; 78: 1426–31
33. Harden SP, Neal AJ, Al-Nasiri N et al: Predicting axillary lymph node metastases in patients with T1 infiltrating ductal carcinoma of the breast. *Breast*, 2001; 10: 155–59
34. Coombs N, Chen W, Taylor R, Boyages J: A decision tool for predicting sentinel node accuracy from breast tumor size and grade. *Breast J*, 2007; 13: 593–98
35. Veronesi U, Viale G, Paganelli G et al: Sentinel lymph node biopsy in breast cancer: ten-year results of a randomized controlled study. *Ann Surg*, 2010; 251: 595–600

Acknowledgements

Editorial support was provided by Ms. Yu-Fen Wang, M.S.

Conflict of interest statement

None declared.