



Case Report

# Brain abscess caused by *Nocardia thailandica* infection in systemic lupus erythematosus patient with steroid therapy

Ryokichi Yagi<sup>1</sup>, Yukimasa Ooi<sup>2</sup>, Naosuke Nonoguchi<sup>1</sup>, Masahiko Wanibuchi<sup>1</sup>

Departments of <sup>1</sup>Neurosurgery, <sup>2</sup>Infection Control and Prevention, Osaka Medical and Pharmaceutical University, Takatsuki City, Osaka, Japan.

E-mail: \*Ryokichi Yagi - ryokichi.yagi@ompu.ac.jp; Yukimasa Ooi - yukimasa.ooi@ompu.ac.jp; Naosuke Nonoguchi - naosuke.nonoguchi@ompu.ac.jp; Masahiko Wanibuchi - wanibuchi@ompu.ac.jp



\*Corresponding author:

Ryokichi Yagi,  
Department of Neurosurgery,  
Osaka Medical and  
Pharmaceutical University,  
Takatsuki City, Osaka, Japan.

ryokichi.yagi@ompu.ac.jp

Received : 19 January 2022

Accepted : 06 March 2022

Published : 08 April 2022

DOI:

10.25259/SNI\_78\_2022

Quick Response Code:



## ABSTRACT

**Background:** *Nocardia* is an aerobic Gram-negative bacillus belonging to actinomycetes and has been reported to be an infectious disease in healthy individuals. However, more than 60% have some underlying illnesses and are said to be opportunistic infections.

**Case Description:** The case was a 69-year-old man who had been on long-term steroids for systemic lupus erythematosus. He developed with nausea and gait disturbance and was suspected of having a brain abscess by imaging. Abscess drainage detects actinomycetes that appear to belong to the genus *Nocardia* and brain abscess by *Nocardia thailandica* using matrix-assisted laser desorption/ionization time-of-flight mass analysis (MALDI-TOFMS) I was diagnosed. He died during the course of the treatment, and his organs did not detect his *N. thailandica* at necropsy, so he concluded that bacterial death from long-term administration of antibiotics was the cause of death.

**Conclusion:** *N. thailandica* is a very rare bacterium belonging to *Nocardia asteroides* and is said to easily form brain lesions. In immunocompromised patients, prophylaxis with antibiotics and detailed examination of lung lesions for surveillance were considered necessary. This paper is the first report of a brain abscess caused by *N. thailandica*, including a review of the literature.

**Keywords:** Brain abscess, Long-term steroid therapy, *Nocardia thailandica*, *Nocardia*, Systemic lupus erythematosus

## INTRODUCTION

Opportunistic infections occur more frequently, or are more severe, in people with weakened immune systems (such as people with HIV); these can be life-threatening and cause severe complications in patients receiving long-term treatment with immunosuppressants and steroids. *Nocardia*, a naturally occurring actinomycete, cannot be detected by culture tests and, thus, requires genetic analysis. In human, almost 90% of *Nocardia* infections are caused by the *Nocardia asteroides* group. *Nocardia thailandica* is an extremely rare bacterium related to *Nocardia asteroides*. Of note, *N. thailandica* drug sensitivity is relatively good, and its standard treatments are  $\beta$ -lactam antibiotics, sulfamethoxazole/trimethoprim (ST) combination, tetracycline, and macrolides. To the best of our knowledge, this is the first clinical report of an *N. thailandica*-

This is an open-access article distributed under the terms of the Creative Commons Attribution-Non Commercial-Share Alike 4.0 License, which allows others to remix, transform, and build upon the work non-commercially, as long as the author is credited and the new creations are licensed under the identical terms.

©2022 Published by Scientific Scholar on behalf of Surgical Neurology International

associated brain abscess. In our case, after the diagnosis of an *N. thailandica*-associated brain abscess, the original disease was ameliorated by the administration of antibiotics; however, the patient died from microbial substitution caused by prolonged administration of antibiotics.

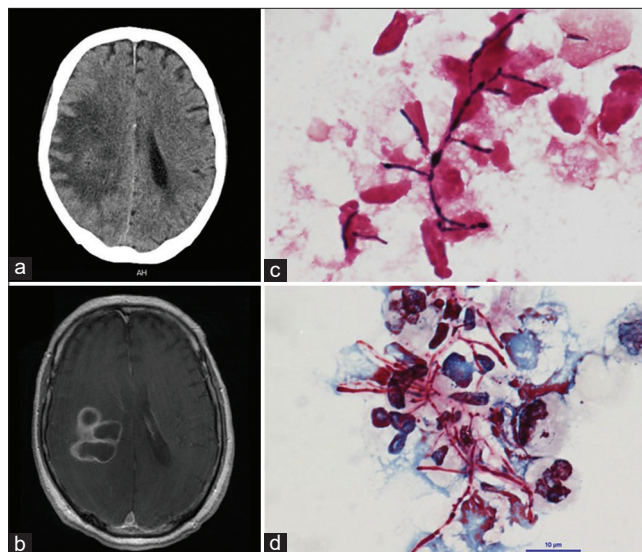
## CASE REPORT

A 69-year-old male with systemic lupus erythematosus (SLE) presented with a chief complaint of nausea and gait disorder. The patient's eldest daughter also had SLE. He had no smoking history, no drinking, no travel history, no outdoor activities, and no sexual activity.

The patient's present medical history was as follows. The patient became aware of dyspnea and edema of the lower extremities during exercise; thus, he consulted a family doctor. The examination revealed hypertension, proteinuria, and hematuria. A chest X-ray revealed bilateral pleural effusion. Because of an increase in antinuclear antibodies (Anti-ds-DNA antibody 218.5) and a decline in complement (C3 51 and C4 12.3), a connective tissue disease was suspected, and the patient was referred to our Department of Rheumatic Collagen Disease. After 2 months, he was hospitalized for examination and diagnosed with SLE because of (i) renal lesions, (ii) leukopenia, (iii) positive anti-ds-DNA antibody, and (iv) positive antinuclear antibody. Based on the renal biopsy results 2 months later, he was diagnosed with lupus nephritis Class IV. Accordingly, steroid pulse therapy (methylprednisolone, 1000 mg) and tacrolimus (2 mg/day) were initiated intravenously. As SLE and lupus nephritis improved, the patient received prednisolone (25 mg/day) + tacrolimus (2 mg/day) + azathioprine (100 mg/day) orally and was discharged after 6 months. He returned for follow-up as an outpatient.

After 1 year, the patient visited a family doctor for nausea and dizziness. A brain computed tomography (CT) revealed a multilocular cystic lesion with edema. Thus, he was referred to our department for neurosurgery.

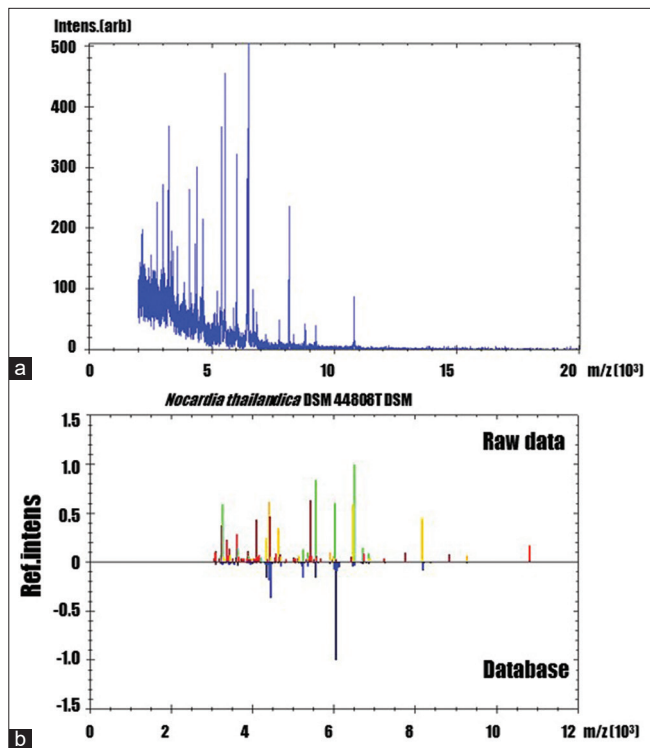
On day 1 of admission, the initial brain CT in the axial plane shows the low-density area in the right parietal lobe [Figure 1a]. Moreover, we suspected a cerebral abscess because a multilocular cystic lesion, which was imaged in a ring shape, was observed on the enhanced T1-weighted magnetic resonance imaging axial image [Figure 1b]. On day 10 of admission, the cranial brain abscess was excised by burr hole surgery used by stereotactic techniques, and intravenous meropenem (MEPM; 1 g TID) + vancomycin (0.5 g BID) was started postoperatively. Of note, Gram-positive bacilli, suspected to be actinomycetes, were detected in the puncture fluid collected intraoperatively. Since the culture specimen was positive for Kinyoun staining, Gram-positive bacilli were found to belong to the *Nocardia* genus



**Figure 1:** (a) Preoperative the brain CT in the axial plane shows the low-density area in the right parietal lobe. (b) The enhanced T1-weighted MRI axial image revealed that polycystic ring-enhancing lesions with surrounding vasogenic edema in the right parietal lobe. (c) Gram stain for brain pus showing Gram-positive actinomycetes with beaded staining pattern. ( $\times 1000$ ). (d) Kinyoun smear stain showing a cluster of filamentous branching rods that are partially acid fast, which is characteristic for *Nocardia* ( $\times 1000$ ).

[Figures 1c and d]. On day 15 of admission, vancomycin was discontinued because it was later determined as *N. thailandica* based on the 16S rRNA sequence and matrix-assisted laser desorption ionization time-of-flight mass spectrometry [MALDI-TOFMS; Figures 2a and b]. The change to an ST combination was considered, but the patient had an allergic function. Hence, intravenous MEPM (1 g TID) was continued. On day 20 of admission, a blood test revealed improved inflammatory response, but renal function had deteriorated, resulting in decreased MEPM (1 g BID).

The patient remained hospitalized for 30 days without further deterioration of renal function; however, consciousness disorder appeared because of deteriorating central nervous system lupus. Consequently, oral administration became difficult; thus, we switched to ceftriaxone (CTRX; 2 g BID) intravenously. A brain CT revealed that the brain abscess had decreased gradually. The treatment of the abscess and SLE was progressing smoothly. However, on day 77 of admission, the patient developed a catheter-associated urinary tract infection and catheter-associated bloodstream infection due to *Corynebacterium striatum* and extended spectrum  $\beta$ -lactamase *Escherichia coli*. Gradually, the patient's condition worsened and he died 86 days after admission. After death, a pathological autopsy was performed with the approval of the patient's family. We established the formation of microabscesses in the lungs, mitral valve, liver, and kidneys;

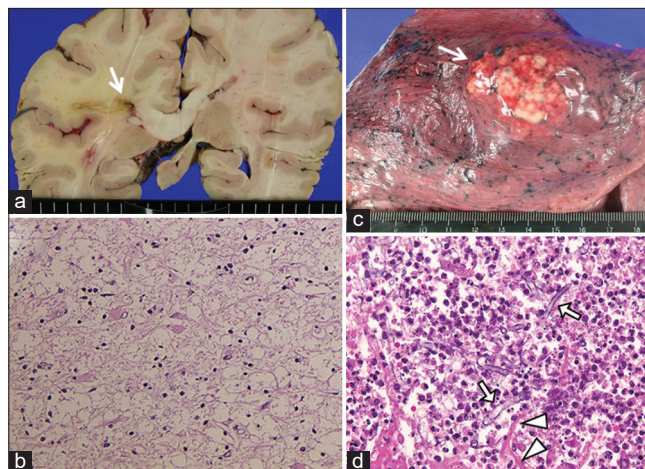


**Figure 2:** (a) MALDI-TOF mass spectra of the extract from a patient's abscess (b): *Nocardia thailandica* (identification score: 1.731) The comparison between the raw MALDI-TOF mass spectra and the most possibility reference mass spectra. Yellowish-green, yellowish, and reddish spectra indicated as correct, possible, and difference to the reference mass spectra of the database, respectively.

however, no Gram-positive bacilli suspected of being *Nocardia* were detected in the brain or other organs. Since filamentous fungi, suspected of *Aspergillus*, and yeast-like fungi, suspected of *Candida*, were detected in the abscesses and blood vessels, the cause of death was established as aspergillosis and disseminated candidiasis due to bacterial replacement caused by the prolonged administration of antibiotics [Figure 3].

## DISCUSSION

*Nocardia* is an aerobic Gram-negative bacillus belonging to the order actinomycetes and is found in soil, water, rotten plants, and animal excrement. Although infections in healthy individuals have been reported, more than 60% have some underlying diseases, and are said to be opportunistic infections that develop in an immunocompromised state with reduced cellular immunity.<sup>[1]</sup> There are more than 80 bacterial species in the genus *Nocardia*, *N. thailandica* was first clinically reported for ocular nocardiosis in 2004, and pulmonary nocardiosis was clinically reported in 2014.<sup>[2,3]</sup> The clinical infection route is classified into a skin type of wound infection and a visceral type of airway infection. *Nocardia*



**Figure 3:** Postmortem specimens of the patient. (a) Gross brain section showing a collapsed abscess in the right parietal lobe (arrow). (b) H.E. stain revealed that no viable bacteria was in and around the cerebral abscess ( $\times 100$ ). (c) Gross appearance of lung showing an abscess occupying the right inferior lobe (arrow). (d) *Aspergillus* (arrow) and *Candida* (arrow head) genus were seen in the lung abscess stained with H.E. ( $\times 100$ ).

brain abscess is caused by blood flow dissemination from lung lesions.<sup>[4]</sup> Brain abscesses account for 15–44% of all *Nocardia* infections, and *Nocardia* brain abscesses are extremely rare, accounting for 2% of all brain abscesses.<sup>[5]</sup> Since the efficacy of ST combination therapy was reported, the first choice of antibiotic is ST combination with or without brain abscess; however, if it cannot be used because of side effects such as liver damage, IPM, AMK, MINO, and CTRX could be used.<sup>[6]</sup> Visceral nocardiosis is said to have a minimum of 6 months of antimicrobial administration, the central nocardiosis requires a minimum of 12 months of administration, and the period is further extended in patients who received steroids and immunosuppressants. It is stated in the book that it is necessary.<sup>[7]</sup> Regarding the prognosis, the 6-month survival rate of 74% was favorable for all nocardiosis due to the use of ST combination.<sup>[8]</sup> The *Nocardia* brain abscess was 54% in a single case with 33% mortality and 38% in multiple cases with 66% mortality, which is inferior to other bacterial brain abscesses (10% mortality).<sup>[9]</sup>

Since intestinal mucosal disorders occur in patients treated with steroids and antitumor drugs, it has been reported that *Candida*, which is a resident bacterium of the digestive tract and invades the body due to microbial substitution disease due to long-term antimicrobial administration.<sup>[10]</sup> This case was treated with *N. thailandica* for 10 weeks or longer by long-term administration of antibacterial drugs. *N. thailandica* was not detected by autopsy and abscess formation due to *Candida* and *Aspergirus* was observed. Therefore, it was strongly suspected that multiple organ infection due to the bacterial replacement phenomenon occurred.

Opportunistic infections such as *Nocardia* are a serious complication for immunocompromised patients. In addition, long-term administration of antibacterial drugs in patients who need to continue administration of steroids and immunosuppressive drugs may cause other infections due to bacterial replacement phenomenon. Although it is of course possible to prevent opportunistic infections, early detection is important. We think that it is necessary to perform CT examinations regularly instead of simple X-ray examinations so as not to miss microscopic lesions. If any infection is suspected, antibiotics should be started early and, if possible, temporary discontinuation of steroids and immunosuppressants should be considered.

This case developed a brain abscess due to an opportunistic infection with *N. thailandica* during long-term steroid administration to SLE. This is the first case of a brain abscess of *N. thailandica* because we were able to identify *N. thailandica* using genetic analysis of the isolate. Although the patient was lost due to the bacterial replacement phenomenon associated with treatment, it is a valuable case to report.

## CONCLUSION

To the best of our knowledge, this is the first case report of an *N. thailandica*-associated brain abscess. Although the patient died, the autopsy revealed that the cause of death was not the *N. thailandica*-associated brain abscess, but bacterial replacement due to the treatment of the brain abscess. Since opportunistic infections in immunocompromised patients with various underlying diseases are leading risk factors, prophylactic antimicrobial therapy before infection and regular chest CT screening could be beneficial for the patients' prognosis.

## Acknowledgments

We are grateful to Dr. Shinji Kawabata and Motomasa Furuse for helpful discussions.

## Declaration of patient consent

The authors certify that they have obtained all appropriate patient consent.

## Financial support and sponsorship

Nil.

## Conflicts of interest

There are no conflicts of interest.

## REFERENCES

1. Beaman BL, Burnside J, Edwards B, Causey W. Nocardial infections in the United States, 1972-1974. *J Infect Dis* 1976;134:286-9.
2. Edwards U, Rogall T, Blocker H, Emde M, Bottger EC. Isolation and direct complete nucleotide determination of entire genes. Characterization of a gene coding for 16S ribosomal RNA. *Nucleic Acids Res* 1989;17:7843-53.
3. Jodlowski TZ, Melnychuk I, Conry J. Linezolid for the treatment of *Nocardia* spp. infections. *Ann Pharmacother* 2007;41:1694-9.
4. Kageyama A, Yazawa K, Ishikawa J, Hotta K, Nishimura K, Mikami Y. Nocardial infections in Japan from 1992 to 2001, including the first report of infection by *Nocardia transvalensis*. *Eur J Epidemiol* 2004;19:383-9.
5. Kageyama A, Yazawa K, Nishimura K, Mikami Y. *Nocardia testaceus* sp. Nov. and *Nocardia senatus* sp. Nov., isolated from patients in Japan. *Microbiol Immunol*. 2004;48:271-6.
6. Kurahara Y, Tachibana K, Tsuyuguchi K, Akira M, Suzuki K, Hayashi S. Pulmonary nocardiosis: A clinical analysis of 59 cases. *Respir Investig* 2014;52:160-6.
7. Malincarne L, Marroni M, Farina C, Camanni G, Valente M, Belfiori B, et al. Primary brain abscess with *Nocardia farcinica* in an immunocompetent patient. *Clin Neurol Neurosurg* 2002;104:132-5.
8. Mamelak AN, Obana WG, Flaherty JF, Rosenblum ML. Nocardial brain abscess: Treatment strategies and factors influencing outcome. *Neurosurgery* 1994;35:622-31.
9. McBride WJ. Mandell, Douglas, and Bennett's principles and practice of infectious diseases 7<sup>th</sup> edition. *Sex Health* 2010;7:218.
10. Torack RM. Fungus infections associated with antibiotic and steroid therapy. *Am J Med* 1957;22:872-82.

**How to cite this article:** Yagi R, Ooi Y, Nonoguchi N, Wanibuchi M. Brain abscess caused by *Nocardia thailandica* infection in systemic lupus erythematosus patient with steroid therapy. *Surg Neurol Int* 2022;13:126.