



Since January 2020 Elsevier has created a COVID-19 resource centre with free information in English and Mandarin on the novel coronavirus COVID-19. The COVID-19 resource centre is hosted on Elsevier Connect, the company's public news and information website.

Elsevier hereby grants permission to make all its COVID-19-related research that is available on the COVID-19 resource centre - including this research content - immediately available in PubMed Central and other publicly funded repositories, such as the WHO COVID database with rights for unrestricted research re-use and analyses in any form or by any means with acknowledgement of the original source. These permissions are granted for free by Elsevier for as long as the COVID-19 resource centre remains active.



Review Article

A systemic review and recommendation for an autopsy approach to death followed the COVID 19 vaccination



Lii Jye Tan^{a,*}, Cai Ping Koh^b, Shau Kong Lai^c, Woon Cheng Poh^b, Mohammad Shafie Othman^a, Huzlinda Hussin^c

^a Department of Forensic Medicine, Hospital Raja Permaisuri Bainun, Ipoh, Perak Darul Ridzuan, Malaysia

^b Department of Biochemistry, Faculty of Medicine, Quest International University, Malaysia

^c Department of Pathology, Faculty of Medicine and Health Sciences, Universiti Putra Malaysia, Malaysia

ARTICLE INFO

Article history:

Received 11 April 2022

Received in revised form 28 July 2022

Accepted 18 September 2022

Available online 20 September 2022

Keywords:

COVID19

Vaccine

Myocarditis

Thrombosis

Anaphylaxis

Adverse effects

ABSTRACT

The outbreak of severe acute respiratory syndrome coronavirus 2 (SARS-CoV-2) started in December 2019. An immediate prevention approach for the outbreak is the development of a vaccination program. Despite a growing number of publications showing the effectiveness of vaccination in preventing SARS-CoV-2 outbreak and reducing the mortality rate, substantial fatal adverse effects were reported after vaccination. Confirmation of the causal relationship of death is required to reimburse under the national vaccination program and could provide a reference for the selection of vaccination. However, a lack of guidelines in the laboratory study and autopsy approach hampered the investigation of post-vaccination death. In this paper, we performed a systematic electronic search on scientific articles related to severe Covid-19 vaccination adverse effects and approaches in identifying the severe side effects using PubMed and Cochrane libraries. A summary on the onset, biochemistry changes and histopathological analyzes of major lethally side effects post-vaccination were discussed. Ultimately, a checklist is suggested to improve the quality of investigation

© 2022 Elsevier B.V. All rights reserved.

Contents

1. Introduction	2
2. Methods	2
2.1. Search strategy	2
2.2. Eligibility criteria	2
2.3. Data extraction and bias assessment	2
3. Results	3
3.1. Study selection	3
3.2. Study characteristics	3
3.3. Severe allergic effect related to anaphylaxis	3
3.4. Cardiovascular adverse events	3
3.5. Thrombosis, thrombocytopenia related adverse event	6
4. Discussion	6
4.1. Anaphylaxis	6
4.2. Myocarditis	11
4.3. Vaccine-induced immune thrombotic thrombocytopenia (VITT)	11
5. Conclusions	12
CRediT authorship contribution statement	12

* Correspondence to: Department of Forensic Medicine, Hospital Raja Permaisuri Bainun, Jalan Raja Ashman Shah, 30450 Ipoh, Perak Darul Ridzuan, Malaysia.
E-mail address: ilyy812@hotmail.com (L.J. Tan).

Declaration of Competing Interest	12
Acknowledgements	12
References	12

1. Introduction

Severe acute respiratory syndrome coronavirus 2 (SARS-CoV-2) was firstly reported in China and declared as a pandemic by World Health Organization (WHO) in the year 2020. Generation of vaccines and the establishment of vaccination programs immediately took place to mitigate the infection and mortality rate. Upon the starting of vaccination programs, severity on vaccine adverse effect and the causal relationship between vaccination and death brings up the attention of publicity. An average of 0.0018 % SARS-CoV-2 vaccine-related death cases were reported by Vaccine Adverse Event Reporting System (VAERS) before July 2021. [1]. Unfortunately, due to the limitation of time, guideline and procedure in the postmortem investigation during the pandemic, bias in the justification of the causal association between vaccination and death remained unsolved [2]. Therefore, compensations for vaccine-related death were hardly determined.

The vaccine-related injury or death compensation was initially covered under National Vaccine Injury Compensation Program (NVICP or VICP). In the case of recently developed SARS-CoV-2 vaccines, two medico-legal compensation guidelines, which are no-fault vaccine injury regimens and constructing a third regimen under COVAX's authority, were applied for the compensation of SARS-CoV-2 vaccine injuries [3]. The no-fault vaccine injury regimens are generally applied to wealthier countries, such as Canada [4]. However, Nepal and Vietnam also took this guideline to compensate SARS-CoV-2 vaccine-related injury. The constructing a third regimen under COVAX's authority compensates WHO, donors, manufacturers, and health care workers who helps in performing vaccination. Though the two systems are currently useful to covered part of the vaccine-related injury or death compensation, a lack of guideline and procedure in biochemistry investigation, pathology analysis and autopsy procedure prohibited the judgement of successful claims. Of note, the judgement on limited time for investigation should not be considered in any of the compensation scheme.

To develop a procedure for identification on the cause of death after vaccination, massive studies should be revisited and compiled. Firstly, a biological understanding on the serious adverse effect caused after SARS-CoV-2 vaccination should be included and a specific downstream specimen collection could be proposed in postmortem investigation. Generally, severe adverse effects which might lead to fatality are classified into anaphylaxis, thrombotic event, and myocarditis [5]. Anaphylaxis is a fatal allergy reaction, which could be observed in the first few hours and rarely up to days of vaccination, causing shock or asphyxia. Generally, mRNA vaccines utilized lipid nanoparticle (LNP) delivery system to improve the efficacy of mRNA delivery. However, the cationic/ionizable lipid in LNP delivery system activates innate inflammation and therefore initiates subsequent immune responses. Though the use of viral vector vaccine excludes the necessity of a LNP delivery system, polyethylene glycol (PEG) is commonly added to increase the half-life and effective concentration of the viral vectors [6]. Polysorbate is another chemical that works similarly as PEG to improve the efficacy of viral vector vaccines. Both molecules could potentially induce immune responses, which lead to different degrees of allergic reaction [7].

Vaccine induced thrombotic thrombocytopenia (VITT), similar to heparin-induced thrombocytopenia, results in formation of anti-platelet factor 4 (PF4) leading to thrombocytopenia and thrombosis. Pomara et al., 2021 suggested the causality of VITT after AstraZeneca vaccination through activation of platelet-activating antibodies against platelet factor 4 (PF4) [8]. The most frequently reported fatal adverse reaction with VITT is cerebral venous sinus thrombosis (CVST). Myocarditis is another key severe adverse effect described after vaccination. Myocarditis is an inflammatory event which leads to the damage of heart muscle. It was reported that mRNA vaccines, particularly Pfizer vaccine, induced a higher occurrence of myocarditis [9]. The mechanism of vaccine induced myocarditis is largely unknown.

In this systematic review, the three major fatal adverse effects are discussed, including anaphylaxis, myocarditis, and thrombosis. An autopsy approach is suggested to improve the efficiency of sample collection for subsequent investigation on the causality of post-vaccination death.

2. Methods

This study was conducted according to Cochrane collaboration recommendations [10]. The objectives of our systemic review are to summarize the reported pathomorphological adverse reactions post COVID-19 vaccination, followed by recommendations in autopsy approach in those suspected fatal adverse reaction following vaccination.

2.1. Search strategy

Systemic searches were conducted in PubMed and Cochrane library. The search strategy included the following descriptors: "adverse", "vaccine", "covid-19", "sars-cov-2", "anaphylaxis", "allergy", "thrombosis", "myocarditis" with Boolean operators "AND" and "Or". All searches were limited to articles written in English. Reference lists of included articles were hand-searched to ensure that relevant publications were not missed.

2.2. Eligibility criteria

The studies were included in this systemic review if they met all the following eligibility criteria: (i) Original articles published in peer reviewed journal, including research papers reviews articles, case reports and case series (ii) serious adverse reaction including anaphylaxis, myocarditis and thrombosis, (iii) the type of vaccine is specified. The date of last searches is February 28th, 2022, hence any articles published after this date are excluded. We will exclude articles that are not published in peer-reviewed journal, incomplete full test records, preliminary communications, conference and commentaries papers.

2.3. Data extraction and bias assessment

Three authors (TLJ, KCP, LSK) critically reviewed all the studies retrieved and selected relevant articles. The title and abstracts were independently screened for eligibility by the authors. Search results were exported into Atlas.ti (Scientific Software Development,

Technical University, Berlin) [11] and duplicate articles deleted. Relevant articles were read in full and those that met the inclusion criteria had their data extracted by 4 reviewers (LSK, MSO, HH, KCP) independently: authors, type of vaccine, country of the reported event, total vaccinated population, age group, vaccine dose and types of adverse reaction. Two reviewers (TLJ, KCP) evaluated independently the risk of bias in each study using Diagnostic Precision Study Quality Assessment Tool (QUADAS-2) recommended by the Cochrane Collaboration.

3. Results

3.1. Study selection

A total of 1025 articles were yielded after initial searching (Fig. 1). Of these, 980 articles were identified after duplicates removal, with 319 articles being fully reviewed and 140 articles meeting the inclusion criteria. Finally, 47 articles were unintelligible and unable to be included, leaving a total of 96 articles. (Fig. 2).

3.2. Study characteristics

Studies included in this review were tabulated according to the three major types of fatal adverse effects: anaphylaxis (Table 1), myocarditis (Table 2) and thrombotic events (Table 3). All included studies were cohort designs and case report, and most of the studies are conducted based on registry databases.

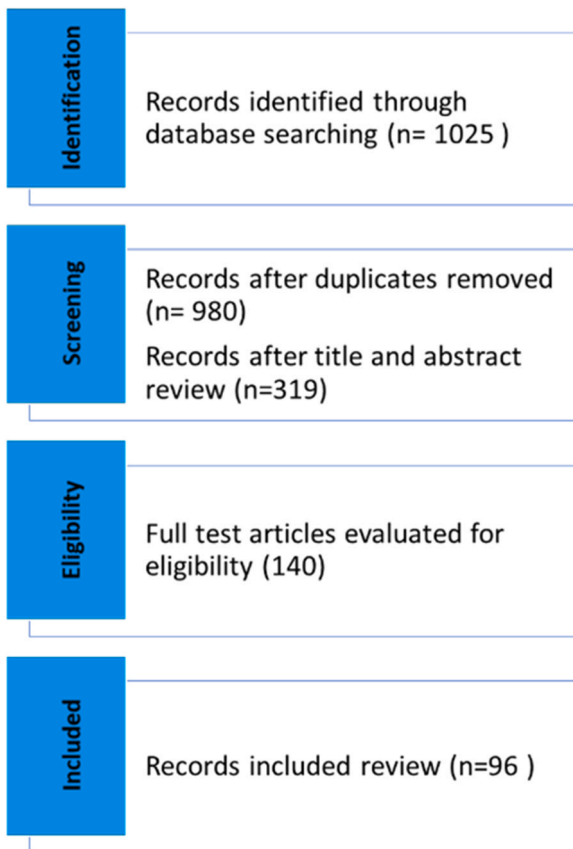

Fig. 1. Flowchart of included studies.

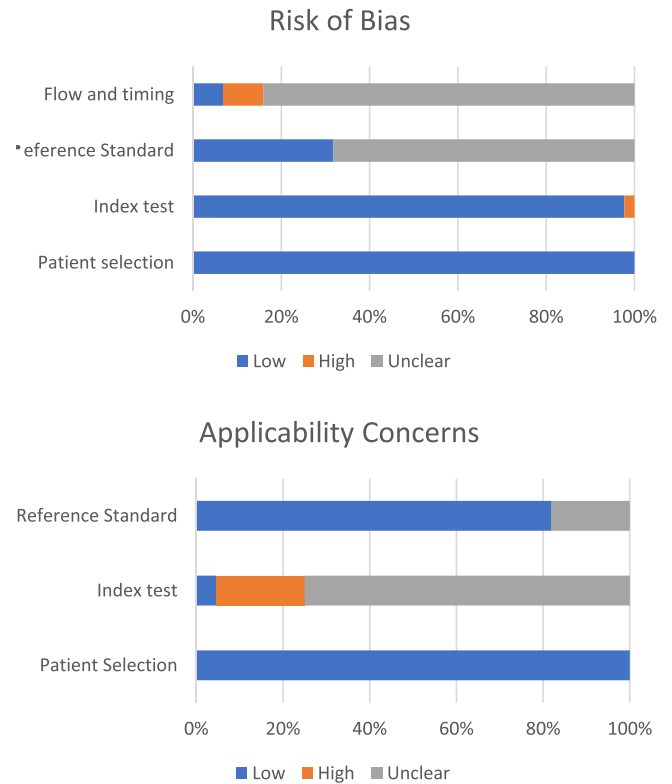


Fig. 2. Summary of the methodological quality of the included studies.

3.3. Severe allergic effect related to anaphylaxis

Studies included in this review were 25 cohort studies and 8 case report or case series. Among the studies, the incidence of anaphylaxis was reported varies from 8 in 100,000 up to 5 in 1000 doses in Pfizer (1151 cases), 2 in 100,000 up to 1 in 100 doses in Moderna (544 cases), 1 in 10,000 up to 3 in 1000 doses in AstraZeneca (875 cases) and 2 in 1000 doses in Janssen vaccine (59 cases). Anaphylaxis is more frequently reported with the mRNA vaccine (Table 1). In three of the mRNA vaccination studies, hypersensitive and/or allergy source of Pfizer vaccine is linked to the presence of PEG [12–14]. Perivascular lymphocytic infiltration with or without mentioning eosinophils were found in biopsy of allergy skin reaction [15–18]. Other studies reported local skin reaction to the injection site, facial edema, throat swelling and bronchospasm.

3.4. Cardiovascular adverse events

This review included 8 cohort studies and 24 case report or case series. Cardiovascular adverse events, including myocarditis and myopericarditis were reported after the vaccination. There are 1059 reports (ranging from 4 in 100,000 up to 3 in 1000 doses) of myocarditis after the Pfizer, 249 reports (ranging from 2 in 10,000 up to 1 in 1000) after Moderna, 178 reports (4 in 100,000) after AstraZeneca and 8 cases (2 in 10,000) after Janssen vaccine. Similar with anaphylaxis, myocarditis is more frequently reported with mRNA vaccine (Table 2). Overall, most cases occurred after the second dose of vaccine, mainly affecting the adolescent age groups and male gender is predominant. Seven cases of death were reported [17,19], only one study stated the exact cause of death as intracranial bleeding with hypertensive crisis after vaccination [19].

Table 1
Anaphylaxis cases after SARS-CoV-2 vaccination after SARS-CoV-2 vaccines & methodological quality of the included studies.

Vaccine Brand	Country	Age group	Vaccine dose	Total vaccine administered/ Reported case	Total cases	Incidence	Reference	Risk of Bias		Applicability Concerns		
								Patient selection	Index test	Reference standard	Flow & timing	Patient selection
1 Pfizer	US	NS	1st	25,929 persons	Anaphylaxis(7)	2×10^{-4}	Blumenthal et al. [20]	⊕	⊕	⊕	⊕	⊕
2 Pfizer	US	> 16	1 st , 2nd	51,205 persons	Anaphylaxis(297)	0.005	Singh et al. [21]	⊕	⊕	⊕	?	⊕
3 Pfizer	US	> 16	1st, 2nd	6994 doses	Anaphylaxis(46)	0.006	Gee et al. [22]	⊕	⊕	?	?	⊕
4 Pfizer	US	27–60	1st	1,893,360 persons	Anaphylaxis(21)	1×10^{-5}	CDC covid19 response team [23]	⊕	⊕	?	?	⊕
5 Pfizer	US	18–80	1st, 2nd	1271 persons	Anaphylaxis(1)	7×10^{-4}	Kadali et al. [24]	⊕	⊕	⊕	?	⊕
6 Pfizer	US	19–89	1st, 2nd	62 cases	Anaphylaxis(62)	–	Kaplan et al. [25]	⊕	⊕	⊕	⊕	⊕
7 Pfizer	US	> 16	2nd	18,801	Anaphylaxis(1)	1×10^{-5}	Clinical Trial data by FDA [26]	⊕	⊕	?	?	⊕
8 Pfizer	US	55	1st	1 case	Anaphylaxis(1)	–	Frank et al. [27]	NA	NA	NA	NA	NA
9 Pfizer	US	34	1st	1 case	Anaphylaxis(1)	–	Park et al. [28]	NA	NA	NA	NA	NA
10 Pfizer	Canada	> 25	NS	737,728 doses	Anaphylaxis(28)	4×10^{-5}	Ontario public health agency [29]	⊕	⊕	?	?	⊕
11 Pfizer	Ecuador	39.3 mean age	1st, 2nd	1291 persons	Anaphylaxis(2)	0.001	Vanegas et al. [30]	⊕	⊕	?	?	⊕
12 Pfizer	UK	NS	1st, 2nd, 3rd	71.4million doses	Anaphylaxis, anaphylactoid reactions(592)	8×10^{-6}	MHRA [17]	⊕	⊕	?	?	⊕
13 Pfizer	UK	52	NS	1 case	Anaphylaxis, positive skin prick test to PEG 4000(1)	–	Sellaturay et al. [13]	NA	NA	NA	NA	NA
14 Pfizer	Italy	> 19	1st, 2nd	2030 persons	Anaphylaxis(1)	0.0004	Ossato et al. [31]	⊕	⊕	⊕	?	⊕
15 Pfizer	Italy	30	1st	1 case	Anaphylaxis(1)	–	Restivo et al. [32]	NA	NA	NA	NA	NA
16 Pfizer	Israel	52 mean ages	1st, 2nd	429 persons	Anaphylaxis(3)	0.007	Shavit et al. [33]	⊕	⊕	⊕	⊕	⊕
17 Pfizer	Lebanon	30	1st	1 case	Biphasic anaphylaxis(1)	–	Abi Zeid Daou et al. [34]	NA	NA	NA	NA	NA
18 Pfizer	Korea	> 19	NS	288 persons	Anaphylactoid reaction(1)	0.003	Song et al. [35]	⊕	⊕	⊕	?	⊕
19 Pfizer	Japan	22–56	1st, 2nd	578,835 doses	Anaphylaxis(47)	6×10^{-5}	Iguchi et al. [36]	⊕	⊕	?	?	⊕
20 Pfizer	Japan	23–58	1st, 2nd	181,184 persons	Anaphylaxis(37)	0.0002	Hashimoto et al. [37]	⊕	⊕	?	?	⊕
21 Moderna	US	> 16	1st, 2nd	61,258 persons	Anaphylaxis(392)	0.006	A Singh et al. [21]	⊕	⊕	⊕	⊕	⊕
22 Moderna	US	31–63	1st	4,042,396 persons	Anaphylaxis(10)	2×10^{-6}	CDC covid19 response team [23]	⊕	⊕	?	?	⊕
23 Moderna	US	NS	1st	38,971 persons	Anaphylaxis(9)	0.0002	Blumenthal et al. [20]	⊕	⊕	⊕	⊕	⊕
24 Moderna	US	18–80	1st, 2nd	1116 persons	Anaphylaxis(1)	0.0009	Kadali et al. [24]	⊕	⊕	?	?	⊕
25 Moderna	US	31–63/F	1st	4,041,396 doses	Anaphylaxis(10)	2×10^{-6}	Shimabukuro [38]	⊕	⊕	?	?	⊕
26 Moderna	US	> 16	1st	1373 doses	Anaphylaxis(16)	0.01	Gee et al. [22]	⊕	⊕	?	?	⊕
27 Moderna	US	19–89	1st, 2nd	50 cases	Anaphylaxis(50)	–	Kaplan et al. [25]	NA	NA	NA	NA	NA
28 Moderna	Canada	> 25	NS	152,876 doses	Anaphylaxis(5)	3×10^{-5}	Ontario public health agency [29]	⊕	⊕	?	?	⊕
29 Moderna	UK	NS	1st, 2nd	2.9million dose	Anaphylaxis(61)	2×10^{-5}	MHRA [17]	⊕	⊕	?	?	⊕
30 AZ	UK	NS	1st, 2nd	49 million doses	Anaphylaxis, anaphylactoid reactions(852)	1×10^{-5}	MHRA [17]	⊕	⊕	?	?	⊕
31 AZ	Korea	> 19	NS	5930 persons	Anaphylactoid reaction(23)	0.003	Song et al. [35]	⊕	⊕	⊕	⊕	?
32 Janssen	US	> 16	1 dose	28,745 persons	Anaphylaxis(58)	0.002	A Singh et al. [21]	⊕	⊕	⊕	?	⊕
33 Janssen	US	19–89	1 dose	1 case	Anaphylaxis(1)	–	Kaplan et al. [25]	NA	NA	NA	NA	NA

Abbreviation: AZ, AstraZeneca; CDC, center of disease control and prevention; F, female; FDA, food and drug administration; M, Male; MHRA, Medicine and healthcare products regulatory agency; NS, not specified; PEG, Polyethylene Glycol; ⊕, low risk; ⊕, high risk; NA, not applicable.

Table 2
Myocarditis cases after SARS-CoV-2 vaccines & methodological quality of the included studies.

Vaccine brand	Country	Age group	Vaccine dose	Total vaccine administered/ Reported cases	Total cases	Incidence	References	Risk of Bias		Applicability Concerns			
								Patient selection	Index test	Reference Standard	Flow & timing	Patient Selection	Index Test
1 Pfizer	US	> 18	1st,2nd	51,205 persons	Myocarditis(108)	0.002	A Singh et al.[21]	⊕	⊕	⊕	?	⊕	?
2 Pfizer	US	12-17	1st,2nd	9246 persons	Myocarditis(347)	0.03	Hause et al.[39]	⊕	⊕	?	?	⊕	?
3 Pfizer & Moderna	US	19-94	1st,2nd	296million doses	Myocarditis(1226)	4×10^{-6}	Gargano et al.[40]	⊕	⊕	?	?	⊕	?
4 Pfizer	UK	NS	1st, 2nd	46.4 million doses	Myocarditis(543), pericarditis(378), eosinophilic myocarditis (1), death(4)	1×10^{-5} (Myo) 8×10^{-6} (Peri)	MHRA[17]	⊕	⊕	?	?	⊕	?
5 Pfizer	US	12-18/M	2nd	15 cases	Myocarditis(15)	-	Dionne et al.[41]	NA	NA	NA	NA	NA	NA
6 Pfizer	US	14-19/M	2nd	7 cases	Myocarditis, myopericarditis(7)	-	Marshall et al.[42]	NA	NA	NA	NA	NA	NA
7 Pfizer	US	20-51/M	1st(1), 2nd(6)	7 cases	Myocarditis(7)	-	Montgomery et al.[43]	NA	NA	NA	NA	NA	NA
8 Pfizer	US	19-39/M	1st(1), 2nd(4)	5 cases	Myocarditis(5)	-	Rosner et al.[44]	NA	NA	NA	NA	NA	NA
9 Pfizer	US	23, 24/M	2nd	2 cases	Myocarditis(2)	-	Kim et al.[45]	NA	NA	NA	NA	NA	NA
10 Pfizer	US	46/M	2nd	1 case	Myopericarditis(1)	-	Bartlett et al.[46]	NA	NA	NA	NA	NA	NA
11 Pfizer	US	16/M	2nd	1 case	Myopericarditis(1)	-	McLean et al.[47]	NA	NA	NA	NA	NA	NA
12 Pfizer	Israel	18-24/M	2nd	7 cases	Myocarditis(7)	-	Levin et al.[48]	NA	NA	NA	NA	NA	NA
13 Pfizer	Israel	16-45/M	1st(1), 2nd(5)	6 cases	Myocarditis(6)	-	Abu Mouch et al.[49]	NA	NA	NA	NA	NA	NA
14 Pfizer	Italy	21-56/M	1st(1), 2nd(4)	5 cases	Myocarditis(5)	-	Larson et al.[50]	NA	NA	NA	NA	NA	NA
15 Pfizer	Italy	56/M	2nd	1 case	Myocarditis(1)	-	Anmirati et al.[51]	NA	NA	NA	NA	NA	NA
16 Pfizer	Italy	20/M	2nd	1 case	Myopericarditis(1)	-	Facetti et al.[52]	NA	NA	NA	NA	NA	NA
17 Pfizer	Korea	29/M	2nd	1 case	Myopericarditis(1)	-	Kim et al.[53]	NA	NA	NA	NA	NA	NA
18 Pfizer	Spain	39/M	2nd	1 case	Myocarditis(1)	-	Bautista Garcia et al.[54]	NA	NA	NA	NA	NA	NA
19 Pfizer	France	19/M	NS	1 case	Myocarditis(1)	-	Schmitt et al.[55]	NA	NA	NA	NA	NA	NA
20 Moderna	US	> 17	1st,2nd	61,258 persons	Myocarditis(101)	0.001	A Singh et al.[21]	⊕	⊕	⊕	?	⊕	?
21 Moderna	UK	NS	1st, 2nd	2.9million doses	Myocarditis(122), pericarditis(69), hypersensitivity myocarditis(1), Myocarditis(16)	4×10^{-5} (Myo) 2×10^{-5} (Peri)	MHRA[17]	⊕	⊕	?	?	⊕	?
22 Moderna	US	20-51/M	1st(2), 2nd(14)	16 cases	Myocarditis(16)	-	Montgomery et al.[43]	NA	NA	NA	NA	NA	NA
23 Moderna	US	36/M, 70/F	2nd	2 cases	Myocarditis(2)	-	Kim et al.[45]	NA	NA	NA	NA	NA	NA
24 Moderna	US	39/M	2nd	1 case	Myocarditis(1)	-	Rosner et al.[44]	NA	NA	NA	NA	NA	NA
25 Moderna	US	24/M	2nd	1 case	Myocarditis(1)	-	Albert el al[56]	NA	NA	NA	NA	NA	NA
26 Moderna	US	52/M	2nd	1 case	Myocarditis(1)	-	Murthukumar et al.[57]	NA	NA	NA	NA	NA	NA
27 Moderna	Italy	22-31/M	2nd	3 cases	Myocarditis(3)	-	Larson et al.[50]	NA	NA	NA	NA	NA	NA
28 Moderna	Italy	30/M	2nd	1 case	Myocarditis(1)	-	D'Angelo et al.[58]	NA	NA	NA	NA	NA	NA
29 Moderna	Greece	71/F	1st	1 case	ICB, hypertensive crisis, death(1)	-	Athyros & Doumas[19]	NA	NA	NA	NA	NA	NA

(continued on next page)

Table 2 (continued)

Vaccine brand	Country	Age group	Vaccine dose	Total vaccine administered/ Reported cases	Total cases	Incidence	References	Risk of Bias		Applicability Concerns		
								Index test	Reference Standard	Flow & timing	Patient Selection	Index Test
30 AZ	UK	NS	1st, 2nd	49 million doses	Myocarditis(178), pericarditis(201), autoimmune myocarditis (1), death(2)	3×10^{-6} (Myo) 4×10^{-6} (Peri)	MHRA[17]	⓪	⓪	⓪	?	?
31 Janssen	US	>17	1	28745 persons	Myocarditis(7)	0.0002	A Singh et al.[21] Rosner et al.[44]	⓪	⓪	⓪	⓪	?
32 Janssen	US	28/M	1	1 case	Myocarditis(1)	-		NA	NA	NA	NA	NA

Abbreviation: AZ, AstraZeneca; CDC, center of disease control and prevention; MHRA, Medicine and healthcare products regulatory agency; NS, not specified; ⓪, low risk; ⓧ, high risk; NA, not applicable.

3.5. Thrombosis, thrombocytopenia related adverse event

Studies included in this review included 10 cohort studies and 57 case report or case series. A total of over 24,000 thrombotic events have been reported, the majority of which have been associated with adenoviral vector-based vaccine, particularly AstraZeneca (5 in 100,000 up to 6 in 1000), followed by Janssen (8–30 in 1,000,000 doses), Pfizer (6 in 1,000,000 up to 1 in 1000 doses) and Moderna (4 in 10,000,000). Antibodies against platelet factor 4 (PF 4) were positive in 67 cases in AstraZeneca and 17 cases in Janssen, and it was not tested or mentioned in cases of mRNA-based vaccine. Overall, the thrombotic event is more frequently occurred after 1st dose of AstraZeneca vaccine (Table 3). Death related with thrombotic event was registered 238 cases in Pfizer, 186 cases in AstraZeneca, 54 cases in Moderna and 17 cases in Janssen. The incidence of thrombosis is more commonly observed in female gender (103) than male (24). Vaccine-induced immune thrombotic thrombocytopenia (VITT) has heterogenous presentation, however, the main cause of death is related to complication of cerebral venous sinus thrombosis.

4. Discussion

Deaths that occurred within short intervals post-vaccination are exceptionally driven the public concern about the safety of vaccination programs. Except for the concern on vaccination programs, compensation schemes related to vaccine-related injury or death are of high interest in public. As a consequence, a guideline on postmortem investigation is important to evaluate the cause of death and determine the causality for the claim of compensation. Here, we comprehensively discussed the onset, autopsy approach, histopathology, and biochemistry analysis of the three most common post-vaccination lethally adverse effects: anaphylaxis, VITT, and myocarditis.

During the pandemic, COVID-19 screening is generally required prior any postmortem examination. Positive virus detection could be an alternative explanation for the cause of adverse reactions following vaccination. A multi-site viral detection study in mildly infected patient found higher nasopharyngeal viral loads in the early course of disease, despite finding Viral RNA in sputum for longer periods of time [117]. When compared to deep respiratory samples, nasopharyngeal swabs were relatively insensitive for detecting virus in critically ill patient [118]. The viral genome could be found in lung tissues for months after death, indicating the virus's stability [119,120]. Grassi et al. examined 29 autopsy cases and discovered that the mean viral load of SARS-CoV-2 death is higher in those who died without hospitalization than in those who died while hospitalized. The relationship between the presence of replicative mRNA and death without hospitalization and that between minimum cycle threshold value of SARS-CoV-2 RNA and the cycle threshold value of replicative SARS-CoV-2 mRNA were found to be statistically significant. As a result, autopsies of untreated SARS-CoV-2 patients may pose a higher risk of infection; therefore, strict adherence to biological safety guidelines in the autopsy room is required [121].

4.1. Anaphylaxis

In the clinical setting, the acute symptoms of anaphylaxis include allergic skin changes, respiratory, cardiovascular and/or severe gastrointestinal symptoms [122,123]. Adverse Events of Special Interest (AESI) for anaphylaxis case definition, required an event time course that includes “sudden onset”- the event occurred unexpectedly and without warning, resulting in marked changes in a subject's previously stable condition and rapid progression [123]. Of note, the pathological changes in vaccine-related anaphylaxis and allergy reactions to other medications or foods are similar.

Diagnosis of anaphylaxis in autopsy is challenging as there is no pathognomic change. Gross findings included local or generalized

Table 3
Thrombosis, thrombocytopenia related adverse event after SARS-CoV-2 vaccines & methodological quality of the included studies.

Vaccine brand	Country	Age group	Vaccine dose	Total vaccine administered/ Reported cases	Total cases	Incidence of thrombosis	Study	Risk of bias		Applicability concerns			
								Patient selection	Index test	Reference standard	Flow & timing	Patient selection	Index test
1 AZ	England	> 16	1st	19608008 persons	CVST(23), thrombocytopenia(1480), venous(3077), arterial (11617) thrombosis, stroke(3976)	6×10^{-4}	NS Hippisley-Cox et al.[59]	⊕	⊕	?	⊕	?	⊕
2 AZ	UK	NS	1st, 2nd	49 million doses	CVST(156), thrombotic thrombocytopenia(429), death(75)	8×10^{-6}	NS MHRA [17]	⊕	⊕	?	⊕	?	⊕
3 AZ	UK	21–77	1st	23 cases	CVT(13), stroke(2), AMI (1), PE(4), thrombotic thrombocytopenia(23), venous(4), arterial(1) thrombosis, death(7)	-	P(22), N(1) Scully et al.[60]	NA	NA	NA	NA	NA	NA
4 AZ	UK	NS	NS	21.2 million persons	CVST(77)	3×10^{-6}	NS Bikdeli et al.[61]	⊕	⊕	?	?	?	⊕
5 AZ	UK	32, 25/M	1st	2 cases	CVST, ICB, SAH, thrombocytopenia, death(2)	-	P(1) Mehta et al.[62]	NA	NA	NA	NA	NA	NA
6 AZ	UK	54/M	NS	1 case	CVST, VITT, venous thrombosis(1)	-	P Ramdeny et al.[63]	NA	NA	NA	NA	NA	NA
7 AZ	UK	27/M	1st	1 case	CVST, ICB, thrombocytopenia, death(1)	-	P Suresh et al.[64]	NA	NA	NA	NA	NA	NA
8 AZ	UK	30/F	NS	1 case	CVST, venous thrombosis(1)	-	P Tølbøll Sørensen et al.[65]	NA	NA	NA	NA	NA	NA
9 AZ	UK	35/F, 37/F, 43/F	NS	3 cases	CVST(2), VITT(3), ICB(2), venous(2), arterial(1) thrombosis, death(1)	-	P(3) Al-mayhani et al.[66]	NA	NA	NA	NA	NA	NA
10 AZ	Ireland	29/F, 38/M, 50/F, 35/F	NS	4 cases	VITT(4), CVST(1), venous thrombosis(1), PE (1)	-	P(4) Lavin et al.[67]	NA	NA	NA	NA	NA	NA
11 AZ	Europe	NS	NS	NS	CVST, thrombocytopenia(243)	-	NS Van de Muncckhof et al.[68]	NA	NA	NA	NA	NA	NA
12 AZ	Germany, Austria	22–49	NS	11 cases	CVST(9), ICB(1), venous thrombosis(4), PE(3), death(6)	-	P(9) Greinacher et al.[69]	NA	NA	NA	NA	NA	NA
13 AZ	Germany	29 /M	1st	1 case	CVST, VITT, venous thrombosis(1)	-	NS Graf et al.[70]	NA	NA	NA	NA	NA	NA
14 AZ	Germany	41–67/F	1st	5 cases	CVST(5), ICB(1), stroke(1), venous(1), arterial(12) thrombosis.	-	P(5) Tiede et al.[71]	NA	NA	NA	NA	NA	NA
15 AZ	Germany	30/F	1st	1 case	CVST, ICB, VITT(1)	-	P Ikenberg et al.[72]	NA	NA	NA	NA	NA	NA
16 AZ	Germany	55/F	1st	1 case	Venous thrombosis, stroke,	-	N Bayas et al.[73]	NA	NA	NA	NA	NA	NA
17 AZ	Germany	31/M	1st	1 case	Stroke, arterial thrombosis(1)	-	P Walter et al.[74]	NA	NA	NA	NA	NA	NA

(continued on next page)

Table 3 (continued)

Vaccine brand	Country	Age group	Vaccine dose	Total vaccine administered/ Reported cases	Total cases	Incidence of thrombosis	Pf4	Study	Risk of bias		Applicability concerns	
									Patient selection	Index test	Reference standard	Flow & timing
18 AZ	France	19–99	NS	639 cases	CVST(6), CVT(1), PE(211), DVT(111), venous(92), arterial(308) thrombosis, stroke(219), AMI(81), death(82)	–	NS	Smadja et al.[75]	NA	NA	NA	NA
19 AZ	France	69/F	1st	1 case	CVST, PE, thrombocytopenia, ICB, death(1)	–	P	Jamme et al.[76]	NA	NA	NA	NA
20 AZ	France	21/F	1st	1 case	CVT, stroke, VITT, PE, venous thrombosis(1)	–	NS	Bersinger et al.[77]	NA	NA	NA	NA
21 AZ	Norway	32–54	1st	NS	CVST(4), CVT(3), VITT(5), venous thrombosis(1), death(3)	–	NS	Schultz et al.[78]	NA	NA	NA	NA
22 AZ	Norway	30/F	NS	1 case	CVST, ICB, PE, thrombocytopenia, death(1)	–	P	Björnstad-Tuveng et al.[79]	NA	NA	NA	NA
23 AZ	Spain	47/M	NS	1 case	CVST, CVT, VITT, PE(1)	–	P	Varona et al.[80]	NA	NA	NA	NA
24 AZ	Denmark	60/M	1st	1 case	Stroke, thrombocytopenia, death(1)	–	P	Blaufenfeldt et al.[81]	NA	NA	NA	NA
25 AZ	Austria	51/F	NS	1 case	Thrombocytopenia, PE, venous thrombosis(1)	–	NS	Muster et al.[82]	NA	NA	NA	NA
26 AZ	Italy	50/M	1st	1 case	CVST, CVT, ICB, thrombocytopenia, death(1)	–	N	Castelli et al.[83]	NA	NA	NA	NA
27 AZ	Italy	32/F	1st	1 case	CVST, VITT, venous thrombosis, death(1)	–	NS	Centonze et al.[84]	NA	NA	NA	NA
28 AZ	Italy	54/F	NS	1 case	CVST, ICB, SAH, venous, arterial thrombosis, PE, MI, death(1)	–	NS	D'Agostino et al.[85]	NA	NA	NA	NA
29 AZ	Italy	26/F	1st	1 case	CVST, CVT, ICB(1)	–	P	Bonato et al.[86]	NA	NA	NA	NA
30 AZ	Italy	50/M	1st	1 case	CVST, ICB, death(1)	–	P	Franchini et al.[87]	NA	NA	NA	NA
31 AZ	Austria	39/F; 24/F	1st	2 cases	CVST(1), CVT(1), ICB(1), thrombocytopenia(2)	–	P(2)	Gattringer et al.[88]	NA	NA	NA	NA
32 AZ	Canada	72/F; 63/M; 69/M	NS	3 cases	CVST(1), VITT(3), stroke (1), venous(3), arterial(3) thrombosis, PE(2), ICB, VITT(1)	–	NS	Bourguignon et al.[89]	NA	NA	NA	NA
33 AZ	Brazil	57/F	1st	1 case	CVST, VITT(1)	–	NS	de Melo Silva et al.[90]	NA	NA	NA	NA
34 AZ	Saudi Arabia	40/M; 61/F	1st	2 cases	CVST, thrombocytopenia(1)	–	NS	Esba et al.[91]	NA	NA	NA	NA
35 AZ	Saudi Arabia	36/F	1st	1 case	CVST, VITT, stroke, venous thrombosis, death(1)	–	NS	Aladdin et al.[92]	NA	NA	NA	NA
36 AZ	Taiwan	52/M	NS	1 case	CVST, VITT, venous thrombosis(1)	–	P	Guan et al.[93]	NA	NA	NA	NA
37 AZ	Taiwan	41/F	1st	1 case	CVST, thrombocytopenia, PE(1)	–	P	Wang et al.[94]	NA	NA	NA	NA
38 AZ	Korea	33/M	1st	1 case	CVST, ICB, thrombocytopenia, death(1)	–	P	Choi et al.[95]	NA	NA	NA	NA

(continued on next page)

Table 3 (continued)

Vaccine brand	Country	Age group	Vaccine dose	Total vaccine administered/ Reported cases	Total cases	Incidence of thrombosis	PF4	Study	Risk of bias		Applicability concerns	
									Patient selection	Index test	Reference standard	Flow & timing
39 AZ	India	51/M	1st	1 case	CVT(1)	-	N	Dutta et al.[96]	NA	NA	NA	NA
40 AZ	India	44/F	1st	1 case	CVST, SAH, stroke, thrombocytopenia(1)	-	P	Maramattom et al.[97]	NA	NA	NA	NA
41 Janssen	US	NS	1 dose	12.6 million doses	Thrombotic thrombocytopenia syndromes(38)	3×10^{-6}	NS	Rosenblum et al.[98]	⊖	?	?	⊖
42 Janssen	US	NS	1 dose	6.85 million persons	CVST(6)	8×10^{-7}	NS	Bikdeli et al.[61]	⊖	?	?	⊖
43 Janssen	US	18-48	1 dose	6.86 million doses	CVST, thrombocytopenia (6), venous thrombosis (3), PE(1), DVT, death(1)	8×10^{-7}	NS	ACIP[99]	⊖	?	?	⊖
44 Janssen	US	12-60/F	1 dose	12 cases	CVST, thrombocytopenia (12), venous thrombosis (8), DVT(2), PE(3), ICB(7), death(3)	-	P(11), NS(1)	See et al.[100]	NA	NA	NA	NA
45 Janssen or AZ	US	NS	NS	NS	CVT(77)	-	NS	García-Azorín et al.[101]	NA	NA	NA	NA
46 Janssen	US	40/F	1 dose	1 case	Thrombocytopenia, CVST, PE(1)	-	P	Clark et al.[102]	NA	NA	NA	NA
47 Janssen	US	24/M	1 dose	1 case	VITT, venous thrombosis(1)	-	P	Dhoot et al.[103]	NA	NA	NA	NA
48 Janssen	US	48/F	1 dose	1 case	CVST, ICB, thrombocytopenia, venous thrombosis(1)	-	P	Muir et al.[104]	NA	NA	NA	NA
49 Janssen	US	43/F	1 dose	1 case	TIA, arterial thrombosis, PE, CVST,	-	P	Malik et al.[105]	NA	NA	NA	NA
50 Janssen	US	40/F	1 dose	1 case	thrombocytopenia(1)	-	P	George et al.[106]	NA	NA	NA	NA
51 Janssen	US	48/F	1 dose	1 case	CVST, venous thrombosis, PE, thrombocytopenia(1)	-	P	Abou-ismail et al.[107]	NA	NA	NA	NA
52 Janssen	Europe	NS	1 dose	NS	VITT, DVT, PE(1)	-	NS	Van de Munckhof et al.[68]	NA	NA	NA	NA
53 Pfizer	France	18-102	NS	1197 cases	CVST, thrombocytopenia(23)	-	NS	Smadja et al.[75]	NA	NA	NA	NA
54 Pfizer	Portugal	47/F, 67/F	1st, 2nd	2 cases	PE(211), DVT(111), CVST(3), CVT(3) venous (42), arterial(813)	-	NS	Dias et al.[108]	NA	NA	NA	NA
55 Pfizer	Poland	86/M	1st	1 case	thrombosis, stroke(561), AMI(238), death(223)	-	NS	Tajstra et al.[109]	NA	NA	NA	NA
56 Pfizer or Moderna	Austria	52/M	2nd	1 case	CVT(2), CVST(1), stroke (1), normal platelet(2)	-	NS	Finsterer et al.[110]	NA	NA	NA	NA
57 Pfizer	UK	NS	1st, 2nd	46.4 million doses	MI, death(1)	6×10^{-7}	NS	MHRA[17]	⊖	?	?	⊖
58 Pfizer	England	> 16	1st	9513625 persons	Thrombotic thrombocytopenia(29), death(4)	0.001	NS	Hippisley-Cox et al.[59]	⊖	?	?	⊖
					Thrombocytopenia(1010), venous(2054), arterial (9473) thrombosis, CVST(6), stroke(3167)							

(continued on next page)

Table 3 (continued)

Vaccine brand	Country	Age group	Vaccine dose	Total vaccine administered/ Reported cases	Total cases	Incidence of thrombosis	PF4	Study	Risk of bias		Applicability concerns	
									Patient selection	Index test	Reference standard	Flow & timing
59 Pfizer	Saudi Arabia	27/M	2nd	1 case	PE(1)	-	NS	Esba et al.[91]	NA	NA	NA	NA
60 Pfizer or Moderna	US	< 50/F	1st, 2nd	13.6million persons	Thrombosis(14), stroke (18), MI(11), PE(25)	1 × 10 ⁻⁶	NS	Sessa et al.[111]	⊕	?	?	⊕
61 Pfizer & Moderna	US	22-74	NS	20 cases	Thrombocytopenia(20), ICB, death(1), CVST(1)	-	NS	Lee et al.[112]	NA	NA	NA	NA
62 Pfizer	Malaysia	49/M	1st,2nd	1 case	CVST(1)	-	NS	Zakaria et al.[113]	NA	NA	NA	NA
63 Pfizer	Singapore	54/M, 62/F, 60/F	2nd	3 cases	CVST(3), ICB(3), SAH(2)	-	N(1) NS(2)	Fan et al.[114]	NA	NA	NA	NA
64 Moderna	US	NS	NS	84.7 million doses	CVST with normal platelet(3)	4 × 10 ⁻⁸	NS	ACIP[99]	⊕	?	?	⊕
65 Moderna	US	65/M	2nd	1 case	PE, DVT, thrombocytopenia, CVST, death(1)	-	N	Sangi et al.[115]	NA	NA	NA	NA
66 Moderna	US	45/M	2nd	1 case	CVST, ICB, SAH, normal platelet(1)	-	NS	Syed et al.[116]	NA	NA	NA	NA
67 Moderna	France	19-102	NS	325 cases	Venous(13), arterial(253) thrombosis, CVST(3), stroke(173), PE(53), AMI (67), death(53)	-	NS	Smadja et al.[75]	NA	NA	NA	NA

Abbreviation: ACIP, Advisory Committee on Immunization Practices; AMI, acute myocardial infarction; AZ, AstraZeneca; CVST, cerebral venous sinus thrombosis; CVT, cerebral vein thrombosis; DVT, deep vein thrombosis; FDA, food and drug administration; ICB, intracerebral bleeding; MHRA, Medicine and healthcare products regulatory agency; N, negative; NS, not specified; P, positive; PE, pulmonary thromboembolism; SAH, Subarachnoid hemorrhage; VITT, vaccine induced immune thrombotic thrombocytopenia; ⊕, low risk; ⊕, high risk; NA, not applicable.

allergic skin reaction, laryngeal edema and hyperinflated lungs with mucus plugging. Mast cell and eosinophil infiltration of the injection site, airway, lungs, spleen, and gastrointestinal tract are remarkable histological findings. Technically, morphological study and calculating the number of mast cells is important to confirm the mast cell infiltration and to differentiate it from other conditions, such as systemic mastocytosis, myelodysplastic syndrome or mast cell leukaemia.

For the biochemistry investigation, serum tryptase should be taken immediate for analysis. Tryptase is rapidly released from mast cell with peak level within 1–2 h after exposure to allergen. Serum tryptase has a half-life of 2 h, its level is rapidly depleted if the survivor period or postmortem interval are prolonged [124]. The normal level of tryptase level does not exclude the possibility of anaphylaxis. On the contrary, serum tryptase levels can be elevated in a variety of non-anaphylactic conditions, for example Gaucher's disease, parasitic infections, haematological malignancies, cardiovascular disease, chronic kidney disease etc [125].

Testing of specific IgE toward PEG or anti-PEG IgG may demonstrate the PEG-mediated allergic reaction. However, non-IgE activation of mast cells should be considered, it was previously known as anaphylactoid reaction. They shared similar clinical features and responses to epinephrine treatment. The non-IgE mediated pathways, such as complement activation, C3, or C5 might trigger allergic reactions even on the first exposure of allergen [3].

4.2. Myocarditis

Myocarditis is generally observed in mRNA vaccine cohort, predominantly in adolescent male and onset within 2–4 days after 2nd dose of vaccination. In clinical setting, patient may present with acute myocardial infarction like syndrome, new onset of arrhythmia or heart block, fulminant heart failure and sudden cardiac death. Laboratory investigation included endomyocardial biopsy (Dallas criteria), elevated cardiac enzymes and inflammatory biomarkers eg ESR, D-dimer and CRP. Routine clinical imaging study eg cardiac MRI, Echocardiography and ECG will also aid in diagnosis [126].

Postmortem diagnosis of myocarditis requires histology confirmation of myocardial damage and inflammatory cells infiltration [127]. However, histological study is insufficient to determine the etiology and there is no specific testing to link the myocarditis to vaccination. Biological markers, such as Troponin or Creatine Kinase (CK)-MB could be utilized in supporting the diagnosis of myocarditis [127]. Microbiological analysis of serum, pericardial fluid, and myocardium should be collected as soon as practicable [128]. As viral infection is the most common cause of myocarditis, RT-PCR or viral culture could be useful in identifying the type of infectious agent and ruling out the possibility of post-vaccine death.

Ascertained with other cardiac pathology, for example, ischemic heart disease is important. Although exacerbation of underlying cardiac conditions has been reported with the vaccination, the causality between vaccination and underlying heart disease has yet to be established.

4.3. Vaccine-induced immune thrombotic thrombocytopenia (VITT)

VITT is a life-threatening thrombosis with thrombocytopenia syndrome (TTS) characterized by venous or arterial thrombosis with mild to severe degree of thrombocytopenia. Thrombocytopenia was reported to have a higher occurrence in adenoviral-based vector vaccines [129]. Furthermore, a higher incidence of VITT was observed in women with a mean age of 35-year-old [67]. The onset of VITT is reported within 5–24 days after AstraZeneca or Janssen vaccination [130].

Clinically, Brighton Collaboration case definition of thrombosis and thromboembolism is used in evaluation of adverse reaction following vaccination, which included scoring system: Wells score and revised Geneva score, D-dimer, targeted organ biopsy, compression ultrasonography (DVT), CT pulmonary angiography (pulmonary thromboembolism) and contrast CT, MR venography (CVST, stroke) etc. [131].

The primary focus of an autopsy is to seek evidence of thrombosis in damaged organs. Careful dissection of arteries and veins is needed to detect the thrombus and demonstrate ischemic or hemorrhagic infarction in serial sections of organs especially cerebral venous sinuses. Of note, Hippisley-Cox et al. (2021) study reported an increased risk of thrombocytopenia, venous thromboembolism, and arterial thrombotic events in a short time interval after AstraZeneca vaccination, while arterial thromboembolism and ischemic stroke is more frequently observed after Pfizer vaccination [59].

Several studies reported the detection of anti-PF4 antibodies in cadaveric blood in post-SARS-CoV-2 vaccination patient blood [79,132]. Therefore, immediate collection of fresh blood for the analysis of anti-PF4 antibodies is recommended. Postmortem confirmation of thrombocytopenia is difficult as the level of platelet is normally depleted after death, especially in prolonged postmortem intervals. Functional platelet activation assays such as PF4 induced platelet activation test (PIPA) and heparin-induced platelet activation test (HIPA), could serve as alternative way to identify identification of VITT, which is not significantly affected by postmortem interval [69,133].

Finally, to ascertain the causal relationship of death with vaccination, a multidisciplinary approach is required for assessing each case of death after vaccination by integrating epidemiological data, risk factors, clinical information, postmortem findings, and laboratory studies. (Tables 4 and 5).

Table 4
Summary of order of incidence and total number of reported cases.

Adverse reaction	Parameter	First	Second	Third	Fourth
Anaphylaxis	Total number of cases	Pfizer	AstraZeneca	Moderna	Janssen
	Incidence	Moderna	Pfizer	AstraZeneca	Janssen
Myocarditis	Total number of cases	Pfizer	Moderna	AstraZeneca	Janssen
	Incidence	Pfizer	Moderna	Janssen	AstraZeneca
Thrombosis	Total number of cases	AstraZeneca	Pfizer	Janssen	Moderna
	Incidence	AstraZeneca	Pfizer	Janssen	Moderna

Table 5
Checklist for postmortem examination in vaccination-related death.

Past medical history and vaccine information
General
<ul style="list-style-type: none"> Comorbidity: heart disease, pulmonary disease, coagulopathy History of COVID-19 infection.
Vaccine related information
<ul style="list-style-type: none"> Number of vaccination dose Type and batch of vaccine Data and time of onset of symptom Time interval between vaccination and death
Anaphylaxis
<ul style="list-style-type: none"> History of an allergy reaction, type of reaction, and allergen History of exposure to allergen other than vaccine e.g. food, medication Clinical symptoms of wheezing, shortness of breath, cough, cyanosis, rhinorrhea, tachycardia, hypotension, syncope, nausea, vomiting, abdominal pain, or diarrhea.
Myocarditis
<ul style="list-style-type: none"> History of recent fever, upper respiratory tract infection, arthralgia, pharyngitis, tonsillitis, medication, or toxin exposure. Clinical symptoms of chest pain, fever, dyspnea, or palpitation.
VITT
<ul style="list-style-type: none"> History of using contraception, heparin, prolonged immobility, skin rashes. Medical history of diabetes mellitus, obesity, antiphospholipid syndrome, coagulopathy
Internal & external examination
Anaphylaxis
<ul style="list-style-type: none"> Injection site reaction Local or generalized skin rash eg urticaria, erythema, angioedema Pneumothorax assessment Respiratory tract: laryngeal edema, hyperinflated lung, mucus plugging Gastrointestinal tract anomaly
Myocarditis
<ul style="list-style-type: none"> Macro & microscopical feature of myocarditis: Cardiac hypertrophy, cardiac ventricular dilatation, pale or hemorrhagic foci of myocardium, histological type of inflammation of myocardium.
VITT
<ul style="list-style-type: none"> Macro & microscopical feature of thromboembolism: thrombosis (CVST, CVT, jugular, splanchnic, hepatic, portal, renal, mesenteric vein, deep vein of lower limb, pulmonary trunk, carotid artery), ischemic or hemorrhagic cerebral infarction, myocardial infarction, bowel ischemia and finger gangrene.
Laboratory investigation
General investigation
<ul style="list-style-type: none"> Upper (nasopharyngeal, oropharyngeal) and lower (sputum, tracheal, lung) respiratory tract swab for COVID-19 Blood culture for bacterial and fungal organism Toxicology analysis Extensive histopathological examination of targeted organs and representative sampling of other organs.
Anaphylaxis
<ul style="list-style-type: none"> Serum tryptase, Total Ig E, specific IgE (PEG), anti-PEG antibody, interleukin-6, CRP, complement factor 3,5[134] Histopathological examination of injection site (skin, deltoid muscle, axillary lymph node), respiratory tract (pharyngeal mucosa, epiglottis, trachea, bronchi, all the lung lobes), GIT tract, myocardium, coronary arteries and spleen for mast cell and eosinophil infiltration. Mast cell identification and quantification using Giemsa and immunostaining e.g. CD117, anti-tryptase, and anti-chymase antibody. Normal number of mast cell in: Lung (0.051 per HPF), skin (0.79 per HPF), colon (13 per HPF)[135–137]
Myocarditis
<ul style="list-style-type: none"> Troponin, CK-MB[127] Blood, pericardial fluid, myocardium for PCR and viral culture for cardiotropic virus e.g. influenza, adenovirus, enterovirus, cytomegalovirus, Epstein-Barr virus, Herpes simplex virus. Human Herpes virus 6, Mycoplasma, Syphilis, Leptospiral, Borrelia burgdorferi serology
VITT
<ul style="list-style-type: none"> Platelet factor 4 (PF4) concentration
Other
<ul style="list-style-type: none"> Proper storage of extra blood and tissue samples for future investigation.

5. Conclusions

This study presented the incident, onset, histopathology and biochemistry analysis of major post-vaccination lethally side effects.

The precensuring clinical trial does not represent the overall incidence of vaccine side effects; passive surveillance, identifying and weighting the potential side effect against the advantages after vaccination are important. An immediate standardized autopsy approach, histopathology and biochemistry analysis is required to improve the investigation the causality of post-vaccination death. Through improving the accuracy of investigation, a guideline of vaccine selection could be suggested and decrease the mortality rate of post-vaccination. The safety of vaccination is the top priority of SARS-CoV-2 battle and gain public confidence in vaccination program.

CRedit authorship contribution statement

Lii Jye Tan: Conceptualization, Methodology, Formal analysis, Investigation, Resources, Writing – original draft, Writing – review & editing. **Cai Ping Koh:** Conceptualization, Methodology, Formal analysis, Writing – review & editing. **Shau Kong Lai:** Formal analysis, Investigation, Resources, Writing – original draft. **Wong Cheng Poh:** Formal analysis, Investigation, Resources. **Mohammad Shafie Othman:** Investigation, Resources, Visualization, Supervision. **Huzlinda Hussin:** Investigation, Resources, Visualization, Supervision.

Declaration of Competing Interest

None.

Acknowledgements

The authors thank the Director-General of Ministry of Health Malaysia, Director of Perak State Health Department, Dean of Faculty of Medicine, Quest University and those who helped and assisted in the preparation and publication of this article.

References

- A. Oliva, et al., Liability of Health Care Professionals and Institutions during COVID-19 pandemic in Italy: symposium proceedings and position statement, *J. Patient Saf.* 16 (4) (2020) e299–e302, <https://doi.org/10.1097/PTS.0000000000000793>
- S. Halabi, A. Heinrich, S.B. Omer, No-fault compensation for vaccine injury - the other side of equitable access to Covid-19 vaccines, *N. Engl. J. Med.* 383 (23) (2020) e125, <https://doi.org/10.1056/NEJMp2030600>
- R.G. Mungwira, et al., Global landscape analysis of no-fault compensation programmes for vaccine injuries: a review and survey of implementing countries, *PLoS One* 15 (5) (2020) e0233334, <https://doi.org/10.1371/journal.pone.0233334>
- P.C. Fragkou, D. Dimopoulou, Serious complications of COVID-19 vaccines: a mini-review, *Metab. Open* 12 (2021) 100145, <https://doi.org/10.1016/j.metop.2021.100145>
- C. Pomara, et al., COVID-19 vaccine and death: causality algorithm according to the WHO eligibility diagnosis, *Diagnosis* 11 (6) (2021), <https://doi.org/10.3390/diagnostics11060955>
- L. Schoenmaker, D. Witzigmann, J.A. Kulkarni, R. Verbeke, G. Kersten, W. Jiskoot, D.J.A. Crommelin, mRNA-lipid nanoparticle COVID-19 vaccines: structure and stability, *Int. J. Pharm.* 601 (2021) 120586, <https://doi.org/10.1016/j.ijpharm.2021.120586>
- A. Banerji, P.G. Wickner, R. Saff, C.A.Jr Stone, L.B. Robinson, A.A. Long, A.R. Wolfson, P. Williams, D.A. Khan, E. Phillips, K.G. Blumenthal, mRNA vaccines to prevent COVID-19 disease and reported allergic reactions: current evidence and suggested approach, *J. Allergy Clin. Immunol. Pract.* 9 (4) (2021) 1423–1437, <https://doi.org/10.1016/j.jaip.2020.12.047>
- C. Pomara, et al., COVID-19 vaccine and death: causality algorithm according to the WHO eligibility diagnosis, *Diagnosis* 11 (6) (2021).
- Oster M.E., Shay D.K., Su J.R., Gee J., Creech C.B., Broder K.R., Edwards K., Soslow J.H., Dendy J.M., Schlaudecker E., Lang S.M., Barnett E.D., Ruberg F.L., Smith M.J., Campbell M.J., Lopes R.D., Sperling L.S., Baumblatt J.A., Thompson D.L., Marquez P.L., Strid P., Woo J., Pugsley R., Reagan-Steiner S., DeStefano F., Shimabukuro T.T., Myocarditis Cases Reported After mRNA-Based COVID-19 Vaccination in the US From December 2020 to August 2021, *JAMA.* 2022 Jan 25, 327(4):331–340. (<https://doi.org/10.1001/jama.2021.24110>).

- [10] Higgins J, Green S. Cochrane Handbook for Systematic Reviews of interventions, Version 5.1.02011.
- [11] ATLAS.ti Scientific Software Development GmBH. ATLAS.ti (internet). ATLAS.ti Scientific Software Development GmBH, Berlin, 1993. (<https://atlasti.com>). (Accessed 11 February 2022).
- [12] M.D. McSweeney, M. Mohan, S.P. Commins, S.K. Lai, Anaphylaxis to Pfizer/BioNTech mRNA COVID-19 Vaccine in a Patient with Clinically Confirmed PEG Allergy. *Front. Allergy* 2 (2021) 715844, <https://doi.org/10.3389/falgy.2021.715844>
- [13] P. Sellaturay, S. Nasser, S. Islam, P. Gurugama, P.W. Ewan, Polyethylene glycol (PEG) is a cause of anaphylaxis to the Pfizer/BioNTech mRNA COVID-19 vaccine. *Clin. Exp. Allergy* 51 (6) (2021) 861–863, <https://doi.org/10.1111/cea.13874>
- [14] J. Vieira, J. Marcelino, F. Ferreira, S. Farinha, R. Silva, M. Proença, E. Tomaz, Skin testing with Pfizer SARS-CoV-2 vaccine and PEG 2000. *Asian Pac. Allergy* 11 (2) (2021) e18, <https://doi.org/10.5415/apallergy.2021.11.e18>
- [15] A.C. Leasure, S.E. Cowper, J. McNiff, J.M. Cohen, Generalized eczematous reactions to the Pfizer-BioNTech COVID-19 vaccine. *J. Eur. Acad. Dermatol. Venereol.* 35 (11) (2021) e716–e717, <https://doi.org/10.1111/jdv.17494>
- [16] D. Fernandez-Nieto, J. Hammerle, M. Fernandez-Escribano, C.M. Moreno-Del Real, P. Garcia-Abellas, I. Carretero-Barrio, E. Solano-Solares, B. de-la-Hoz-Caballer, J. Jimenez-Cauhe, D. Ortega-Quijano, M. Fernandez-Guarino, Skin manifestations of the BNT162b2 mRNA COVID-19 vaccine in healthcare workers. 'COVID-arm': a clinical and histological characterization. *J. Eur. Acad. Dermatol. Venereol.* 35 (7) (2021) e425–e427, <https://doi.org/10.1111/jdv.17250>
- [17] United Kingdom. Medicines & Healthcare Products Regulatory Agency. Coronavirus vaccination program: information for healthcare practitioners [Internet]. London: Crown Copyright, 2022. (https://assets.publishing.service.gov.uk/government/uploads/system/uploads/attachment_data/file/1059979/COVID-19_vaccine_Information_for_healthcare_practitioners_10032022.pdf) (Accessed 11 March 2022).
- [18] M. Ackerman, D. Henry, A. Finon, R. Binois, E. Esteve, Persistent maculopapular rash after the first dose of Pfizer-BioNTech COVID-19 vaccine. *J. Eur. Acad. Dermatol. Venereol.* 35 (7) (2021) e423–e425, <https://doi.org/10.1111/jdv.17248>
- [19] V.G. Athyros, M. Doumas, A possible case of hypertensive crisis with intracranial haemorrhage after an mRNA Anti-COVID-19 vaccine. *Angiology* 73 (1) (2022) 87, <https://doi.org/10.1177/00033197211018323>
- [20] K.G. Blumenthal, E.E. Freeman, R.R. Saff, L.B. Robinson, A.R. Wolfson, R.K. Foreman, D. Hashimoto, A. Banerji, L. Li, S. Anvari, E.S. Shenoy, Delayed large local reactions to mRNA-1273 vaccine against SARS-CoV-2. *N. Engl. J. Med.* 384 (13) (2021) 1273–1277, <https://doi.org/10.1056/NEJMc2102131>
- [21] A. Singh, R. Khillan, Y. Mishra, S. Khurana, The safety profile of COVID-19 vaccinations in the United States. *Am. J. Infect. Control* S0196–6553 (21) (2021) 00684–2, <https://doi.org/10.1016/j.ajic.2021.10.015>
- [22] J. Gee, P. Marquez, J. Su, G.M. Calvert, R. Liu, T. Myers, N. Nair, S. Martin, T. Clark, L. Markowitz, N. Lindsey, B. Zhang, C. Licata, A. Jazwa, M. Sotir, T. Shimabukuro, First month of COVID-19 vaccine safety monitoring - United States, December 14, 2020–January 13, 2021. *MMWR Morb. Mortal. Wkly Rep.* 70 (8) (2021) 283–288, <https://doi.org/10.15585/mmwr.mm7008e3>
- [23] CDC COVID-19 Response Team, Food and Drug Administration. Allergic reactions including anaphylaxis after receipt of the first dose of Pfizer-BioNTech COVID-19 Vaccine - United States, December 14–23, 2020. *MMWR Morb Mortal Wkly Rep.* 2021 Jan 15, 70(2):46–51. <https://doi.org/10.15585/mmwr.mm7002e1>
- [24] R.A.K. Kadali, R. Janagama, S. Peruru, V. Gajula, R.R. Madathala, N. Chennaiahgari, S.V. Malayala, Non-life-threatening adverse effects with COVID-19 mRNA-1273 vaccine: a randomized, cross-sectional study on healthcare workers with detailed self-reported symptoms. *J. Med. Virol.* 93 (7) (2021) 4420–4429, <https://doi.org/10.1002/jmv.26996>
- [25] B. Kaplan, S. Farzan, G. Coscia, D.W. Rosenthal, A. McInerney, A.M. Jongco, P. Ponda, V.R. Bonagura, Allergic reactions to coronavirus disease 2019 vaccines and addressing vaccine hesitancy: Northwell Health experience. *Ann. Allergy Asthma Immunol.* 128 (21) (2021) 01172–8, <https://doi.org/10.1016/j.ana.2021.10.019>
- [26] U.S. Food and Drug Administration. Pfizer-BioNTech COVID-19 vaccine (BNT162, PF-07302048) [FDA briefing document]. Silver Spring, MD: U.S. Food and Drug Administration, Vaccines and Related Biological Products Advisory Committee; 2020. <https://www.fda.gov/media/144246/download>. (Accessed 24 December 2020).
- [27] A. Frank, S. Radparvar, A. Manasia, A. Bassily-Marcus, R. Kohli-Seth, Prolonged anaphylaxis to Pfizer coronavirus disease 2019 vaccine: a case report and mechanism of action. *Crit. Care Explor* 3 (4) (2021) e0397, <https://doi.org/10.1097/CCE.0000000000000397>
- [28] H.J. Park, J.R. Montgomery, N.A. Boggs, Anaphylaxis after the Covid-19 vaccine in a patient with cholinergic urticaria. *Mil. Med.* (2021) usab138, <https://doi.org/10.1093/milmed/usab138>
- [29] Ontario Agency for Health Protection and Promotion (Public Health Ontario). Reports of Events Managed as Anaphylaxis Following COVID-19 Vaccines in Ontario: December 13, 2020 to March 6, 2021. <https://www.publichealthontario.ca/-/media/documents/ncov/epi/covid-19-anaphylaxis-epi-summary.pdf?la=en>. (Accessed 29 May 2021).
- [30] E. Vanegas, K. Robles-Velasco, M.F. Osorio, M.J. Farfán Bajaña, Z. Sarfraz, A. Sarfraz, J.C. Fernández Cadena, D.M. Andrade Molina, M. Panchana Lascano, I. Cherrez-Ojeda, Adverse reactions following COVID-19 vaccination: an Ecuadorian experience. *Ann. Med Surg.* 72 (2021) 103044, <https://doi.org/10.1016/j.amsu.2021.103044>
- [31] Ossato A, Tessari R, Trabucchi C, Zuppini T, Realdon N, Marchesini F, Comparison of medium-term adverse reactions induced by the first and second dose of mRNA BNT162b2 (Comirnaty, Pfizer-BioNTech) vaccine: a post-marketing Italian study conducted between 1 January and 28 February 2021. *Eur J Hosp Pharm.* 2021 Jul 27:ejhpharm-2021-002933. <https://doi.org/10.1136/ejhpharm-2021-002933>
- [32] V. Restivo, G. Candore, M. Barrale, E. Caravello, G. Graziano, R. Onida, M. Raineri, S. Tiralongo, I. Brusca, Allergy to polyethylenglicole of anti-SARS CoV2 vaccine recipient: a case report of young adult recipient and the management of future exposure to SARS-CoV2. *Vaccine* 9 (5) (2021) 412, <https://doi.org/10.3390/vaccines9050412>
- [33] R. Shavit, R. Maoz-Segal, M. Iancovici-Kidon, I. Offengenden, S. Haj Yahia, D. Machnes Maayan, Y. Lifshitz-Tunitsky, S. Niznik, S. Frizinsky, M. Deutch, E. Elbaz, H. Genaim, G. Rahav, I. Levy, A. Belkin, G. Regev-Yochay, A. Afek, N. Agmon-Levin, Prevalence of allergic reactions after Pfizer-BioNTech COVID-19 vaccination among adults with high allergy risk. *JAMA Netw. Open* 4 (8) (2021) e2122255, <https://doi.org/10.1001/jamanetworkopen.2021.22255>
- [34] C. Abi Zeid Daou, M.A. Natout, N. El Hadi, Biphasic anaphylaxis after exposure to the first dose of Pfizer-BioNTech COVID-19 mRNA vaccine. *J. Med Virol.* 93 (10) (2021) 6027–6029, <https://doi.org/10.1002/jmv.27109>
- [35] J.Y. Song, H.J. Cheong, S.R. Kim, S.E. Lee, S.H. Kim, J.Y. Noh, Y.K. Yoon, W.S. Choi, D.W. Park, J.W. Sohn, W.J. Kim, M.J. Kim, Early safety monitoring of COVID-19 vaccines in healthcare workers. *J. Korean Med. Sci.* 36 (15) (2021) e110, <https://doi.org/10.3346/jkms.2021.36.e110>
- [36] T. Iguchi, H. Umeda, M. Kojima, Y. Kanno, Y. Tanaka, N. Kinoshita, D. Sato, Cumulative adverse event reporting of anaphylaxis after mRNA COVID-19 vaccine (Pfizer-BioNTech) injections in Japan: the first-month report. *Drug Saf.* 44 (11) (2021) 1209–1214, <https://doi.org/10.1007/s40264-021-01104-9>
- [37] T. Hashimoto, A. Ozaki, D. Bhandari, T. Sawano, R. Sah, T. Tanimoto, High anaphylaxis rates following vaccination with the Pfizer BNT162b2 mRNA vaccine against COVID-19 in Japanese healthcare workers: a secondary analysis of initial post-approval safety data. *J. Travel Med* 28 (7) (2021) taab090, <https://doi.org/10.1093/jtm/taab090>
- [38] T. Shimabukuro, Allergic reactions including anaphylaxis after receipt of the first dose of Moderna COVID-19 vaccine - United States, December 21, 2020–January 10, 2021. *Am. J. Transpl.* 21 (3) (2021) 1326–1331, <https://doi.org/10.1111/ajt.16517>
- [39] A.M. Hause, J. Gee, J. Baggs, W.E. Abara, P. Marquez, D. Thompson, J.R. Su, C. Licata, H.G. Rosenblum, T.R. Myers, T.T. Shimabukuro, D.K. Shay, COVID-19 vaccine safety in adolescents aged 12–17 Years - United States, December 14, 2020–July 16, 2021. *MMWR Morb. Mortal. Wkly Rep.* 70 (31) (2021) 1053–1058, <https://doi.org/10.15585/mmwr.mm7031e1>
- [40] J.W. Gargano, M. Wallace, S.C. Hadler, G. Langley, J.R. Su, M.E. Oster, K.R. Broder, J. Gee, E. Weintraub, T. Shimabukuro, H.M. Scobie, D. Moulia, L.E. Markowitz, M. Wharton, V.V. McNally, J.R. Romero, H.K. Talbot, G.M. Lee, M.F. Daley, S.E. Oliver, Use of mRNA COVID-19 vaccine after reports of myocarditis among vaccine recipients: update from the advisory committee on immunization practices - United States, June 2021. *MMWR Morb. Mortal. Wkly Rep.* 70 (27) (2021) 977–982, <https://doi.org/10.15585/mmwr.mm7027e2>
- [41] A. Dionne, F. Sperotto, S. Chamberlain, A.L. Baker, A.J. Powell, A. Prakash, D.A. Castellanos, S.F. Saleeb, S.D. de Ferranti, J.W. Newburger, K.G. Friedman, Association of myocarditis with BNT162b2 messenger RNA COVID-19 vaccine in a case series of children. *JAMA Cardiol.* 6 (12) (2021) 1446–1450, <https://doi.org/10.1001/jamacardio.2021.3471>
- [42] M. Marshall, I.D. Ferguson, P. Lewis, P. Jaggi, C. Gagliardo, J.S. Collins, R. Shaughnessy, R. Caron, C. Fuss, K.J.E. Corbin, L. Emuren, E. Faherty, E.K. Hall, C. Di Pentima, M.E. Oster, E. Painsil, S. Siddiqui, D.M. Timchak, J.A. Guzman-Cottrill, Symptomatic acute myocarditis in 7 adolescents after Pfizer-BioNTech COVID-19 vaccination. *Pediatrics* 148 (3) (2021) e2021052478, <https://doi.org/10.1542/peds.2021-052478>
- [43] J. Montgomery, M. g. R. Engler, D. Hoffman, B. McClenathan, L. Collins, D. Loran, D. Hrcncir, K. Herring, M. Platzer, N. Adams, A. Sanou, L.T. Cooper Jr., Myocarditis following immunization with mRNA COVID-19 vaccines in members of the US military. *JAMA Cardiol.* 6 (10) (2021) 1202–1206, <https://doi.org/10.1001/jamacardio.2021.2833>
- [44] C.M. Rosner, L. Genovese, B.N. Tehrani, M. Atkins, H. Bakshsi, S. Chaudhri, A.A. Damluji, J.A. de Lemos, S.S. Desai, A. Emaminia, M.C. Flanagan, A. Khera, A. Maghsoudi, G. Mekonnen, A. Muthukumar, I.M. Saeed, M.W. Sherwood, S.S. Sinha, C.M. O'Connor, C.R. deFilippi, Myocarditis temporally associated with COVID-19 vaccination. *Circulation* 144 (6) (2021) 502–505, <https://doi.org/10.1161/CIRCULATIONAHA.121.055891>
- [45] H.W. Kim, E.R. Jenista, D.C. Wendell, C.F. Azevedo, M.J. Campbell, S.N. Darty, M.A. Parker, R.J. Kim, Patients with acute myocarditis following mRNA COVID-19 vaccination. *JAMA Cardiol.* 6 (10) (2021) 1196–1201, <https://doi.org/10.1001/jamacardio.2021.2828>
- [46] V.L. Bartlett, A. Thomas, D.J. Hur, B. Malm, Myopericarditis with significant left ventricular dysfunction following COVID-19 vaccination: a case report. *Am. J. Case Rep.* 22 (2021) e934066, <https://doi.org/10.12659/AJCR.934066>
- [47] K. McLean, T.J. Johnson, Myopericarditis in a previously healthy adolescent male following COVID-19 vaccination: a case report. *Acad. Emerg. Med.* 28 (8) (2021) 918–921, <https://doi.org/10.1111/acem.14322>
- [48] D. Levin, G. Shimom, M. Fadlon-Derai, L. Gershovitz, A. Shovali, A. Sebbag, S. Bader, N. Fink, B. Gordon, Myocarditis following COVID-19 vaccination - a case series. *Vaccine* 39 (42) (2021) 6195–6200, <https://doi.org/10.1016/j.vaccine.2021.09.004>

- [49] S. Abu Mouch, A. Roguin, E. Hellou, A. Ishai, U. Shoshan, L. Mahamid, M. Zoabi, M. Aisman, N. Goldschmid, N. Berar Yanay, Myocarditis following COVID-19 mRNA vaccination, *Vaccine* 39 (29) (2021) 3790–3793, <https://doi.org/10.1016/j.vaccine.2021.05.087>
- [50] K.F. Larson, E. Ammirati, E.D. Adler, L.T. Cooper Jr, K.N. Hong, G. Saponara, D. Couri, A. Cereda, A. Procopio, C. Cavalotti, F. Oliva, T. Sanna, V.A. Cicone, G. Onyango, D.R. Holmes, D.D. Borgeson, Myocarditis after BNT162b2 and mRNA-1273 vaccination, *Circulation* 144 (6) (2021) 506–508, <https://doi.org/10.1161/CIRCULATIONAHA.121.056933>
- [51] E. Ammirati, C. Cavalotti, A. Milazzo, P. Pedrotti, F. Soriano, J.W. Schroeder, N. Morici, C. Giannattasio, M. Frigerio, M. Metra, P.G. Camici, F. Oliva, Temporal relation between second dose BNT162b2 mRNA Covid-19 vaccine and cardiac involvement in a patient with previous SARS-CoV-2 infection, *Int. J. Cardiol. Heart Vasc.* 34 (2021) 100774, <https://doi.org/10.1016/j.ijcha.2021.100774>
- [52] S. Facetti, M. Giraldo, A.L. Vecchi, S. Rogiani, D. Nassiaco, Myocardite acuta in giovane adulto due giorni dopo vaccino Pfizer [Acute myocarditis in a young adult two days after Pfizer vaccination] (Italian), *G Ital. Cardiol.* 22 (11) (2021) 891–893, <https://doi.org/10.1714/3689.36746>
- [53] D. Kim, J.H. Choi, J.Y. Jang, O. So, E. Cho, H. Choi, K.S. Hong, K.T. Park, A case report for myopericarditis after BNT162b2 COVID-19 mRNA vaccination in a Korean young male, *J. Korean Med Sci.* 36 (39) (2021) e277, <https://doi.org/10.3346/jkms.2021.36.e277>
- [54] J. Bautista García, P. Peña Ortega, J.A. Bonilla Fernández, A. Cárdenes León, L. Ramírez Burgos, E. Caballero Dorta, Acute myocarditis after administration of the BNT162b2 vaccine against COVID-19, *Rev. Esp. Cardiol. (Engl. Ed.)* 74 (9) (2021) 812–814, <https://doi.org/10.1016/j.rec.2021.04.005>
- [55] P. Schmitt, R. Demoulin, R. Poyet, E. Capilla, G. Rohel, F. Pons, C. Jégo, S. Sidibe, A. Druelle, F.X. Brocq, F. Dutasta, G.R. Cellarier, Acute myocarditis after COVID-19 vaccination: a case report, *Rev. Med. Interne* 42 (11) (2021) 797–800, <https://doi.org/10.1016/j.revmed.2021.10.003>
- [56] E. Albert, G. Aurigemma, J. Saucedo, D.S. Gerson, Myocarditis following COVID-19 vaccination, *Radiol. Case Rep.* 16 (8) (2021) 2142–2145, <https://doi.org/10.1016/j.radcr.2021.05.033>
- [57] A. Muthukumar, M. Narasimhan, Q.Z. Li, L. Mahimainathan, I. Hitto, F. Fuda, K. Batra, X. Jiang, C. Zhu, J. Schoggins, J.B. Cutrell, C.L. Croft, A. Khera, M.H. Drazner, J.L. Grodin, B.M. Greenberg, P.P.A. Mammen, S.J. Morrison, J.A. de Lemos, In-depth evaluation of a case of presumed myocarditis after the second dose of COVID-19 mRNA vaccine, *Circulation* 144 (6) (2021) 487–498, <https://doi.org/10.1161/CIRCULATIONAHA.121.056038>
- [58] T. D'Angelo, A. Cattafi, M.L. Carerj, C. Booz, G. Ascenzi, G. Cicero, A. Blandino, S. Mazziotti, Myocarditis after SARS-CoV-2 vaccination: a vaccine-induced reaction, *Can. J. Cardiol.* 37 (10) (2021) 1665–1667, <https://doi.org/10.1016/j.cjca.2021.05.010>
- [59] J. Hippisley-Cox, M. Patone, X.W. Mei, D. Saatci, S. Dixon, K. Khunti, F. Zaccardi, P. Watkinson, M. Shankar-Hari, J. Doidge, D.A. Harrison, S.J. Griffin, A. Sheikh, C.A.C. Coupland, Risk of thrombocytopenia and thromboembolism after covid-19 vaccination and SARS-CoV-2 positive testing: self-controlled case series study, *BMJ* 374 (2021) n1931, <https://doi.org/10.1136/bmj.n1931>
- [60] M. Scully, D. Singh, R. Lown, A. Poles, T. Solomon, M. Levi, D. Goldblatt, P. Kotoucek, W. Thomas, W. Lester, Pathologic antibodies to platelet factor 4 after ChAdOx1 nCoV-19 vaccination, *N. Engl. J. Med.* 384 (23) (2021) 2202–2211, <https://doi.org/10.1056/NEJMoa2105385>
- [61] B. Bikkeli, S. Chatterjee, S. Arora, M. Monreal, D. Jimenez, H.M. Krumholz, S.Z. Goldhaber, M.S.V. Elkind, G. Piazza, Cerebral venous sinus thrombosis in the U.S. population, after adenovirus-based SARS-CoV-2 vaccination, and after COVID-19, *J. Am. Coll. Cardiol.* 78 (4) (2021) 408–411, <https://doi.org/10.1016/j.jacc.2021.06.001>
- [62] P.R. Mehta, S. Apap Mangion, M. Bengler, B.R. Stanton, J. Czuprynska, R. Arya, L.K. Sztrihai, Cerebral venous sinus thrombosis and thrombocytopenia after COVID-19 vaccination - a report of two UK cases, *Brain Behav. Immun.* 95 (2021) 514–517, <https://doi.org/10.1016/j.bbi.2021.04.006>
- [63] S. Ramdeny, A. Lang, S. Al-Izzi, A. Hung, I. Anwar, P. Kumar, Management of a patient with a rare congenital limb malformation syndrome after SARS-CoV-2 vaccine-induced thrombosis and thrombocytopenia (VITT), *Br. J. Haematol.* 195 (3) (2021) 299, <https://doi.org/10.1111/bjh.17619>
- [64] P. Suresh, W. Petchey, ChAdOx1 nCoV-19 vaccine-induced immune thrombotic thrombocytopenia and cerebral venous sinus thrombosis (CVST), *BMJ Case Rep.* 14 (6) (2021) e243931, <https://doi.org/10.1136/bcr-2021-243931>
- [65] A.L. Tølbøll Sørensen, M. Rolland, J. Hartmann, Z.B. Harboe, C. Roed, T.Ø. Jensen, L. Kolte, D. El Fassi, J. Hillingsø, A. Radziwon-Balicka, R.S. Soyka, K. Hansen, N. Kirkby, J.P. Goetze, M. Gybel-Brask, E.B. Leinøe, A.M. Hvas, P. Kampmann, J. Stensballe, A case of thrombocytopenia and multiple thromboses after vaccination with ChAdOx1 nCoV-19 against SARS-CoV-2, *Blood Adv.* 5 (12) (2021) 2569–2574, <https://doi.org/10.1182/bloodadvances.2021004904>
- [66] T. Al-Mayhani, S. Saber, M.J. Stubbs, N.A. Losseff, R.J. Perry, R.J. Simister, D. Gull, H.R. Jäger, M.A. Scully, D.J. Werring, Ischaemic stroke as a presenting feature of ChAdOx1 nCoV-19 vaccine-induced immune thrombotic thrombocytopenia, *J. Neurol. Neurosurg. Psychiatry* 92 (11) (2021) 1247–1248, <https://doi.org/10.1136/jnnp-2021-326984>
- [67] M. Lavin, P.T. Elder, D. O'Keefe, H. Enright, E. Ryan, A. Kelly, E. El Hassadi, F.P. McNicholl, G. Benson, G.N. Le, M. Byrne, K. Ryan, N.M. O'Connell, J.S. O'Donnell, Vaccine-induced immune thrombotic thrombocytopenia (VITT) - a novel clinico-pathological entity with heterogeneous clinical presentations, *Br. J. Haematol.* 195 (1) (2021) 76–84, <https://doi.org/10.1111/bjh.17613>
- [68] A. van de Munchhof, K. Krzywicka, D. Aguiar de Sousa, M. Sánchez van Kammen, M.R. Heldner, K. Jood, E. Lindgren, T. Tatlisumak, J. Putaala, J.A. Kremer Hovinga, S. Middeldorp, M. Levi, M. Arnold, J.M. Ferro, J.M. Coutinho, Declining mortality of cerebral venous sinus thrombosis with thrombocytopenia after SARS-CoV-2 vaccination, *Eur. J. Neurol.* 29 (1) (2022) 339–344, <https://doi.org/10.1111/ene.15113>
- [69] A. Greinacher, T. Thiele, T.E. Warkentin, K. Weisser, P.A. Kyrle, S. Eichinger, Thrombotic thrombocytopenia after ChAdOx1 nCoV-19 vaccination, *N. Engl. J. Med.* 384 (22) (2021) 2092–2101, <https://doi.org/10.1056/NEJMoa2104840>
- [70] T. Graf, T. Thiele, R. Klingebiel, A. Greinacher, W.R. Schäbitz, I. Greeve, Immediate high-dose intravenous immunoglobulins followed by direct thrombin-inhibitor treatment is crucial for survival in Sars-Covid-19-adenoviral vector vaccine-induced immune thrombotic thrombocytopenia VITT with cerebral sinus venous and portal vein thrombosis, *J. Neurol.* 268 (12) (2021) 4483–4485, <https://doi.org/10.1007/s00415-021-10599-2>
- [71] A. Tiede, U.J. Sachs, A. Czwalinna, S. Werwitzke, R. Bikker, J.K. Krauss, F. Donnerstag, K. Weißenborn, G. Höglinger, B. Maasoumy, H. Wedemeyer, A. Ganser, Prothrombotic immune thrombocytopenia after COVID-19 vaccination, *Blood* 138 (4) (2021) 350–353, <https://doi.org/10.1182/blood.2021011958>
- [72] B. Ikenberg, A.F. Demleitner, T. Thiele, B. Wiestler, K. Götz, G. Mößner, P. Lingor, Cerebral venous sinus thrombosis after ChAdOx1 nCoV-19 vaccination with a misleading first cerebral MRI scan, *Stroke Vasc. Neurol.* 6 (4) (2021) 668–670, <https://doi.org/10.1136/svn-2021-001095>
- [73] A. Bayas, M. Menacher, M. Christ, L. Behrens, A. Rank, M. Naumann, Bilateral superior ophthalmic vein thrombosis, ischaemic stroke, and immune thrombocytopenia after ChAdOx1 nCoV-19 vaccination, *Lancet* 397 (10285) (2021) e11, [https://doi.org/10.1016/S0140-6736\(21\)00872-2](https://doi.org/10.1016/S0140-6736(21)00872-2)
- [74] U. Walter, M. Fuchs, A. Grossmann, M. Walter, T. Thiele, A. Storch, M. Wittstock, Adenovirus-vectored COVID-19 vaccine-induced immune thrombosis of carotid artery: a case report, *10.1212/WNL.00000000000012576*, *Neurology* (2021), <https://doi.org/10.1212/WNL.00000000000012576>
- [75] D.M. Smadja, Q.Y. Yue, R. Chocron, O. Sanchez, A. Lillo-Le Louet, Vaccination against COVID-19: insight from arterial and venous thrombosis occurrence using data from VigiBase, *Eur. Respir. J.* 58 (1) (2021) 2100956, <https://doi.org/10.1183/13993003.00956-2021>
- [76] M. Jamme, E. Mosnino, J. Hayon, G. Franchineau, Fatal cerebral venous sinus thrombosis after COVID-19 vaccination, *Intensive Care Med.* 47 (7) (2021) 790–791, <https://doi.org/10.1007/s00134-021-06425-y>
- [77] S. Bersinger, K. Lagarde, R. Marlu, G. Pernod, J.F. Payen, Using nonheparin anticoagulant to treat a near-fatal case with multiple venous thrombotic lesions during ChAdOx1 nCoV-19 vaccination-related vaccine-induced immune thrombotic thrombocytopenia, *Crit. Care Med.* 49 (9) (2021) e870–e873, <https://doi.org/10.1097/CCM.0000000000005105>
- [78] N.H. Schultz, I.H. Sørvoll, A.E. Michelsen, L.A. Munthe, F. Lund-Johansen, M.T. Ahlen, M. Wiedmann, A.H. Aamodt, T.H. Skattør, G.E. Tjønnfjord, P.A. Holme, Thrombosis and thrombocytopenia after ChAdOx1 nCoV-19 vaccination, *N. Engl. J. Med.* 384 (22) (2021) 2124–2130, <https://doi.org/10.1056/NEJMoa2104882>
- [79] T.H. Bjørnstad-Tuveng, A. Rudjord, P. Anker, Fatal cerebral haemorrhage after COVID-19 vaccine (English, Norwegian), *Tidsskr. Nor. Laege* 141 (2021), <https://doi.org/10.4045/tidsskr.21.0312>
- [80] J.F. Varona, M. García-Isidro, M. Moeinvaziri, M. Ramos-López, M. Fernández-Domínguez, Primary adrenal insufficiency associated with Oxford-AstraZeneca ChAdOx1 nCoV-19 vaccine-induced immune thrombotic thrombocytopenia (VITT), *Eur. J. Intern Med* 91 (2021) 90–92, <https://doi.org/10.1016/j.ejim.2021.06.025>
- [81] R.A. Blauenfeldt, S.R. Kristensen, S.L. Ernstsén, C.C.H. Kristensen, C.Z. Simonsen, A.M. Hvas, Thrombocytopenia with acute ischemic stroke and bleeding in a patient newly vaccinated with an adenoviral vector-based COVID-19 vaccine, *J. Thromb. Haemost.* 19 (7) (2021) 1771–1775, <https://doi.org/10.1111/jth.15347>
- [82] V. Muster, T. Gary, R.B. Raggam, A. Wölfler, M. Brodmann, Pulmonary embolism and thrombocytopenia following ChAdOx1 vaccination, *Lancet* 397 (10287) (2021) 1842, [https://doi.org/10.1016/S0140-6736\(21\)00871-0](https://doi.org/10.1016/S0140-6736(21)00871-0)
- [83] G.P. Castelli, C. Pognani, C. Sozzi, M. Franchini, L. Vivona, Cerebral venous sinus thrombosis associated with thrombocytopenia post-vaccination for COVID-19, *Crit. Care* 25 (1) (2021) 137, <https://doi.org/10.1186/s13054-021-03572-y>
- [84] L. Centonze, A. Lauterio, R. De Carlis, F. Ferla, L. De Carlis, Successful liver transplantation from a deceased donor with vaccine-induced thrombotic thrombocytopenia causing cerebral venous sinus and hepatic veins thrombosis after ChAdOx1 nCoV-19 vaccination, *Transplantation* 105 (10) (2021) e144–e145, <https://doi.org/10.1097/TP.0000000000003875>
- [85] V. D'Agostino, F. Caranci, A. Negro, V. Piscitelli, B. Tuccillo, F. Fasano, G. Sirabella, I. Marano, V. Granata, R. Grassi, D. Pupo, R. Grassi, A rare case of cerebral venous thrombosis and disseminated intravascular coagulation temporally associated to the COVID-19 vaccine administration, *J. Pers. Med* 11 (4) (2021) 285, <https://doi.org/10.3390/jpm11040285>
- [86] S. Bonato, A. Artoni, A. Lecchi, G. Schwarz, S. La Marca, L. Padovan, M. Clerici, C. Guadino, G.P. Comi, A. Tripodi, F. Peyvandi, Massive cerebral venous thrombosis due to vaccine-induced immune thrombotic thrombocytopenia, *Haematologica* 106 (11) (2021) 3021–3024, <https://doi.org/10.3324/haematol.2021.279246>
- [87] M. Franchini, S. Testa, M. Pezzo, C. Glingani, B. Caruso, I. Terenziani, C. Pognani, S.A. Bellometti, G. Castelli, Cerebral venous thrombosis and thrombocytopenia post-COVID-19 vaccination, *Thromb. Res.* 202 (2021) 182–183, <https://doi.org/10.1016/j.thromres.2021.04.001>
- [88] T. Gattringer, P. Gressenberger, T. Gary, A. Wölfler, M. Kneihis, R.B. Raggam, Successful management of vaccine-induced immune thrombotic thrombocytopenia-related cerebral venous thrombosis after ChAdOx1 nCoV-19

- vaccination, svn-2021-001142, *Stroke Vasc. Neurol.* (2021), <https://doi.org/10.1136/svn-2021-001142>
- [89] A. Bourguignon, D.M. Arnold, T.E. Warkentin, J.W. Smith, T. Pannu, J.M. Shrum, Z.A.A. Al Maqrashi, A. Shroff, M.C. Lessard, N. Blais, J.G. Kelton, I. Nazy, Adjuvant immune globulin for vaccine-induced immune thrombotic thrombocytopenia, *N. Engl. J. Med.* 385 (8) (2021) 720–728, <https://doi.org/10.1056/NEJMoa2107051>
- [90] M.L. de Mélo Silva Jr, D.P. Lopes, Large hemorrhagic stroke after ChAdOx1 nCoV-19 vaccination: a case report, *Acta Neurol. Scand.* 144 (6) (2021) 717–718, <https://doi.org/10.1111/ane.13505>
- [91] L.C.A. Esba, M. Al Jeraisy, Reported adverse effects following COVID-19 vaccination at a tertiary care hospital, focus on cerebral venous sinus thrombosis (CVST, Expert Rev. Vaccin. 20 (8) (2021) 1037–1042, <https://doi.org/10.1080/14760584.2021.1940145>
- [92] Y. Aladdin, H. Algahtani, B. Shirah, Vaccine-induced immune thrombotic thrombocytopenia with disseminated intravascular coagulation and death following the ChAdOx1 nCoV-19 vaccine, *J. Stroke Cereb. Dis.* 30 (9) (2021) 105938, <https://doi.org/10.1016/j.jstrokecerebrovasdis.2021.105938>
- [93] C.Y. Guan, S.H. Tsai, J.S. Fan, Y.K. Lin, C.C. Kao, Middle-age Asian male with cerebral venous thrombosis after COVID-19 AstraZeneca vaccination, *Am. J. Emerg. Med.* 51 (2022) 427, <https://doi.org/10.1016/j.ajem.2021.07.011> (e3-427.e4).
- [94] R.L. Wang, W.F. Chiang, H.Y. Shyu, M.H. Chen, C.I. Lin, K.A. Wu, C.C. Yang, L.Y. Huang, P.J. Hsiao, COVID-19 vaccine-associated acute cerebral venous thrombosis and pulmonary artery embolism, *QJM* 114 (7) (2021) 506–507, <https://doi.org/10.1093/qjmed/hcab185>
- [95] J.K. Choi, S. Kim, S.R. Kim, J.Y. Jin, S.W. Choi, H. Kim, J.H. Yoo, I.S. Park, S.R. Kim, Intracerebral hemorrhage due to thrombosis with thrombocytopenia syndrome after vaccination against COVID-19: the first fatal case in Korea, *J. Korean Med Sci.* 36 (31) (2021) e223, <https://doi.org/10.3346/jkms.2021.36.e223>
- [96] A. Dutta, R. Ghosh, D. Bhattacharya, S. Bhat, A. Ray, A. Pandit, S. Das, S. Dubey, Anti-PF4 antibody negative cerebral venous sinus thrombosis without thrombocytopenia following immunization with COVID-19 vaccine in an elderly non-comorbid Indian male, managed with conventional heparin-warfarin based anticoagulation, *Diabetes Metab. Syndr.* 15 (4) (2021) 102184, <https://doi.org/10.1016/j.dsx.2021.06.021>
- [97] B.V. Maramattom, F.M. Moidu, S. Varikkottil, A.A. Syed, Cerebral venous sinus thrombosis after ChAdOx1 vaccination: the first case of definite thrombosis with thrombocytopenia syndrome from India, *BMJ Case Rep.* 14 (10) (2021) e246455, <https://doi.org/10.1136/bcr-2021-246455>
- [98] H.G. Rosenblum, S.C. Hadler, D. Moulia, T.T. Shimabukuro, J.R. Su, N.K. Tepper, K.C. Ess, E.J. Woo, A. Mba-Jonas, M. Alimchandani, N. Nair, N.P. Klein, K.E. Hanson, L.E. Markowitz, M. Wharton, V.V. McNally, J.R. Romero, H.K. Talbot, G.M. Lee, M.F. Daley, S.A. Mbaeyi, S.E. Oliver, Use of COVID-19 Vaccines after reports of adverse events among adult recipients of Janssen (Johnson & Johnson) and mRNA COVID-19 vaccines (Pfizer-BioNTech and Moderna): update from the Advisory Committee on Immunization Practices - United States, July 2021, *MMWR Morb. Mortal. Wkly Rep.* 70 (32) (2021) 1094–1099, <https://doi.org/10.15585/mmwr.mm7032e4>
- [99] NCIRD. Reports of cerebral venous sinus thrombosis with thrombocytopenia after Janssen COVID-19 vaccine. <https://www.cdc.gov/vaccines/acip/meetings/downloads/slides-2021-04/03-COVID-Shimabukuro-508.pdf>. (Accessed 10 May 2021).
- [100] I. See, J.R. Su, A. Lale, E.J. Woo, A.Y. Guth, T.T. Shimabukuro, M.B. Streiff, A.K. Rao, A.P. Wheeler, S.F. Beavers, A.P. Durbin, K. Edwards, E. Miller, T.A. Harrington, A. Mba-Jonas, N. Nair, D.T. Nguyen, K.R. Talaat, V.C. Urrutia, S.C. Walker, C.B. Creech, T.A. Clark, F. DeStefano, K.R. Broder, US case reports of cerebral venous sinus thrombosis with thrombocytopenia after Ad26.COV2.S vaccination, March 2 to April 21 2021, *JAMA* 325 (24) (2021) 2448–2456, <https://doi.org/10.1001/jama.2021.7517>
- [101] D. García-Azorín, T.P. Do, A.R. Gantenbein, J.M. Hansen, M.N.P. Souza, M. Obermann, H. Pohl, C.J. Schankin, H.W. Schytz, A. Sinclair, G.G. Schoonman, E.S. Kristoffersen, Delayed headache after COVID-19 vaccination: a red flag for vaccine induced cerebral venous thrombosis, *J. Headache Pain.* 22 (1) (2021) 108, <https://doi.org/10.1186/s10194-021-01324-5>
- [102] R.T. Clark, L. Johnson, J. Billotti, G. Foulds, T. Ketels, K. Heard, E. Calvello Hynes, Early outcomes of bivalirudin therapy for thrombotic thrombocytopenia and cerebral venous sinus thrombosis after Ad26.COV2.S vaccination, *Ann. Emerg. Med.* 78 (4) (2021) 511–514, <https://doi.org/10.1016/j.annemergmed.2021.04.035>
- [103] R. Dhoot, A. Kansal, C. Handran, T. Haykal, J. Ronald, M. Kappus, G.M. Arepally, M. Graham, J.J. Strouse, Thrombocytopenia and splanchnic thrombosis after Ad26.COV2.S vaccination successfully treated with transjugular intrahepatic portosystemic shunting and thrombectomy, *Am. J. Hematol.* 96 (9) (2021) 1180–1182, <https://doi.org/10.1002/ajh.26258>
- [104] K.L. Muir, A. Kallam, S.A. Koepsell, K. Gundabolu, Thrombotic thrombocytopenia after Ad26.COV2.S vaccination, *N. Engl. J. Med.* 384 (20) (2021) 1964–1965, <https://doi.org/10.1056/NEJMc2105869>
- [105] B. Malik, A. Kalantary, K. Rikabi, A. Kunadi, Pulmonary embolism, transient ischaemic attack and thrombocytopenia after the Johnson & Johnson COVID-19 vaccine, *BMJ Case Rep.* 14 (7) (2021) e243975, <https://doi.org/10.1136/bcr-2021-243975>
- [106] George G., Friedman K.D., Curtis B.R., Lind S.E., 2021 Successful treatment of thrombotic thrombocytopenia with cerebral sinus venous thrombosis following Ad26.COV2.S vaccination (published online ahead of print, 2021 May 14), *Am J Hematol.* <https://doi.org/10.1002/ajh.26237>.
- [107] M.Y. Abou-Ismaïl, K.A. Moser, K.J. Smock, M.Y. Lim, Vaccine-induced thrombotic thrombocytopenia following Ad26.COV2.S vaccine in a man presenting as acute venous thromboembolism, *Am. J. Hematol.* 96 (9) (2021) E346–E349, <https://doi.org/10.1002/ajh.26265>
- [108] L. Dias, R. Soares-Dos-Reis, J. Meira, D. Ferrão, P.R. Soares, A. Pastor, G. Gama, L. Fonseca, V. Fagundes, M. Carvalho, Cerebral venous thrombosis after BNT162b2 mRNA SARS-CoV-2 vaccine, *J. Stroke Cereb. Dis.* 30 (8) (2021) 105906, <https://doi.org/10.1016/j.jstrokecerebrovasdis.2021.105906>
- [109] M. Tajstra, J. Jaroszewicz, M. Gašior, Acute coronary tree thrombosis after vaccination for COVID-19, *JACC Cardiovasc Interv.* 14 (9) (2021) e103–e104, <https://doi.org/10.1016/j.jcin.2021.03.003>
- [110] J. Finsterer, M. Korn, Aphasia seven days after second dose of an mRNA-based SARS-CoV-2 vaccine, *Brain Hemorrhages* 2 (4) (2021) 165–167, <https://doi.org/10.1016/j.hest.2021.06.001>
- [111] M. Sessa, K. Kragholm, A. Hviid, M. Andersen, Thromboembolic events in younger women exposed to Pfizer-BioNTech or Moderna COVID-19 vaccines, *Expert Opin. Drug Saf.* 20 (11) (2021) 1451–1453, <https://doi.org/10.1080/14740338.2021.1955101>
- [112] E.J. Lee, D.B. Cines, T. Gernsheimer, C. Kessler, M. Michel, M.D. Tarantino, J.W. Semple, D.M. Arnold, B. Godeau, M.P. Lambert, J.B. Bussel, Thrombocytopenia following Pfizer and Moderna SARS-CoV-2 vaccination, *Am. J. Hematol.* 96 (5) (2021) 534–537, <https://doi.org/10.1002/ajh.26132>
- [113] Z. Zakaria, N.A. Sapiai, A.R.I. Ghani, Cerebral venous sinus thrombosis 2 weeks after the first dose of mRNA SARS-CoV-2 vaccine, *Acta Neurochir.* 163 (8) (2021) 2359–2362, <https://doi.org/10.1007/s00701-021-04860-w>
- [114] B.E. Fan, J.Y. Shen, X.R. Lim, T.M. Tu, C.C.R. Chang, H.S.W. Khin, J.S. Koh, J.P. Rao, S.L. Lau, G.B. Tan, Y.W. Chia, K.Y. Tay, S. Hameed, T. Umaphathi, K.H. Ong, B.M.R.V. Prasad, Cerebral venous thrombosis post BNT162b2 mRNA SARS-CoV-2 vaccination: a black swan event, *Am. J. Hematol.* 96 (9) (2021) E357–E361, <https://doi.org/10.1002/ajh.26272>
- [115] S. Sangli, A. Virani, N. Cheronis, B. Vannatter, C. Minich, S. Noronha, R. Bhagavatula, D. Sperdelozzi, M. Sareen, R.B. Kaplan, Thrombosis with thrombocytopenia after the messenger RNA-1273 vaccine, *Ann. Intern. Med.* 174 (10) (2021) 1480–1482, <https://doi.org/10.1093/ajl/121-0244>
- [116] K. Syed, H. Chaudhary, A. Donato, Central venous sinus thrombosis with subarachnoid hemorrhage following an mRNA COVID-19 vaccination: are these reports merely co-incidental, *Am. J. Case Rep.* 22 (2021) e933397, <https://doi.org/10.12659/AJCR.933397>
- [117] R. Wölfel, V.M. Corman, W. Guggemos, M. Seilmaier, S. Zange, M.A. Müller, D. Niemeyer, T.C. Jones, P. Vollmar, C. Rothe, M. Hoelscher, T. Bleicker, S. Brünink, J. Schneider, R. Ehmann, K. Zwirgmaier, C. Drosten, C. Wendtner, Virological assessment of hospitalized patients with COVID-2019, *Nature* 581 (7809) (2020) 465–469, <https://doi.org/10.1038/s41586-020-2196-x>
- [118] I. Hamed, N. Shaban, M. Nassar, D. Cayir, S. Love, M.D. Curran, S. Webb, H. Yang, K. Watson, A. Rostron, V. Navapurkar, R. Mahroof, A. Conway Morris, Paired nasopharyngeal and deep lung testing for severe acute respiratory syndrome Coronavirus-2 reveals a viral gradient in critically ill patients: a multicenter study, *Chest* 159 (4) (2021) 1387–1390, <https://doi.org/10.1016/j.chest.2020.10.017>
- [119] M. Gabbrielli, C. Gandolfo, G. Anichini, T. Candelori, M. Benvenuti, G.G. Savellini, M.G. Cusi, How long can SARS-CoV-2 persist in human corpses? *Int. J. Infect. Dis.* *IJID Off. Publ. Int. Soc. Infect. Dis.* 106 (2021) 1–2, <https://doi.org/10.1016/j.ijid.2021.03.052>
- [120] S. Plenzig, F. Holz, D. Bojkova, M. Kettner, J. Cinatl, M.A. Verhoff, C.G. Birngruber, S. Ciesek, H.F. Rabenau, Detection and infectivity of SARS-CoV-2 in exhumated corpses, *Int. J. Leg. Med.* 135 (6) (2021) 2531–2536, <https://doi.org/10.1007/s00414-021-02670-4>
- [121] S. Grassi, V. Arena, P. Cattani, M. Dell'Aquila, F.M. Liotti, M. Sanguinetti, A. Oliva, GEMELLI AGAINST COVID-19 group, SARS-CoV-2 viral load and replication in postmortem examinations, *Int. J. Leg. Med.* 136 (3) (2022) 935–939, <https://doi.org/10.1007/s00414-021-02753-2>
- [122] Australasian Society of Clinical Immunology and Allergy (internet), ASCIA; 2021, Brookvale. <https://www.allergy.org.au/hp/papers/acute-management-of-anaphylaxis-guidelines>. (Accessed 17 February 2022).
- [123] Brighton Collaboration (internet), Decatur: Brighton Collaboration, 5 Feb 2021. https://brightoncollaboration.us/wp-content/uploads/2021/03/SPEAC_D2.5.2.1_Anaphylaxis-Case-Definition-Companion-Guide_V1.0-12070-1.pdf. (Accessed 17 February 2022).
- [124] C.B. Sarah, W. Thomas, J.B. Richard, et al., Biomarkers in human anaphylaxis: a critical appraisal of current evidence and perspectives, *Front. Immunol.* 10 (2019) 494, <https://doi.org/10.3389/fimmu.2019.00494>
- [125] A. Lee, Elevated serum tryptase in non-anaphylaxis cases: a concise review, *Int. Arch. Allergy Immunol.* 181 (5) (2020) 357–364, <https://doi.org/10.1159/000506199>
- [126] Brighton Collaboration (internet), Decatur: Brighton Collaboration, 19 Nov 2021. https://brightoncollaboration.us/wp-content/uploads/2022/05/SPEAC_D2.5.2.2_Myocarditis-companion-guide_codes-updated_BL_2022_May12.pdf. (Accessed 17 February 2022).
- [127] A. Fazlollahi, M. Zahmatyar, M. Noori, S.A. Nejadghaderi, M.J.M. Sullman, R. Shekarriz-Foumani, A.A. Kolahi, K. Singh, S. Safiri, Cardiac complications following mRNA COVID-19 vaccines: a systematic review of case reports and case series, *Rev. Med. Virol.* (2021) e2318, <https://doi.org/10.1002/rmv.2318>
- [128] B.L. Zhu, T. Ishikawa, T. Michiue, D.R. Li, D. Zhao, Y. Bessho, Y. Kamikodai, K. Tsuda, S. Okazaki, H. Maeda, Postmortem cardiac troponin I and creatine kinase MB levels in the blood and pericardial fluid as markers of myocardial

- damage in medicolegal autopsy, *Leg. Med.* 9 (5) (2007) 241–250, <https://doi.org/10.1016/j.legalmed.2007.01.010>
- [129] L. Cari, P. Fiore, M. Naghavi Alhosseini, G. Sava, G. Nocentini, Blood clots and bleeding events following BNT162b2 and ChAdOx1 nCoV-19 vaccine: an analysis of European data, *J. Autoimmun.* 122 (2021) 102685, <https://doi.org/10.1016/j.jaut.2021.102685>
- [130] M. Makris, S. Pavord, W. Lester, M. Scully, B. Hunt, Vaccine-induced immune thrombocytopenia and thrombosis (VITT), *Res Pract. Thromb. Haemost.* 5 (5) (2021 1) e12529, <https://doi.org/10.1002/rth2.12529>
- [131] Brighton Collaboration (internet). Decatur: Brighton Collaboration, 5 May 2021. https://brightoncollaboration.us/wp-content/uploads/2021/03/SPEAC_D2.5.2.1_Anaphylaxis-Case-Definition-Companion-Guide_V1.0-12070-1.pdf. (Accessed 17 February 2022).
- [132] J. Schneider, L. Sottmann, A. Greinacher, M. Hagen, H.U. Kasper, C. Kuhnen, S. Schlepper, S. Schmidt, R. Schulz, T. Thiele, C. Thomas, A. Schmeling, Postmortem investigation of fatalities following vaccination with COVID-19 vaccines, *Int J. Leg. Med.* 135 (6) (2021) 2335–2345, <https://doi.org/10.1007/s00414-021-02706-9>
- [133] I. Nazy, U.J. Sachs, D.M. Arnold, S.E. McKenzie, P. Choi, K. Althaus, M.T. Ahlen, R. Sharma, R.F. Grace, T. Bakchoul, Recommendations for the clinical and laboratory diagnosis of VITT against COVID-19: Communication from the ISTH SSC Subcommittee on Platelet Immunology, *J. Thromb. Haemost.* 19 (6) (2021) 1585–1588, <https://doi.org/10.1111/jth.15341>
- [134] C. Edler, A. Klein, A.S. Schröder, J.P. Spermhake, B. Ondruschka, Deaths associated with newly launched SARS-CoV-2 vaccination (Comirnaty®, *Leg. Med (Tokyo)* 51 (2021) 101895, <https://doi.org/10.1016/j.legalmed.2021.101895>
- [135] Motta Junior JdS, Miggiolaro AFRdS, Nagashima S et al. Mast cell in Alveolar septa of Covid-19 Patients: a pathogenic pathway that may link interstitial edema to immunothrombosis, *Front. Immunol.* 2020, 11, 574862. <https://doi.org/10.3389/fimmu.2020.574862>.
- [136] A.S. Janssens, R. Heide, B. Tank, A.P. Oranje, Mast cell distribution in normal adult skin, *J. Clin. Pathol.* 58 (2005) 286–289, <https://doi.org/10.1136/jcp.2004.017210>
- [137] S. Jakate, M. Demeo, R. John, M. Tobin, A. Keshavarzian, Mastocytic enterocolitis: increased mucosal mast cells in chronic intractable diarrhoeas, *Arch. Pathol. Lab. Med.* 130 (3) (2006) 362–367, <https://doi.org/10.5858/2006-130-362-MEIMMC>