

Longitudinal Evaluation of the Histological Changes in a Rat Model of Paravertebral Muscle Injury

Koki Abe¹⁾, Kazuhide Inage¹⁾, Sumihisa Orita¹⁾, Yoshihiro Sakuma²⁾, Hirohito Kanamoto¹⁾, Masahiro Inoue¹⁾, Hideyuki Kinoshita¹⁾, Masaki Norimoto¹⁾, Tomotaka Umimura¹⁾, Ikuko Tajiri¹⁾, Miyako Suzuki¹⁾, Yawara Eguchi³⁾, Kazuhisa Takahashi¹⁾ and Seiji Ohtori¹⁾

1) Department of Orthopaedic Surgery, Graduate School of Medicine, Chiba University, Chiba, Japan

2) Department of Orthopaedic Surgery, National Hospital Organization, Chiba Medical Center, Chiba, Japan

3) Department of Orthopaedic Surgery, Shimoshizu National Hospital, Yotsukaido, Japan

Abstract:

Introduction: Thus far, few reports have described the time series histological variations in injured paravertebral muscle tissues for long durations, considering the type of pain. The purpose of this study is to evaluate histological changes in injured paravertebral muscles and dominant nerves considering the type of pain.

Methods: We used 59 eight-week-old male Sprague-Dawley rats. A 115-g weight was dropped from a height of 1 m on the right paravertebral muscle. Fluoro-Gold (FG), a sensory nerve tracer, was injected into this muscle. Hematoxylin and eosin (HE) staining and nerve growth factor (NGF) immunostaining of the muscle were performed for histological evaluation. L2 dorsal root ganglia (DRG) on both sides were resected, and immunohistochemical staining was performed for calcitonin gene-related peptide (CGRP, a pain-related neuropeptide) and for activating transcription factor 3 (ATF3, a neuron injury marker). Each examination was performed at 3 days, 1-3 weeks, and 6 weeks after injury.

Results: HE staining of the paravertebral muscle indicated infiltration of inflammatory cells and the presence of granulation tissue in the injured part on the ipsilateral side at 3 days and 1 week after the injury. Fibroblasts and adipocytes were present at 2-3 weeks. At 6 weeks, the injured tissue was almost completely repaired. NGF was detected at 2-3 weeks post injury and appeared to colocalize with fibroblasts, but was not observed at 6 weeks post injury. The percentage of cells double-labeled with FG and CGRP in FG-positive cells of the primary muscle was significantly higher in the injured side at 3 days and 1-3 weeks post injury ($P < 0.05$). However, at 6 weeks, no significant difference was observed. No significant expression of ATF3 was observed.

Conclusions: These results suggest that sensitization of the dominant nerve in the DRG, in which NGF may play an important role, can protract pain in injured muscles.

Keywords:

CGRP, muscle injury, NGF, rat, paravertebral muscle, DRG

Spine Surg Relat Res 2018; 2(4): 324-330
dx.doi.org/10.22603/ssrr.2017-0094

Introduction

The number of lumbar fusion surgeries in Japan has been increasing over the last 10 years¹⁾. The use of a conventional midline posterior approach for lumbar spine surgery has been reported to cause significant muscle injury, which is especially severe if powerful self-retaining retractors are used^{2,3)}. The extended use of muscle retractors was also reported to cause back muscle atrophy and postoperative

lower back pain at 6 months after surgery⁴⁾. In contrast, another study of patients who underwent surgery for lumbar spinal stenosis reported that despite worsened muscle atrophy, lower back pain had improved significantly at one year post surgery⁵⁾. We previously reported a time series of the histological changes in injured paravertebral muscles and dominant nerves during the first 3 weeks post injury in rats⁶⁾. In this study, the inflammatory phase at the injury site ended at 1 week post injury. However, activation of the

Corresponding author: Koki Abe, abeabeabe04@yahoo.co.jp

Received: December 18, 2017, Accepted: April 10, 2018, Advance Publication: May 29, 2018

Copyright © 2018 The Japanese Society for Spine Surgery and Related Research

dominant nerve in the dorsal root ganglia (DRG) continued throughout the experimental period. The cause of this gap between activation in the DRG and local injury, and how long the agitation in the dominant nerve continues after inflammation of the injured muscle has ceased are unknown. Thus far, very few reports have described the relationship between histological variations in injured tissues and neuropeptide transition in the dominant nerve for long durations.

Regarding pain type, many pathways, including neuropathic and nociceptive pathways, have been reported to contribute to perioperative pain^{7,8)}. However, it has not been clarified whether or not muscle injury causes emphatic neuropathic pain. Therefore, the purpose of the current study was to determine the relationship between a time series of histological variations in injured back muscles, and the production of calcitonin gene-related peptide (CGRP; a pain-related neuropeptide) and activating transcription factor 3 (ATF3, a neuron injury marker) in the dominant nerve over a 6-week period after experimental back muscle injury in rats.

We previously reported the expression of inflammatory mediators, such as nerve growth factor (NGF), tumor necrosis factor- α , and interleukin-6, at 1 day after injury in a rat model of gastrocnemius muscle injury⁹⁾, and showed that administration of an antibody against NGF suppressed the inflammation in the DRG¹⁰⁾. Therefore, here we focused on the role of NGF in the pain-producing mechanism in injured back muscles.

Materials and Methods

Animal models

All animal procedures and protocols were approved by the ethics committee of our university and were performed in accordance with the United States National Institutes of Health Guidelines for the Care and Use of Laboratory Animals (1996 revision). The methods used to generate the models and obtain specimens were described previously⁶⁾. For the model, we used 59 eight-week-old male Sprague-Dawley rats. Each rat weighed 250-300 g at the time of muscle injury. Before injury, the rats were anesthetized with ketamine hydrochloride and xylazine. Following anesthesia, a muscle contusion was induced without making a skin incision by dropping a 115-g weight from 1 m onto a target drawn on the right side of the paravertebral back muscle (Fig. 1).

Histology

Hematoxylin-eosin (HE) staining

For HE staining, the muscle injury site (i.e., the right side) was dissected from the back muscle under anesthesia with sodium pentobarbital (40 mg/kg, intraperitoneally) at 3 days and at 1, 2, 3, and 6 weeks post muscle injury (4 rats

per time point, 20 rats in total), and perfused transcardially with 0.9% saline, and then with 500 mL of 4% paraformaldehyde in phosphate-buffered saline (PBS; 0.1 M, pH 7.4). After dehydration for 14 h in a graded series of ethanol, each tissue specimen was formalin-fixed and embedded in paraffin with a Tissue-Tek VIP (M1500; Sakura Finetek Japan Co., Ltd., Tokyo, Japan).

Subsequently, 4- μ m-thick sections were generated from these paraffin blocks using a sliding microtome (LS113; Yamato Kohki Industrial Co., Ltd., Saitama, Japan). The sections were then placed on glass slides (#5116; Muto Pure Chemicals Co., Ltd., Tokyo, Japan) and stained with Mayer's hematoxylin (Muto Pure Chemicals Co., Ltd.) for 5 min after deparaffinization with xylene and ethanol. After washing with distilled water, these sections were dipped in 0.1% ammonium solution several times, washed again, and stained with a mixture of 1% eosin and phloxine (equal parts) in ethanol for 20 s. The sections were finally overlaid with Entellan mounting medium (Merck KGaA, Darmstadt, Germany) after dehydration in a graded series of ethanol and xylene. A professional animal pathologist scored the slides under a microscope (BH20; Olympus Corp., Tokyo, Japan), and each finding was semi-quantitatively evaluated. The slides were evaluated for the presence or absence of histological degeneration, bleeding, and neutrophil recruitment.

NGF immunostaining

The muscle injury site (i.e., the right side) was dissected from the back muscle under anesthesia at 2, 3, and 6 weeks post injury (3 rats per time point, 9 rats in total).

Paraffin blocks were made with a Tissue-Tek VIPTM6 (Sakura Finetek Japan). The central portion of each tissue block was cut into 4- μ m-thick sections with a sliding microtome. Each section was mounted on a glass slide coated with 3-aminopropyltrimethoxysilane and dried. Then, the slide was immunostained for NGF.

Deparaffinized specimens were immersed in 10 mM citrate buffer (pH 6.0) and autoclaved at 121°C for 10 min to induce antigen activation. After the treatment, peroxidase activity and nonspecific proteins were blocked by placing specimens in a refrigerator. Next, the sections were incubated with an anti-NGF rabbit polyclonal antibody (ab 6199; Abcam, Cambridge, UK; 1:250) overnight at 4°C. Then, the sections were incubated with a horseradish peroxidase-labeled anti-rabbit IgG goat polyclonal antibody (#424144; Nichirei Corp., Tokyo, Japan) at room temperature for 30 min. Finally, a chromogenic substrate, 3,3'-diaminobenzidine-4-hydrochloric acid, was added. Antibody-positive signals were detected as a brown color, and nuclei were counterstained with hematoxylin (light purple).

Immunohistochemistry for CGRP and ATF3

Fluoro-Gold (FG; Fluorochrome, Denver, CO, USA), a retrograde neuronal tracer, was injected into both sides of the paravertebral muscle to label the afferent sensory nerves.

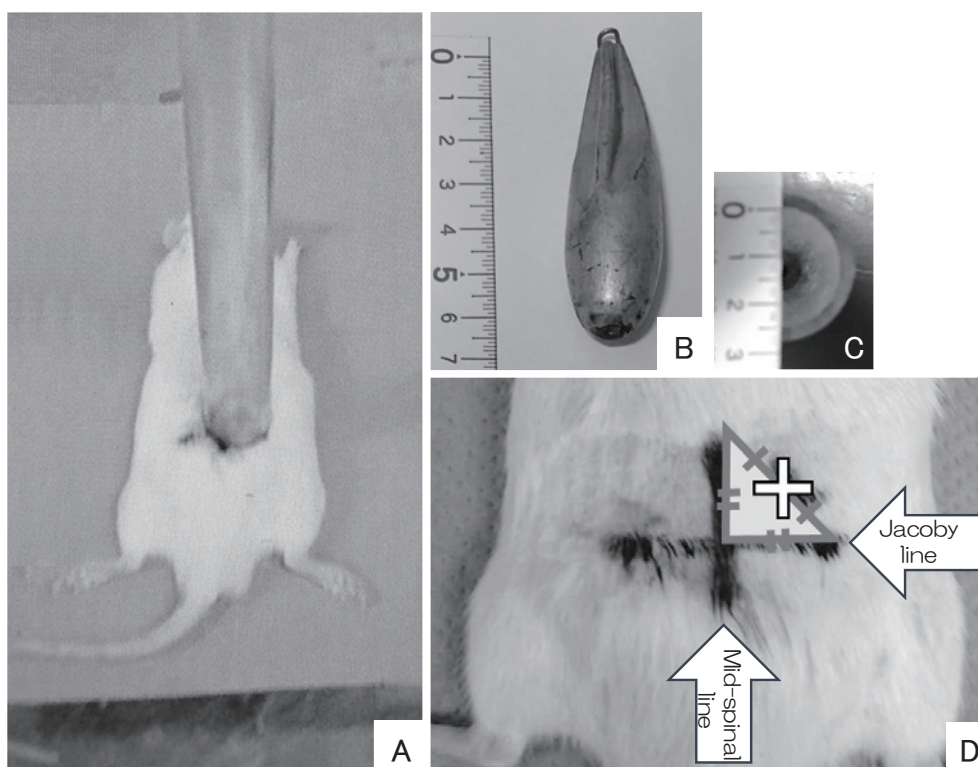


Figure 1. Back injury method in the rat model.

(A) A 115-g weight was dropped from a height of 100 cm onto the right side of the back of the anesthetized rat. (B) (C) A plastic tube with a length of 100 mm and an inner diameter of 25 mm, and a 24-mm-diameter weight were used. (D) The white cross mark was used as the strike target, which is at the midpoint of the baseline of the isosceles triangle formed by the mid-spinal line and the Jacoby line.

The L2 DRG of both the injured and uninjured sides were removed at 3 days, and 1, 2, 3, and 6 weeks after injury. According to a previous report, the paravertebral musculature is under a significant degree of L2 control^[11]. The proportion of FG-labeled neurons also showing immunoreactivity for CGRP, a marker of inflammatory pain, was determined. Endogenous peroxidase activity was quenched by soaking sections with 0.3% hydrogen peroxide in 0.01 M PBS for 30 min. The specimens were then incubated in a blocking solution (0.3% Triton X-100 and 3% skim milk in 0.01 M PBS) for 90 min at room temperature. The sections were incubated with a primary rabbit antibody against CGRP (Chemicon, Temecula, CA, USA; 1:1,000 in blocking solution), and then incubated for 20 h at 4°C. To detect CGRP immunoreactivity in the DRG, the sections were incubated with an Alexa Fluor 488-conjugated goat anti-rabbit fluorescent antibody (Molecular Probes, Eugene, OR, USA; 1:400). The sections were examined under a fluorescence microscope, and the number of FG-labeled neurons, CGRP-immunoreactive (ir) neurons, and FG- and CGRP-ir-labeled neurons were determined in five randomly selected areas of each DRG section.

We used an anti-ATF3 antibody (Chemicon; 1:200) to detect ATF3-labeled cells. The experiment to detect ATF3 was performed as described above for CGRP.

Statistical analysis

A Mann-Whitney U test was used to compare the proportion of CGRP- and FG-positive neurons, and ATF3- and FG-positive neurons in the DRG between the injured and uninjured sides at 3 days, and 1, 2, 3, and 6 weeks after injury. A P value less than 0.05 was considered significant.

Results

Histology

The histological changes in the muscle samples from the injured side over time are shown in Fig. 2. HE staining of the paravertebral muscle showed infiltration of inflammatory cells and the presence of granulation tissue in the injured site, as well as neovascular hyperplasia at 3 days and 1 week post injury. Absorption of degenerated cell tissues, fibroblasts, and fat cells was observed at 2 and 3 weeks post injury. Muscle atrophy was observed at 6 weeks post injury (Fig. 2).

NGF was detected at 2-3 weeks post injury, and appeared to colocalize with the fibroblasts, but was not observed at 6 weeks post injury (Fig. 3).

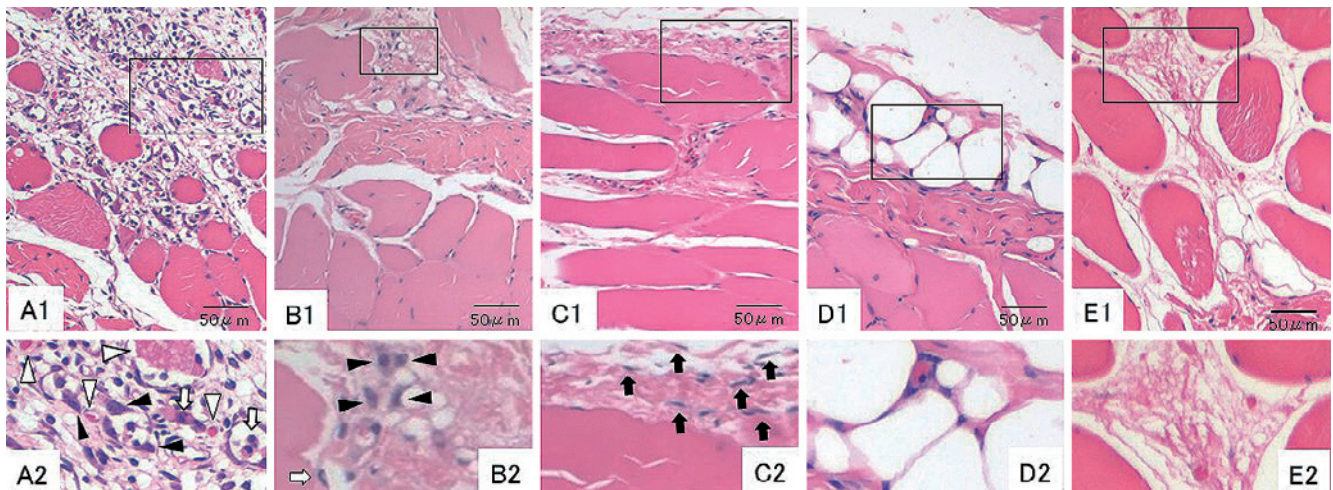


Figure 2. Histological images of injury sites.

Transverse sections showing injured muscles at 3 days (A1), 1 week (B1), 2 weeks (C1), 3 weeks (D1), and 6 weeks (E1) post injury with hematoxylin-eosin staining (100× magnification). (A2), (B2), (C2), (D2), and (E2) are enlarged views of black-framed areas in (A1), (B1), (C1), (D1), and (E1), respectively. White arrowheads indicate red blood cells. Black arrowheads indicate macrophages. White arrows indicate neutrophils. Notably, fat cells were observed at 3 weeks post injury (D1). Muscle atrophy was observed at 6 weeks post injury (E1).

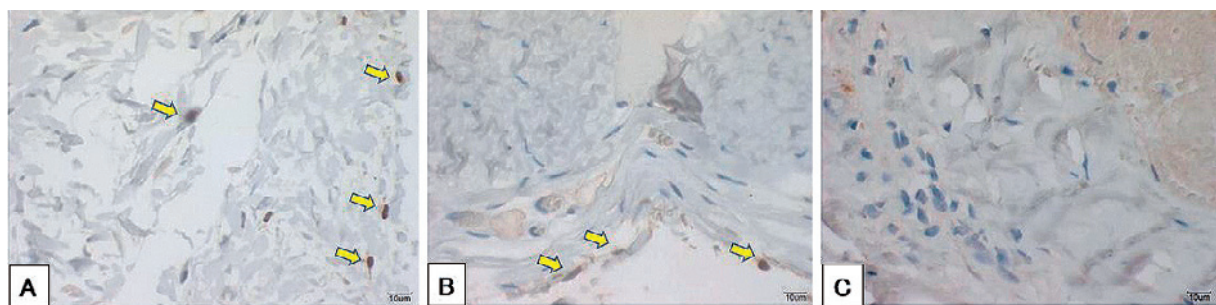


Figure 3. Histological evaluation for nerve growth factor (NGF).

Transverse sections showing injured muscles at 2 weeks (A), 3 weeks (B), and 6 weeks (C) post injury immunostained for NGF (100× magnification). NGF was detected at 2-3 weeks post injury, and appeared to colocalize with the fibroblasts, but was not observed at 6 weeks post injury. Arrows indicate antibody-positive signals, which were detected as a brown color.

Immunohistochemistry for CGRP and ATF3

The results of the L2 DRG immunohistochemistry assay are shown in Fig. 4. The percentage of cells double-labeled with FG and CGRP in the primary muscle was significantly higher on the injured side than on the uninjured side at all the time points (3 days, injured side: $47.1 \pm 6.1\%$ [mean% \pm SD], uninjured side: $29.2 \pm 4.1\%$, $P < 0.05$; 1 week, injured side: $51.9 \pm 9.4\%$, uninjured side: $25.6 \pm 4.4\%$, $P < 0.05$; 2 weeks, injured side: $41.1 \pm 7.9\%$, uninjured side: $21.3 \pm 6.2\%$, $P < 0.05$; 3 weeks, injured side: $40.5 \pm 5.4\%$, uninjured side: $20.4 \pm 6.1\%$, $P < 0.05$). However, at 6 weeks, no significant difference was observed (injured side: $24.1 \pm 6.9\%$, uninjured side: $25.1 \pm 8.7\%$). In contrast, although a few ATF3-labeled cells were detected at 1 and 2 weeks post injury (1 week, injured side: $0.8 \pm 3.0\%$, uninjured side: 0% ; 2 weeks, injured side: $0.5 \pm 2.9\%$, uninjured side: 0%), we did not detect any ATF3-labeled cells at the other time points, and we did not observe a significant dif-

ference between the injured and uninjured sides at any tested time point (Fig. 5).

Discussion

Huard described the healing of the injured muscle in three phases¹²⁾: the first phase is degeneration and inflammation, which lasts for 1-2 weeks post injury. The second is the muscle regeneration phase, which starts in the first week and peaks at 2 weeks post injury. Finally, the fibrosis phase occurs at 2-4 weeks post muscle injury. In the present study, inflammation at the injured site peaked at 3 days post injury and ended during the first week post injury; scarring developed by the third week. Although we detected fibrosis and muscle atrophy, we were unable to detect fibroblasts at 6 weeks post injury. These transitions occurred a little earlier in this study than in Huard's study. However, the appropriate cells were detected in the corresponding order¹¹⁾ (Fig. 6). Furthermore, Kawaguchi et al. had reported that regenera-

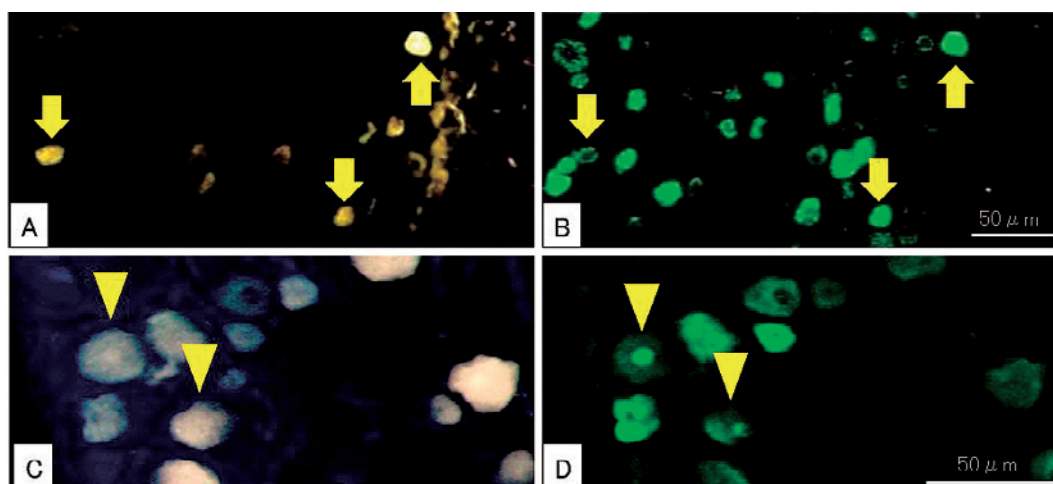


Figure 4. Immunohistochemical assessment of L2 dorsal root ganglion (DRG) neurons at 2 weeks post injury.

The pairs (A) and (B), and (C), and (D) are the same sections. (A) (C) Fluoro-Gold (FG)-labeled DRG neurons innervating injured muscles. (B) Calcitonin gene-related peptide (CGRP)-immunoreactive DRG neurons. (D) Activating transcription factor-3 (ATF-3)-immunoreactive DRG neurons.

Arrows indicate FG and CGRP double-labeled neurons. Arrowheads indicate FG and ATF3 double-labeled neurons.

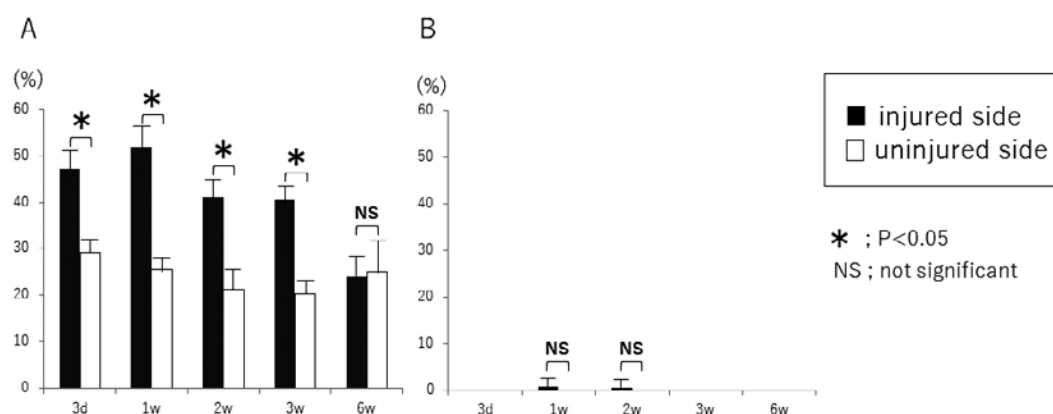


Figure 5. Change of activation in DRG neurons over time.

(A) The proportion of Fluoro-Gold (FG) and calcitonin gene-related peptide (CGRP) double-labeled dorsal root ganglion (DRG) neurons among all FG-labeled DRG neurons. (B) The proportion of FG and activating transcription factor-3 (ATF-3) double-labeled DRG neurons among all FG-labeled DRG neurons (* $P < 0.05$, Mann-Whitney U test).

tion began at 1 week post injury, and was complete by 6 weeks in a rat model of back muscle injury caused by a self-retractor for 3 hours¹³. Although the type of injury was different, we found that the repair process was nearly identical to that in the present model. It is noteworthy that the proportion of CGRP-labeled neurons on the injury side remained high for more than 3 weeks, which is during the regeneration or the fibrosis phase, even though the inflammatory cells had disappeared from the site before 2 weeks post injury. A similar gap was observed in our previous study⁶. This discrepancy may provide insights into the mechanism underlying the prolonged pain experienced after muscle injury. Additionally, NGF was detected on fibroblasts at 2-3 weeks post injury, during the regeneration phase, in which

neuronal cells in the DRG were inflamed. NGF disappeared at 6 weeks post injury, and at this time point, the previously elevated levels of CGRP decreased. These results suggest that NGF on fibroblasts in the regeneration phase may maintain the activation of the DRG, which can protract nociceptive pain in the injured muscle. An anti-NGF agent was reported to be very effective for injured calf muscles in the rat model¹⁰, and for chronic lower back pain in clinical trial studies^{14,15}. Thus, this anti-NGF agent may be useful for lower back pain following paravertebral muscle injury, including spinal surgery.

In contrast, a significant elevation of ATF3 was not detected at any time point. This result may imply that neuropathic pain did not contribute to paravertebral muscle injury.

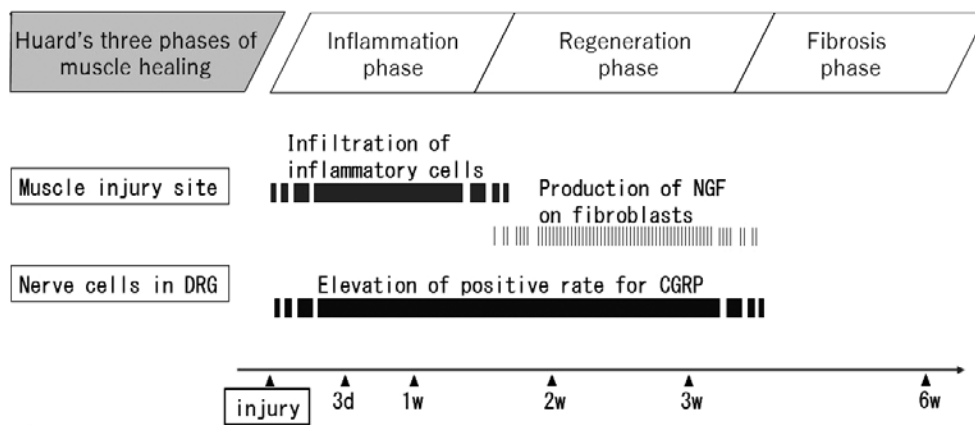


Figure 6. Flow of events at the local injury site in the paravertebral muscle and dominant neurons in the dorsal root ganglion (DRG).

The proportion of calcitonin gene-related peptide (CGRP)-positive neurons remained high for more than 3 weeks, i.e., during the regeneration or fibrosis phase, even though the inflammatory cells had disappeared from the site by 2 weeks post injury. Nerve growth factor (NGF) was detected in fibroblasts at 2-3 weeks post injury, during the regeneration phase, in which neuronal cells in the DRG were inflamed. NGF disappeared at 6 weeks post injury, and at this time point, the previously elevated levels of CGRP decreased. Transitions occurred slightly earlier in the present study than in Huard's study. This figure uses Huard's schematic representation as a reference.

However, the extended use of muscle retractors was reported to cause neurogenic back muscle atrophy¹³⁾ and paravertebral muscle injury in a rat model using a needle puncture as indicated by elevated ATF3 at the dominant nerve¹⁶⁾. Therefore, we do not dismiss the role of neuropathic pain in paravertebral muscle injury. Tesarz reported that peripheral nerves run only along the surface of the thoracolumbar fascia. Furthermore, on the ventricle side of paravertebral muscle, only soft tissue, such as intra-abdominal organs and fat, is present¹⁷⁾. Therefore, the weight dropped may not have caused sufficient damage to the nerves around the fascia of the back muscle.

Limitations

The contusion model in the present study was an acute type and slightly different from injury in an actual surgical operation where the muscle retractor causes a subacute type of muscle injury⁴⁾. Furthermore, we experimented over the course of only 6 weeks. Although the healing processes among the various types of muscle injury have been reported to be similar¹¹⁾, we understand that this model does not explain the entire mechanism of prolonged pain, but reveals only a part of the mechanism of nociceptive pain. This limitation of our model led us to plan another experiment in which the model is injured by a retractor and a cautery knife, and the observation period is greater than 6 weeks.

As an additional limitation, we did not conduct a quantitative evaluation of NGF at the injury site or the DRG. However, we cannot exclude the idea that NGF on fibroblasts may stimulate the neuron cells in the DRG. Further experiments, such as an evaluation of the dorsal horn of the spinal cord and behavioral studies, may elucidate the role of NGF in prolonged pain after back muscle injury.

Conclusions

In the present study, inflammation at the injured site peaked at 3 days post injury and terminated at 1 week post injury. However, the sensory nervous system in the DRG was still activated for more than 3 weeks post injury. This result provides a clue to resolving refractory pain after back muscle injury. NGF, which was detected at 2-3 weeks, may play an important role in the pain mechanism after a back muscle injury. No significant expression of ATF3 was observed.

Conflicts of Interest: The authors declare that there are no relevant conflicts of interest.

Author Contributions: All the authors contributed to all aspects of this study. We held meetings once or twice a month to discuss how to conduct this study. We cooperated and complemented each other's work during this study. In particular, Koki Abe, Masahiro Inoue, Masaki Norimoto, and Tomotaka Umimura contributed extensively to all the experiments. Yoshihiro Sakuma, Hideyuki Kinoshita, Ikuko Tajiri, and Miyako Suzuki supervised the experiments. Kazuhide Inage and Yoshihiro Sakuma experimented with muscle injuries. Sumihisa Orita, Hirohito Kanamoto, and Yawara Eguchi wrote the manuscript. Kazuhisa Takahashi and Seiji Ohtori checked the integrity and accuracy of the work.

References

1. Imajo Y, Taguchi T, Yone K, et al. Japanese 2011 nationwide survey on complications from spine surgery. *J Orthop Sci.* 2015;20(1):38-54.

2. Gejo R, Kawaguchi Y, Kondoh T, et al. Magnetic resonance imaging and histologic evidence of postoperative back muscle injury in rats. *Spine*. 2000;25(8):941-6.
3. Kim CW. Scientific basis of minimally invasive spine surgery: prevention of multifidus muscle injury during posterior lumbar surgery. *Spine*. 2010;35(26Suppl):S281-6.
4. Gejo R, Matsui H, Kawaguchi Y, et al. Serial changes in trunk muscle performance after posterior lumbar surgery. *Spine*. 1999;24(10):1023-8.
5. Ohtori S, Orita S, Yamauchi K, et al. Classification of chronic back muscle degeneration after spinal surgery and its relationship with low back pain. *Asian Spine J*. 2016;10(3):516-21.
6. Abe K, Inage K, Sakuma Y, et al. Evaluation of Histological Changes in Back Muscle Injuries in Rats over Time. *Asian Spine J*. 2017;11(1):88-92.
7. Martinez V, Ben Ammar S, Judet T, et al. Risk factors predictive of chronic postsurgical neuropathic pain: the value of the iliac crest bone harvest model. *Pain*. 2012;153(7):1478-83.
8. Haroutiunian S, Nikolajsen L, Finnerup NB, et al. The neuropathic component in persistent postsurgical pain: a systematic literature review. *Pain*. 2013;154(1):95-102.
9. Sakuma Y, Miyagi M, Inoue G, et al. Muscle injury in rats induces upregulation of inflammatory cytokines in injured muscle and calcitonin gene-related peptide in dorsal root ganglia innervating the injured muscle. *Muscle Nerve*. 2016;54(4):776-82.
10. Suzuki M, Inage K, Sakuma Y, et al. Effect of administration of antibodies against nerve growth factor in a rat model of muscle injury. *Injury*. 2016;47(3):609-12.
11. Wakai K, Ohtori S, Yamashita M, et al. Primary sensory neurons with dichotomizing axons projecting to the facet joint and the low back muscle in rats. *J Orthop Sci*. 2010;15(3):402-6.
12. Huard J, Li Y, Fu FH. Muscle injuries and repair: current trends in research. *J Bone Joint Surg Am*. 2002;84(5):822-32.
13. Kawaguchi Y, Matsui H, Tsuji H. Back muscle injury after posterior lumbar spine surgery. Part 1: Histologic and histochemical analyses in rats. *Spine*. 1994;19(22):2590-7.
14. Knezevic NN, Mandalia S, Raasch J, et al. Treatment of chronic low back pain - new approaches on the horizon. *J Pain Res*. 2017;10(10):1111-23.
15. Katz N, Borenstein DG, Birbara C, et al. Efficacy and safety of tanezumab in the treatment of chronic low back pain. *Pain*. 2011;152(10):2248-58.
16. Ohtori S, Miyagi M, Takaso M, et al. Differences in damage to CGRP immunoreactive sensory nerves after two lumbar surgical approaches. *Spine*. 2012;37(3):168-73.
17. Tesarz J, Hoheisel U, Wiedenhöfer B, et al. Sensory innervation of the thoracolumbar fascia in rats and humans. *Neuroscience*. 2011;27(194):302-8.

Spine Surgery and Related Research is an Open Access journal distributed under the Creative Commons Attribution-NonCommercial-NoDerivatives 4.0 International License. To view the details of this license, please visit (<https://creativecommons.org/licenses/by-nc-nd/4.0/>).