

# Traumatic Ptosis: Evaluation of Etiology, Management and Prognosis

Sarah Mireles Jacobs<sup>1,2</sup>, MD; Ariel J. Tyring<sup>2</sup>, MD; Arash J. Amadi<sup>2,3</sup>, MD

<sup>1</sup>Department of Ophthalmology, University of Alabama Birmingham, Birmingham, Alabama, USA

<sup>2</sup>Department of Ophthalmology, University of Washington, Seattle, Washington, USA

<sup>3</sup>Seattle Face and Skin, Seattle, Washington, USA

## Abstract

**Introduction:** To investigate whether a systematic approach to subgrouping traumatic ptosis according to etiology can allow for better tailoring of prognosis and treatment.

**Methods:** Retrospective chart review of patients with trauma-related blepharoptosis managed by Oculoplastic surgery specialists at an academic medical center from January 1995 to November 2015. Injury mechanism, eyelid position and function, interventions, and outcomes were reviewed.

**Results:** Of 648 patients treated for blepharoptosis, 55 (8.5%) were traumatic. Careful review revealed 4 subcategories of traumatic ptosis cases: aponeurotic ( $n = 16$ ), myogenic ( $n = 18$ ), neurogenic ( $n = 7$ ), and mechanical ( $n = 14$ ). Margin reflex distance (MRD1) at presentation was significantly worse for the myogenic subtype ( $-0.59$  mm, SD  $\pm 2.09$ ,  $P = 0.046$ ). The aponeurotic subtype had the best average levator function at presentation (14.29 mm, SD  $\pm 2.05$ ), while myogenic had the worst (8.41 mm, SD  $\pm 4.94$ ) ( $P = 0.004$ ). Thirty-five (63.6%) patients were managed surgically. Final MRD1 was significantly different for each subtype ( $P = 0.163$ ), with aponeurotic 2.63 mm (SD  $\pm 1.01$ ), myogenic 1.29 mm (SD  $\pm 2.24$ ), neurogenic 1.79 mm (SD  $\pm 2.48$ ), and mechanical 2.31 mm (SD  $\pm 1.18$ ). There was a significant increase in MRD1 from presentation to final follow up across all groups ( $P < 0.05$ ).

**Conclusion:** Traumatic ptosis is heterogenous. Systematically evaluating traumatic ptosis cases by trauma mechanism can guide decisions about prognosis and management. Two-thirds of cases were treated surgically, with most patients responding well to conjunctiva-Müller resection or external levator advancement. While all subgroups demonstrated improvement in MRD1 at final follow up, aponeurotic cases had the best prognosis, while myogenic fared the worst and required the longest for maximal recovery.

**Keywords:** Blepharoptosis; Eyelids; Eye Injuries

*J Ophthalmic Vis Res* 2018; 13 (4): 447-452

## Correspondence to:

Sarah Mireles Jacobs, MD. 700 18<sup>th</sup> Street South, Suite 410, Birmingham, AL 35233, USA.  
E-mail: jacobs.sarahm@gmail.com

Received: 10-07-2017 Accepted: 13-01-2018

## INTRODUCTION

Blepharoptosis is frequent encountered in oculoplastics practice, most commonly arising from acquired involutional dehiscence of the levator aponeurosis from

This is an open access journal, and articles are distributed under the terms of the Creative Commons Attribution-NonCommercial-ShareAlike 4.0 License, which allows others to remix, tweak, and build upon the work non-commercially, as long as appropriate credit is given and the new creations are licensed under the identical terms.

For reprints contact: reprints@medknow.com

**How to cite this article:** Jacobs SM, Tyring AJ, Amadi AJ. Traumatic ptosis: Evaluation of etiology, management, and prognosis. *J Ophthalmic Vis Res* 2018;13:447-52.

## Access this article online

Quick Response Code:



Website:

www.jovr.org

DOI:

10.4103/jovr.jovr\_148\_17

its insertion on the tarsus. Other less common mechanisms include congenital ptosis due to hypofunction of a fibrofatty levator muscle, myogenic ptosis due to weakness of the levator muscle itself as occurs in certain muscular dystrophies, and neurogenic ptosis resulting from complete or partial loss of the third cranial nerve III (CNIII) and/or the sympathetic fibers supplying the Müller's muscle.<sup>[1]</sup>

In contrast to these distinct categories, when the upper lid height is decreased after an injury, it is considered as a "traumatic ptosis." In a study on the relative incidence of blepharoptosis subtypes, traumatic ptosis was the second most common (11.2%).<sup>[2]</sup> A review of the literature reveals traumatic ptosis cases resulting from a broad range of insults including direct muscular injury, neurotoxins, mass effect from scars or foreign bodies, cranial nerve damage, and cicatricial tethering of the skin.<sup>[3-9]</sup> Therefore, a highly heterogeneous group of trauma-related eyelid issues is described with a single label that reveals very little about the exact reason why the lid is ptotic. Data enabling a more systematic approach to tailoring treatments would be of use.

The purpose of this study was to assess whether meaningful differences exist between traumatic ptosis subtypes based on the underlying mechanism of injury, and whether these differences can impact the prognostic counseling a patient should receive and the type of management the surgeon should choose.

## METHODS

The research protocol was approved by the institutional review board and the project was conducted in compliance with the Health Insurance Portability and Accountability Act of 1996 (HIPAA). Clinical records at an urban academic medical center were screened for non-congenital blepharoptosis (using diagnostic codes; ICD-9 codes 374.30–374.33) and ptosis (using procedure codes; CPT codes 67901-67904, and 67908) treated from January 1995 to November 2015. The records were further screened to identify the subset of patients with trauma-related ptosis. Patients were excluded if any eyelid surgery or pre-existing ptosis was present prior to injury, fewer than two follow-up visits occurred, or if they had not been evaluated and managed by an attending-level physician in the Oculoplastics Division. A retrospective chart review was then performed to acquire patient demographics, mechanism of injury and resulting subtype of traumatic ptosis, interventions, and measurements of eyelid position and function at baseline and over the course of management.

The patients were divided into five subcategories based on careful review of the mechanism of injury and physical findings:

- *Traumatic myogenic ptosis* ( $T_{myo}$ ): This occurs due to direct injury to the levator muscle and/or Müller's

muscle. For example, the laceration of the levator by broken glass in a motor vehicle accident or by a knife blade in an assault.

- *Traumatic aponeurotic ptosis* ( $T_{apo}$ ): This results from dehiscence of the levator aponeurosis from its tarsal insertion without significant injury to the muscle belly. For example, an injury where the lid is vigorously pulled (as with a fishhook through the tarsus and subsequent manipulations to remove it), stretched (as with a large hematoma distending the soft tissues within the lid), or lacerated at the level of the tarsus.
- *Traumatic mechanical ptosis* ( $T_{mech}$ ): This results from cicatricial bands tethering, stiffening, or weighing down the lid in a way that limits its opening.
- *Traumatic neurogenic ptosis* ( $T_{neuro}$ ): This occurs as a result of neural injury to CNIII or sympathetic fibers. This may occur at any point along the course of the nerve, spanning the thorax/neck/intracranial/orbital course of the sympathetic pathway, and the intracranial/superior orbital fissure/orbital course of CNIII.
- *Traumatic mixed mechanism ptosis* ( $T_{mix}$ ): This results from a combination of one or more injury mechanisms.

Measures of major outcomes included upper eyelid margin reflex distance (MRD1), lower eyelid margin reflex distance (MRD2), levator function, lagophthalmos, and corneal health. The criteria for satisfactory resolution were complete clearance of the visual axis in primary gaze and MRD1 symmetry <1 mm. Eyelid measurements were compared across groups using analysis of variance (ANOVA), followed by Fisher's exact test due to the small subgroup sample sizes. Paired t-tests were used to compare each patient's lid measurements during the initial and final examinations.

## RESULTS

Of the 648 patients with ICD-9 codes for blepharoptosis, 55 (8.5%) cases were found to be traumatic in nature. These cases were divided into the aforementioned subcategories. The number of patients with  $T_{myo}$ ,  $T_{apo}$ ,  $T_{mech}$ , and  $T_{neuro}$  were 18, 16, 14, and 7, respectively. While some of the cases ( $n = 5$ ) had more than one contributing traumatic subtype, a dominant subtype was apparent in every patient and classified accordingly. We anticipate that  $T_{mix}$  cases exist for which a dominant subtype cannot be identified. All five of the mixed-mechanism cases in this study were a combination of myogenic and mechanical ptosis, in which a lacerating injury that traversed the eyelid skin caused cicatricial downward tethering of the lid, and a direct injury to the levator muscle caused diminished levator function.

Patient demographics and examination findings are shown in Table 1. In our study, the average age at trauma

**Table 1. Traumatic ptosis patient characteristics, subgrouped by ptosis mechanism**

	Overall (n=55), n (%)	Myogenic (n=18), n (%)	Aponeurotic (n=16), n (%)	Mechanical (n=14), n (%)	Neurogenic (n=7), n (%)	P
Sex						
Male	31 (56.4)	13 (72.2)	6 (37.5)	7 (50)	5 (71.4)	0.916
Female	24 (43.6)	5 (27.8)	10 (62.5)	7 (50)	2 (28.6)	
Age at trauma	39.16±17.43	35.50±15.54	41.06±21.98	36.14±16.07	42.57±15.36	0.833
Eyelid injury requiring sutures	38 (71.7)	14 (82.4)	10 (66.7)	12 (85.7)	2 (28.6)	<b>0.039</b>
Coexisting facial palsy	7 (12.7)	1 (5.5)	2 (12.5)	1 (7.1)	3 (42.9)	0.236
Coexisting facial deformity	6 (10.9)	2 (11)	1 (6.2)	3 (21.4)	0 (0)	0.541
Coexisting traumatic optic neuropathy	11 (20)	5 (27.8)	0 (0)	4 (28.6)	2 (28.6)	<b>0.022</b>
Initial MRD1 (mm)*	0.4	-0.6	1.0	0.9	0.3	<b>0.046</b>
Initial levator function (mm)*	10.5	8.4	14.3	8.7	10.7	<b>0.004</b>
Management						
Surgical	35 (64)	9 (50)	11 (69)	10 (71)	5 (71)	0.644
Observation	20 (36)	9 (50)	5 (31)	4 (29)	2 (29)	
Total follow-up duration (weeks)	66	69	46	99	35	<b>0.022</b>

MRD1, upper eyelid margin reflex distance. \*Measurements from the traumatized eyelid

was 39.16 years (SD ±17.43), and 56.4% of the patients were males.

MRD1 at presentation was significantly worse for  $T_{myo}$  cases (-0.59 mm, SD ±2.09,  $P = 0.046$ ), than for  $T_{apo}$  (1.02 mm, SD ±1.08),  $T_{mech}$  (0.88 mm, SD ±1.91), and  $T_{neuro}$  (0.29 mm, SD ±1.60) cases.  $T_{apo}$  (14.29 mm, SD ±2.05) cases had the best average levator function at presentation, while  $T_{myo}$  (8.41 mm, SD ±4.94) cases had the worst ( $P = 0.004$ ).

Thirty-five (63.6%) patients were managed surgically, while 20 (34.6%) were managed non-operatively. The decision for non-operative management was based on the presence of progressive spontaneous improvement ( $T_{apo}$ :  $n = 5$ ,  $T_{mech}$ :  $n = 2$ , and  $T_{myo}$ :  $n = 2$ ), the concern of the surgeon that ptosis repair would worsen corneal exposure issues ( $T_{mech}$ :  $n = 2$ ,  $T_{myo}$ :  $n = 3$ , and  $T_{neuro}$ :  $n = 1$ ), or patient reluctance to undergo surgery ( $T_{myo}$ :  $n = 4$  and  $T_{neuro}$ :  $n = 1$ ). While no significant differences were found among subgroups based on the average number of surgeries performed per patient ( $P = 0.525$ ), a small percentage of  $T_{myo}$  cases underwent surgery (50%) and the average number of surgeries performed on each patient was higher (1.44) when they were surgically managed. The majority of surgically-managed  $T_{apo}$  cases ( $n = 8$  of 11) were treated with conjunctiva-Müller resection, whereas external levator advancement (ELA) was most commonly chosen for the other subtypes.  $T_{neuro}$  cases that responded well to clinical tests with topical phenylephrine were treated with conjunctiva-Müller resection (2 Horner's, 1 CNIII palsy), whereas those patients who responded inadequately were treated with ELA (1 Horner's, 1 CNIII palsy). The frontalis sling was utilized in any case with <5 mm of levator function, regardless of its traumatic subgroup.

A significantly better final MRD1 was observed with surgical management than with observation in  $T_{myo}$  ( $P = 0.02$ ),  $T_{mech}$  ( $P = 0.04$ ), and  $T_{neuro}$  ( $P = 0.006$ )

cases. The aponeurotic subgroup showed a trend toward better MRD1 outcomes with surgery compared to observation, but this was not statistically significant ( $P = 0.13$ ) [Figure 1].

The average follow-up duration was 66 weeks (range: 24-119 weeks). A significantly longer follow-up ( $P = 0.022$ ) was required for  $T_{myo}$  (69 weeks) and  $T_{mech}$  (99 weeks) cases than for  $T_{apo}$  (46 weeks) and  $T_{neuro}$  (35 weeks) cases. The final average MRD1 was 2.63 mm (SD ±1.01) for  $T_{apo}$  cases, 1.29 mm (SD ±2.24) for  $T_{myo}$  cases, 1.79 mm (SD ±2.48) for  $T_{neuro}$  cases, and 2.31 mm (SD ±1.18) for  $T_{mech}$  cases ( $P = 0.163$ ). There was a significant improvement in MRD1 in all groups ( $P < 0.05$ ) [Figure 2].

Partial spontaneous improvement without surgical intervention was appreciable in all subgroups except the neurogenic subgroup. Over the course of management, there was an increase in symptomatic dry eye in the aponeurotic ( $P = 0.018$ ) and mechanical subgroups ( $P = 0.021$ ). A trend toward increased lagophthalmos was noted in mechanical cases ( $0.82 \pm 1.03$  mm,  $P = 0.112$ ).

## DISCUSSION

Blepharoptosis is commonly classified as either congenital or acquired. It can also be subdivided into categories based on etiology. Trauma is the second most common cause of blepharoptosis, as reported in some studies.<sup>[2,10]</sup> While there exists in the literature a large volume of data on ptosis with different causes, specific research on traumatic ptosis is sparse, with many reports either out of date or presented as part of a case study.<sup>[11-15]</sup>

Consolidating traumatic ptosis cases into one highly heterogeneous group makes prognosis and management more difficult. Trauma can induce ptosis by a wide variety of mechanisms. For instance, direct injury to the

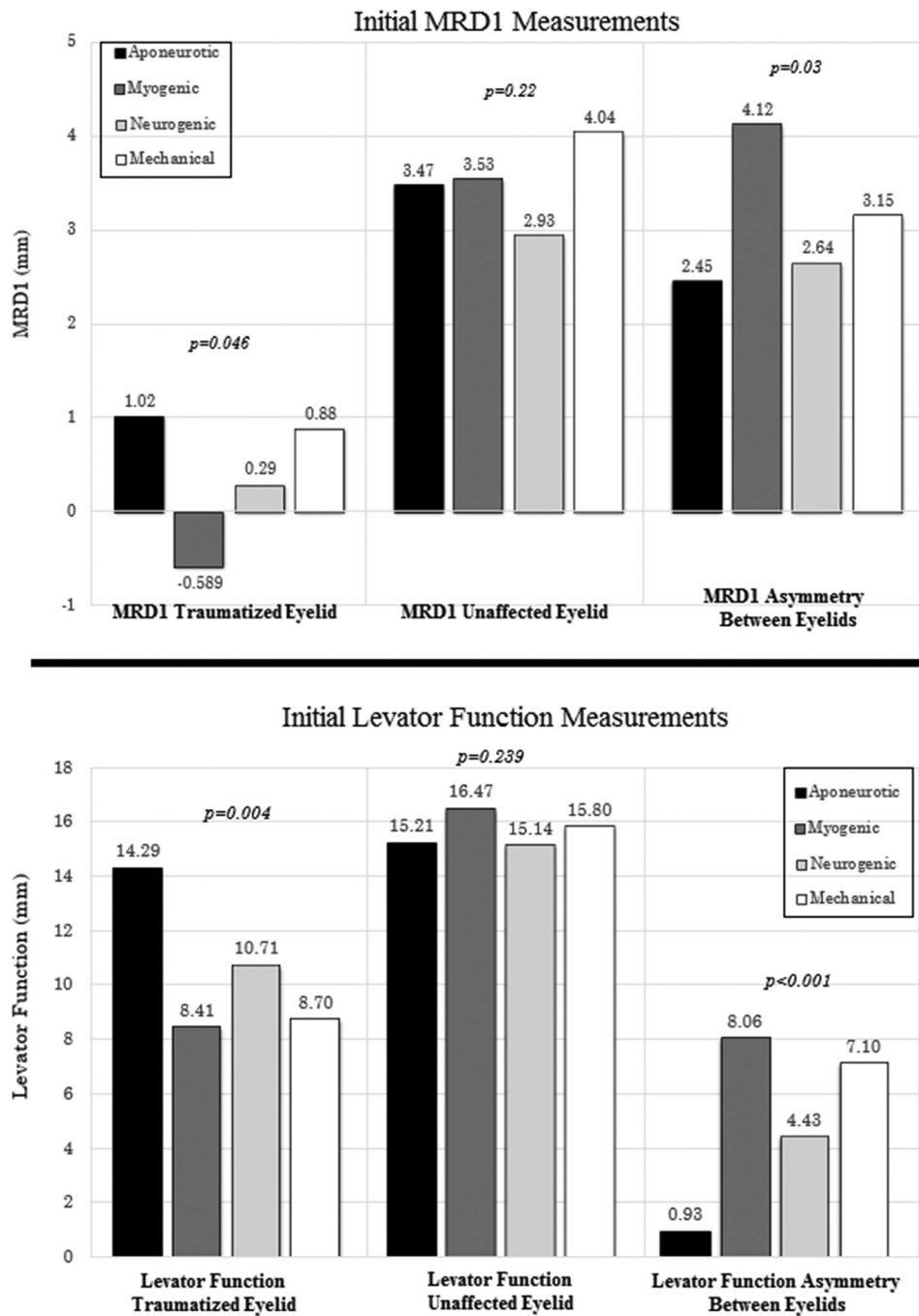


Figure 1. Initial margin reflex distance 1 and levator function measurements.

levator muscle belly and/or Müller’s muscle results in traumatic myogenic ptosis. In contrast, penetrating neck injuries, closed head injuries, traumatically-introduced neurotoxins such as wasp venom and botulinum toxin, post-traumatic cavernous sinus thrombosis, fractures involving the orbital apex, and nerve compression by intraorbital foreign bodies have all been reported as mechanisms for traumatic neurogenic ptosis due to their effects on CNIII or the sympathetic pathway.<sup>[16-20]</sup> While lid trauma often results in cicatricial retraction, it can sometimes result in traumatic mechanical ptosis due to

scar tissue that either restricts lid excursion or creates a mass effect that weighs the lid down as described in several case reports.<sup>[8-9,21]</sup> Traumatic stretching or pulling of the lid is known to produce traumatic aponeurotic ptosis via disinsertion of the levator aponeurosis from the tarsal plate.<sup>[3,22]</sup> According to the mechanism and severity of injury, the degree of ptosis may range from mild to severe, and MRD1 deficits may be transient or permanent.<sup>[2,22,23]</sup> It is worth noting that ptosis cases presumed to be due to microtraumas such as contact lens usage or intraocular surgery were not included in this study.

Tailoring the management approach for traumatic ptosis to the mechanism of ptosis has been shown to improve outcomes in non-traumatic cases.<sup>[24]</sup> From the results of our study, this appears to be the case in traumatic cases. The trends in the causes of traumatic ptosis and recommendations

for the management of traumatic ptosis based on this cohort are summarized in Table 2. The T<sub>myo</sub> subtype was the most common and most severe, impairing MRD1 by the largest margin. "Patients with T<sub>myo</sub> required the most surgical revisions, had the lowest likelihood of regaining symmetry, and required the most time to reach an optimized plateau after injury." However, management with external levator advancement (if levator function >5 mm) or frontalis sling (if levator function <5 mm) did improve lid height and symmetry in traumatic myogenic ptosis cases. In contrast, the majority of T<sub>apo</sub> cases responded well to conjunctiva-Müller resection surgery, which addresses aponeurotic dehiscence using internal levator advancement.<sup>[25]</sup> Mild T<sub>apo</sub> cases resolved well with non-operative management, perhaps due to the tissue tightening effects of fibroblast activity during the healing process after injury.<sup>[22]</sup> Complications including lagophthalmos and dry eye were the most common in the mechanical subgroup, which reflects the restricted lid excursion that often complicates cases involving cicatricial tethering.

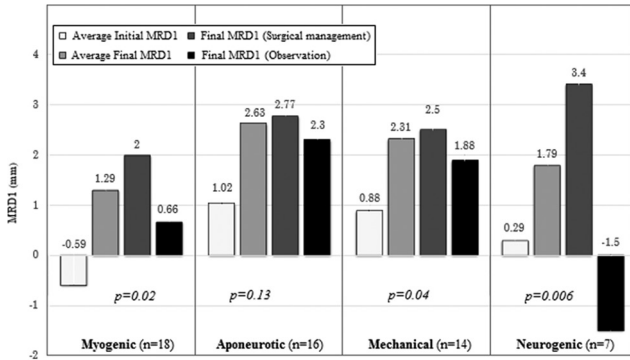


Figure 2. Initial and final margin reflex distance 1 with versus without surgery.

Table 2. Trends within traumatic ptosis subgroups, and management recommendations

Clinical question	Recommendations
How likely is spontaneous recovery without surgical intervention? [Figure 2]	Wait ≥6 months before surgery in traumatic aponeurotic ptosis cases (significant spontaneous improvement can occur) Wait ≥6 months before surgery in traumatic myogenic and mechanical ptosis cases (allows for scar tissue stabilization) If no progressive improvement is seen after three months in traumatic neurogenic cases, surgery can be performed. If an improvement is observed, wait until 6 months
If surgery is recommended, how many procedures is a patient likely to require? Myogenic: 1 (n=6), 2 (n=2), 3 (n=1) Aponeurotic: 1 (n=9), 2 (n=2) Mechanical: 1 (n=7), 2 (n=3) Neurogenic: 1 (n=5)	Counsel patients that ~1/3 of traumatic myogenic and mechanical cases require multiple surgeries
Which surgical procedure should be utilized? Myogenic ELA (n=5), müllerectomy (n=3), frontalis sling (n=1) Aponeurotic Müllerectomy (n=8), ELA (n=3) Mechanical ELA (n=7), Müllerectomy (n=3) Neurogenic Müllerectomy (n=3), ELA (n=2)	Perform phenylephrine testing in all cases Majority of traumatic aponeurotic and neurogenic cases responded well to müllerectomy Majority of traumatic myogenic and mechanical cases required ELA Frontalis sling should be considered if levator function ≤5 mm, regardless of traumatic subtype Avoid aggressive lifting in traumatic mechanical ptosis cases due to higher risk of symptomatic lagophthalmos in this subgroup
What is the overall prognosis? Meaningful improvement* Myogenic (29%), aponeurotic (68%) Mechanical (39%), neurogenic (29%) Partial improvement** Myogenic (24%), aponeurotic (13%) Mechanical (46%), neurogenic (43%) Unsatisfactory Myogenic (47%), aponeurotic (19%) Mechanical (15%), neurogenic (28%)	Traumatic aponeurotic ptosis has the highest rate of meaningful resolution Traumatic mechanical and neurogenic cases can be, at least, partially improved Neurogenic cases show significantly more improvement with surgery compared to observation Half of the myogenic cases may remain unsatisfactorily resolved

\*Criteria for meaningful improvement: MRD1 asymmetry <1 mm, lid margin fully clears visual axis, and no symptomatic lagophthalmos.

\*\*Criteria for partial improvement: MRD1 ≥1.5 mm, and no symptomatic lagophthalmos. ELA, external levator advancement; MRD, margin reflex distance

Compared to other subtypes, patients with neurogenic traumatic ptosis showed the greatest benefit from surgery rather than observation. "Initially, neurogenic deficits should be observed for spontaneous recovery prior to intervention." McCullen et al and Satchi et al have each reported examples of recovery from isolated traumatic neurogenic ptosis, with initial recovery beginning after several weeks but potentially taking up to six months to reach plateau.<sup>[4,23]</sup> In our study, T<sub>neuro</sub> patients demonstrated better final outcomes after surgery compared to that after non-operative management. However, considering the potential for spontaneous recovery, adequate time should be allowed for improvement prior to surgical treatment. In accordance with institutional practice patterns, our T<sub>neuro</sub> patients were observed for spontaneous recovery after injury. Surgery was recommended when at least three months had elapsed and either (A) the patient had not shown any progressive recovery compared to presentation, or (B) progressive recovery had occurred and a clear plateau had been reached after serial examinations of MRD1.

This study has several limitations including its retrospective design, the small subgroup size, and the potential for multiple trauma subtypes to occur from a single injury which means that patients may not always fit into one discrete subgroup. Although several findings in the study reached statistical significance, the inherent variability in trauma mechanism and severity prevents the findings from being applied directly to prognosis or treatment. Management must still be on a case-by-case basis. Nevertheless, this study suggests that there are meaningful differences between traumatic ptosis subtypes (myogenic, aponeurotic, mechanical, and neurogenic) which can be used to guide a more systematic approach to tailoring patient care. We recommend eliminating the usage of the vague term "traumatic ptosis" and encourage the classification of cases according to distinct subtypes (e.g. traumatic myogenic ptosis, and traumatic aponeurotic ptosis) to maintain precision when discussing and managing patients with ptosis secondary to injury.

### Financial Support and Sponsorship

Nil.

### Conflicts of Interest

There are no conflicts of interest.

### REFERENCES

- Cohen AJ, Weinberg DA. Evaluation and Management of Blepharoptosis. New York: Springer New York; 2010.
- Lim JM, Hou JH, Singa RM, Aakalu VK, Setabutr P. Relative incidence of blepharoptosis subtypes in an oculoplastics practice at a tertiary care center. *Orbit* 2013;32:231-234.
- Baylis HI, Sutcliffe T, Fett DR. Levator injury during blepharoplasty. *Arch Ophthalmol* 1984;102:570-571.
- Satchi K, Kumar A, McNab AA. Isolated traumatic neurogenic ptosis with delayed recovery. *Ophthalmic Plast Reconstr Surg* 2014;30:57-59.
- McCulley TJ, Kersten RC, Yip CC, Kulwin DR. Isolated unilateral neurogenic blepharoptosis secondary to eyelid trauma. *Am J Ophthalmol* 2002;134:626-627.
- Parwar BL, Fawzi AA, Arnold AC, Schwartz SD. Horner's syndrome and dissection of the internal carotid artery after chiropractic manipulation of the neck. *Am J Ophthalmol* 2001;131:523-524.
- Mondal N, Krishnamurthy S, Narayanan P, Srinivasan S. Bilateral ptosis in a child following massive attack by a swarm of wasps. *J Child Neurol* 2011;26:1322-1324.
- Donker DL, Paridaens D, Mooy CM, van den Bosch WA. Blepharoptosis and upper eyelid swelling due to lipogranulomatous inflammation caused by silicone oil. *Am J Ophthalmol* 2005;140:934-936.
- Gilil GA, Ibrahim RA, Barrada A, Radwaan R, Mohamed MA. Management of post-traumatic cicatricial ptosis. *Bull Ophthalmol Soc Egypt* 1975;68:545-553.
- Finsterer J. Ptosis: Causes, presentation, and management. *Aesthetic Plast Surg* 2003;27:193-204.
- Silkiss RZ, Baylis HI. Management of traumatic ptosis. *Adv Ophthalmic Plast Reconstr Surg* 1987;7:149-155.
- Berke RN. Surgical treatment of traumatic blepharoptosis. *Am J Ophthalmol* 1971;72:691-698.
- Pearl RM. Acquired ptosis: A reexamination of etiology and treatment. *Plast Reconstr Surg* 1985;76:56-64.
- Waller PY, Chossegros C, Semeria E, Gola R. Post-traumatic ptosis. *Rev Stomatol Chir Maxillofac* 1991;92:237-246.
- Betharia SM, Kumar S. Levator surgery in post traumatic ptosis. *Indian J Ophthalmol* 1987;35:132-135.
- Bagheri A, Borhani M, Salehirad S, Yazdani S, Tavakoli M. Blepharoptosis associated with third cranial nerve palsy. *Ophthalmic Plast Reconstr Surg* 2015;31:357-360.
- Senthilkumaran S, Menezes RG, Pant S, Balamurgan N, Thirumalaikolundusubramanian P, Lasrado S, et al. Isolated Horner's syndrome following penetrating neck injury. *Clin Neurol Neurosurg* 2013;115:1855-1857.
- Miller NR, Moses H. Ocular involvement in wound botulism. *Arch Ophthalmol* 1977;95:1788-1789.
- Coll GE, Boxrud CA, Steinsapir KD, Goldberg RA. Septic cavernous sinus thrombosis after head trauma. *Am J Ophthalmol* 1994;117:538-539.
- Lin C, Dong Y, Lv L, Yu M, Hou L. Clinical features and functional recovery of traumatic isolated oculomotor nerve palsy in mild head injury with sphenoid fracture. *J Neurosurg* 2013;118:364-369.
- Glasgow BJ, Vinters HV, Foos RY. Traumatic neuroma of the eyelid associated with ptosis. *Ophthalmic Plast Reconstr Surg* 1990;6:269-272.
- Arden RL, Moore GK. Complete post-traumatic ptosis: A mechanism for recovery? *Laryngoscope* 1989;99:1175-1179.
- Li G, Zhang Y, Zhu X, Hou K. Transient traumatic isolated neurogenic ptosis after a mild head trauma: A case report. *BMC Ophthalmol* 2015;15:161.
- Gao MH, Xu X, Yu J, Yu H, Chen YX. Surgical management of blepharoptosis: A report of 500 cases. *Zhonghua Zheng Xing Wai Ke Za Zhi* 2007;23:398-401.
- Morris CL, Morris WR, Fleming JC. A histological analysis of the müllerectomy: Redefining its mechanism in ptosis repair. *Plast Reconstr Surg* 2011;127:2333-2341.