

## CASE REPORT

# Severe congenital neutropenia associated with the ELANE gene in Chinese children: case report

Liwei Gao<sup>1</sup> | Jianxin He<sup>1</sup> | Runhui Wu<sup>2</sup>

<sup>1</sup>National Clinical Research Center for Respiratory Diseases, Department of Respiratory Medicine, Beijing Children's Hospital, Capital Medical University, National Center for Children's Health, Beijing, China

<sup>2</sup>Hematology Oncology Center, Beijing Children's Hospital, Capital Medical University, National Center for Children's Health, Beijing, China

### Correspondence

Runhui Wu, Hematology Oncology Center, Beijing Children's Hospital, Capital Medical University, National Center for Children's Health, Beijing, China.

Email: runhuiwu@hotmail.com

Received: 24 November, 2017

Accepted: 19 December, 2017

## INTRODUCTION

Congenital neutropenia (CN) is a rare primary immunodeficiency disease that includes severe congenital neutropenia (SCN) as a major subtype. SCN was first described in 1956 by Rolf Kostmann, and is characterized by an absolute neutrophil count (ANC) of  $<0.5 \times 10^9/L$ . SCN patients can also develop acute myelogenous leukemia (AML) and myelodysplastic syndrome (MDS).<sup>1</sup> In this study, we report two pediatric patients from one family with SCN associated with the neutrophil elastase gene (ELANE).

## CASE DESCRIPTION

A 10-month-old girl (P1) was admitted to our hospital as a result of recurrent fever that had persisted for 8 months. She had been diagnosed with stomatitis, cervical suppurative lymphadenitis, and pneumonia at the age of 2 months, 5 months, and 7 months, respectively. The infections could be controlled by antibiotic treatment at her local hospital. However, a new infection developed after an interval of 1 month. During this period, she was

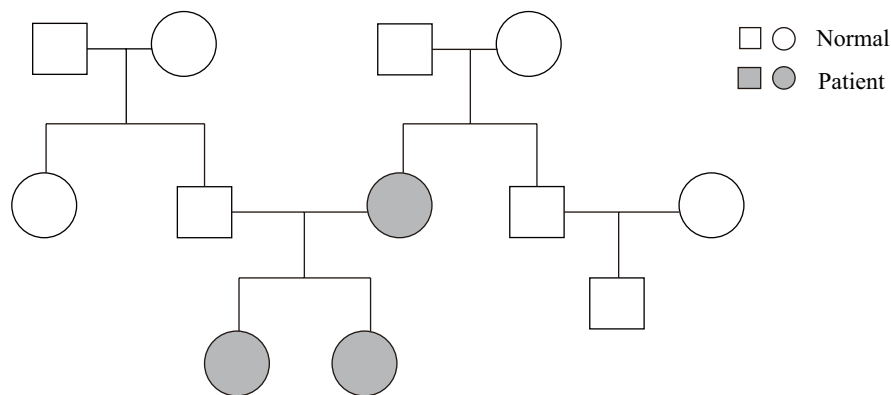
found to have neutropenia, with neutrophil counts ranging from  $0.21 \times 10^9/L$  to  $0.56 \times 10^9/L$ , with a high percentage of monocytes ( $>20\%$ ). Staphylococcus aureus was detected as the cause of suppurative lymphadenitis. Her sister, a 4-year-old girl (P2), had experienced recurrent episodes of bacterial infections such as pyoderma, stomatitis, pneumonia, cervical lymphadenitis, and chronic gingivitis since the age of 2 months. She also had a decreased number of neutrophils, ranging from  $0.26 \times 10^9/L$  to  $0.68 \times 10^9/L$ , with an elevated percentage of monocytes ( $>20\%$ ). Her hemoglobin levels were slightly lower during the time of infection. Six days before admission, the two siblings developed coughs and fever, and were diagnosed with bronchitis. However, they were still unstable after treatment with antibiotics, so were referred to our hospital.

Both patients were born via vaginal delivery at 39 weeks of gestation. Their mother had experienced recurrent soft tissue infections, pneumonia, and neutropenia ( $<0.1 \times 10^9/L$  neutrophils) since she was an infant, and her bone marrow analysis revealed maturation arrest of her myeloid lineage cells at the promyelocyte/myelocyte stage. Their mother had been treated by granulocyte colony-stimulating factor (G-CSF) at intervals until now that had reduced the time

DOI:10.1002/ped4.12027

This is an open access article under the terms of the Creative Commons Attribution-NonCommercial-NoDerivs License, which permits use and distribution in any medium, provided the original work is properly cited, the use is non-commercial and no modifications or adaptations are made.

©2018 Chinese Medical Association. *Pediatric Investigation* published by John Wiley & Sons Australia, Ltd on behalf of Futang Research Center of Pediatric Development.



**FIGURE 1.** The family pedigree.

of infection, but the number of neutrophils remained low. The patients' father was healthy. The family pedigree is shown in Figure 1.

On admission to our hospital, physical examination revealed the two children to be alert and febrile. Chest auscultation revealed no rales in the lungs. The other organs were normal. Laboratory investigations showed a white blood cell count of  $13.0\text{--}15.0 \times 10^9/\text{L}$ , a neutrophil count of  $0.2\text{--}0.3 \times 10^9/\text{L}$ , hemoglobin levels of 85–96 g/L, C-reactive protein levels of 30–40 mg/L, and normal liver, renal, and cardiac functions. No definitive evidence of infection by bacteria, viruses, fungi, or other pathogens was found. Immunological evaluation showed slightly higher IgA, IgM, and IgG serum concentrations. The numbers of circulating B cells, T cells, and natural killer cells were normal. A bone marrow smear showed decreased levels of mature granulocytes and maturation arrest of myeloid lineage cells at the promyelocyte/myelocyte stage in both patients. Respiratory burst activity detected by dihydrorhodamine 123 flow cytometry was normal. Genetic analysis confirmed the presence of a mutation (c. 302T>G (p. V101G)) in the neutrophil elastase gene (ELANE) in P1, P2, and their mother. It was the known pathogenicity of mutant site. Other genes, including HAX1, WAS, GF11, CSF3R, and CXCR4 which were related to CN, were normal. Therefore, ELANE-related SCN was confirmed in P1, P2, and their mother.

Two months later, both siblings received an allogeneic hematopoietic stem cell transplantation (HSCT). At their 6-month follow-up, the level of neutrophils in both patients was normal, but P1 had developed a rash and bronchiolitis obliterans. Their mother did not receive an HSCT because of financial constraints, but was treated with G-CSF intermittently. All members of the family were followed-up continuously.

## DISCUSSION

SCN is characterized by a permanently decreased ANC of

$<0.5 \times 10^9/\text{L}$ . Recurrent infection is the major manifestation, and the lungs are the most commonly infected site<sup>2</sup> followed by the oral cavity, skin, and soft tissue. ELANE mutations are the main cause of SCN, accounting for 38%–80% of cases.<sup>3</sup> ELANE encodes neutrophil elastase, which is a protease packaged in the primary granules of neutrophil precursors that degrades bacterial proteins and plays an important role in the innate immune system. More than 100 ELANE mutations have been reported in CN patients, with most being located in exons 4 and 5.<sup>3</sup> However, few cases have been reported in China, so there is no definitive prevalence of ELANE mutation sites in Chinese pediatric patients with ELANE-related SCN.

Preventing infection is an important therapy. G-CSF is known to increase blood neutrophil levels and reduce the incidence of infection. A dosage of 2–10  $\mu\text{g}/\text{kg}$  was previously shown to be effective for 70% of CN patients, while 10–20  $\mu\text{g}/\text{kg}$  was effective for 20% of CN patients.<sup>4</sup> However, long-term use of G-CSF was shown to can cause osteoporosis in 25% of SCN patients, and high doses of G-CSF appears to increase the risk of developing MDS or AML in CN patients with or without ELANE mutations after 15 years of treatment.<sup>4</sup> HSCT was demonstrated to be an effective method of treating patients with ELANE-related CN,<sup>5</sup> especially for G-CSF non-responders, patients with leukemic transformation, or those with C151Y and G214R mutations.

## CONFLICT OF INTEREST

The authors declare that they have no competing interests.

## REFERENCES

- Horwitz MS, Corey SJ, Grimes HL, et al. ELANE mutations in cyclic and severe congenital neutropenia: genetics and pathophysiology. *Hematol Oncol Clin North Am.* 2013;27:19–41.
- Shu Z, Li XH, Bai XM, et al. Clinical characteristics of severe congenital neutropenia caused by novel ELANE gene

- mutations. *Pediatr Infect Dis J.* 2015;34:203-207.
3. Bellanné-Chantelot C, Clauin S, Leblanc T, et al. Mutations in the ELA2 gene correlate with more severe expression of neutropenia: a study of 81 patients from the French Neutropenia Register. *Blood.* 2004;103:4119-4125.
  4. Rosenberg PS, Zeidler C, Bolyard AA, et al. Stable long-term risk of leukaemia in patients with severe congenital neutropenia maintained on G-CSF therapy. *Br J Haematol.* 2010;150:196-199.
  5. Fioredda F, Iacobelli S, van Biezen A, et al. Stem cell transplantation in severe congenital neutropenia: an analysis from the European Society for Blood and Marrow Transplantation. *Blood.* 2015;126:1885-1892.

**How to cite this article:** Gao L, He J, Wu R. Severe congenital neutropenia associated with the ELANE gene in Chinese children: a case report. *Pediatr Invest.* 2018;2:59-61. <https://doi.org/10.1002/ped4.12027>