

# Comparison of surgically induced astigmatism between horizontal and X-pattern sutures in the scleral tunnel incisions for manual small incision cataract surgery

Yadollah Eslami, Arash Mirmohammadsadeghi

**Background:** Two types of popular scleral tunnel sutures in the manual small incision cataract surgery (MSICS) are horizontal and X-pattern sutures. Surgically induced corneal astigmatism (SIA) is a useful indicator of the suturing effect. **Aims:** To compare SIA between horizontal and X-pattern sutures in the scleral tunnel incisions for MSICS. **Design:** Prospective, nonrandomized comparative trial. **Materials and Methods:** After superior scleral tunnel incision and capsulorhexis, the nucleus was prolapsed into the anterior chamber and delivered. The wound was sutured with either horizontal or X-pattern suture. The simulated keratometry values were derived from the corneal topography preoperatively and 1.5 and 3 months postoperatively. **Statistical Analysis:** The SIA was calculated by Cartesian coordinates based analysis. **Results:** Sixty-four patients (32 patients in each group) were included in the study. In the horizontal suture group, the SIA centroid values at 1.5 and 3 months after the surgery were  $0.87 \times 1^\circ$  and  $1.11 \times 180^\circ$ , respectively, showing induction of against-the-rule astigmatism. In the X-pattern suture group, the SIA centroid values at 1.5 and 3 months after the surgery were  $0.61 \times 97^\circ$  and  $0.66 \times 92^\circ$ , respectively, showing induction of mild with-the-rule astigmatism. The difference between the amount of SIA at 1.5 and 3 months after surgery was small. **Conclusion:** In the MSICS, the X-pattern sutures were preferred to the horizontal sutures in the patients without significant preoperative steepening in line with the central meridian of the incision. In the cases with significant preoperative steepening, sutureless surgery or horizontal sutures were preferred. Corneal astigmatism in the patients undergoing MSICS was stable at 1.5 months after the surgery.

**Key words:** Horizontal suture, manual small incision cataract surgery, scleral tunnel incision, X-pattern suture

Manual small incision cataract surgery (MSICS) was one of the techniques, gaining popularity before the advent of the phacoemulsification.<sup>[1-13]</sup> Now, with increasing use of the phacoemulsification, the MSICS is again valuable for cataract surgery in the developing world, especially in the cases with a corneal scar or lens subluxation.<sup>[1-13]</sup> In some developing countries, the ophthalmology residents learn the MSICS initially, followed by the phacoemulsification.<sup>[1]</sup>

The scleral tunnel is the main incision of MSICS, as well as one of the incisions used for the phacoemulsification.<sup>[1-25]</sup> At the end of the surgery, the scleral tunnel can be sealed without sutures<sup>[1-16]</sup> or sutured in various ways.<sup>[17-25]</sup> Two types of popular sutures are horizontal and X-pattern sutures.<sup>[17-25]</sup> To the best of our knowledge, no study was performed about the benefits of each type of scleral tunnel suturing in the MSICS. The surgically induced corneal astigmatism (SIA) is a useful indicator of the suturing effect. In this study, the effects of two suture types (horizontal and X-pattern sutures) on the SIA in the scleral tunnel incisions for the MSICS were compared.

Farabi Eye Research Center, Tehran University of Medical Sciences, Tehran, Iran

**Correspondence to:** Dr. Arash Mirmohammadsadeghi, Farabi Eye Hospital, Ghazvin Square, Tehran, Iran. E-mail: a1sadeghi@yahoo.com

**Manuscript received:** 08.06.14; **Revision accepted:** 29.09.14

Access this article online

**Website:**

www.ijo.in

**DOI:**

10.4103/0301-4738.167113

**Quick Response Code:**



## Materials and Methods

In a nonrandomized comparative trial, 64 consecutive patients (64 eyes) diagnosed with a cataract in the Farabi Eye Hospital that required surgery were included. The patients with intra- and post-operative complications (vitreous loss and endophthalmitis), pediatric cataracts, traumatic cataracts, and previous ocular surgeries (scleral buckling surgery, vitrectomy, and strabismus surgery) were excluded from the study.

The study was approved by the institutional review board of the Farabi Eye Research Center and was compliant with the principles of the Declaration of Helsinki. Informed consent was obtained from all patients prior to surgery. Complete ophthalmologic examinations were done for each patient. Corneal topography (TMS-4, Tomey, Japan) was done for all patients prior to surgery. The simulated keratometry (Sim K) values were used as measures of corneal power. The amount of

This is an open access article distributed under the terms of the Creative Commons Attribution-NonCommercial-ShareAlike 3.0 License, which allows others to remix, tweak, and build upon the work non-commercially, as long as the author is credited and the new creations are licensed under the identical terms.

**For reprints contact:** reprints@medknow.com

**Cite this article as:** Eslami Y, Mirmohammadsadeghi A. Comparison of surgically induced astigmatism between horizontal and X-pattern sutures in the scleral tunnel incisions for manual small incision cataract surgery. Indian J Ophthalmol 2015;63:606-10.

corneal astigmatism was calculated by subtracting Sim K values, using the plus cylinder notation. Types of preoperative corneal astigmatism (with-the-rule [WTR], against-the-rule [ATR], oblique) and their percentages were also recorded.

All surgeries were done by one of the authors (YE). The patients were allocated alternately to one of the groups: Horizontal or X-pattern suture group.

### Method of surgery

The surgeries were done under local (peribulbar) anesthesia. The incision was made on the steep meridian of preoperative astigmatism (if it was possible technically). The meridian of the incision was marked before anesthesia in the upright position to avoid errors induced by supine position and peribulbar anesthesia. Postoperatively, the actual site of incision was also checked. If there was any misalignment from the marked axis, the patient was excluded from the study. After superior rectus bridle suture (with 4/0 silk) and superior peritomy, the scleral incision (straight, 5 mm length, 2 mm posterior to limbus, and 1/2–2/3 of scleral depth) was made with the help of blade no. 15. The scleral tunnel was dissected with a crescent knife. The dissection continued 1–2 mm into clear cornea.<sup>[1]</sup>

A paracentesis was made at 10 o'clock position with 15° knife. After injection of viscoelastic into the anterior chamber, a large capsulorhexis (about 5–6 mm in diameter) was performed with an insulin needle through the paracentesis. Then, the scleral tunnel was opened into the anterior chamber with 15° knife and opened further with a crescent. Hydrodissection and hydrodelineation were performed in multiple quadrants.

The nucleus might be prolapsed into the anterior chamber during hydrodissection. If it did not occur, the prolapse could be done with bimanual technique.<sup>[1,2]</sup> In this technique, after injection of the viscoelastic, with the cystotome needle in the right hand and viscoelastic cannula in the left hand of the surgeon, the nucleus was pushed slightly to the right with cystotome needle. Then, the tip of the cannula was positioned under the left edge of the nucleus, and this edge of the nucleus was elevated slightly in front of the capsular bag.<sup>[2]</sup> With the help of both needle and cannula, the nucleus was rotated in a clockwise direction.<sup>[2]</sup> The cannula supported the posterior surface of the nucleus, and the needle rotated the nucleus clockwise out of the bag.<sup>[2]</sup>

After bringing the nucleus into the anterior chamber, a dispersive viscoelastic was injected into the front and back surface of the nucleus to protect the endothelium and posterior capsule. A lens loop was slipped under the nucleus, and a viscoelastic cannula was passed over the nucleus. The nucleus was sandwiched between these two instruments and gently taken out of the eye.

Then, the cortical materials were aspirated, and a foldable posterior chamber intraocular lens was implanted in the bag after viscoelastic injection. The wound was sutured with either horizontal or X-pattern suture [Figs. 1 and 2]. In the X-pattern suturing method [Fig. 1], the following parts of the incision were respectively passed by the suture needle: (1) Posterior lip of the left side of the incision, (2) Anterior lip of the right side of the incision, (3) Posterior lip of the right side of the incision, and (4) Anterior lip of the left side of the incision. In the horizontal suturing method [Fig. 2], the following parts of the incision were respectively passed by the suture needle: (1) Posterior lip of the left side of the incision, (2) Posterior lip of the right side of the incision, (3) Anterior lip of the right side of the incision, and (4) Anterior lip of the left side of the incision. In both suturing techniques, the suture knots were buried in the tunnel to avoid exposure. Then, the viscoelastic was removed and the paracenteses were hydrated. The conjunctival flap was repositioned over the incision with one suture.

### Postoperative follow-up

The patients were followed 1-day, 3 days, 1-week, 1.5 months and 3 months after cataract surgery. The scleral sutures were not removed at all. Any intraoperative or postoperative complications were noted. Corneal topography was repeated at 1.5 and 3 months after surgery. Again, the Sim K values and amount of corneal astigmatism were derived from the topography. The examiner that collected pre- and post-operative data was unaware of the group of the patients.

The amount of SIA was calculated by Cartesian coordinates based analysis (using SIA calculator, version 2.1 by Dr. Saurabh Sawhney and Dr. Aashima Aggarwal). In this system, the astigmatic vectors in each case were converted into horizontal (X) and vertical (Y) vectors. The X- and Y-vectors were averaged and reconverted into the astigmatic vector. This new astigmatic vector, called centroid, showed the magnitude

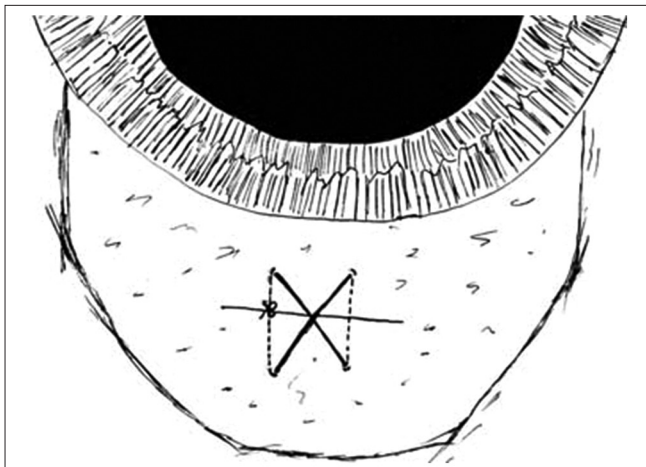


Figure 1: Scleral tunnel incision, X-pattern suture

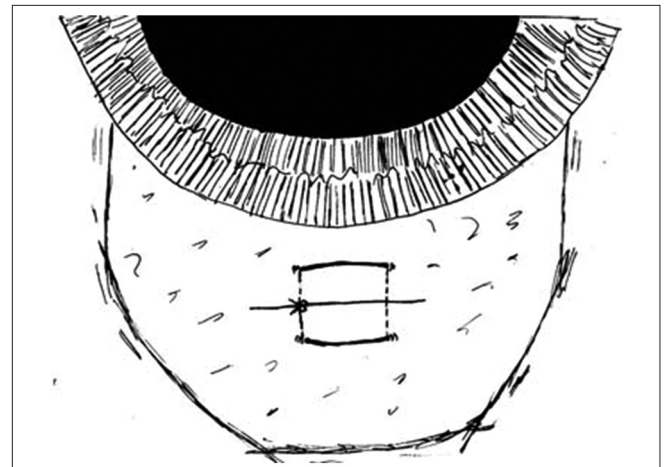


Figure 2: Scleral tunnel incision, horizontal suture

and axis of true mean astigmatism. This analysis was done preoperatively and 1.5 and 3 months postoperatively in each of the horizontal and X-pattern groups. The SIAs at 1.5 and 3 months after the operation were calculated by subtracting pre- and post-operative X vectors and also subtracting pre- and post-operative Y vectors. The resultant new X- and Y-vectors were converted into the centroid of SIA in each group. The coherence values were also described to demonstrate the reliability of centroid values.

The doubled-angle plots (DAP)<sup>[26]</sup> were also used to map the aggregate astigmatic data in both groups. In these plots, four concentric circles demonstrates the magnitude and axis of astigmatism from 0° to 180°.<sup>[26]</sup> The 12 o'clock position of the circle shows 45°, 9 o'clock position shows 90°, and 6 o'clock position shows 135° axis of astigmatism.<sup>[26]</sup> The center shows zero and each circle demonstrates 0.5 D steps.<sup>[26]</sup>

The other analyzes were done with SPSS version 20 (SPSS Inc., Chicago, IL). The Chi-square test was used to compare the percentages of different types of astigmatism between preoperative and 1.5 and 3 months postoperative examinations. The level of significance was considered to 0.05.

## Results

Sixty-four patients (32 patients in each group) were included in the study. Twenty-six patients were male. The mean age of the patients was  $67.3 \pm 8.2$  years. There were no significant differences in age and sex between two groups ( $P = 0.5$ ). The postoperative site of the incision was aligned with the marked axis in all cases. No complication occurred in these cases.

**Table 1: Number (percentage) of the patients with each type of astigmatism in preoperative and 1.5 and 3 months postoperative topographies**

Type of astigmatism	Preoperative (%)	1.5 months postoperative (%)	3 months postoperative (%)
WTR	18 (28.1)	19 (29.7)	19 (29.7)
ATR	16 (25.0)	32 (50.0)	33 (51.6)
Oblique	12 (18.8)	11 (17.2)	10 (15.6)
No astigmatism	18 (28.1)	2 (3.1)	2 (3.1)

WTR: With-the-rule, ATR: Against-the-rule

The number (percentage) of the patients with each type of astigmatism in preoperative and 1.5 and 3 months postoperative topographies were demonstrated in Table 1. In 1.5 and 3 months after the surgery, the percentages of different types of astigmatism were significantly different from the same percentages preoperatively (Chi-square test,  $P = 0.002$  and  $0.004$ , respectively). But these proportions were not significantly different between 1.5 and 3 months postoperatively (Chi-square test,  $P = 0.7$ ).

The results of Cartesian coordinates based analysis in each of the horizontal and X-pattern groups are summarized in Table 2. The relatively high levels of coherence for SIA in both groups showed reliability of centroid values. The preoperative centroid values showed small WTR astigmatism in both horizontal and X-pattern groups ( $0.36 \times 77^\circ$  and  $0.13 \times 77^\circ$ , respectively). In the horizontal suture group, the SIA centroid value ( $0.87 \times 1^\circ$ ) showed that ATR astigmatism was induced at 1.5 months after the surgery. The amount of the surgically induced ATR astigmatism was higher ( $1.11 \times 180^\circ$ ) at 3 months after the surgery. In the X-pattern suture group, the SIA centroid values at 1.5 and 3 months after the surgery ( $0.61 \times 97^\circ$  and  $0.66 \times 92^\circ$ , respectively) were lower than the horizontal suture group values, showing induction of mild WTR astigmatism. As demonstrated in Table 2, the difference between the amount of SIA at 1.5 and 3 months after surgery was small, especially in the X-pattern suture group.

The DAP of the preoperative astigmatism and 1.5 and 3 months postoperative SIA were shown in Figs. 3-5. Highly localized points around centroids in Figs. 4 and 5 showed that the SIA centroids were truly representative of data. Similarly, these plots showed that the horizontal sutures induced ATR astigmatism and the X-pattern sutures induced mild WTR astigmatism.

## Discussion

The MSICS is one of the effective techniques for cataract surgery.<sup>[1]</sup> Multiple studies compared the safety, efficacy, and cost of this technique with the phacoemulsification.<sup>[3-5]</sup> In 2007, Gogate *et al.* found that visual results of the MSICS and the phacoemulsification were comparable, but the MSICS was more economical than phacoemulsification because the last technique needed additional cost of the machine.<sup>[3,4]</sup> Ruit *et al.* found that both phacoemulsification and MSICS achieved

**Table 2: The results of the Cartesian coordinates based analysis in each of the horizontal and X-pattern groups**

	Mean±SD*		Horizontal suture centroid magnitude × axis (degree)	Horizontal suture coherence (%)	Mean±SD*		X-pattern suture centroid magnitude × axis (degree)	X-pattern suture coherence (%)
	Horizontal suture X value	Horizontal suture Y value			X-pattern suture X	X-pattern suture Y		
Preoperative astigmatism	-0.32±1.84	0.16±0.42	0.36×77	32	-0.12±0.81	0.05±0.29	0.13×77	23
1.5 months postoperative astigmatism	0.54±2.27	0.18±0.38	0.57×10	36	-0.71±1.01	-0.08±0.61	0.72×93	68
1.5 months postoperative SIA <sup>†</sup>	0.86±1.62	0.02±0.26	0.87×1	63	-0.59±1.03	-0.14±0.50	0.61×97	63
3 months postoperative astigmatism	0.78±1.66	0.16±0.30	0.80×6	55	-0.78±1.09	0.01±0.37	0.78×89	71
3 months postoperative SIA <sup>†</sup>	1.10±1.36	0.00±0.36	1.11×180	82	-0.66±1.12	-0.04±0.25	0.66×92	66

The unit of the astigmatic values was diopter. \*SD: Standard deviation, <sup>†</sup>SIA: Surgically induced astigmatism

excellent surgical outcomes with low complication rates.<sup>[5]</sup> They also found that the MSICS was significantly less expensive and less technology dependent than phacoemulsification and concluded that the MSICS may be the more appropriate surgical procedure for the treatment of advanced cataracts in the developing world.<sup>[5]</sup>

Our technique for the MSICS had slight differences with other studies. The main difference was the method of bringing nucleus into the anterior chamber. No complication occurred in our cases. However, controlled studies must be done to evaluate the safety and efficacy of our technique compared with other techniques and phacoemulsification.

Some studies evaluated the effect of suturing in scleral tunnel phacoemulsification on the amount of astigmatism.<sup>[17-25]</sup> Davison compared two groups of the patients operated with the scleral tunnel phacoemulsification with 4 mm and 5.5 mm incisions that all closed with two X-pattern sutures.<sup>[17]</sup> The average SIA in 1-year was  $-0.34 \pm 0.91$  for the 4.0 mm group and  $-0.23 \pm 1.01$  for the 5.5 mm group.<sup>[17]</sup> On the other hand, Storr-Paulsen analyzed postoperative corneal astigmatism after phacoemulsification with a 4 mm scleral tunnel incision and a single-stitch, horizontal suture technique.<sup>[18]</sup> The mean SIA was  $-0.01$  D at 1-year, and  $-0.07$  D at 3 years postoperatively.<sup>[18]</sup> To the best of our knowledge, no study about the effect of different types of scleral tunnel suturing in MSICS was published.

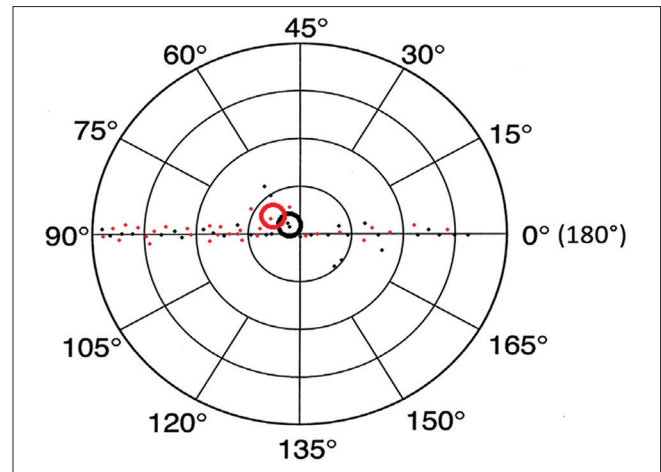
The MSICS could be done without sutures. Because of the expected surgically induced ATR astigmatism, wound suturing might be preferred to sutureless surgery. In this study, in the horizontal suture group, a postoperative shift toward ATR astigmatism was observed. But in the X-pattern group, the SIA was lower, with a smaller postoperative shift toward WTR astigmatism [Table 2 and Figs. 3-5]. The increase in the proportions of ATR astigmatism at 1.5 and 3 months after surgery [Table 1] might be due to the shift toward ATR in the horizontal suture group. Thus, when there is no significant preoperative steepening in line with the central meridian of the incision, wound suturing with X-pattern sutures is preferred. In the cases with significant preoperative steepening, sutureless surgery or horizontal sutures are preferred.

In this study, the patients were followed until 3 months after surgery. Because of the small difference between 1.5 and 3 months postoperative and surgically induced astigmatism in both groups, the astigmatism seems to be stable at 1.5 months after surgery. So, the other managements of the astigmatism (such as glasses or refractive surgery) in the patients that underwent MSICS might be done at 1.5 months after the surgery.

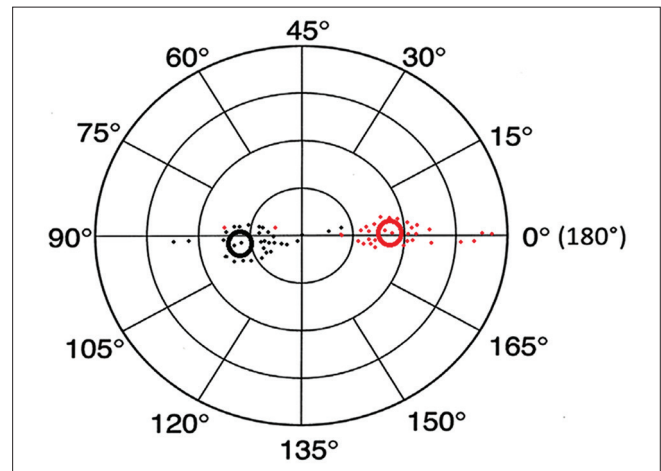
Our limitations were relatively low sample size, short length of follow-up, the absence of a control group with sutureless surgery, and the absence of a control group with phacoemulsification. Further studies must be done to evaluate any differences between the astigmatism in this technique and the clear corneal or scleral tunnel phacoemulsification.

## Conclusion

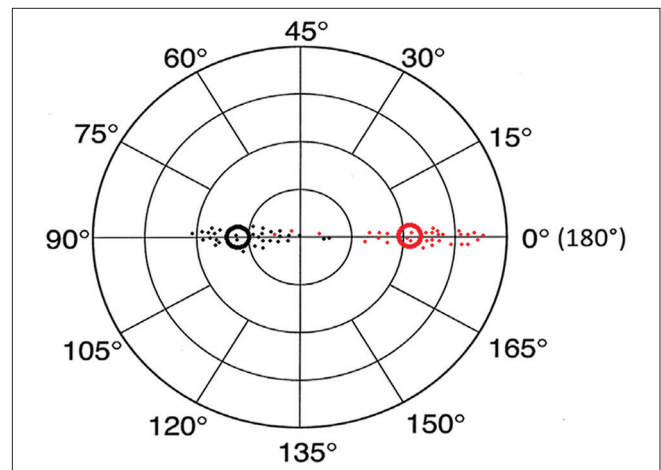
In the MSICS (an acceptable method for cataract surgery in the developing world), the horizontal sutures induced ATR astigmatism and the X-pattern sutures induced mild WTR astigmatism. So, the X-pattern sutures were preferred



**Figure 3:** Doubled-angle plot of preoperative astigmatism in horizontal (red color) and X-pattern (black color) suture groups. The hollow circles demonstrated centroid in each group



**Figure 4:** Doubled-angle plot of surgically induced astigmatism at 1.5 months after the operation in horizontal (red color) and X-pattern (black color) suture groups. The hollow circles demonstrated centroid in each group



**Figure 5:** Doubled-angle plot of surgically induced astigmatism at 3 months after the operation in horizontal (red color) and X-pattern (black color) suture groups. The hollow circles demonstrated centroid in each group

to the horizontal sutures in the patients without significant preoperative steepening in line with the central meridian of the incision. In the cases with significant preoperative steepening, sutureless surgery or horizontal sutures were preferred. Furthermore, the corneal astigmatism in the patients that underwent MSICS was stable at 1.5 months after the surgery.

#### Acknowledgements

The authors acknowledge the use of the SIA calculator version 2.1, ©2010 and also grateful to Dr Saurabh Sawhney and Dr Aashima Aggarwal, in the analysis of data in the present study.

#### Financial support and sponsorship

Nil.

#### Conflicts of interest

There are no conflicts of interest.

#### References

1. Khanna RC, Kaza S, Palamaner Subash Shantha G, Sangwan VS. Comparative outcomes of manual small incision cataract surgery and phacoemulsification performed by ophthalmology trainees in a tertiary eye care hospital in India: A retrospective cohort design. *BMJ Open* 2012;2. pii: e001035.
2. Ravindra MS. Nucleus management in manual small incision cataract surgery by phacoemulsification. *Indian J Ophthalmol* 2009;57:41-3.
3. Gogate P, Deshpande M, Nirmalan PK. Why do phacoemulsification? Manual small-incision cataract surgery is almost as effective, but less expensive. *Ophthalmology* 2007;114:965-8.
4. Gogate PM, Kulkarni SR, Krishnaiah S, Deshpande RD, Joshi SA, Palimkar A, *et al.* Safety and efficacy of phacoemulsification compared with manual small-incision cataract surgery by a randomized controlled clinical trial: Six-week results. *Ophthalmology* 2005;112:869-74.
5. Ruit S, Tabin G, Chang D, Bajracharya L, Kline DC, Riehheimer W, *et al.* A prospective randomized clinical trial of phacoemulsification vs manual sutureless small-incision extracapsular cataract surgery in Nepal. *Am J Ophthalmol* 2007;143:32-8.
6. Gogate P, Ambardekar P, Kulkarni S, Deshpande R, Joshi S, Deshpande M. Comparison of endothelial cell loss after cataract surgery: Phacoemulsification versus manual small-incision cataract surgery: Six-week results of a randomized control trial. *J Cataract Refract Surg* 2010;36:247-53.
7. Gogate PM, Deshpande M, Wormald RP, Deshpande R, Kulkarni SR. Extracapsular cataract surgery compared with manual small incision cataract surgery in community eye care setting in western India: A randomised controlled trial. *Br J Ophthalmol* 2003;87:667-72.
8. Bond BF. The small incision phaco section planned extracapsular manual technique. *Highl Ophthalmol* 1997;25:15-25.
9. Blumenthal M, Ashkenazi I, Assia E, Cahane M. Small-incision manual extracapsular cataract extraction using selective hydrodissection. *Ophthalmic Surg* 1992;23:699-701.
10. Hepsen IF, Cekiç O, Bayramlar H, Totan Y. Small incision extracapsular cataract surgery with manual phacotrisection. *J Cataract Refract Surg* 2000;26:1048-51.
11. Bayramlar H, Cekiç O, Totan Y. Manual tunnel incision extracapsular cataract extraction using the sandwich technique. *J Cataract Refract Surg* 1999;25:312-5.
12. Gokhale NS, Sawhney S. Reduction in astigmatism in manual small incision cataract surgery through change of incision site. *Indian J Ophthalmol* 2005;53:201-3.
13. Singh P, Singh S, Bhargav G, Singh M. Conjunctival flap in manual sutureless small-incision cataract surgery: A necessity or dogmatic. *Int Ophthalmol* 2012;32:349-55.
14. Yi K, Li Q. Unfolded intraocular lens implantation through a 6 mm sutureless incision. *Yan Ke Xue Bao* 1999;15:262-4.
15. Merriam JC, Zheng L, Merriam JE, Zaider M, Lindström B. The effect of incisions for cataract on corneal curvature. *Ophthalmology* 2003;110:1807-13.
16. Sadiq MN, Pai A, Kurup PM. Cataract surgeries by phaco-sandwich technique through sclerocorneal tunnel, a cohort study in Oman. *J Ayub Med Coll Abbottabad* 2006;18:53-7.
17. Davison JA. Keratometric comparison of 4.0 mm and 5.5 mm scleral tunnel cataract incisions. *J Cataract Refract Surg* 1993;19:3-8.
18. Storr-Paulsen A, Henning V. Long-term astigmatic changes after phacoemulsification with single-stitch, horizontal suture closure. *J Cataract Refract Surg* 1995;21:429-32.
19. Azar DT, Stark WJ, Dodick J, Khoury JM, Vitale S, Enger C, *et al.* Prospective, randomized vector analysis of astigmatism after three-, one-, and no-suture phacoemulsification. *J Cataract Refract Surg* 1997;23:1164-73.
20. Vass C, Menapace R, Rainer G. Corneal topographic changes after frown and straight sclerocorneal incisions. *J Cataract Refract Surg* 1997;23:913-22.
21. Mendivil A. Frequency of induced astigmatism following phacoemulsification with suturing versus without suturing. *Ophthalmic Surg Lasers* 1997;28:377-81.
22. Bellucci R, Morselli S, Pucci V, Palamara A. Corneal topography and astigmatism after superior sutured 8 mm scleral tunnel incisions. *J Cataract Refract Surg* 1996;22:690-5.
23. Gimbel HV, Sun R, DeBroff BM. Effects of wound architecture and suture technique on postoperative astigmatism. *Ophthalmic Surg Lasers* 1995;26:524-8.
24. Werblin TP. Refractive stability after cataract extraction using a 6.5-millimeter scleral pocket incision with horizontal or radial sutures. *J Refract Corneal Surg* 1994;10:339-42.
25. Rauber M, Grewing R, Mester U. Calculating the induced, computerized tomography measured corneal astigmatism after cataract surgery with small incision technique and wound closure with single suture technique based on various mathematical models. *Ophthalmology* 1993;90:336-8.
26. Holladay JT, Dudeja DR, Koch DD. Evaluating and reporting astigmatism for individual and aggregate data. *J Cataract Refract Surg* 1998;24:57-65.