

A Case of Intramural Pregnancy: Differential Diagnosis for Distinguishing from Retained Products of Conception and Gestational Trophoblastic Disease

Qing-Yun Song^{1,2}, Fan Yang^{1,2}, Hong Luo^{1,2*}

¹Department of Ultrasound, West China Second University Hospital, ²Key Laboratory of Obstetric and Gynecologic and Pediatric Diseases and Birth Defects of Ministry of Education, Sichuan University, Chengdu, Sichuan Province, China

Abstract

Intramural pregnancy refers to the implantation of fertilized eggs in uterine musculature, separated from the uterine cavity and tube. We report a case of intramural pregnancy previously misdiagnosed as retained products of conception and gestational trophoblastic disease. This case highlights the difficulty in the diagnosis of intramural pregnancy. Clinicians should be clear about the risk factors of the disease. Judicious selection of the appropriate imaging modalities is vital to making an accurate diagnosis and providing effective treatment.

Keywords: Gestational trophoblastic disease, intramural pregnancy, retained products of conception, ultrasound

INTRODUCTION

Intramural pregnancy is a rare ectopic pregnancy. It refers to the implantation of fertilized eggs in the uterine musculature, separated from the uterine cavity and tube. The incidence is <1% among ectopic pregnancies.^[1] It shows no specific early clinical manifestations, mostly amenorrhea, mild vaginal bleeding, abdominal pain, and Human Chorionic Gonadotropin (HCG) elevation. If left undetected and treated, it often leads to severe complications such as uterine rupture, massive hemorrhage, and infertility. Damage or defect of the endometrium due to a history of induced abortion, cesarean section and uterine curettage may be an important aspect in the pathogenesis. The fertilized eggs may implant into the myometrium through the damaged serous membrane. Difficulties during the *in vitro* fertilization and embryo transfer may also cause the embryos to implant into the myometrium. In the case of adenomyosis patients, the

embryos can enter the myometrium through the sinus of ectopic endometrium.^[2] We report herein a case of intramural pregnancy previously misdiagnosed as retained products of conception (RPOC) and gestational trophoblastic disease (GTD).

CASE REPORT

The patient was a 44-year-old female with G6P2 (spontaneous delivery once, cesarean section once, and induced abortion four times). Five months previously, the patient underwent uterine curettage in another hospital due to “50+ days of amenorrhea as well as RPOC in the uterine cavity.” The postoperative pathological examination findings indicated a less number of placental villi and a large amount of decidual tissue. Two months previously, uterine curettage was performed again in another hospital due to “RPOC in

Address for correspondence: Dr. Hong Luo,

Department of Diagnostic Ultrasound, West China Second University Hospital, Sichuan University, Chengdu, Sichuan Province 610041, China.

E-mail: huaxi2chaosheng@163.com

Article History:

Submitted: 8 May 2019

Revised: 25 December 2019

Accepted: 16 April 2020

Published: 15 October 2020

Access this article online

Quick Response Code:



Website:
www.e-gmit.com

DOI:
10.4103/GMIT.GMIT_39_19

This is an open access journal, and articles are distributed under the terms of the Creative Commons Attribution-NonCommercial-ShareAlike 4.0 License, which allows others to remix, tweak, and build upon the work non-commercially, as long as appropriate credit is given and the new creations are licensed under the identical terms.

For reprints contact: WKHLRPMedknow_reprints@wolterskluwer.com

How to cite this article: Song QY, Yang F, Luo H. A case of intramural pregnancy: Differential diagnosis for distinguishing from retained products of conception and gestational trophoblastic disease. *Gynecol Minim Invasive Ther* 2020;9:231-3.

the uterine cavity and HCG 1301 mIU/ml.” Postoperative Pathological results showed that there were no placental villi and trophoblast cells, but a small amount of degenerative smooth muscle tissue and broken endometrial tissue. The transvaginal ultrasound result at our hospital indicated distinguishable inferior endometrium, but the middle and upper endometria were unclear. There was a heterogeneous hyperechogenic mass with a clear boundary at the size of approximately 6.2 cm × 6.6 cm × 6.4 cm in the middle to the upper uterine segment. Several irregular liquid dark areas were detected in the mass, with a maximum diameter of 4.3 cm [Figure 1a]. Point-like or line-like blood flow signals were detected around and inside the mass, Resistance Index (RI) = 0.41 [Figure 1b]. Thoracic and abdominal enhanced computed tomography (CT) results were as follows: cystic and solid space-occupying lesions in the uterine cavity, with a clear flocculent heterogeneous enhancement in the right uterine wall and fundus uteri, reaching deep into the musculature. There were low-density focuses in the anterior and posterior uterine walls, and one in the anterior wall reached the serosa layer, suggesting trophoblastic tumors [Figure 1c]. In addition, a small nodule shadow of unknown nature appeared in the inner side of the middle lobe of the right lung [Figure 1d]. The patient’s serum HCG level was 547.9 mIU/ml.

Following three courses of diagnostic chemotherapy with (Etoposide+Methotrexate+Actinomycin D+cyclophosphamide) (MEA-CO), the serum HCG level decreased to 172.6 mIU/ml, while the uterine mass did not shrink. Therefore, hysterectomy

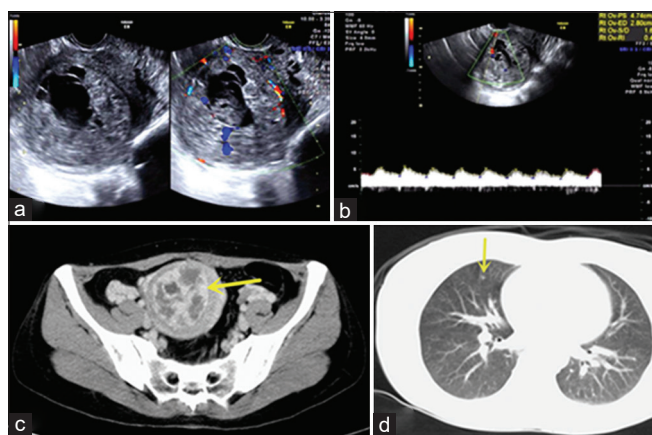


Figure 1: (a) The transvaginal ultrasound shows a heterogeneous hyperechogenic mass with a clear boundary in the middle to the upper uterine segment. (b) Point-like or line-like blood flow signals were detected around and inside the mass, RI = 0.41. (c) Abdominal enhanced computed tomography shows cystic and solid space-occupying lesions in the uterine cavity, with a clear flocculent heterogeneous enhancement in the right uterine wall and fundus uteri, reaching deep into the musculature. (d) Thoracic enhanced computed tomography shows a small nodule shadow of unknown nature appeared in the inner side of the middle lobe of the right lung

and hysterectomy were performed. The postoperative pathological examination results were as follows: the gross specimen revealed a dissected, spheric dark brown mass of 6.5 cm × 5.5 cm × 4.5 cm in the posterior wall of the uterus. A layer of opalescent translucent membranous tissue roughly 0.1 cm thick attached on the surface of the section, resembling the fetal membranes. Part of the area of the shape of a half-moon, approximately 5 cm × 2.5 cm, had peeled off [Figure 2a]. The section of the mass was map-like, showing extensive hemorrhage and necrosis, and of fragile texture. The mass invaded nearly the entire muscular wall. Pathological microscopy showed a large number of highly degenerative or fibrotic placental villi in the tissue of hemorrhage and necrosis in the muscular wall of the uterine floor and body [Figure 2b]. No trophoblastic tumors were detected.

DISCUSSION

A typical ultrasonographic image of intramural pregnancy shows a gestational sac in the myometrium, separated from the uterine cavity, and surrounded by abundant blood flow signals. However, sometimes, it is difficult to distinguish an intramural pregnancy from normal intrauterine pregnancy, liquefied uterine fibroids, or GTD. In retrospect, for this case, the internal hemorrhage and necrosis of a large mass appeared as heterogeneous liquid dark areas inside the mass on the ultrasound image. There were abundant blood flow signal surrounding the mass (RI<0.5), which was similar to the sonographic findings of GTD. However, the patient had a history of cesarean section and a slightly elevated blood HCG level. Enclosed by a layer of fetal membrane-like tissue, an intramural pregnancy shows a well-defined boundary in the ultrasound image, whereas the GTD usually does not have a sharp boundary due to its invasive nature. Intramural pregnancy should have been considered in the diagnosis of the patient. Unfortunately, due to the neglect of the possible impact of a large mass oppressing the uterine cavity on the examination, the diagnosis and treatment were negatively

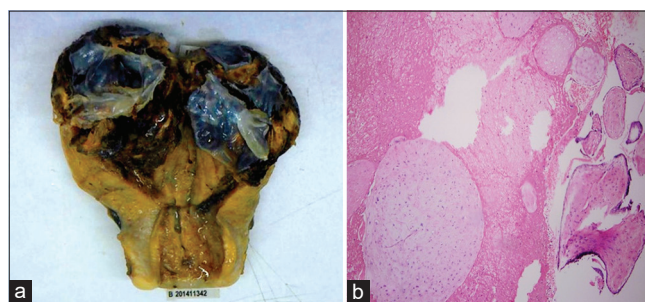


Figure 2: (a) The gross specimen revealed a dissected, spheric dark brown mass in the posterior wall of the uterus. (b) Histopathological image: Hemorrhage and necrotic tissues of intramural muscle wall showed a large amount of highly degenerated or fibrotic placental villus tissues

affected. First, the endometrial echoes at the upper and middle uterine segments were not clear; therefore, the conventional ultrasound could not accurately locate the mass. The suction device may impinge on the mass during the operation, hence the pathological findings following the first curettage showed a small number of placental villi. A suggested solution is to use saline infusion sonohysterography to reveal the uterine cavity and determine whether the mass is inside the uterine cavity.^[3] Second, intramural pregnancy and GTD can't be distinguished well by enhanced CT. Moreover, the patient's chest CT result showed a small solitary nodule, which also affected the judgment of the clinic physicians. The solution may be to prioritize magnetic resonance imaging and hysteroscopy in further examination.^[4]

In summary, this case highlights the difficulty in the diagnosis of intramural pregnancy. Clinicians should be clear about the risk factors of the disease. Judicious selection of the appropriate imaging modalities is vital to making an accurate diagnosis and providing effective treatment.

Ethical approval

This study was approved by the IRB of Sichuan University West China Second University Hospital (Approval number: 2020-014 obtained on May 10th in 2019).

Declaration of patient consent

The authors certify that they have obtained all appropriate patient consent forms. In the form, the patient has provided consent for her images and other clinical information to be reported in the journal. The patient understands that her name and initials will not be published and due efforts will be made to consent her identity, but anonymity cannot be guaranteed.

Financial support and sponsorship

Nil.

Conflicts of interest

There are no conflicts of interest.

REFERENCES

1. Biswas A, Choolani M, Ong C, Chia D, Su LL. Sonographic diagnosis and successful medical management of an intramural ectopic pregnancy. *J Clin Ultrasound* 2010;38:320-4.
2. Kirk E, McDonald K, Rees J, Govind A. Intramural ectopic pregnancy: A case and review of the literature. *Eur J Obstet Gynecol Reprod Biol* 2013;168:129-33.
3. Liao CY. Distinguishing between interstitial and angular pregnancies: Is there a role for saline infusion sonohysterography? *Taiwan J Obstet Gynecol* 2018;57:605-7.
4. Ko HS, Lee Y, Lee HJ, Park IY, Chung DY, Kim SP, *et al.* Sonographic and MR findings in 2 cases of intramural pregnancy treated conservatively. *J Clin Ultrasound* 2006;34:356-60.