

## Two cases of retrobulbar meningioma excised by skull base approaches

Masaki Fujioka,<sup>1</sup> Hiroshi Baba,<sup>2</sup>  
Keisuke Toda,<sup>2</sup> Akiyoshi Hirano<sup>3</sup>

Departments of <sup>1</sup>Plastic and Reconstructive Surgery; <sup>2</sup>Neurosurgery and National organization Nagasaki Medical Center, Nagasaki, Japan; <sup>3</sup>Department of Plastic and Reconstructive Surgery, Nagasaki University, Nagasaki, Japan

### Abstract

We present two cases of orbital meningioma which were totally excised by a neurosurgical and craniomaxillofacial team using skull base approaches.

### Introduction

We present two cases of orbital meningioma which were totally excised by a neurosurgical and craniomaxillofacial team using skull base approaches.

Orbital meningioma is relatively rare; they accounted for only 4% of orbital masses in a series of 1246.<sup>1</sup> Although locally invasive, meningioma has a favorable prognosis if completely removed.<sup>2</sup>

### Case Reports

#### Case #1

A 6-year-old girl consulted the department of neurosurgery complaining of acute loss of vision in the left eye of 6 months' duration. Visual activity was 1.2/1.2 OD and no light perception OS. Magnetic resonance imaging (MRI) indicated a mass around the optic nerve within the left orbital apex (Figure 1).

Tumor excision was performed via frontal craniotomy and orbitotomy. Because the mass measuring 2.3×0.5 cm was adherent to the optic nerve, it was excised completely along with the optic nerve (Figure 2). Histological examinations showed that the tumor consisted of bundles of spindle-shaped cells within a psammomatous body. Immunohistochemical staining revealed that the tumor cells were positive for keratin and involucrin, were negative for S-100 protein and epithelial membrane antigen. MRI of the orbit after surgery revealed

no residual tumor. There was no evidence of recurrence 3 years after surgery.

#### Case #2

A 59-year-old man presented with acute loss of light perception in the right eye of 6 months' duration. He had been examined at the department of ophthalmology 3 years previously. At that time visual activity was 1.2/1.5 OD and 1.2/1.2 OS, and ophthalmologic examination showed 3-mm proptosis of the right eye. MRI indicated a mass within the right orbital apex which was diagnosed as a meningioma. The patient was evaluated by a neurosurgeon, who recommended regular follow-up and treatment with cortico steroids. However, 3 years later the patient's eyesight rapidly deteriorated such that visual activity was counting fingers OD and 1.2/1.2 OS. Ophthalmologic examination showed 4-mm proptosis of the right eye. An MRI revealed a well-defined mass measuring 2.0×2.0 cm in the retrobulbar compartment of the right orbit (Figure 3). Computed tomography indicated no involvement of bony structures.

Frontal craniotomy with orbitotomy and complete removal of the tumor was performed. Although the tumor enclosed the optic nerve, it had not invaded to either the nerve or the orbital wall and could be separated easily. Histological examinations showed that solid nests of meningothelial cells arranged in whorls. Immunohistochemical studies showed that, most tumor cells were positive for S-100 protein and focally positive for Ki-67. These findings indicated that the tumor was a meningothelial meningioma. Ocular movement recovered completely and proptosis resolved within 1 year of surgery. There was no evidence of recurrence 4 years after surgery.

### Discussion

Extracranial meningiomas are unusual tumors that sometimes occur in the skin or soft tissue of the scalp or along the vertebral axis.<sup>3</sup> In particular, orbital meningiomas are so rare that only 53 (4%) were found in 1264 consecutive patients referred for an orbital mass, and Dalia and Neil reported that optic nerve sheath meningiomas comprise 1-2% of all meningiomas.<sup>1,4</sup>

Although extracranial meningiomas arise from ectopic arachnoid linking cells, their precise presentation suggests two pathogenetic mechanisms. One form, termed type I, usually gives rise to cutaneous lesions and is believed to be the result of abnormalities of neural tube closure. The second form (type II) arises around sensory organs or along the cranial and spinal nerves.<sup>5</sup> Orbital meningiomas arise from the skull base and spread via the sphenoid

Correspondence: Masaki Fujioka, Director of Department of Plastic and Reconstructive Surgery, National Nagasaki Medical Center, 1001-1 Kubara 2 Ohmura city, 856-8562 Japan. E-mail: mfujioka@nmc.hosp.go.jp

Key words: retrobulbar meningiomas, skull base approach, frontal craniotomy.

Conflict of interest: the authors report no conflict of interest.

Received for publication: 13 February 2010.  
Revision received: 29 September 2010.  
Accepted for publication: 6 October 2010.

This work is licensed under a Creative Commons Attribution 3.0 License (by-nc 3.0).

©Copyright M. Fujioka et al., 2010  
Licensee PAGEPress, Italy  
Rare Tumors 2010; 2:e60  
doi:10.4081/rt.2010.e60

noid ridge and the optic canal.<sup>2</sup> Case #1 originating in the arachnoid layer of the optic nerve, was categorized as type II and was designated a typical optic sheath meningioma. Although its form was not irregular, the tumor of case 2 was also considered to have originated from the optic nerve because it was separate from the intracranial meninges.

Most orbital meningiomas present with a slowly progressive optic neuropathy characterized by a variable loss of visual acuity. However, our cases showed acute loss of vision of 6 months' duration. Approximately 4-7% of optic nerve sheath meningiomas occur in childhood, and they grow faster, involve intracranial space more frequently than occurs in adults.<sup>6</sup>

Traditionally, orbital meningiomas have been observed without intervention, or treated by excision of the tumor along with the nerve because of difficulty of surgical approach. Attempts to excise these tumors while keeping the optic nerve intact had been unsuccessful.<sup>7</sup>

Berman et al. reviewed 150 articles and evaluated their over 100 cases of orbital meningioma, and reported that the short-term efficacy of stereotactic fractionated radiotherapy (SFR) in preserving or improving vision appears to be excellent, with more than half of the patients having an improvement within 3 months following treatment. They concluded that SFR is the best option for most cases of progressive or advanced disease.<sup>4</sup> However, late toxicity due to irradiation are sometimes seen including the optic nerve, retina, pituitary gland, and the white-matter tracts of the brain.<sup>8</sup> Retinal injury has been described with exposures of more than 50 Gy.<sup>9</sup> Late non-ocular side effects were also reported such as pituitary dysfunction and cerebral punctate small-

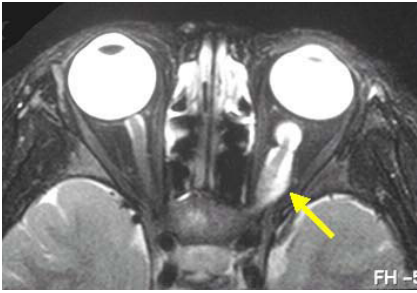


Figure 1. Axial magnetic resonance imaging of case 1 revealed a mass measuring 2.3×0.5 cm (arrow). It enclosed and adhered to the optic nerve.

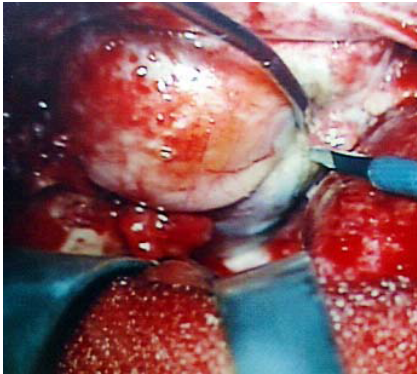


Figure 2. Intraoperative view of case #1. The tumor around the optic nerve was exposed through a defect of the orbital roof after orbitotomy.

vessel fallout.<sup>4</sup> These undesirable complications bring continuous distress for the patients and decrease their quality of life.

Extensive removal of orbital meningioma which is located in the posterior orbit is recommended because it prevents recurrence.<sup>10</sup> Orbital apex tumors were considered to be

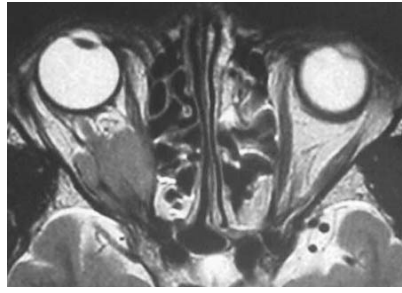


Figure 3. Axial magnetic resonance imaging of case 2 revealed a mass measuring 2.0×2.0 cm in the retrobulbar compartment of the right orbit causing proptosis.

unresectable previously, because of the risks involved with surgical intervention.<sup>11</sup> However, skull base approaches by a neurosurgical and craniomaxillofacial team provide excellent exposure of important neurovascular structures and enable total and extensive ablation of a retrobulbar mass.<sup>10</sup> We conclude that basal frontal craniotomy contributes to a successful, complete excision of retrobulbar meningiomas. Thus, extensive removal of orbital meningioma through an extradural route is recommended as a favorable option for patients with progressive or advanced retrobulbar meningioma.

## References

1. Shields JA, Shields CL, Scartozzi R. Survey of 1264 patients with orbital tumors and simulating lesions. The 2002 Montgomery Lecture, part 1. *Ophthalmology* 2004;111: 997-1008.

2. Farah SE, Konrad H, Huang DT, Geist CE. Ectopic orbital meningioma: a case report and review. *Ophthal Plast Reconstr Surg* 1999;15:463-6.
3. Lopez DA, Silvers DN, Helwing EB. Cutaneous meningiomas: a clinicopathologic study. *Cancer* 1974;34:728-44.
4. Berman D, Miller NR. New concepts in the management of optic nerve sheath meningiomas. *Ann Acad Med Singapore* 2006;35: 168-74.
5. Sharon WW, John RG. Extracranial meningioma. In: Strauss Med. *Soft tissue tumors: Benign tumors of peripheral nerves*. St. Louis: Mosby 2001:1193-6.
6. Saeed P, Rootman J, Nugent RA, et al. Optic nerve sheath meningiomas. *Ophthalmology* 2003;110:2019-30.
7. Miller NR. The evolving management of optic nerve sheath meningiomas. *Br J Ophthalmol* 2002;86:1198.
8. Stelzer KJ. Acute and long-term complications of therapeutic radiation for skull base tumors. *Neurosurg Clin North Am* 2000;11:597-604.
9. Parsons JT, Bova FJ, Fitzgerald CR, et al. Radiation retinopathy after external-beam irradiation: analysis of timedose factors. *Int J Radiat Oncol Biol Phys* 1994;30:765-73.
10. Sandalcioğlu IE, Gasser T, Mohr C, et al. Spheno-orbital meningiomas: interdisciplinary surgical approach, resectability and long-term results. *J Craniomaxillofac Surg* 2005;33:260-6.
11. Ugurlu S, Bartley GB. Evolution of an orbital apex tumor over a decade. *Ophthal Plast Reconstr Surg* 2004;20:75-7.