

CASE REPORT

Cardiology

Emergency department extracorporeal membrane oxygenation as a rescue therapy for ventricular tachycardia electrical storm: a case report

Andrew Pugh MBBS¹  | Joseph E. Tonna MD^{1,2} | Scott Youngquist MD¹ |
John J. Ryan MD, MB, BCh, BAO³ | Graham Brant-Zawadzki MD¹

¹Division of Emergency Medicine, Department of Surgery, University of Utah Health, Salt Lake City, Utah

²Division of Cardiothoracic Surgery, Department of Surgery, University of Utah Health, Salt Lake City, Utah

³Division of Cardiovascular Medicine, University of Utah Health, Salt Lake City, Utah

Correspondence

Andrew Pugh, MBBS, University of Utah Health, Salt Lake City, UT.
Email: andrew.pugh@hsc.utah.edu

Funding information

National Heart, Lung, and Blood Institute, Grant/Award Number: K23HL141596; National Institutes of Health

Funding and support: Dr. Tonna was supported by a career development award (K23HL141596) from the National Heart, Lung, and Blood Institute (NHLBI) of the National Institutes of Health (NIH).

Abstract

Arrhythmogenic right ventricular cardiomyopathy is a cause of sudden cardiac death in often otherwise healthy young adults. Cardiac arrest following an unstable tachydysrhythmia may be the primary presenting symptom. Venous arterial extracorporeal life support via extracorporeal membrane oxygenation (VA ECMO) has been used as a rescue strategy in emergency departments (EDs) for patients with cardiac arrest unresponsive to conventional cardiopulmonary resuscitation. We present a case of a previously healthy 18-year-old male who presented to our emergency department with ECG features of arrhythmogenic right ventricular cardiomyopathy and subsequent pulseless polymorphic ventricular tachycardia refractory cardiac arrest, treated with ED-initiated VA ECMO.

KEYWORDS

arrhythmogenic right ventricular cardiomyopathy, epsilon waves, extracorporeal life support, sudden cardiac death

1 | INTRODUCTION

Arrhythmogenic right ventricular cardiomyopathy is a cause of sudden cardiac death in often otherwise healthy young adults. Cardiac arrest following an unstable tachydysrhythmia may be the primary presenting symptom.¹ Venous arterial extracorporeal life support via extracorporeal membrane oxygenation (VA ECMO) has been used as a rescue strategy in emergency departments for patients with cardiac arrest unresponsive to conventional cardiopulmonary resuscitation.² We present a case of a previously healthy 18-year-old male who presented

to our ED with ECG features of arrhythmogenic right ventricular cardiomyopathy and subsequent pulseless polymorphic ventricular tachycardia refractory cardiac arrest, treated with ED-initiated VA ECMO.

2 | CASE

A previously healthy 18-year-old male presented to our ED following a witnessed episode of out-of-hospital cardiac arrest. He had been helping valet cars for a music event when he suddenly collapsed. Bystanders

Supervising Editor: Kelly N. Sawyer, MD

This is an open access article under the terms of the Creative Commons Attribution-NonCommercial-NoDerivs License, which permits use and distribution in any medium, provided the original work is properly cited, the use is non-commercial and no modifications or adaptations are made.

© 2020 The Authors. *JACEP Open* published by Wiley Periodicals LLC on behalf of the American College of Emergency Physicians.

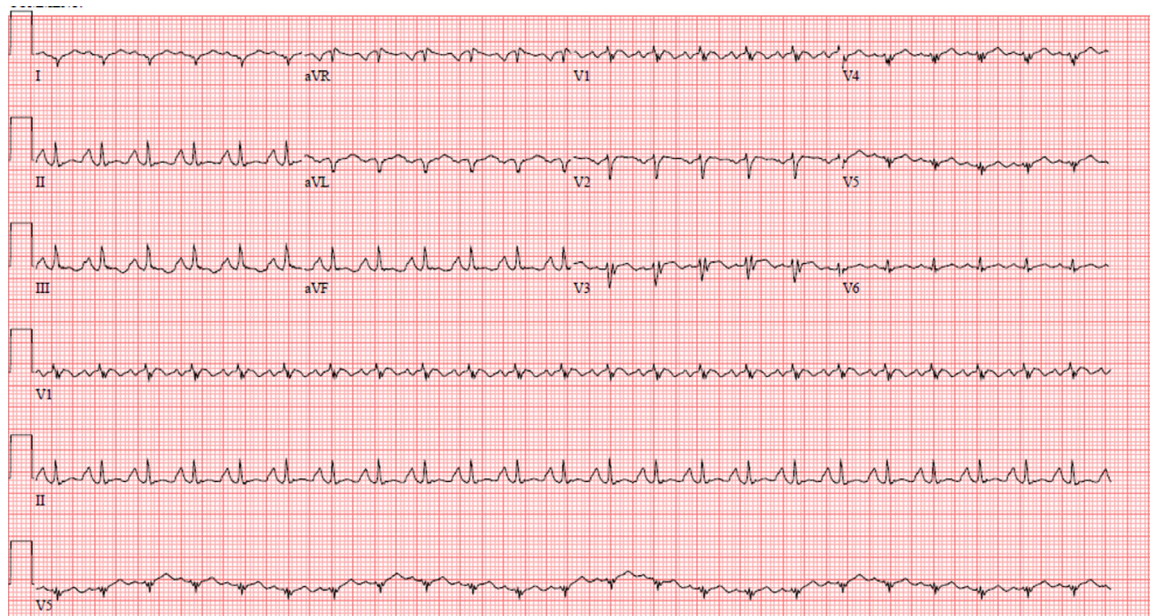


FIGURE 1 12 lead ECG prior to cannulation for VA ECMO

found the patient pulseless and immediately began cardiopulmonary resuscitation (CPR). During resuscitation, the patient began moving spontaneously, vomited, but again lost pulses; CPR resumed until emergency medical services (EMS) arrived 15 minutes after his initial collapse. On arrival, EMS continued one round of CPR and then successfully defibrillated the patient from ventricular tachycardia into sinus tachycardia. During his 25-minute ground transport time to our ED, the patient's rhythm returned to pulseless ventricular tachycardia and he was again defibrillated back into a perfusing normal sinus rhythm.

On arrival to our ED, the patient's neurologic status was rated 5 points by the Glasgow Coma Scale (GCS). Blood pressure was 149/70 mm Hg, pulse rate 116 beats/min, oxygen saturation 78% on 100% FiO₂ via laryngeal mask airway, respiratory rate 26 breaths/min, and temperature was 34°C. We performed tracheal intubation and found an initial end-tidal CO₂ reading of 26 mm Hg. We placed right femoral arterial line for real-time hemodynamic monitoring. ECG displayed sinus tachycardia, prolonged QT interval, and a distinct positive deflection following the QRS complex in lead V3 (Figure 1). Chest radiograph demonstrated a normal-sized heart with bilateral pulmonary congestion. Laboratory examination revealed an initial pH of 6.8, lactate 10.7 mEq/L, troponin I 0.44, platelets 133 thousand/deciliter, and INR 3.7. Computed tomography (CT) scan of the chest revealed diffuse alveolar hemorrhage and bilateral pleural effusions.

Shortly after this initial workup, the patient developed recurrent episodes of polymorphic pulseless ventricular tachycardia, each initially responsive to defibrillation but with ultimate reversion back into non-perfusing ventricular tachycardia. We administered magnesium sulphate and lidocaine for polymorphic ventricular tachycardia storm, as the patient's persistently low blood pressures between episodes of ventricular tachycardia initially precluded the use of beta-blockade medications. Unfortunately, the patient's clinical status continued to

deteriorate. In the setting of persistent hemodynamically unstable ventricular tachycardia refractory to medical management, we consulted the ECMO team to discuss its use in this case. Given the patient's persistent cardiac arrest secondary to electrical storm and refractory hypoxemia in the setting of massive pulmonary hemorrhage, the patient was cannulated for VA ECMO via the left femoral vein and left femoral artery. The patient stabilized on ECMO and was admitted to our cardiovascular intensive care unit. The patient had no prior ECGs for comparison.

Unfortunately, following stabilization of his electrical storm, the patient developed severe disseminated intravascular coagulation. Despite operative attempts at hemorrhage control and massive transfusion, the patient expired.

The patient's family consented to post-mortem examination that revealed fibrofatty changes in the myocardium of the right ventricle consistent with arrhythmogenic right ventricular cardiomyopathy. Further genetic testing revealed a pathogenic variant of the DSG2 gene, known to be associated with autosomal dominant arrhythmogenic right ventricular cardiomyopathy and dilated cardiomyopathy. The patient's family was notified, and family members were referred for further genetic testing.

3 | DISCUSSION

Here, we present a case of an 18-year-old previously healthy male with witnessed cardiac arrest and ECG features of arrhythmogenic right ventricular cardiomyopathy. Despite its low prevalence, arrhythmogenic right ventricular cardiomyopathy accounts for ≈5%–20% of sudden arrhythmic death cases in young people.³ Much of the available evidence regarding arrhythmogenic right ventricular cardiomyopathy management relates to stable patients. A paucity of evidence exists

to guide effective management of these patients in cardiac arrest secondary to recurrent ventricular arrhythmias. Our patient's ED course was characterized by the development of polymorphic ventricular tachycardia electric storm and hemodynamic stabilization with ECMO. The case is notable for the rarity of the underlying diagnosis, the size of the characteristic Epsilon waves on ECG, the infrequency with which polymorphic ventricular tachycardia is noted in cases of arrhythmogenic right ventricular cardiomyopathy, and for being the first reported case of ECMO use in decompensated arrhythmogenic right ventricular cardiomyopathy in the ED setting.

Arrhythmogenic right ventricular cardiomyopathy is a rare cardiovascular disease belonging to a subset of cardiomyopathies known as "arrhythmogenic cardiomyopathies" that each carry a propensity for arrhythmia.⁴ First described by Fontaine and colleagues, arrhythmogenic right ventricular cardiomyopathy is now understood as a genetically determined myocardial dystrophy propagated by an autosomal dominant pattern of inheritance, incomplete penetrance, and variable expressivity.⁵ In afflicted patients, pathogenic mutations lead to fibrofatty replacement of cardiac myocytes.⁶ This process originates in the epicardium of the right ventricle, progresses into the endocardium, and occasionally extends beyond the right ventricle.⁷ Subsequent functional impediment is seen most prominently in the subendocardial region of the right ventricle free wall, specifically in portions that experience the most mechanical stress during the cardiac cycle.^{3,6} These impairments may lead to conduction disturbances and corresponding characteristic ECG changes, local or global right ventricle enlargement, and significant cardiac dysrhythmia.⁸

Fontaine was also the first to describe a small positive deflection buried in the QRS segment of the ECGs of patients suffering from arrhythmogenic right ventricular cardiomyopathy. These waves were termed Epsilon waves and these post-excitation potentials occur between the end of the QRS complex and the T-wave. Epsilon waves are now understood to be specific for arrhythmogenic right ventricular cardiomyopathy, but only present in 30% of cases.⁹ The detection of Epsilon waves on 12-lead ECG has been associated with higher episodes of sustained ventricular tachycardia, but is not associated with increased sudden cardiac death risk.¹⁰ Epsilon waves and other electrical changes in arrhythmogenic right ventricular cardiomyopathy may precede structural cardiac change and may provide a clue to the presence of arrhythmogenic right ventricular cardiomyopathy in otherwise healthy patients. However, the sensitivity of Epsilon waves on the ECG is low, and therefore a normal ECG does not exclude the diagnosis.¹¹ Given the potential devastating consequences of missed diagnosis, providers should be aware of other major and minor diagnostic ECG criteria (Table 1).¹¹ Our case is unusual for the presence of Epsilon waves that were substantially taller than those typically observed in the literature and were initially confused with QRS fragmentation. In addition, the presence of polymorphic ventricular tachycardia is unusual; according to a large North American arrhythmogenic right ventricular cardiomyopathy registry, up to 94% of ventricular arrhythmias are monomorphic.¹²

Recommended treatment strategies to address arrhythmogenic right ventricular cardiomyopathy include exercise restriction,

TABLE 1 ECG features of arrhythmogenic right ventricular cardiomyopathy

I. Repolarization abnormalities	<p>Major:</p> <ul style="list-style-type: none"> • Inverted T waves in right precordial leads (V1, V2, and V3) or beyond in individuals > 14 years of age (in the absence of complete right bundle branch block QRS \geq 120 ms) <p>Minor</p> <ul style="list-style-type: none"> • Inverted T waves in leads V1 and V2 in individuals > 14 years of age (in the absence of complete right bundle branch block) or in V4, V5, or V6 • Inverted T waves in leads V1, V2, V3, and V4 in individuals > 14 years of age in the presence of complete right bundle branch block
II. Depolarization/conduction abnormalities	<p>Major</p> <ul style="list-style-type: none"> • Epsilon wave (reproducible low-amplitude signals between end of QRS complex to onset of the T wave) in the right precordial leads (V1 to V3) <p>Minor</p> <ul style="list-style-type: none"> • Late potentials by SAEKG in \geq 1 of 3 parameters in the absence of a QRS duration of \geq 110 ms on the standard ECG • Filtered QRS duration (fQRS) \geq 114 ms • Duration of terminal QRS $<$ 40 μ V (low-amplitude signal duration) \geq 38 ms • Root-mean-square voltage of terminal 40 ms \geq 20 μ V • Terminal activation duration of QRS \geq 55 ms measured from the nadir of the S wave to the end of the QRS, including R0, in V1, V2, or V3, in the absence of complete right bundle branch block
III. Arrhythmias	<p>Major</p> <ul style="list-style-type: none"> • Nonsustained or sustained ventricular tachycardia of left bundle branch morphology with superior axis (negative or indeterminate QRS in leads II, III, and aVF and positive in lead aVL) <p>Minor</p> <ul style="list-style-type: none"> • Nonsustained or sustained ventricular tachycardia of RV outflow configuration, left bundle branch block morphology with inferior axis (positive QRS in leads II, III, and aVF and negative in lead aVL) or of unknown axis • > 500 ventricular extra systoles per 24 h (Holter)

Marcus et al.¹¹

pharmacological therapy (primarily using beta-blockers, although anti-arrhythmic treatment with amiodarone may be indicated), radiofrequency catheter ablation, and/or an implantable cardiac defibrillator placement.⁹ Should patients with known or suspected arrhythmogenic right ventricular cardiomyopathy develop ventricular tachycardia storm, initial management should be the same as with other unstable tachydysrhythmias following advanced cardiac life support (ACLS) algorithms. Ensure reversible causes such as electrolyte disturbance are addressed, and if ventricular tachycardia persists, consider non-specific beta-blockade with an agent such as esmolol, which has the advantage of being rapidly titratable.⁹ Should providers suspect arrhythmogenic right ventricular cardiomyopathy, early cardiology consult for potential urgent cardiac ablation or implantable cardiac defibrillator placement is warranted.³

VA ECMO has been used as a rescue strategy in EDs for patients with cardiac arrest unresponsive to CPR by standard guidelines.¹³ VA ECMO as a bridge to arrhythmia quiescence in patients with ventricular tachycardia electrical storm has been documented in patients with other inherited arrhythmogenic conditions, and falls within recommendations for appropriate use.¹⁴ Our patient developed malignant ventricular arrhythmia and electrical storm in the setting of concurrent hypoxia due to massive pulmonary hemorrhage. Treatment with VA ECMO offered cardiopulmonary support, permitted the use of negative inotropic anti-arrhythmic drug therapy such as esmolol, and facilitated the weaning of pro-arrhythmic catecholaminergic medications. It should be noted that venous-venous ECMO would not have been sufficient in this case as it would only have improved oxygenation of the blood without improving tissue or coronary artery perfusion in the setting of hemodynamic instability and repeat cardiac arrest. Our case was notable for resolution of electrical storm facilitated by VA ECMO, but unfortunately complicated by hemorrhage. Disseminated intravascular coagulation is a known complication of "post-cardiac arrest syndrome" (PCAS), a complex global syndrome that occurs in the setting of total body hypoperfusion and subsequent reperfusion. Furthermore, disseminated intravascular coagulation has been shown to confer worse prognosis in patients with PCAS.¹⁵ In this case, the benefits of VA ECMO as a last resort for cardiopulmonary support were considered to outweigh the risks of cannulation in the setting of coagulopathy.

Despite the poor outcome in this case, the use of VA ECMO as a potential bridge to recovery in cases of hemodynamically unstable ventricular tachycardia electrical storm in the setting of underlying arrhythmogenic conditions such as arrhythmogenic right ventricular cardiomyopathy should be considered and warrants further study. Currently, the decision to deploy ECMO remains a multi-disciplinary decision that should be considered on a case-by-case basis, taking into account risks, benefits and any known patient wishes.

CONFLICTS OF INTEREST

JET was supported by a career development award (K23HL141596) from the National Heart, Lung, And Blood Institute (NHLBI) of the National Institutes of Health (NIH). JET received modest speakers fees from LivaNova and Philips Healthcare, outside of the submitted work.

ORCID

Andrew Pugh MBBS  <https://orcid.org/0000-0003-4605-0321>

REFERENCES

- Dalal D, Nasir K, Bomma C, et al. Arrhythmogenic right ventricular dysplasia: a United States experience. *Circulation*. 2005;112(25):3823-3832.
- Johnson NJ, Acker M, Hsu CH, et al. Extracorporeal life support as rescue strategy for out-of-hospital and emergency department cardiac arrest. *Resuscitation*. 2014;85(11):1527-1532.
- Neto JE, Tonet J, Frank R, Fontaine G. Arrhythmogenic Right Ventricular Cardiomyopathy/Dysplasia (ARVC/D) - what we have learned after 40 years of the diagnosis of this clinical entity. *Arq Bras Cardiol*. 2019;112:91-103.
- Elliott PM, Anastasakis A, Asimaki A, et al. Definition and treatment of arrhythmogenic cardiomyopathy: an updated expert panel report. *Eur J Heart Fail*. 2019;21(8):955-964.
- Goff ZD, Calkins H. Sudden death related cardiomyopathies - Arrhythmogenic right ventricular cardiomyopathy, arrhythmogenic cardiomyopathy, and exercise-induced cardiomyopathy. *Prog Cardiovasc Dis*. 2019;62(3):217-226.
- Gandjbakhch E, Redheuil A, Pousset F, Charron P, Frank R. Clinical diagnosis, imaging, and genetics of arrhythmogenic right ventricular cardiomyopathy/dysplasia: JACC state-of-the-art review. *J Am Coll Cardiol*. 2018;72(7):784-804.
- Basso C, Corrado D, Marcus FI, Nava A, Thiene G. Arrhythmogenic right ventricular cardiomyopathy. *Lancet*. 2009;373(9671):1289-1300.
- Zhang L, Liu L, Kowey P, Fontaine G. The Electrocardiographic manifestations of arrhythmogenic right ventricular dysplasia. *CCR*. 2014;10(3):237-245.
- Li KHC, Bazoukis G, Liu T, et al. Arrhythmogenic right ventricular cardiomyopathy/dysplasia (ARVC/D) in clinical practice. *J Arrhythm*. 2018;34(1):11-22.
- Protonotarios A, Anastasakis A, Tsatsopoulou A, et al. Clinical significance of epsilon waves in arrhythmogenic cardiomyopathy. *J Cardiovasc Electrophysiol*. 2015;26(11):1204-1210.
- Marcus FI, McKenna WJ, Sherrill D, et al. Diagnosis of arrhythmogenic right ventricular cardiomyopathy/dysplasia: proposed modification of the task force criteria. *Eur Heart J*. 2010;31(7):806-814.
- Link MS, Laidlaw D, Polonsky B, et al. Ventricular arrhythmias in the North American multidisciplinary study of ARVC: predictors, characteristics, and treatment. *J Am Coll Cardiol*. 2014;64(2):119-125.
- Tonna JE, Selzman CH, Mallin MP, et al. Development and implementation of a comprehensive, multidisciplinary emergency department extracorporeal membrane oxygenation program. *Ann Emerg Med*. 2017;70(1):32-40.
- Abrams D, Garan AR, Abdelbary A, et al. Position paper for the organization of ECMO programs for cardiac failure in adults. *Intensive Care Med*. 2018;44(6):717-729.
- Kim J, Kim K, Lee JH, et al. Prognostic implication of initial coagulopathy in out-of-hospital cardiac arrest. *Resuscitation*. 2013;84(1):48-53.

How to cite this article: Pugh A, Tonna JE, Youngquist S, Ryan JJ, Brant-Zawadzki G. Emergency department extracorporeal membrane oxygenation as a rescue therapy for ventricular tachycardia electrical storm: a case report. *JACEP Open*. 2020;1:371-374. <https://doi.org/10.1002/emp2.12053>