

Extraction of a “floating leadless pacemaker”: A case report



Masato Kawasaki, MD, Takahisa Yamada, MD, PhD, Tetsuya Watanabe, MD, PhD, Yoshio Furukawa, MD, PhD, Masatake Fukunami, MD, PhD

From the Division of Cardiology, Osaka General Medical Center, Osaka, Japan.

Introduction

The clinical efficacy of pacemaker therapy is well established. Early and late pacemaker adverse events are mostly associated with the implanted lead. Transcatheter pacing systems (TPS) represent an exciting recent development compared with conventional pacemakers.¹ Despite these promising results, the ability to retrieve a chronically implanted leadless pacemaker is an important component of leadless pacemaker management. Few reports on TPS retrieval have been presented in the literature, but apparent cases of dislodgement are rare.² We report a case of a TPS floating in the heart and its retrieval using a “double sheath/double snare technique.”

Case report

A 75-year-old man who had been fitted with a VVI pacemaker implanted 24 years prior was admitted to our hospital for lead extraction because of device infection. A successful open surgical extraction was undertaken. After antibiotic treatment, he underwent Micra TPS (Medtronic plc, Dublin, Ireland) implantation for bradycardia with atrial fibrillation. It was difficult to fix the system at the right ventricular septum, but uncomplicated. Two months after TPS implantation, it was decided to retrieve the TPS owing to the high pacing threshold. An 8.5F steerable catheter (Agilis; St Jude Medical, St Paul, MN) was introduced through the 23F Medtronic Micra sheath to the right atrium. The deflectable sheath was used to advance a retrieval device (20-mm snare). The single-loop snare was used to capture the retrieval feature on the device, and the device was removed to the right atrium. However, the tension on the snare was inadvertently reduced, and the device detached from the snare. A fluoroscopic check showed an impressive floating movement of the TPS in the right atrium.

KEYWORDS Bail-out; Double sheath/double snare technique; Floating; Leadless pacemaker; Removal
(Heart Rhythm Case Reports 2020;6:457–459)

Address reprint requests and correspondence: Dr Masato Kawasaki, Division of Cardiology, Osaka General Medical Center, 3-1-56 Bandai-Higashi, Sumiyoshi-ku, Osaka 558-8558, Japan. E-mail address: masato.kawasaki0731@gmail.com.

KEY TEACHING POINTS

- If you encounter a floating Micra transcatheter pacing system (Medtronic plc, Dublin, Ireland), you should catch it immediately with a snare anywhere on the device, so as to avoid cardiac injury by the tine or by the movement of the Micra device into the pulmonary artery.
- It might be more difficult to retrieve a floating Micra device with a single snare and single sheath than you can imagine.
- The “double sheath/double snare technique” is a method to retrieve a floating Micra device with ease.

Immediately, the snare was used to attempt to capture the retrieval feature on the device, but the attempt failed. We tried to grab the retrieval button with the first snare several times, but it was difficult or even dangerous, because the Micra device was not fixed. The unfixed Micra device rotated, jumped, and moved unexpectedly. Because it was difficult to grab the retrieval button, we decided to capture the device itself. One or 2 of the fixed tines could be easily captured by the snare. However, the device could not be properly aligned and retracted into the introducer. While the first snare kept hold of the tines of the device, another snare (20-mm snare) was advanced through another sheath to the right atrium, and the retrieval feature on the device was snared. Then, the first snare released the tines of the device and was used to catch the neck of the second snare, which held the device, and the device was retracted into the introducer with both the first and second snares and subsequently extracted from the body (Figure 1). It took 35 minutes from the time the device began floating to retrieve the device.

Discussion

The essence of this “double sheath/double snare technique” is that there is no need to catch the retrieval feature on the device directly with the first snare through a 23F Micra

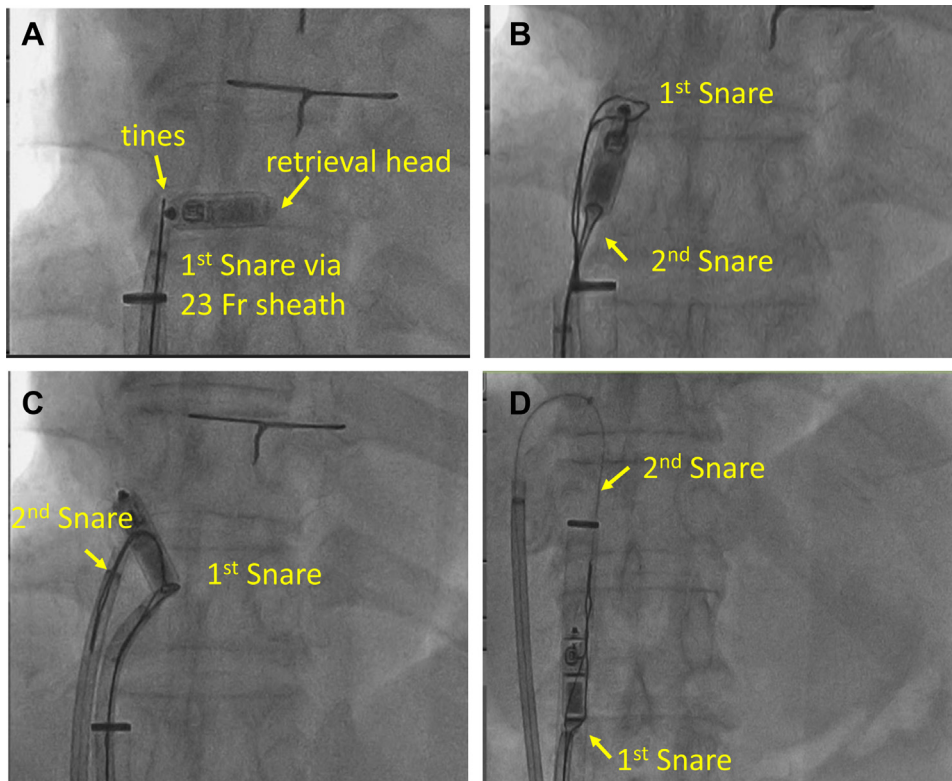


Figure 1 Retrieval procedure for a floating Micra transcatheter pacing system (Medtronic plc, Dublin, Ireland). **A:** Catch the tines with the first snare immediately. **B:** Catch the retrieval feature on the device with the second snare, then release the tines held by the first snare. **C:** Catch the neck of the second snare with the first snare. **D:** Extract the device together with the second snare.

sheath. The body of the Micra device is so large that it cannot be stored into an Agilis sheath. To remove the Micra device out of the body, it is necessary to store the device in a 23F Micra delivery sheath. It involves some risk to advance another 23F Micra delivery sheath into the right atrium, so

we used an Agilis sheath as the second sheath. (However, we should use a nondeflectable sheath as the second sheath from the viewpoint of cost.) A prior report used 2 snares through 1 sheath system.³ However, this can be technically challenging, because it is hard to control the second snare well. Fichtner and colleagues⁴ reported a method using a double sheath and double snare. They used 2 snares to retrieve a Micra, because the Micra was caught on the tricuspid valve and could not be retrieved with a single snare. The device was retrieved into the leadless pacemaker delivery sheath with both the snared tine and the body of the capsule, which is different from our method. It has been reported that it took a very long time to retrieve the Micra.⁴ Once a TPS is floating in the heart, the tines of the TPS will be stacked by the chordae tendinae of the tricuspid valve, or the TPS will migrate to the pulmonary artery; thus, it is important to catch the TPS immediately. While a hold was maintained on the TPS, the retrieval feature on the device could be grabbed with the second snare, and then the first snare could release the TPS. The neck of the second snare should be caught with the first snare, and then the Micra can be properly aligned and extracted completely. The retrieved device retained its original form, which showed the suitability of this procedure (Figure 2).



Figure 2 The retrieved device has retained its original form.

Conclusion

This is the first case report of a floating TPS retrieval in the heart with a “double sheath/double snare technique.”

References

1. Reynolds D, Duray GZ, Omar R, et al. A leadless intracardiac transcatheter pacing system. *N Engl J Med* 2016;374:533–541.
2. Roberts PR, Clementy N, Al Samadi F, et al. A leadless pacemaker in the real-world setting: the Micra Transcatheter Pacing System Post-Approval Registry. *Heart Rhythm* 2017;14:1375–1379.
3. Goyal R, Markowitz SM, Ip JE. Double-snare technique for capturing a wandering leadless pacemaker. *JACC Clin Electrophysiol* 2019;5:872–873.
4. Fichtner S, Estner HL, Nábauer M, Hausleiter J. Percutaneous extraction of a leadless Micra pacemaker after dislocation: a case report. *Eur Heart J Case Rep* 2019; <https://doi.org/10.1093/ehjcr/ytz113>.