

Case Report

Spinal epidural capillary hemangioma: A rare case report with a review of literature

Rajeev M. P., Pravin Y. Waykule, Pavitharan V. M., Nandeesh B. N.¹Department of Neurosurgery, GMCH, Kozhikode, Kerala, ¹Department of Neuropathology, NIMHANS, Bengaluru, Karnataka, IndiaE-mail: Rajeev M. P. - drrajeevmp@gmail.com; *Pravin Y. Waykule - pravin_waykule@rediffmail.com; Pavitharan V. M. - drpavitharanvm@gmail.com; Nandeesh B. N. - nandeeshbn@gmail.com

*Corresponding author

Received: 22 March 17 Accepted: 06 May 17 Published: 21 June 17

Abstract

Background: Purely epidural capillary hemangiomas are very rare. There are only 6 such reports.**Case Description:** A 50-year-old male presented with a progressive lower extremity paraparesis. Magnetic resonance imaging demonstrated a purely epidural lesion at the L1-L2 level without any bony involvement. Following an L1-L2 laminectomy for total excision of the lesion, the patient showed significant improvement. The histopathology was consistent with a pure capillary hemangioma.**Conclusion:** The radiological presentation of purely epidural capillary hemangiomas are often similar to those of schwannomas and meningiomas. Surgical confirmation of the pathology, and gross total excision of these lesions is recommended.**Key Words:** Epidural capillary hemangioma, meningiomas, schwannomas**Access this article online****Website:**www.surgicalneurologyint.com**DOI:**

10.4103/sni.sni_94_17

Quick Response Code:

INTRODUCTION

Capillary hemangiomas are very vascular malformations. Although 83% are located in the head or neck area,^[2,3,5-7] these as “infantile hemangiomas” and appear as raised, red, lumpy lesions occurring anywhere on the body. Most epidural hemangiomas are cavernous hemangiomas.^[1-3] However, epidural capillary hemangiomas are exceedingly rare lesions; reported in only 6 other cases.

CASE HISTORY

A 50-year-old male presented with a 1-year history of low back pain and rapid 1-month onset of a severe paraparesis without bladder and bowel involvement.

Examinations

On examination, he exhibited proximal iliopsoas/quadriceps weakness at the 2/5 level while extensor hallucis longus (EHL) was 0/5 on the right

and 1/5 on the left. He exhibited loss of patellar and Achilles responses, as well as decreased sensation to pin appreciation/vibration below the L1/L2 level. Laboratory examinations were within normal limits.

The magnetic resonance (MR) scan showed an isointense lesion 49 × 37 × 13 mm extending from the T12-L2 Level [Figure 1]. The T2 sagittal scan showed an irregular hyperintense lesion [Figure 2] that intensely enhanced with contrast [Figure 3]. Axial image of the lesion documented

This is an open access article distributed under the terms of the Creative Commons Attribution-NonCommercial-ShareAlike 3.0 License, which allows others to remix, tweak, and build upon the work non-commercially, as long as the author is credited and the new creations are licensed under the identical terms.

For reprints contact: reprints@medknow.com

How to cite this article: Rajeev MP, Waykule PY, Pavitharan VM, Nandeesh BN. Spinal epidural capillary hemangioma: A rare case report with a review of literature. *Surg Neurol Int* 2017;8:123.

<http://surgicalneurologyint.com/Spinal-epidural-capillary-hemangioma-A-rare-case-report-with-a-review-of-literature/>

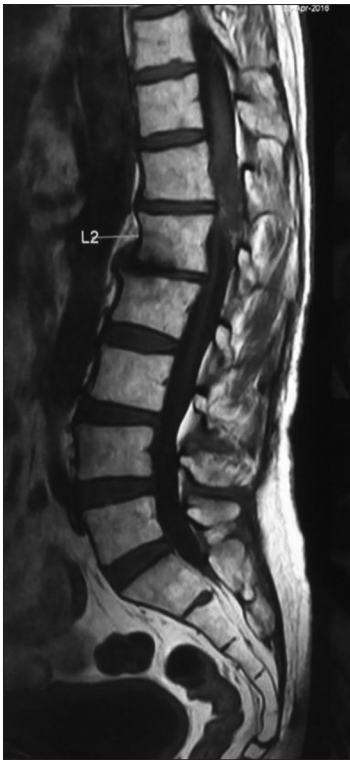

Figure 1: T1 sagittal image which shows isointense lesion which is extending from D12-L2 Level

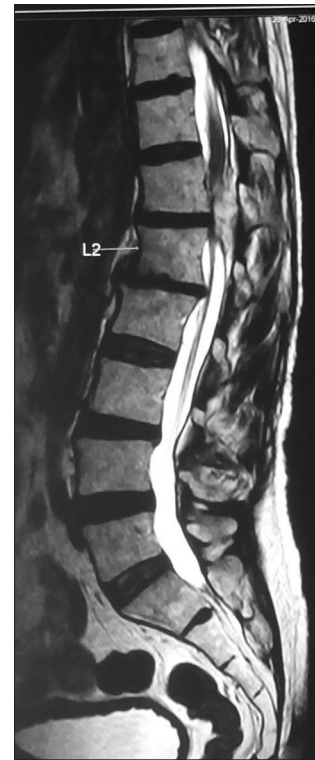

Figure 2: T2 sagittal image shows irregular hyperintense lesion

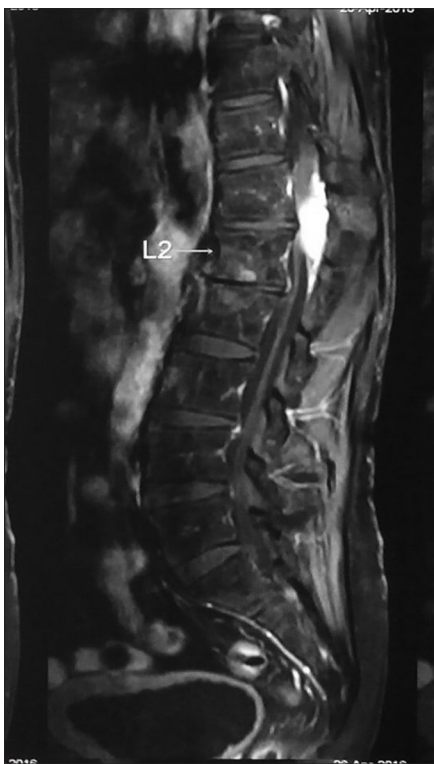

Figure 3: Lesion shows intense post contrast enhancement

its posterior/right lateral epidural location extending through the right L1-L2 neural foramen [Figure 4]. This resulted in severe cauda equina compression. The

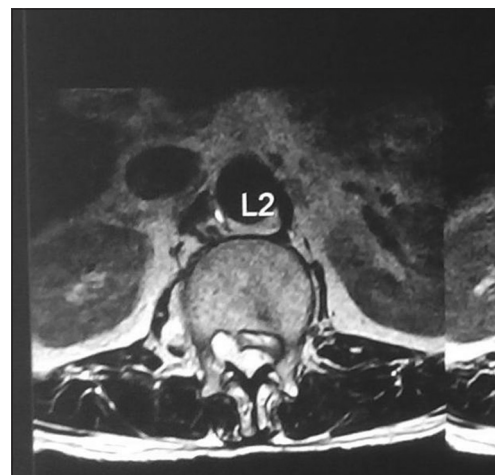


Figure 4: In Axial image the lesion is in posterior and right lateral epidural space extending to the right paraspinous region through the right L1-L2 neural foramina

radiological differential diagnosis was schwannoma vs. epidural hemangioma.

Surgery

Following an L1-L2 laminectomy, a 4 × 1 cm epidural, grayish, firm vascular lesion was observed filling the canal and extending through the right L1-L2 neural foramen. The lesion was easily dissected away from the dura and total excision of the mass was achieved [Figure 5]. Postoperatively, the motor exam improved to the 4/5 level and sensory deficits largely resolved. At 6 postoperative months, MR documented no residual or recurrent lesion [Figure 6].

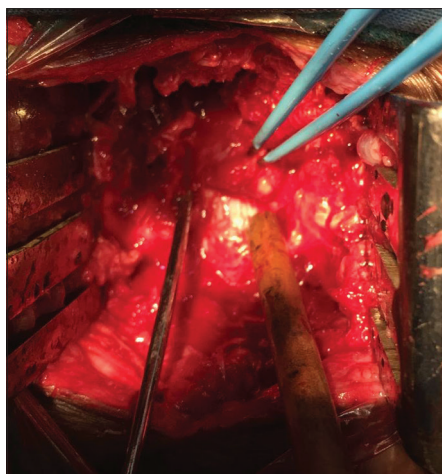


Figure 5: Intra operatively lesion is visible after lifting the dura

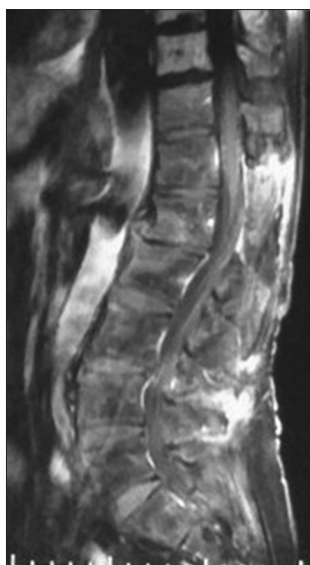

Figure 6: After 6 months of follow up MRI patient does not show any residual or recurrent lesion

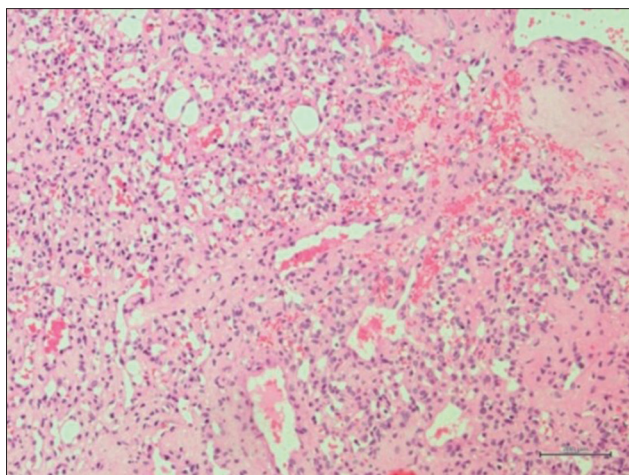


Figure 7: Histopathology sections of lesion shows vascular neoplasm composed of variable caliber blood vessels predominantly thin walled which are arranged back to back

Histopathology

The lesion was vascular, composed of variable caliber blood vessels predominantly thin-walled and back to back. There were areas of hemorrhage and some vessels were thrombosed. The neoplasm was also poorly circumscribed [Figure 7]. The diagnosis of capillary hemangioma was established.

DISCUSSION

Hemangiomas are congenital vascular malformations that pathologists frequently consider to be hamartomatous malformations. They are classified by the predominant type of vascular channel (capillary, cavernous, arteriovenous, or venous) observed on histologic examination. These are usually located in the soft tissue or bone but are mainly found in the spinal column.^[1,3-5] Purely epidural hemangiomas are rare; only 6 patients have been reported in the literature.^[1,6,7] The differential diagnosis for these lesions include nerve sheath tumors, meningiomas, hemangiopericytomas, hemangioblastomas, cavernous hemangiomas, and lymphomas.^[1] All reported cases presented with back pain, radicular pain, or chronic myelopathy because of mass effect, but not with acute or chronic bleeding. Most capillary hemangiomas are still radiologically misdiagnosed and/or mistaken for meningiomas or schwannomas.^[3] Surgical resection utilizing laminectomy/laminotomy should always be indicated regardless of the clinical presentation because of the risk of spinal cord compression.^[7] During surgery, the lesion presents as a reddish epidural mass with arterial feeders surrounding it. It is important to carefully dissect the lesion itself circumferentially away from the dura and exercise judicious hemostasis. Total surgical resection is feasible, although intervertebral foraminal extension may preclude it.

Financial support and sponsorship

Nil.

Conflicts of interest

There are no conflicts of interest.

REFERENCES

- Alakandy LM, Hercules S, Balamurali G, Reid H, Herwadkar A, Holland JP. Thoracic intradural extramedullary capillary haemangioma. *Br J Neurosurg* 2006;20:235-8.
- Aoyagi N, Kojima K, Kasai H. Review of spinal epidural cavernous hemangioma. *Neurol Med Chir (Tokyo)* 2003;43:471-5; discussion 476.
- Badinand B, Morel C, Kopp N, Tran Min VA, Cotton F. Dumbbell shaped epidural capillary hemangioma. *AJNR Am J Neuroradiol* 2003;24:190-2.
- Bozkus H, Tanriverdi T, Kizilkiliç O, Türeci E, Oz B, Hanci M. Capillary hemangiomas of the spinal cord: Report of two cases. *Minim Invasive Neurosurg* 2003;46:41-6.
- Caruso G, Galarza M, Borghesi I, Pozzati E, Vitale M. Acute presentation of spinal epidural cavernous angiomas: Case report. *Neurosurgery* 2007;60:E575-6; discussion E576.
- Gupta S, Kumar S, Banerji D, Pandey R, Gujral R. Magnetic resonance imaging features of an epidural spinal haemangioma. *Australas Radiol* 1996;40:342-4.
- Hasan A, Guiot MC, Torres C, Marcoux J. A case of a spinal epidural capillary hemangioma: Case report. *Neurosurgery* 2011;68:E850-3.