

BTK inhibitor combined with anti-PD-1 monoclonal antibody for the treatment of CD20-negative primary central nervous system lymphoma: A case report

LAN FENG^{1*}, XIAOHUI GAO^{1*}, ZHIYUN JIAO², ZHENG WANG³ and FENGLIN MIN⁴

Departments of ¹Hematology, ²Radiology and ³Pathology, The Affiliated Hospital of Yangzhou University, Yangzhou University, Yangzhou, Jiangsu 225009; ⁴Department of Hematology, Yangzhou Hospital of Traditional Chinese Medicine, Yangzhou, Jiangsu 225012, P.R. China

Received August 24, 2022; Accepted November 11, 2022

DOI: 10.3892/ol.2022.13634

Abstract. CD20-negative diffuse large B-cell lymphoma (DLBCL) is a rare type of lymphoproliferative disorder characterized by a high degree of aggressiveness, a tendency for extranodal invasion and chemotherapeutic resistance. CD20-negative DLBCL originating from the nervous system is rarer. In primary central nervous system lymphoma (PCNSL), >90% of cases are histologically classified as DLBCL. The present study reports the case of a 65-year-old female with CD20-negative PCNSL, whose primary clinical symptom was a persistent headache. Serum tests for human immunodeficiency virus, Epstein-Barr virus-DNA, human herpesvirus 8, hepatitis B and hepatitis C were negative. Cranial magnetic resonance imaging suggested multiple intracranial occupancies. The neoplastic cells were found to be positive for CD19, CD79 α , Bcl-2 (~92%) and c-Myc (~50%), while showing negative results for CD20, CD138, programmed cell death protein 1 (PD-1) and programmed cell death receptor 1 ligand 1 (PD-L1). The Ki-67 proliferation index was >80%. In the tumor microenvironment, <10% of the tumor-associated macrophages expressed PD-L1. The number of PD-1-positive tumor-infiltrating lymphocytes was 30-40 cells according to high-power field microscopy. The patient's disease progressed during methotrexate-based treatment, leading to a change in the treatment regimen to the Bruton tyrosine kinase inhibitor, zanubrutinib, combined with the anti-PD-1 monoclonal antibody tislelizumab. After two courses of the combined

treatment, the patient achieved complete remission (CR) and continued to receive consolidation treatment. In the 20 months of follow-up since CR was achieved, the patient's general condition was good and the disease was in continuous remission. The present case report and literature review show that a combination of drugs targeting different mechanisms may be used to treat PCNSL to prolong patient survival time. The mechanism of the enhanced efficacy of a combination of the two drugs may be related to the enhancement of antitumor T-cell immune responses and reversal of T-cell immune metabolic dysfunctions by the inhibition of glycolysis.

Introduction

CD20-negative diffuse large B-cell lymphoma (DLBCL) accounts for 1-3% of DLBCL cases (1). Commonly reported variants of CD20-negative DLBCL include plasmablastic lymphoma (PBL), primary effusion lymphoma (PEL), large B-cell lymphoma arising from human herpesvirus 8 (HHV8)-associated multicentric Castleman disease (MCD) and anaplastic lymphoma kinase (ALK)-positive DLBCL. Most CD20-negative DLBCL cases develop in the oral cavity, gastrointestinal tract, and other human body cavities (2-4). These lymphomas are associated with highly aggressive pathologies, chemotherapeutic resistance and poor prognoses (2). There is currently no effective treatment for this disease. Primary central nervous system lymphoma (PCNSL) originates in the CNS and accounts for 1-2% of all non-Hodgkin's lymphomas. Over 90% of PCNSL cases are histologically typed as DLBCL and express the pan-B cell markers CD20, CD19, CD22 and CD79a (5). In conjunction with a review of the relevant literature, the present study reports the case of a patient with CD20-negative PCNSL and the course of its diagnosis and treatment, in order to improve our understanding of the characteristics of this rare disorder.

Correspondence to: Dr Fenglin Min, Department of Hematology, Yangzhou Hospital of Traditional Chinese Medicine, 575 Wengchang Middle Road, Hanjiang, Yangzhou, Jiangsu 225012, P.R. China
E-mail: 1014121694@qq.com

*Contributed equally

Key words: CD20-negative diffuse large B cell lymphoma, primary central nervous system lymphoma, Bruton tyrosine kinase inhibitor, programmed cell death protein 1-1 inhibitor

Case report

In April 2020, a 65-year-old woman presented to The Affiliated Hospital of Yangzhou University (Yangzhou, China) with a persistent headache that had lasted for >10 days. The patient

had a history of hypertension of >10 years, but no personal or familial history of neurological disorders or genetic disorders, and no recent history of drug use. On admission, the blood pressure was 158/89 mmHg and vital signs were stable. No abnormalities were observed on cardiopulmonary, abdominal or neurological examination. Laboratory tests suggested that the results of routine blood and blood biochemical examinations were normal. Serum tests for human immunodeficiency virus (HIV), Epstein-Barr virus (EBV)-DNA, HHV8, hepatitis B and hepatitis C were negative. Cranial magnetic resonance imaging (MRI) showed multiple soft-tissue masses of varying sizes in both parietal lobes, the left basal ganglia and both temporal lobes, with a maximum size of ~3.1x2.1 cm, surrounded by irregular edematous signals and slightly narrowed adjacent ventricles, sulci and cisterns (Fig. 1A-F). Whole-body positron emission tomography-computed tomography (PET/CT) results suggested multiple mixed density shadows in the brain, abnormally increased fluorodeoxyglucose metabolism and a maximum standardized uptake value of 29.6, indicating the presence of a tumor. No significant abnormalities were found in other parts of the body. A left parieto-occipital intracerebral tumor resection, expanded meningeal repair and cranioplasty were performed in April 2020, at 23 days post-admission. Immunohistochemical analysis (Data S1) revealed that the tumor cells were positive for CD19, CD79 α , Bcl-2 (~92%), c-Myc (~50%), multiple myeloma oncogene 1 (Mum-1), lymphocyte common antigen and paired box protein 5, while showing negative results for CD20, CD10, CD38, CD56, CD138, Bcl-6, programmed cell death protein 1 (PD-1), programmed cell death receptor 1 ligand 1 (PD-L1), Epstein-Barr encoding region, terminal deoxynucleotidyl transferase and ALK. Microscopic examination revealed scattered positivity for CD3 and CD8, but no CD4 signal. The Ki-67 proliferation index was >80%. In the tumor microenvironment, <10% of tumor-associated macrophages expressed PD-L1, with an intermediate intensity of positive cells. The number of PD-1-positive tumor-infiltrating lymphocytes (TILs) was 30-40 cells in the high-power field microscopy, and the intensity of positive cells was intermediate (Fig. 2 and Data S1). Next-generation sequencing (Data S1) of the brain tumor tissue showed a CD79B p.Y196C missense mutation at 77.64% variant allele frequency (VAF), as well as an MYD88 p.L265P missense mutation at 31.75% VAF, a TP53 p.R110P missense mutation at 20.41% VAF and an IGH/D3-10-IGHJ3 gene rearrangement at 90.69% VAF. Fluorescence *in situ* hybridization (Data S1) of the tumor tissue was negative for the *IGH/BCL-2*, *Bcl-6*, *c-Myc* translocation and *TP53* gene deletion. Upon examination of the peripheral blood, the gene rearrangement of IGH and TCR was negative. Morphological examination and flow cytometry (Data S1) of the bone marrow revealed no abnormalities. Additionally, a bone marrow biopsy showed no evidence of lymphoma. Based on these results, the patient was diagnosed with CD20-negative PCNSL that was double positive for c-Myc and Bcl-2.

First, the patient was treated with high-dose methotrexate (HD-MTX) at 3.0 g/m² on day 1 and administered mannitol to lower cranial pressure, and analgesic symptomatic treatment. After the first cycle of HD-MTX, the patient's headache was not significantly relieved and was accompanied by limb weakness. A cranial MRI examination was performed again, revealing

multiple irregular nodular enhancement shadows in both parietal lobes and the right temporal lobe, with more and larger lesions than had been previously observed, increased edema around some of the lesions, new right ventricular compression narrowing and a midline left deviation. The regimen was then adjusted to HD-MTX combined with cytarabine (Ara-c) and temozolomide chemotherapy at the following doses: 3.5 g/m² MTX on day 1, 1.0 g/m² Ara-c every 12 h on days 2 and 3, and 220 mg temozolomide every day on days 1-5. The patient's headache was relieved by this therapy. However, the headache worsened in the intervals between chemotherapy, accompanied by vomiting and a loss of vision. The patient experienced left-sided limb weakness and impaired voluntary walking; a physical examination revealed that the muscle strength of the left limb was at grade 3. A third cranial MRI was performed, and the results showed that both sides of the parietal occupancy were larger than before, the extent of the surrounding brain parenchymal edema had increased, and the right ventricle and lateral fissure pool were significantly compressed. On assessing the patient's symptoms and MRI results, it was concluded that the patient's disease was progressing. The treatment regimen was changed to a Bruton tyrosine kinase (BTK) inhibitor combined with a PD-1 inhibitor, specifically zanubrutinib at 320 mg/day and tislelizumab at 200 mg on day 1 for 21 days in one cycle. The patient's headache and limb weakness were significantly relieved. After two courses of treatment (5 months after the first admission), the results of the cranial MRI review suggested that the patient's disease had reached complete remission (CR) (Fig. 1G-I). The patient continued to receive the same regimen for consolidation and as maintenance treatment, and a cranial MRI was performed every 3 months. In the 20 months of follow-up since the CR diagnosis, the patient's condition has ultimately remained stable and the patient is in good general condition with no significant toxic side effects.

Discussion

The CD20 protein is expressed in most B-cell tumors, and its expression levels vary amongst different types of diseases (4). Loss of CD20 expression can occur in primary large B-cell lymphomas. Known subtypes include PBL, PEL, ALK-positive DLBCL and large B-cell lymphoma arising in HHV8-associated MCD (2,3). These variants are frequently associated with HIV, EBV and HHV8 infections. The tumor cells are large with vesicular nuclei, and immature plasma cells or plasmablasts that express CD138, CD38, EMA and MUM1 are present amongst them. Most cases have extranodal invasion, more aggressive clinical features, and resistance to both rituximab and conventional chemotherapy (3,6). Some patients even experience rapid progression of their disease, resulting in no opportunity for them to receive chemotherapy (3,6). In this case, the primary mass was focally intracranial, and immunohistochemistry did not support the diagnosis of primary PBL, with negative serum tests for HIV, EBV-DNA and HHV8, unlike the four subtypes of primary CD20-negative large B-cell lymphoma. PCNSL has been identified as a distinct subtype of DLBCL according to the WHO lymphoma classification, and the majority of cases express CD20 and have a poor prognosis (5). Therefore, it is hypothesized that

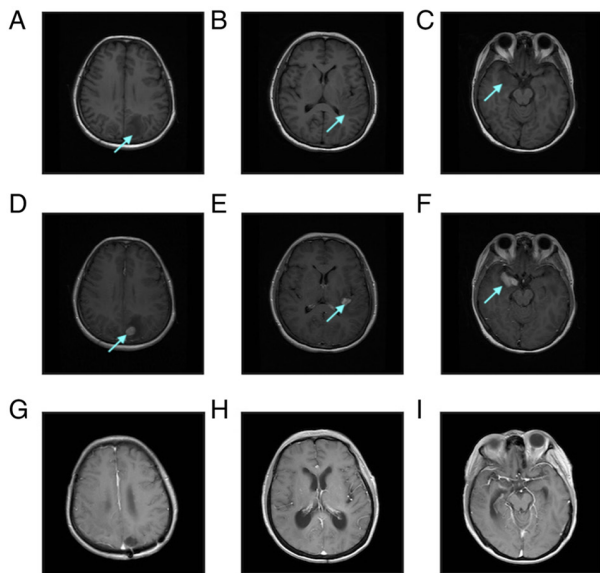


Figure 1. Pre-treatment and post-treatment MRI examinations of the patient. (A-C) Pre-contrast axial T1-weighted imaging revealed multiple patch-shaped hypo-intense shadows in both the parietal and temporal lobes, with blurred boundaries. (D-F) Post-contrast axial T1-weighted MRI showed multiple intense nodular mass enhancement shadows in both the parietal and temporal lobes. (G-I) After treatment with the Bruton tyrosine kinase inhibitor combined with the programmed cell death protein 1 monoclonal antibody regimen, post-contrast axial T1-weighted MRI showed the tumor lesion had disappeared and the surrounding patchy edema zone was no longer enhanced. The arrows show the tumor masses. MRI, magnetic resonance imaging.

CD20-negative PCNSL is more aggressive and patients may have a shorter survival time. In the present case, the patient had a rapidly progressing disease and showed primary resistance to chemotherapy.

The reason for the loss of CD20 expression remains unclear. CD20 is a non-glycosylated protein encoded by the MS4A1 gene located on chromosome 11q12.2 (7). Mutations in MS4A1, resulting in an altered protein conformation, have been proposed to be the molecular mechanism responsible for the CD20-negative phenotype (6). In an *in vitro* trial, Rushton *et al* (8) demonstrated that missense mutations in the MS4A1 gene within the transmembrane region resulted in the loss of CD20 expression, and that patients carrying the mutated gene were negative for CD20 expression. The study also found that MS4A1-harboring subclones might cause relapsing disease progression in a patient who had received multiple rounds of treatment. It has also been proposed that CD20 C-terminal deletion mutations in non-Hodgkin's lymphoma are associated with the loss of CD20 expression (9). Terui *et al* (9) found that downregulation or negativity of CD20 expression was closely associated with C-terminal deletion mutation. C-terminal deletion may mask CD20 expression on the cell surface or affect the time when CD20 is exposed to the cell surface. This previous study also found that the C-terminal CD20 deletion mutant mRNA was produced, but protein expression was not detectable at the cell surface. Further studies are required to investigate the effects of CD20 deficiency.

The current first-line treatment for PCNSL is HD-MTX-based chemotherapy. However, the median survival time of treated patients is short, and most patients relapse

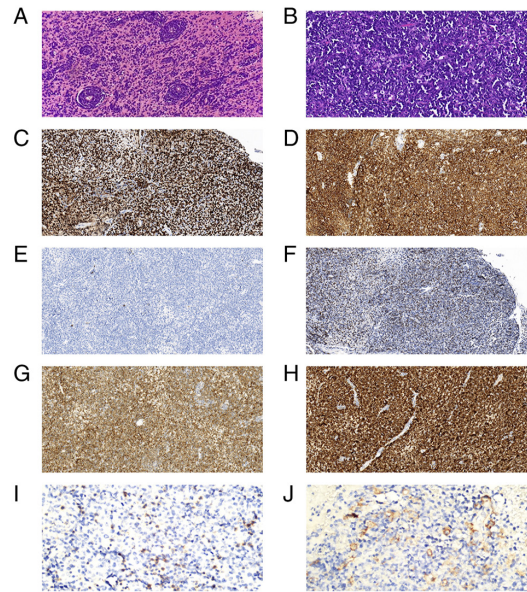


Figure 2. Histological characteristics of the resected brain mass. Light microscopy demonstrated diffuse growth of medium to large lymphoid cells on hematoxylin and eosin staining at (A) x20 and (B) x40 magnification. Immunohistochemistry showed that the tumor lymphocytes were positive for (C) Ki-67, (D) CD19, (E) CD20, (F) c-Myc, (G) Bcl-2, ~92% and (H) CD79 α (x200 magnification). Programmed cell death protein 1 expression: (I) Tumor cells(-), positive rate of tumor-associated macrophages was <10%, and the intensity of positive cells was moderate (x200 magnification). (J) Programmed cell death receptor 1 ligand 1 expression: Tumor cells(-), the number of positive tumor-infiltrating lymphocytes was 30-40 per field of view, and the intensity of positive cells was moderate (x200 magnification).

within a short period of time (5). In the present case, the disease continued to progress even after the administration of MTX and Ara-C standardized chemotherapy. Multiple clinical studies have shown that for patients with PCNSL as well as secondary CNS lymphoma, the administration of ibrutinib alone or in combination with chemotherapy is up to 50-90% effective, with a good overall response rate (ORR) and CR rate (10-12). In several clinical studies, patients with PCNSL, especially those with CD79B and MYD88 mutations, as well as CNS DLBCL, received ibrutinib alone or in combination with chemotherapy (11,13-15). The ORR was 50-90%, indicating a suitable CR rate and treatment effect (11). However, ibrutinib monotherapy for recurrent/refractory PCNSL has a low response rate and short median progression-free survival (PFS) time (14,16).

Immune checkpoint inhibitor (ICI)-PD-1 inhibitors have shown good antitumor effects in several malignant tumors (17-20). PD-1 inhibitors can reactivate cytotoxic T cell-mediated antitumor activity by blocking the binding between PD-1 expressed on T cells and PD-L1 expressed on tumor cells, thereby preventing the immune escape of tumors (13). Due to the large molecular weight of the anti-PD-1 monoclonal antibody, it rarely crosses the blood-brain barrier (BBB). Lymph vessels linking the CNS and deep cervical lymph nodes have been identified. Thus, T cells in the deep cervical lymph nodes can enter the intracranial and cerebrospinal fluid through the blood, while T cells and antigens in the CNS can enter the peripheral lymphatic system and activate T cells in the lymphoid tissue (13). By establishing a

melanoma tumor transplantation model with an intracranial plus extracranial (subcutaneous) tumor, Taggart *et al* (21) found that the application of ICIs (PD-1 inhibitors or CTLA-4 blockers) induced the activation and release of CD8⁺ T cells in extracranial tumors and enhanced the intracranial transport of CD8⁺ T cells by upregulating vascular cell adhesion molecule 1 (VCAM-1) and intercellular adhesion molecule 1 (ICAM-1) to achieve intracranial antitumor effects. Therefore, it was proposed that the intracranial efficacy of anti-PD-1 mAb is primarily achieved by increasing the intracranial transport of extracranially activated CD8⁺ T cells. CD4⁺ T cells are the first to enter the neural tissues as 'pioneers' regulating the entry of other T cells (including CD8⁺ T cells), as well as antibodies (22). It has been suggested that another possible mechanism for the enhanced efficacy of anti-PD-1/PD-L1-based treatments is the local production of IFN- γ by CD4⁺ T cells upon entry into the BBB. IFN- γ can upregulate the expression of VCAM-1 and ICAM-1 to loosen tight junctions between brain microvascular endothelial cells, increase BBB permeability, and facilitate the entry of other lymphocytes and circulating therapeutic antibodies into the CNS (13,22).

Anti-PD-1 monoclonal antibodies have been used in a variety of tumors to prolong patient survival time and have shown therapeutic efficacy in previous clinical trials on DLBCL. A phase Ib clinical trial found that among 11 DLBCL cases treated with nivolumab, the ORR was 36%, with two patients achieving CR (23). In another phase II study, patients with relapsed/refractory DLBCL, who were ineligible for autologous hematopoietic cell transplantation (auto-HCT) or who had experienced auto-HCT failure, received nivolumab treatment. Despite the low response rate to treatment, it was beneficial in extending the survival time of refractory patients (24). In a study by Nayak *et al* (25), four patients with relapsed/refractory PCNSL were treated with an anti-PD-1 monoclonal antibody, and three achieved CR with a PFS time of >13 months. These clinical trials provide a practical basis for the application of anti-PD-1 monoclonal antibodies in PCNSL.

However, no significant clinical effect has been observed for a combination of anti-PD-1 monoclonal antibodies and BTK inhibitors in solid tumors (17-20). There have been some studies on BTK inhibitors in combination with anti-PD-1 monoclonal antibodies for the treatment of B-cell lymphoma. Hanna *et al* (26) observed that ibrutinib effectively controlled the progression of chronic lymphocytic leukemia (CLL) while also reducing the activation, proliferation and efficacy of CD8⁺ T cells. However, the combination of ibrutinib with an anti-PD-1 monoclonal antibody can reduce CLL progression by increasing the percentage and function of effector CD8⁺ T cells. In a trial of PD-1 monoclonal antibodies in combination with a BTK inhibitor for platinum-resistant metastatic urothelial cancer, an increase in CD8⁺ T cells was observed for the combination treatment, despite no significant improvement in patient prognosis (19). However, in experiments using mouse models of lymphoma and CLL, combination therapy achieved better therapeutic results. In a study by Sagiv-Barfi *et al* (27), PD-L1 inhibitor monotherapy only modestly improved the survival of mice with ibrutinib-insensitive A20 lymphoma cells. However, when combined with ibrutinib, approximately one-half of the tumors in the mice were cured, and tumor growth in the

remaining mice was significantly reduced. The study also found evidence of tumor-specific T cells in the urine of mice treated with the combination treatment.

Both TILs and, potentially, tumoricidal macrophages, depend on aerobic glycolysis. Tumor cells can affect the metabolic structure of immune cells by depleting nutrients or directly competing for metabolic nutrients (especially glucose) (28). Tumor cells evade immunity through metabolic competition. Metabolic competition can limit T cell function and activity, and mediate T-cell hyporeactivity, resulting in tumor immune escape (28). Chang *et al* (29) found that blocking PD-L1 in tumor cells can inhibit mTOR activity and reduce the expression of glycolytic enzymes, thereby inhibiting glycolysis. Suppressed glycolytic capacity can leave more glucose available for T cells in the tumor extracellular environment to enhance their activity. Qorraj *et al* (28) found that the use of BTK inhibitors in CLL may exacerbate immune metabolic defects in monocytes. However, blocking PD-1/PD-L1 signaling could reverse these immune metabolic dysfunctions, including T-cell dysfunction.

In a clinical study of an orelabrutinib-based regimen for PCNSL, all four patients who were treated with a combination of orelabrutinib, camrelizumab (PD-1 monoclonal antibody) and fotemustine, with an ORR of 100%, had a 6-month PFS rate of 100% (30). In a prospective phase II study (NCT04899427), a combination of a BTK inhibitor (orelabrutinib) and PD-1 monoclonal antibody (sintilimab) was used for the treatment of relapsed/refractory PCNSL in 13 enrolled patients, and they had an ORR of 61.5%; four patients achieved CR, one patient achieved unconfirmed CR and three achieved partial remission (31). Several clinical trials of BTK inhibitors in combination with immune checkpoint inhibitors for PCNSL are currently underway, including acalabrutinib combined with durvalumab (NCT04462328) and nivolumab combined with ibrutinib (NCT03770416). As of June 2022, the patient in the present study had undergone 23 cycles of the BTK inhibitor combined with anti-PD-1 monoclonal antibody therapy, achieving CR with no significant adverse effects. The effectiveness of the combination of the two targeted drugs in treating PCNSL and the mechanism of the combination of the two drugs should be further confirmed by basic medical research and clinical trials.

In conclusion, by reviewing relevant basic medical research and the few current clinical trials, we propose that BTK inhibitor combined with PD1 monoclonal antibody is feasible for the treatment of PCNSL.

Acknowledgements

Not applicable.

Funding

No funding was received.

Availability of data and materials

The datasets used and/or analyzed during the current study are available from the corresponding author on reasonable request.

Authors' contributions

LF, XG, FM, ZJ and ZW confirm the authenticity of all the raw data. LF, XG, FM contributed to the analysis of the clinical data, as well as the writing of the manuscript. ZJ and ZW contributed to the collection of clinical and laboratory data. All authors read and approved the final version of the manuscript.

Ethics approval and consent to participate

The patient provided written informed consent for participation in the present study.

Patient consent for publication

The patient provided written informed consent for the publication of all the data and associated images.

Competing interests

The authors declare that they have no competing interests.

References

- Devi K, Ali N and Ahmed A: Case report of primary CD20 negative diffuse large B-cell lymphoma. *Oxf Med Case Reports* 2021: omab114, 2021.
- Qunaj L, Castillo JJ and Olszewski AJ: CD20-negative large B-cell lymphomas: Analysis of the National cancer database. *Blood* 128: 4226, 2016.
- Katchi T and Liu D: Diagnosis and treatment of CD20 negative B cell lymphomas. *Biomark Res* 5: 5, 2017.
- Tomita A: Genetic and epigenetic modulation of CD20 Expression in B-Cell Malignancies: Molecular mechanisms and significance to rituximab resistance. *J Clin Exp Hematop* 56: 89-99, 2016.
- Chihara D and Dunleavy K: Primary central nervous system lymphoma: Evolving biologic insights and recent therapeutic advances. *Clin Lymphoma Myeloma Leuk* 21: 73-79, 2021.
- Gamonet C, Bole-Richard E, Delherme A, Aubin F, Toussirot E, Garnache-Ottou F, Godet Y, Ysebaert L, Tournilhac O, Caroline D, *et al*: New CD20 alternative splice variants: Molecular identification and differential expression within hematological B cell malignancies. *Exp Hematol Oncol* 5: 7, 2016.
- Pavlasova G and Mraz M: The regulation and function of CD20: An 'enigma' of B-cell biology and targeted therapy. *Haematologica* 105: 1494-1506, 2020.
- Rushton CK, Arthur SE, Alcaide M, Cheung M, Jiang A, Coyle KM, Cleary KLS, Thomas N, Hilton LK, Michaud N, *et al*: Genetic and evolutionary patterns of treatment resistance in relapsed B-cell lymphoma. *Blood Adv* 4: 2886-2898, 2020.
- Terui Y, Mishima Y, Sugimura N, Kojima K, Sakurai T, Mishima Y, Kuniyoshi R, Taniyama A, Yokoyama M, Sakajiri S, *et al*: Identification of CD20 C-terminal deletion mutations associated with loss of CD20 expression in non-Hodgkin's lymphoma. *Clin Cancer Res* 15: 2523-2530, 2009.
- Goldwirt L, Beccaria K, Ple A, Sauvageon H and Mourah S: Ibrutinib brain distribution: A preclinical study. *Cancer Chemother Pharmacol* 81: 783-789, 2018.
- Lionakis MS, Dunleavy K, Roschewski M, Widemann BC, Butman JA, Schmitz R, Yang Y, Cole DE, Melani C, Higham CS, *et al*: Inhibition of B cell receptor signaling by ibrutinib in primary CNS lymphoma. *Cancer Cell* 31: 833-843. e5, 2017.
- Zhang Y, Li Y, Zhuang Z, Wang W, Wei C, Zhao D, Zhou D and Zhang W: Preliminary evaluation of zanubrutinib-containing regimens in DLBCL and the cerebrospinal fluid distribution of zanubrutinib: A 13-case series. *Front Oncol* 11: 760405, 2021.
- Zhou S, Xie J, Huang Z, Deng L, Wu L, Yu J and Meng X: Anti-PD-(L)1 immunotherapy for brain metastases in non-small cell lung cancer: Mechanisms, advances, and challenges. *Cancer Lett* 502: 166-179, 2021.
- Soussain C, Choquet S, Blonski M, Leclercq D, Houillier C, Rezai K, Bijou F, Houot R, Boyle E, Gressin R, *et al*: Ibrutinib monotherapy for relapse or refractory primary CNS lymphoma and primary vitreoretinal lymphoma: Final analysis of the phase II 'proof-of-concept' iLOC study by the Lymphoma study association (LYSA) and the French oculo-cerebral lymphoma (LOC) network. *Eur J Cancer* 117: 121-130, 2019.
- Rubenstein JL: Biology of CNS lymphoma and the potential of novel agents. *Hematology Am Soc Hematol Educ Program* 2017: 556-564, 2017.
- Grommes C, Pastore A, Palaskas N, Tang SS, Campos C, Schartz D, Codega P, Nichol D, Clark O, Hsieh WY, *et al*: Ibrutinib unmasks critical role of bruton tyrosine kinase in primary CNS lymphoma. *Cancer Discov* 7: 1018-1029, 2017.
- Taylor MH, Betts CB, Maloney L, Nadler E, Algazi A, Guarino MJ, Nemunaitis J, Jimeno A, Patel P, Munugalavada V, *et al*: Safety and efficacy of pembrolizumab in combination with acalabrutinib in advanced head and neck squamous cell carcinoma: Phase 2 Proof-of-Concept Study. *Clin Cancer Res* 28: 903-914, 2022.
- Overman M, Javle M, Davis RE, Vats P, Kumar-Sinha C, Xiao L, Mettu NB, Parra ER, Benson AB, Lopez CD, *et al*: Randomized phase II study of the Bruton tyrosine kinase inhibitor acalabrutinib, alone or with pembrolizumab in patients with advanced pancreatic cancer. *J Immunother Cancer* 8: e000587, 2020.
- Zhang T, Harrison MR, O'Donnell PH, Alva AS, Hahn NM, Appleman LJ, Cetnar J, Burke JM, Fleming MT, Milowsky MI, *et al*: A randomized phase 2 trial of pembrolizumab versus pembrolizumab and acalabrutinib in patients with platinum-resistant metastatic urothelial cancer. *Cancer* 126: 4485-4497, 2020.
- Kim KH, Cho J, Ku BM, Koh J, Sun JM, Lee SH, Ahn JS, Cheon J, Min YJ, Park SH, *et al*: The First-week proliferative response of peripheral blood PD-1+CD8+ T cells predicts the response to Anti-PD-1 therapy in solid tumors. *Clin Cancer Res* 25: 2144-2154, 2019.
- Taggart D, Andreou T, Scott KJ, Williams J, Rippaus N, Brownlie RJ, Ilett EJ, Salmond RJ, Melcher A and Loriger M: Anti-PD-1/anti-CTLA-4 efficacy in melanoma brain metastases depends on extracranial disease and augmentation of CD8+ T cell trafficking. *Proc Natl Acad Sci USA* 115: E1540-E1549, 2018.
- Eguren-Santamaria I, Sanmamed MF, Goldberg SB, Kluger HM, Idoate MA, Lu BY, Corral J, Schalper KA, Herbst RS and Gil-Bazo I: PD-1/PD-L1 Blockers in NSCLC brain metastases: Challenging paradigms and clinical practice. *Clin Cancer Res* 26: 4186-4197, 2020.
- Lesokhin AM, Ansell SM, Armand P, Scott EC, Halwani A, Gutierrez M, Millenson MM, Cohen AD, Schuster SJ, Lebovic D, *et al*: Nivolumab in patients with relapsed or refractory hematologic malignancy: Preliminary results of a phase Ib study. *J Clin Oncol* 34: 2698-2704, 2016.
- Ansell SM, Minnema MC, Johnson P, Timmerman JM, Armand P, Shipp MA, Rodig SJ, Ligon AH, Roemer MGM, Reddy N, *et al*: Nivolumab for relapsed/refractory diffuse large B-Cell lymphoma in patients ineligible for or having failed autologous transplantation: A single-arm, phase II study. *J Clin Oncol* 37: 481-489, 2019.
- Nayak L, Iwamoto FM, LaCasce A, Mukundan S, Roemer MGM, Chapuy B, Armand P, Rodig SJ and Shipp MA: PD-1 blockade with nivolumab in relapsed/refractory primary central nervous system and testicular lymphoma. *Blood* 129: 3071-3073, 2017.
- Hanna BS, Yazdanparast H, Demerdash Y, Roessner PM, Schulz R, Lichter P, Stilgenbauer S and Seiffert M: Combining ibrutinib and checkpoint blockade improves CD8+ T-cell function and control of chronic lymphocytic leukemia in Em-TCL1 mice. *Haematologica* 106: 968-977, 2021.
- Sagiv-Barfi I, Kohrt HE, Czerwinski DK, Ng PP, Chang BY and Levy R: Therapeutic antitumor immunity by checkpoint blockade is enhanced by ibrutinib, an inhibitor of both BTK and ITK. *Proc Natl Acad Sci USA* 112: E966-E972, 2015.
- Qorraj M, Bruns H, Böttcher M, Weigand L, Saul D, Mackensen A, Jitschin R and Mougiakakos D: The PD-1/PD-L1 axis contributes to immune metabolic dysfunctions of monocytes in chronic lymphocytic leukemia. *Leukemia* 31: 470-478, 2017.

29. Chang CH, Qiu J, O'Sullivan D, Buck MD, Noguchi T, Curtis JD, Chen Q, Gindin M, Gubin MM, van der Windt GJ, *et al*: Metabolic competition in the tumor microenvironment is a driver of cancer progression. *Cell* 162: 1229-1241, 2015.
30. Wu JJ, Wang WH, Dong M, Ma SS, Zhang XD, Zhu LN, Niu ST, Ding MJ, Zhang JM, Zhang L, *et al*: Orelabrutinib-bruton tyrosine kinase inhibitor-based regimens in the treatment of central nervous system lymphoma: A retrospective study. *Invest New Drugs* 40: 650-659, 2022.
31. Zhang Y, Wang W, Zhao DQ, Zhang W and Zhou DB: Preliminary results of a phase II study of orelabrutinib in combination with anti-PD-1 monoclonal antibody in refractory or relapsed primary CNS lymphoma. In: *Proceedings of the EHA2022*. EHA Library, S224, 2022.



This work is licensed under a Creative Commons Attribution-NonCommercial-NoDerivatives 4.0 International (CC BY-NC-ND 4.0) License.