



Since January 2020 Elsevier has created a COVID-19 resource centre with free information in English and Mandarin on the novel coronavirus COVID-19. The COVID-19 resource centre is hosted on Elsevier Connect, the company's public news and information website.

Elsevier hereby grants permission to make all its COVID-19-related research that is available on the COVID-19 resource centre - including this research content - immediately available in PubMed Central and other publicly funded repositories, such as the WHO COVID database with rights for unrestricted research re-use and analyses in any form or by any means with acknowledgement of the original source. These permissions are granted for free by Elsevier for as long as the COVID-19 resource centre remains active.

CHAPTER 17

GUINEA PIGS

COMMON SPECIES KEPT IN CAPTIVITY

Guinea pigs, *Cavia porcellus*, are members of the Caviidae family of the order Rodentia. Guinea pigs are native to mountainous regions of South America where they were domesticated as long as 3000 years ago. Wild species of guinea pigs, or *cavies*, still inhabit Columbia, Peru, Venezuela, Argentina, Brazil, and Paraguay. Domesticated cavies in these countries are used for food. In the wild, guinea pigs live in small groups and, therefore, are often more comfortable in the presence of other guinea pigs when maintained as companion animals.

Extensive breeding has resulted in numerous varieties of coat color and characteristics. The most common breeds are the American (or English) which has a short, smooth coat and the multicolored Teddy (Figure 17-1); Abyssinian (Figure 17-2), which has a medium length coat in a whorled pattern; and the Peruvian, which has a very long, smooth coat.

BIOLOGY

Guinea pigs have wide bodies with short limbs. A distinctive anatomic characteristic of species in the family Caviidae is the number of digits on the front and rear feet (4 digits front feet and 3 digits rear). Tails are usually very short or absent. The guinea pig has a short, flat nose, laterally placed eyes, and hairless external pinnae. Adult guinea pigs usually weigh between 700 and 1200 g, with the males being slightly larger than females. The average life span of the companion guinea pig is approximately 5 to 7 years.

The dentition of the guinea pig is described as aradicular hypsodont (e.g., all teeth have a relatively long crown and are “open rooted”).¹ The maxilla is slightly wider than the mandible,

and the occlusal angle of the premolars and molars is marked compared to other rodent species. The dental formula of the guinea pig is $2(I\ 1/1, C\ 0/0, PM\ 1/1, M\ 3/3) = 20$. The maxillary incisors are much shorter than those set in the mandible. The molars and premolars are not easily visualized without special instrumentation because of the small size of the oral cavity and tendency for the involution of the buccal surface.

Females are sexually mature at 6 weeks of age, whereas males on average reach puberty approximately 4 weeks later. Gestation is long, when compared to other rodents, at 68 days.² As a result of this long gestation period, young are precocial when born. Juvenile pigs usually eat solid foods by 4 or 5 days of age.³ Litter sizes range from 1 to 6, with an average of 3 to 4 young.² A female guinea pig should deliver her first young before she is 6 months of age. If birth has not occurred before 6 months of age, the pubic symphysis becomes mineralized, with future pregnancies resulting in an inability of the sow to naturally deliver the babies. Female guinea pigs that become pregnant after 6 months of age invariably require cesarean section deliveries.

HUSBANDRY

Housing

Guinea pigs are best housed in well-ventilated, wire-sided cages with solid bottoms. Wire-bottom cages may also be used; however, care must be taken to ensure that the mesh is small enough that a limb cannot become entrapped. An area of solid flooring should be provided, as uninterrupted time on wire mesh may predispose the guinea pig to pododermatitis. Adequate space is needed in the enclosure for the guinea pig to



Figure 17-1 Two common guinea pig breeds: Teddy (*left*) and American (*right*).

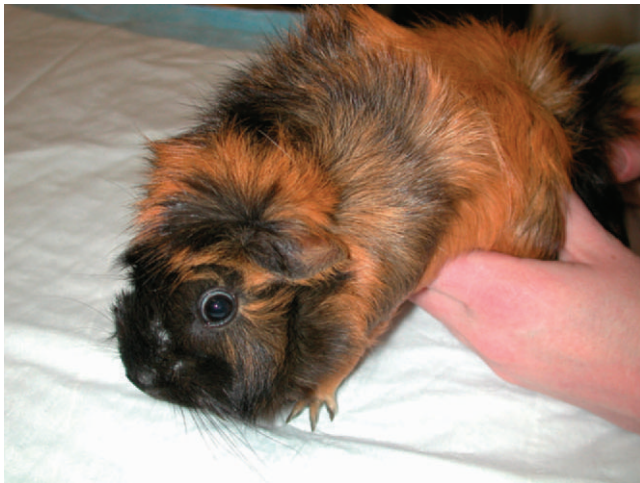

Figure 17-2 Abyssinian guinea pig.

move about unencumbered with enough space for a hide box. Hide boxes or a secluded space is required for prey species (e.g., rodents) to reduce stress that may lead to disease problems. Substrate products that contain aromatic oils (e.g., cedar and pine shavings) should not be used, as they can act as contact and respiratory irritants. Appropriate bedding materials include recycled newspaper products, shredded paper, and aspen shavings. The enclosure should be cleaned thoroughly on a regular basis (e.g., 2 times per week) because unsanitary conditions predispose the guinea pig to pododermatitis, respiratory, and other health problems. If housed indoors, guinea pig enclosures do not require a cover, as these animals do not typically jump or climb. However, the sides of the enclosure should be high enough to prevent escape (approximately 25 cm).² Heavy food containers are recommended to make dumping of the receptacle more difficult. All food containers should be easy to

disinfect and cleaned regularly, as guinea pigs have a habit of soiling their food bowls. Most guinea pigs readily accept drinking water from a sipper bottle, which will decrease spillage and will keep feces, urine, and bedding from contaminating the water.

These animals, native to the Andes Mountains, are very susceptible to hyperthermia and should never be housed in temperatures greater than 80° F. High humidity can also exacerbate a guinea pig's sensitivity to elevated temperatures by increasing the heat index. All animals are very sensitive to environmental and/or nutritional changes. Therefore, if changes have to be made, gradual exposure of the animal to the changes is recommended.

Diet

An appropriate guinea pig diet includes a formulated, pelleted diet for that species, high-quality hay (e.g., timothy, orchard grass, oat) ad libitum, and ample fresh vegetables. As the animal's food intake is more dependent on volume consumed rather than calories consumed, a pet fed a predominantly pelleted diet (higher nutritional concentration) has a tendency to become obese. Fruits and grains, if they are offered at all, should comprise a very small portion (<10%) of the total diet and offered only as treats.

Because guinea pigs lack the enzyme L-gulonolactone oxidase, they are unable to synthesize ascorbic acid from glucose. Therefore, guinea pigs require supplemental vitamin C in their diets. Although commercial guinea pig pellets are manufactured with vitamin C, the supplement often degrades rapidly, especially if the pellets are subjected to high heat and humidity. Vitamin C placed in drinking water also degrades rapidly and should be changed daily. To ensure that a guinea pig is receiving a proper amount of vitamin C, it is necessary to supplement a diet of pellets and hay with plenty of fresh foods or often a specifically manufactured vitamin C supplement tablet (Oxbow, Inc., Murdock, NE). Many green, leafy vegetables, such as kale, mustard greens, dandelion greens, parsley, and many others, are excellent sources of ascorbic acid (Box 17-1). The vitamin C requirement of an adult, nonbreeding guinea pig is 10 mg/kg/day.^{2,3}

PREVENTIVE MEDICINE

In the United States, guinea pigs are not routinely vaccinated for infectious diseases. However, owners should be encouraged to have annual examinations that include an oral examination and a complete blood count. Being prey species in the wild, guinea pigs are adept at hiding illness, and routine evaluations by a qualified veterinarian may help in detecting abnormalities early.

Many health problems of guinea pigs are related to improper husbandry. During a routine veterinary visit, the owners should be asked to provide a detailed description of the animal's housing environment, including substrate, frequency of cleaning, ambient temperature, and exercise time. The diet history is also important. Owners should be asked not only

BOX 17-1 Vitamin C Content of Selected Fruits and Vegetables

Vegetables	mg vitamin C/100 g
Red bell pepper	190
Parsley	133
Kale	120
Broccoli	93.2
Brussels sprouts	85
Mustard greens	70
Turnip greens	60
Cauliflower	46.4
Dandelion greens	35
Cilantro	27
Romaine lettuce	24
Sweet potato	22.7
Carrot	9.3

Fruits	mg vitamin C/100 g
Kiwi	98
Strawberry	56.7
Orange	53.2
Cantaloupe	42.2
Apple	5.7

what the guinea pig is offered, but also in what proportions and of what foods the animal actually eats.

RESTRAINT

Most guinea pigs are quite docile and do not require aggressive restraint. Often a hand on the animal's dorsum is adequate to restrain a guinea pig patient on the examination table (Figure 17-3). When transporting a guinea pig, support the body with one hand under the thorax and abdomen while placing the other hand on the back to prevent the patient from falling or jumping (Figure 17-4).

If chemical restraint is required, gas anesthesia with isoflurane or sevoflurane is generally well tolerated. Anesthetic gases can be delivered via mask or induction chamber. Mild sedation can be achieved with an intramuscular injection of a combination of midazolam (0.2-0.5 mg/kg) and butorphanol (0.2-0.5 mg/kg) intramuscularly.

PERFORMING A PHYSICAL EXAMINATION

Guinea pigs often do not exhibit clinical signs early in a disease process. Therefore, a thorough physical examination can be extremely useful in determining the overall health status of the animal. Before beginning a physical examination, it is important to observe the animal before it has been stressed by restraint. A healthy guinea pig should be alert and aware of its

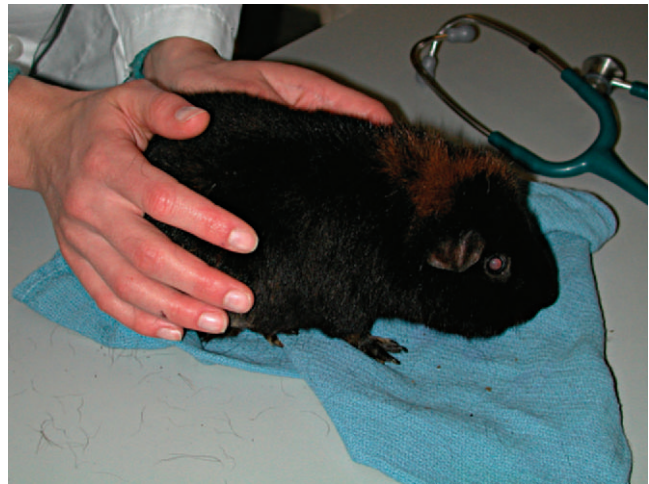

Figure 17-3 Restraint of a guinea pig patient for examination.

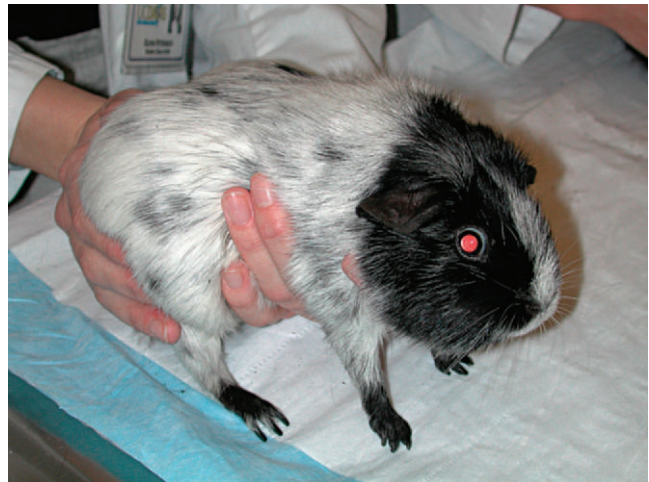

Figure 17-4 Restraint of a guinea pig patient for transport.

surroundings. As guinea pigs are often shy animals, they may attempt to hide or escape. The examiner should use a thorough, systematic approach to focus on the respiratory character and rate, posture, and attitude of the animal. It is also important to have any instruments (e.g., transilluminator, stethoscope, thermometer, blood-collecting supplies) that may be necessary to decrease the amount of handling time for the patient.

Obtaining an accurate body temperature, heart rate, and respiratory rate is best accomplished at the beginning of the examination, as these parameters will invariably change with handling. An accurate weight should be obtained using an electronic gram scale. A "hands-on" physical examination should begin with the head; the veterinarian should assess the eyes for symmetry or discharge and check that the external pinnae of the guinea pig are hairless, as normal. The external ear canals often contain a small to moderate amount of dark,

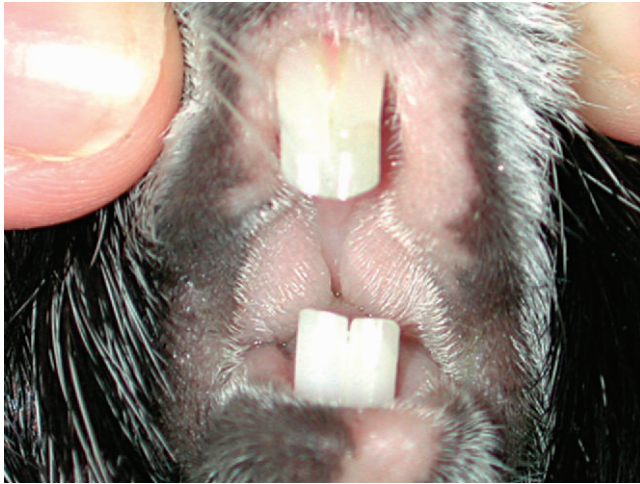

Figure 17-5 The oral cavity of a guinea pig. Note the abundance of soft tissue that obscures visualization of the molars and premolars.

ceruminous debris. The nasal planum should be dry and flat, whereas palpation of the ventral mandible may reveal deformities secondary to overgrowth of molar and premolar apices.

The guinea pig coat varies somewhat with breed but, in general, should be smooth and shiny. Guinea pigs often have a mild to moderate amount of dark sebaceous debris on the skin of the dorsum. Older male guinea pigs may develop a focal accumulation of this debris at the base of the vertebral column, which may be referred to as the “grease gland.”⁴

Thoracic auscultation and abdominal palpation can be performed as in other patients. Heart and respiratory rates will vary depending on the degree of stress a patient experiences. As pulse and respiratory rates can be very rapid, careful auscultation is necessary to detect subtle abnormalities (e.g., murmurs, crackles, wheezes). Auscultation of gut sounds is also an important part of the guinea pig physical exam. A healthy guinea pig should have 1 to 2 borborygmi per minute. The practitioner should keep in mind that stress will decrease gastrointestinal (GI) motility; therefore, a stressed animal will often have a decrease in borborygmi. Structures normally found on abdominal palpation include kidneys, urinary bladder, cecum, and intestines. Fecal pellets are often palpable in the colon. Careful examination may reveal the presence of abnormalities such as GI distention, masses, or, in females, ovarian cysts. Limbs and joints should be carefully evaluated because thickened or painful joints may be indicative of a vitamin C deficiency.

A complete oral examination is an important part of the guinea pig exam. Because of the potential stress associated with the oral exam, this evaluation should be reserved for the end. The oral cavity of the guinea pig is very narrow with a small opening, making visualization difficult (Figure 17-5). Instruments such as an otoscope with cone or a human nasal speculum will increase visualization of the caudal oral cavity (Figure 17-6). However, many dental lesions may be overlooked using these methods, and anesthesia is often required to adequately determine oral health.

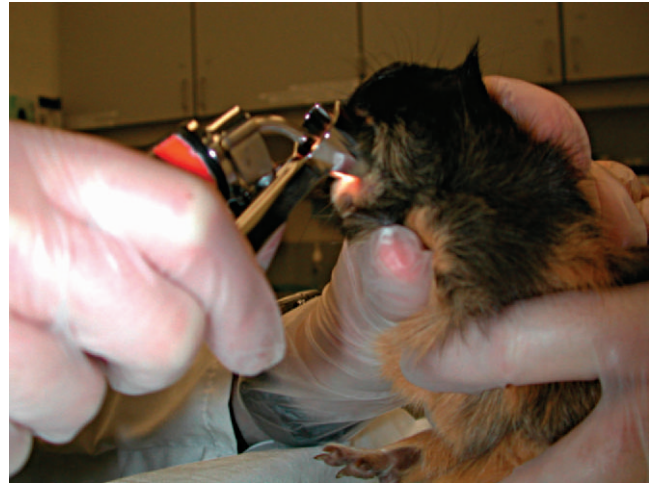

Figure 17-6 Oral examination of a conscious guinea pig using a human nasal speculum on a transilluminator base.

DIAGNOSTIC TESTING

Venipuncture

Obtaining blood samples from guinea pigs for routine diagnostics is a challenging procedure. Peripheral venipuncture sites available for most mammals (e.g., lateral saphenous vein and cephalic vein) are difficult to visualize in guinea pigs and only allow for the collection of small sample volumes. The jugular vein may be used; however, the short neck of the guinea pig and poor tolerance of the aggressive restraint by the patient restrict the availability of this site for blood collection. Often to obtain an adequate blood sample, it is necessary to anesthetize the patient. Once anesthetized, the large central vessels may be accessed with less stress on the patient and phlebotomist. Acceptable venipuncture sites while the patient is anesthetized include the cranial vena cava (Figure 17-7), femoral vein (Figure 17-8), and jugular vein.

Hematology

Baseline blood work is an important tool in the routine monitoring of health as well as in the diagnosis of disease. A complete blood count is essential for assessing red blood cell and white blood cell parameters (Box 17-2).

Guinea pigs have heterophils rather than neutrophils as the predominant circulating granulocyte. Heterophils lack myeloperoxidase, the enzyme that causes purulent, liquid exudates. Therefore, the debris contained in guinea pig abscesses is often found to be very thick and caseous, a fact that must be understood when treating these conditions. A normal guinea pig white blood cell differential will consist of primarily heterophils and lymphocytes, usually with a greater proportion of lymphocytes. The remaining leukocyte types (e.g., monocytes, eosinophils, basophils) are normally present in very low numbers. Early stages of a guinea pig's inflammatory response are often characterized by a shift in the differential white cell ratio (e.g., increased heterophils, decreased lymphocytes) rather

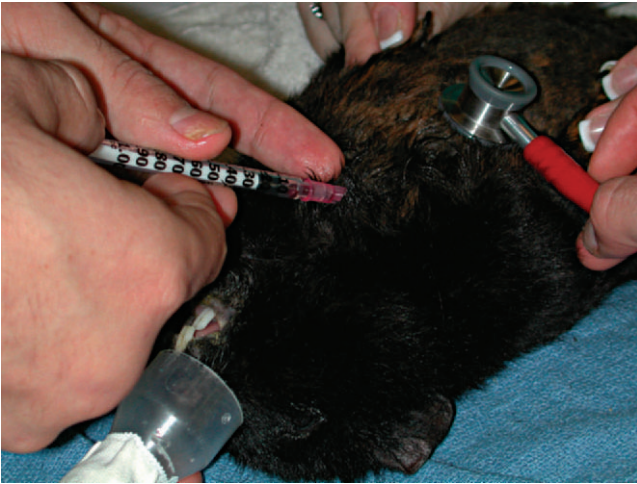

Figure 17-7 Blood collection via the cranial vena cava in an anesthetized guinea pig.

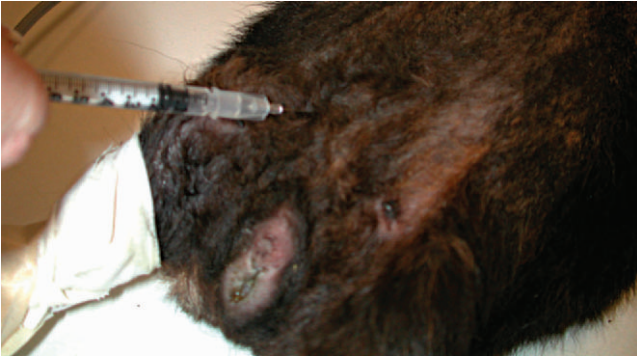

Figure 17-8 Blood collection via the femoral vein in an anesthetized guinea pig.

than an increase in total leukocyte count. This ratio shift makes evaluating the entire leukogram essential for health evaluation (Box 17-3). The platelet count is also an important marker of inflammation in guinea pigs and other small mammal species. Large increases in the platelet count ($>1,000,000/\mu\text{l}$) can be seen without an increase in the total white blood cell count.

A cell type that is unique to guinea pigs is the Kurloff cell. These large lymphocytes contain a cytoplasmic inclusion (e.g., a Kurloff body). Kurloff cells are noted most often in the peripheral blood of reproductive age females, although they are also identified in male guinea pigs. The number of circulating Kurloff cells will increase in response to exogenous estradiol and testosterone administration, although the effects were more dramatic with estradiol administration.^{7,8} Other studies have shown the disappearance of Kurloff cells in spayed female and castrated male guinea pigs.⁸ The function of the Kurloff cell is not completely understood, and these cells appear to lack lysosomes. At this time, there is no evidence that the Kurloff cell has phagocytic activity.⁸ The activity of Kurloff cells appears to most closely correlate with that of natural killer cells found in other species.⁷

BOX 17-2 Hematologic Parameters for Guinea Pigs

Hematologic Parameter	Reference Interval
PCV (%)	30-50
RBC ($\times 10^6$ cells/ μl)	4-11
Hb (g/dl)	11-17
MCV (fl)	70-95
MCHC (%)	25-40
MCH (pg)	23-27
WBC ($\times 10^3$ cells/ μl)	6-17
Heterophils (%)	20-60
Lymphocytes (%)	30-80
Monocytes (%)	1-10
Eosinophils (%)	0-7
Basophils (%)	0-3
Platelets ($\times 10^3$ cells/ μl)	300-600

Data from Quesenberry KE, Donnelly TM, Hillyer EV: Biology, husbandry, and clinical techniques. In Quesenberry KE, Carpenter JW, editors: *Ferrets, Rabbits, and Rodents: Clinical Medicine and Surgery*, ed 2, St Louis, 2003, WB Saunders; Carpenter JW: Hematologic and serum biochemical values of rodents. In Carpenter JW, editor: *Exotic Animal Formulary*, ed 3, St Louis, 2005, WB Saunders; Campbell TW: Mammalian hematology: laboratory animals and miscellaneous species. In Thrall MA, editor: *Veterinary Hematology and Clinical Chemistry*, Baltimore, 2004, Lippincott Williams and Wilkins.

Hb, hemoglobin; MCH, mean corpuscular hemoglobin; MCHV, mean corpuscular hemoglobin concentration; MCV, mean corpuscular volume; PCV, packed cell volume; RBC, red blood cell count; WBC, white blood cell count.

BOX 17-3 Example of an Inflammatory Leukogram in a Guinea Pig

Hematologic Parameter	Value
HCT (%)	43
WBC ($\times 10^3$ cells/ μl)	13.1
Heterophils ($\times 10^3$ cells/ $\mu\text{l}/\%$)	7.8/59.3
Lymphocytes ($\times 10^3$ cells/ $\mu\text{l}/\%$)	3.4/25.9
Monocytes ($\times 10^3$ cells/ $\mu\text{l}/\%$)	1.2/8.8
Eosinophils ($\times 10^3$ cells/ $\mu\text{l}/\%$)	0.7/5.4
Basophils ($\times 10^3$ cells/ $\mu\text{l}/\%$)	0.09/0.7
Platelets ($\times 10^3$ cells/ μl)	694

Clinical Chemistries

Plasma biochemical analysis is necessary for evaluation of organ function as well as plasma glucose and proteins. It is important to interpret the results of a chemistry panel in conjunction with history, physical exam findings, and the results of other diagnostic tests. Reference intervals for biochemical parameters are shown in Box 17-4.

Urinalysis

Urinalysis is a useful diagnostic test in guinea pigs with signs of upper or lower urinary tract disease. Urine samples may be

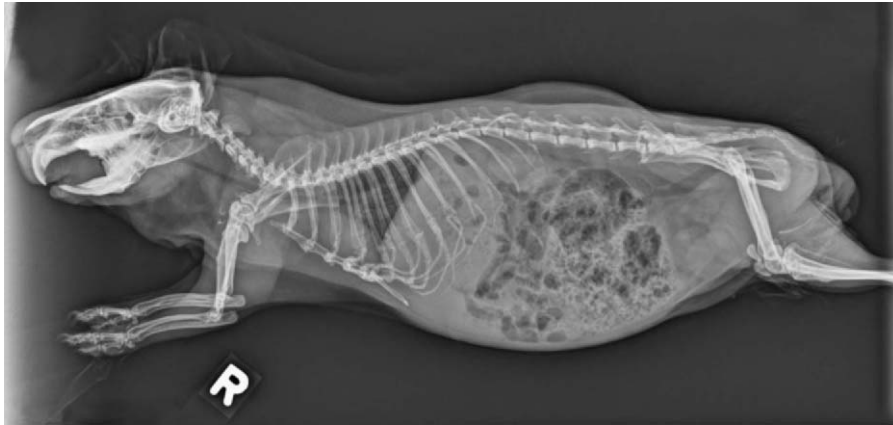


Figure 17-9 Right lateral radiograph of a guinea pig. Note the moderate overgrowth of the apices of the mandibular molars and premolars, remodeling of ribs, and large amount of ingesta within the GI tract. (Courtesy University of California–Davis.)

BOX 17-4 Plasma Biochemical Parameters for Guinea Pigs

Biochemical Parameter	Reference Interval
Sodium (mEq/L)	120-150
Potassium (mEq/L)	4-8
Chloride (mEq/L)	90-115
Glucose (mg/dl)	60-125
Blood urea nitrogen (mg/dl)	9-32
Creatinine (mg/dl)	0.6-2.2
Calcium (mg/dl)	8-12
Phosphorous (mg/dl)	3-8
Total protein (g/dl)	4-7
Albumin (g/dl)	2-5
Globulin (g/dl)	2-4
Creatine kinase (IU/L)	0-300
Aspartate transferase (IU/L)	30-70
Alkaline phosphatase (IU/L)	60-110
Bilirubin (mg/dl)	0-1
Cholesterol (mg/dl)	20-50

Data from Quesenberry KE, Donnelly TM, Hillyer EV: Biology, husbandry, and clinical techniques. In Quesenberry KE, Carpenter JW, editors: *Ferrets, Rabbits, and Rodents: Clinical Medicine and Surgery*, ed 2, St Louis, 2003, WB Saunders; Carpenter JW: Hematologic and serum biochemical values of rodents. In Carpenter JW, editor: *Exotic Animal Formulary*, ed 3, St Louis, 2005, WB Saunders; Campbell TW: Mammalian hematology: laboratory animals and miscellaneous species. In Thrall MA, editor: *Veterinary Hematology and Clinical Chemistry*, Baltimore, 2004, Lippincott Williams and Wilkins.

obtained by free catch, floor catch, or cystocentesis. If urine is to be cultured, it is ideal to use the cystocentesis method of collection. Ultrasound guidance and/or mild sedation of the patient will aid the veterinarian and/or veterinary technician in obtaining the urine sample.

The urine of guinea pigs is typically yellow to amber in color, but it may be darker and more orange depending on the patient's diet. Pigments in the urine can sometimes be mistaken for hematuria, so differentiation is important. Because guinea pigs are herbivores, the pH of guinea pig urine is alkaline, usually 8.0 to 9.0. Crystalluria may be seen but is not a normal finding. If crystals are found in a urine sample, the guinea pig patient should be examined for urinary calculi.

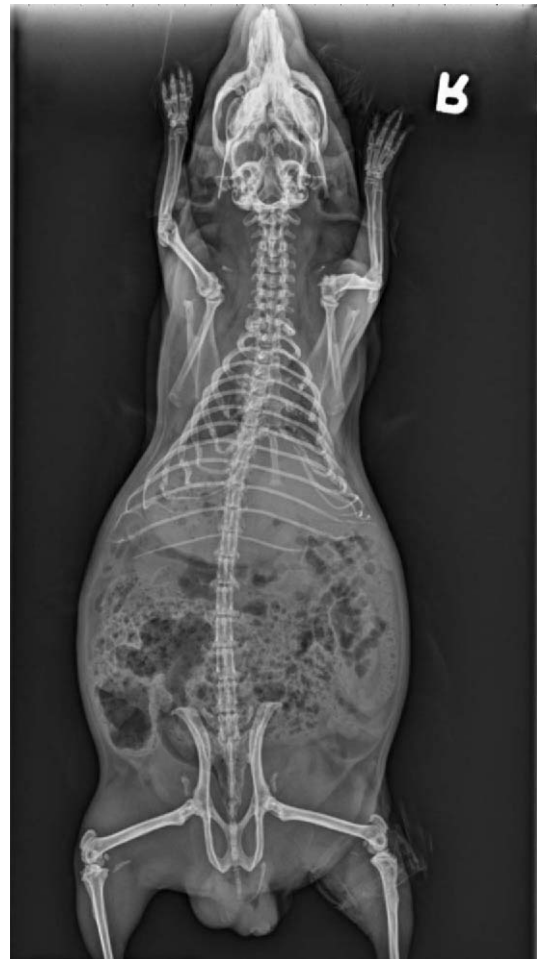

Figure 17-10 Ventrodorsal radiograph of the same guinea pig pictured in Figure 17-9. (Courtesy University of California–Davis.)

Imaging

Whole body radiographs may provide a large amount of information for the veterinarian treating an ill patient. Both lateral and ventrodorsal (or dorsoventral) views should be obtained (Figures 17-9 and 17-10). To minimize rotation, care should




Figure 17-11 Positioning of an anesthetized guinea pig patient for a right lateral radiograph.

TABLE 17-1 Guidelines for Radiographic Techniques for Selected Radiographic Studies in Guinea Pigs

Anatomic location	mA	kVp
Whole body	5.0	44
Extremities	7.5	54
Skull	6.0	48-53

From Silverman S, Tell LA: Radiology equipment and positioning techniques. In Silverman S, Tell LA, editors: *Radiology of Rodents, Rabbits, and Ferrets: An Atlas of Normal Anatomy and Positioning*, St Louis, 2006, WB Saunders. kVp, kilovolt peak; mA, milliamperere.

be taken to extend the limbs symmetrically when positioning the patient. Because guinea pigs have stocky builds with short limbs, and because they resent aggressive restraint, sedation or anesthesia is helpful in obtaining diagnostic radiographs as well as in reducing the patient's stress (Figure 17-11). Table 17-1 is a guideline for radiographic techniques used in common small mammal radiographic studies.

Dental malocclusion is a common disease problem in guinea pigs. Radiographs of the skull are helpful in assessing the degree of malocclusion as well as potential bone involvement. In addition to lateral and dorsoventral views of the skull, right and lateral oblique views can help to localize lesions. Magnified views of the skull can be obtained by placing the patient on an elevated platform under the x-ray beam without changing the distance between the x-ray cassette and beam.

Ultrasound is another imaging modality that is very useful in the diagnosis of common guinea pig disease processes, such as ovarian cysts (Figure 17-12) and urinary tract calculi. As with radiographs, sedation or anesthesia can assist in reducing patient stress and improve the quality of images. Guinea pigs

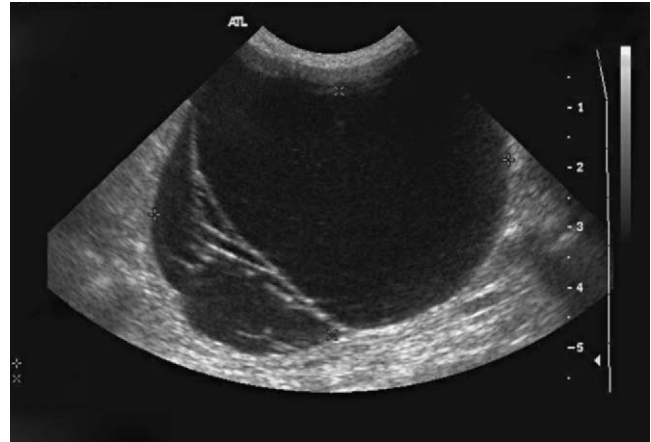


Figure 17-12 Ultrasound image of a large ovarian cyst in a mature female guinea pig. (Courtesy University of California–Davis.)

often have a large amount of gas accumulation in the GI tract, which obscures the ultrasound image, sometimes making this imaging technique of limited value.

Advanced imaging techniques, such as computed tomography (CT) and magnetic resonance imaging (MRI), are useful tools in the diagnosis of disease in guinea pig patients. Limitations of these modalities include limited availability, expense, and decreased image quality compared with that of larger patients. MRI has the added limitation of requiring a significant amount of time (often >45 min) under anesthesia with limited monitoring ability.

Regardless of the present limitations, veterinarians should be aware that these techniques are available and that reference material exists that depicts normal anatomy.⁹ As guinea pig owners continue to demand high-quality care for their pets, these imaging techniques will likely become more commonplace in small mammal practice for these patients.

Microbiology

Microbiologic samples can be obtained for diagnosis of various guinea pig infections. Exudates from nasal or ocular secretions can be examined for abnormal flora. Some bacterial organisms (e.g., *Bordetella bronchiseptica*) are difficult to culture. Laboratories need to be advised as to the organisms in question so they can perform more specific diagnostic tests to obtain organism identification.

Abscesses are another disease condition that may require culture for proper treatment. Because guinea pigs form caseous abscesses, the purulent debris itself is typically not useful for bacterial isolation. For the best chance of identifying organisms within an abscess, a portion of the abscess capsule should be submitted to the laboratory. Both aerobic and anaerobic bacterial cultures should be requested, especially if it is suspected that the abscess may have originated from a dental problem.

Parasitology

Roundworms and coccidia are seen in guinea pigs and can be identified by fecal flotation or fecal direct smear, as in other species. Cryptosporidiosis has also been reported.¹⁰ Identification of *Cryptosporidium* organisms usually requires acid-fast staining or immunofluorescent antibody testing in addition to fecal flotation.

Ectoparasites (e.g., mites, lice, fleas) commonly infest guinea pigs. Visualization of the parasites and/or their waste, as well as skin scrapings, microscopic examination of hair follicles, and tape preparations can be useful in the identification of these parasites.

COMMON DISEASE PRESENTATIONS

Gastrointestinal

ENTEROTOXEMIA

The term *enterotoxemia* refers to the overgrowth of toxin-producing bacteria in the GI tract, particularly *Clostridium difficile*. This can occur with stress, an abrupt change in diet, GI stasis, or inappropriate antibiotic administration. The GI flora of guinea pigs is predominantly Gram positive, and administration of antibiotics with a primarily Gram-positive spectrum (e.g., beta-lactam antibiotics, macrolides, lincosamides) can lead to the depletion of normal gut flora, allowing colonization by opportunistic bacteria (e.g., Gram-negative organisms, *Clostridium* spp.).

DENTAL DISEASE

The dentition of the guinea pig is described as *aradicular hypsodont*, meaning all teeth grow throughout the animal's life and are open-rooted.¹ The dental formula of the guinea pig is I 1/1, C 0/0, P 1/1, M 3/3. The mandible of these animals is wider than the maxilla. The occlusal angle of the molars and premolars in the guinea pig is quite severe when compared with that of rabbits and other rodents (Figure 17-13). Guinea pigs lack the layer of yellow enamel present on the rostral surface of the incisors in most other rodents.

Dental malocclusion is a common disease process in guinea pigs. The development of malocclusion can be the result of multiple etiologies or a combination of factors (e.g., improper diet, genetics, trauma). Incisor malocclusion alone is rare in guinea pigs, so a thorough oral examination is necessary to determine the presence of cheek teeth malocclusion. When the molars and premolars do not occlude properly, overgrowth of the crowns and reserve crowns takes place. With improper wear, sharp points can form on the buccal aspects of the maxillary cheek teeth and the lingual aspects of the mandibular cheek teeth. The mandibular cheek teeth can overgrow to such an extent that they entrap the tongue, making eating and drinking difficult (Figure 17-14).

Clinical signs can include inappetence or dysphagia, decreased fecal output, ptyalism, poor coat quality, and leth-

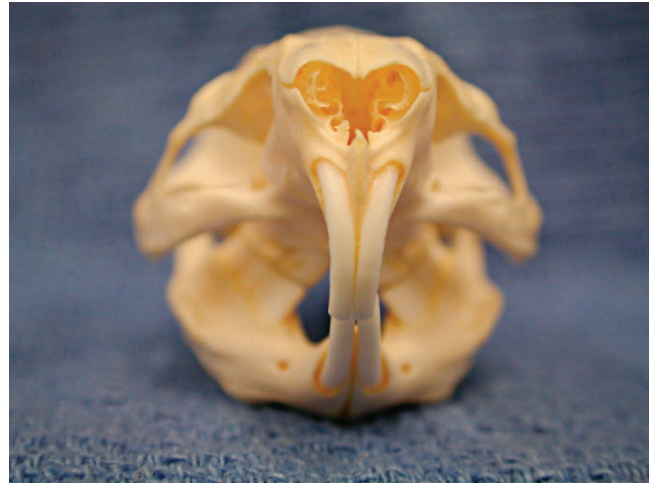

Figure 17-13 Cranial-caudal view of a guinea pig skull. Note the lack of yellow enamel on the cranial surface of the incisors and the severe occlusal angle of the premolars and molars.

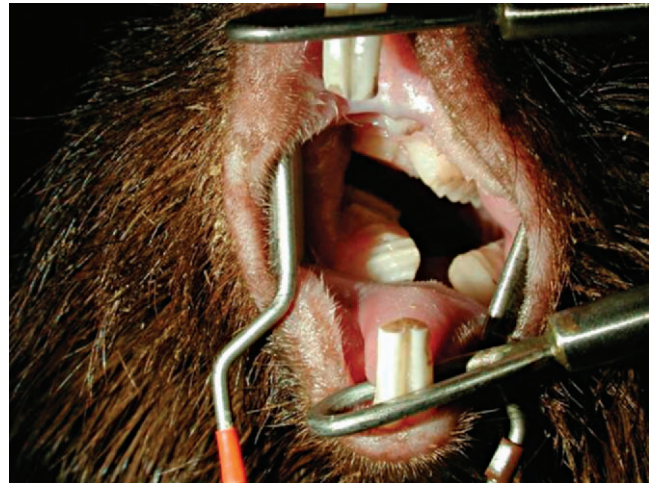


Figure 17-14 Guinea pig with malocclusion. Note the severe overgrowth of the mandibular premolars and molars, causing entrapment of the tongue. (Courtesy Michelle G. Hawkins, VMD, DABVP [Avian].)

argy. Abscesses commonly occur at the apical aspects of overgrown molars and premolars. Because the premolars and molars are elodont (open-rooted), it is possible that these teeth can overgrow and impinge on the nasolacrimal duct, causing ocular and nasal discharge. The reserve crowns can also overgrow into the nasal cavity, where oral bacteria may be seeded, causing rhinitis and sinusitis.

Diagnosis of dental disease is based on physical and oral examination findings. Careful palpation of the ventral mandible and maxilla may reveal bony protuberances corresponding to overgrowth of the apical surfaces of the cheek teeth. Proper instrumentation is very important for adequate visualization of the oral cavity. Dental speculums and pouch dilators are invaluable aids in obtaining a good view of the molars and premolars (Figure 17-15). However, many abnormalities can

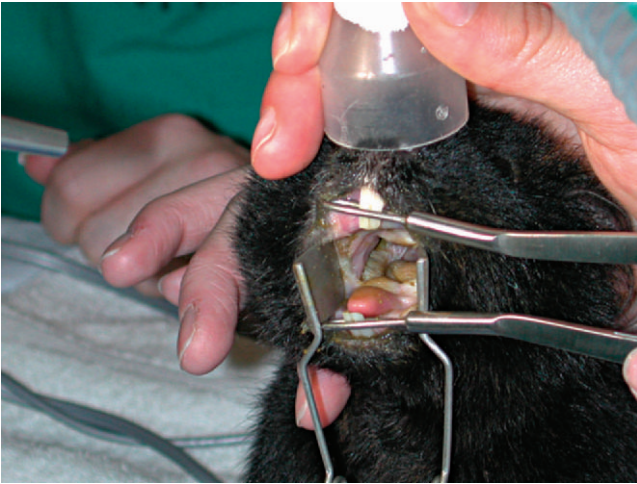


Figure 17-15 Oral examination of an anesthetized guinea pig aided by the use of incisor dilators and pouch dilators.



Figure 17-16 Examination of the oral cavity of an anesthetized guinea pig using a rigid endoscope.

be overlooked in a conscious animal, so anesthesia is often required to obtain a thorough oral examination. Visualization of the oral cavity and occlusal surfaces can be facilitated by the use of an endoscope (Figure 17-16). Most endoscopes available in veterinary practice have a degree of angulation of the field of view, allowing greater focal area. Abnormal oral examination findings may include an uneven occlusal surface or angle of the cheek teeth, formation of sharp points with or without associated ulceration of the oral mucosa, food impaction, and abnormal spaces (diastema) between teeth. Imaging, including routine radiographs, magnified skull radiographs, and computed tomography can be incorporated to better evaluate the extent and seriousness of the process (Figure 17-17). Radiographic studies should include dorsoventral, lateral, and right and left oblique views.

Treatment is centered on restoring a normal occlusal plane to the teeth, a procedure that should be performed while the

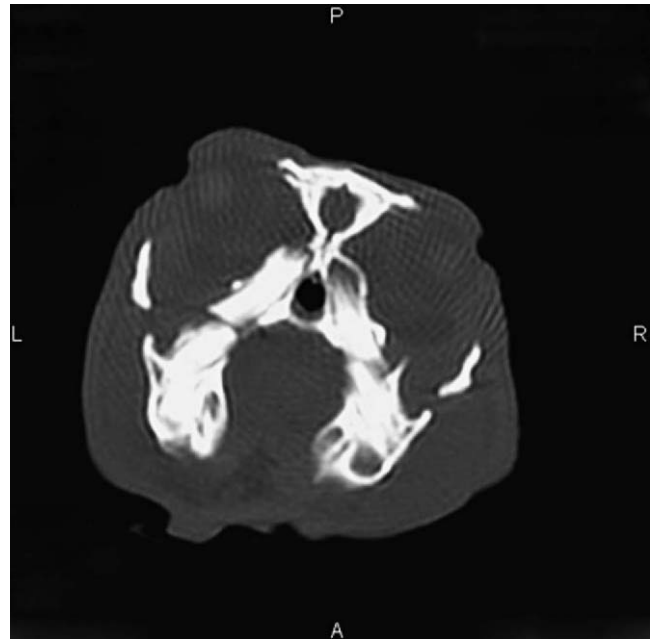


Figure 17-17 Computed tomography image of a guinea pig with mild to moderate malocclusion of the premolars and molars. (Courtesy University of California–Davis.)

animal is under general anesthesia. Unstable animals should be provided with supportive care before the anesthetic event. A high-speed surgical dental handpiece can be used to restore a normal occlusal plane and to reduce any sharp points. Hand-held trimmers are not acceptable, as they tend to crush teeth and can cause fractures and pulp exposure.¹ Dremel tools are also not considered acceptable because the small size of the guinea pig oral cavity will not allow for appropriate trimming. With any dental instruments, care should be observed to minimize oral soft tissue trauma.

When a guinea pig is diagnosed with dental malocclusion, it is important to convey to the owners that this will be a life-long problem for their pets. With many cases, routine occlusal adjustments will be necessary for the remainder of the animal's life.

TYZZER'S DISEASE (*C. PILIFORME*)

Tyzzler's disease is the common term for bacterial enteritis caused by *Clostridium piliforme*. Infection with this organism is more commonly described in small rodents such as mice and hamsters, although it has also been described in guinea pigs as well as other mammalian groups.¹¹ Tyzzler's disease often presents acutely, with signs such as diarrhea, depression, and poor coat quality, often progressing rapidly to death. Transmission is via the fecal-oral route. Guinea pigs can be infected with *C. piliforme* without showing clinical signs. Animals that are carrying the organism but showing no signs of illness have still been found to shed organisms.¹² Animals that carry the organism and then become immunocompromised (e.g., stress, immunosuppressive drug therapy) often develop clinical disease.

Clostridium piliforme is an intracellular bacterium that will not grow on routine culture media, so antemortem

diagnosis is difficult. Tyzzer's disease begins as an intestinal infection, but later spreads to the liver hematogenously, causing areas of necrosis.^{11,15} Positive identification of the organism on necropsy requires examination of hematoxylin and eosin or silver staining of affected tissues.

Treatment should consist of fluid and nutritional support as well as appropriate antibiotic therapy. Unfortunately, the progression of the disease is rapid, making treatment unrewarding. Prevention is key, focusing on owners' reducing housing stress, providing a proper diet, and maintaining a clean environment.

CRYPTOSPORIDIOSIS

Cryptosporidiosis has been described as causing disease in guinea pigs in a laboratory setting.¹⁰ Diagnosis was made histologically from affected animals that lost weight, had diarrhea, and suffered an acute death. *Cryptosporidium* organisms were found in the brush border of the intestinal tract from the duodenum to cecum, with associated inflammation.¹⁰

CORONAVIRUS

Suspected coronavirus infection has been described in young guinea pigs.¹⁴ Clinical signs in affected animals included anorexia, weight loss, and diarrhea.¹⁴ Approximately half of the affected animals in the reported outbreak recovered.¹⁴ Necropsies performed on animals that died or were euthanized showed lesions consistent with coronavirus infection resulting from an acute to subacute necrotizing enteritis involving primarily the distal ileum.¹⁴ Coronavirus-like virions were identified on transmission electron microscopy of feces collected from the lower GI tract at necropsy.¹⁴

SALMONELLOSIS

Outbreaks of salmonellosis have occurred in guinea pig colonies. Some of the organisms that have been isolated include *S. enteritidis*, *S. dublin*, *S. florida*, *S. poona*, and *S. bredeney*.^{15,16} Salmonellosis has been described to affect guinea pigs in acute and chronic disease processes. With acute salmonellosis, guinea pigs often die after a brief illness characterized by nonspecific signs of illness and diarrhea.¹⁵ Usually only a few pathogenic abnormalities are found at necropsy, and confirmation of a diagnosis is dependent on culture of affected tissues.

Chronic salmonellosis is a wasting disease, lasting several weeks. Splenomegaly, hepatomegaly, and mesenteric lymphadenopathy are common postmortem findings in affected animals.¹⁵ Guinea pigs that recover can remain chronic, intermittent shedders of *Salmonella* organisms.

YERSINIA PSEUDOTUBERCULOSIS

Yersinia pseudotuberculosis causes several disease syndromes in guinea pigs.^{15,17} The most common presentation affects the mesenteric and colonic lymph nodes, infiltrating these lymph nodes with caseous nodules. Clinically, affected guinea pigs will lose weight, have diarrhea, and develop a generalized lymphadenopathy. Transmission of the disease can be either vertical or horizontal.

Musculoskeletal HYPOVITAMINOSIS C

As stated previously, guinea pigs require dietary supplementation of ascorbic acid because they lack the enzyme L-gulonolactone oxidase necessary for synthesis of this compound. Although diets formulated for guinea pigs are supplemented with ascorbic acid, it is important to remember that it breaks down very rapidly, usually within the first 90 days after production. If a guinea pig is not receiving vitamin C supplementation in its diet, the veterinarian can assume that the diet is deficient in this important nutrient.

Ascorbic acid is a necessary component of collagen, and deficiencies are often noted as manifestations of abnormal collagen synthesis.¹³ Clinical signs of hypovitaminosis C can include lameness, hemorrhage, lethargy, anorexia, poor coat quality, and bruxism.

Diagnosis of hypovitaminosis C is based largely on clinical signs and history. Radiographs will reveal changes to the costochondral junctions and widening of the epiphyses of long bones. Recommended treatment includes fluids and nutritional support, pain control, and parenteral vitamin C supplementation. Attention should also be paid to improvement of the guinea pig's diet at home.

In addition to causing skeletal and cartilage abnormalities, vitamin C deficiency has been known to reduce immune function. In vitro, vitamin C deficiency was demonstrated to cause a reduction in migration of macrophages in guinea pigs.¹⁸

Urogenital DYSTOCIA

Dystocia most frequently occurs in primiparous sows that are bred after approximately 6 months of age. At this time, the symphysis between the pubic bones becomes fused and will not expand to allow the passage of fetuses. Cesarean section must be performed in these cases to save the sow and the young. Factors other than age that can predispose a sow to dystocia include large fetuses in relation to sow size, uterine inertia, and obesity.¹³

URINARY CALCULI

Urolithiasis occurs commonly in pet guinea pigs, and the common clinical signs associated with the disease include stranguria and pollakiuria, vocalizing when urinating, and hematuria. The underlying cause(s) of this condition is not completely understood but is likely associated with a genetic predisposition and/or the presence of a high-calcium diet. Other less common underlying etiologies associated with urinary calculi formation include ureteral neoplasms (e.g., papilloma).¹⁹ Calculi are primarily composed of calcium carbonate, although magnesium ammonium phosphate hexahydrate and calcium phosphate calculi will also occur.²⁰ Radiographic or ultrasonic imaging can be used to confirm the location of the urinary calculi, which may be present in the renal pelvis, ureters, urinary bladder, or urethra (Figure 17-18). Urinary tract calculi often require surgical removal. Ideally, once

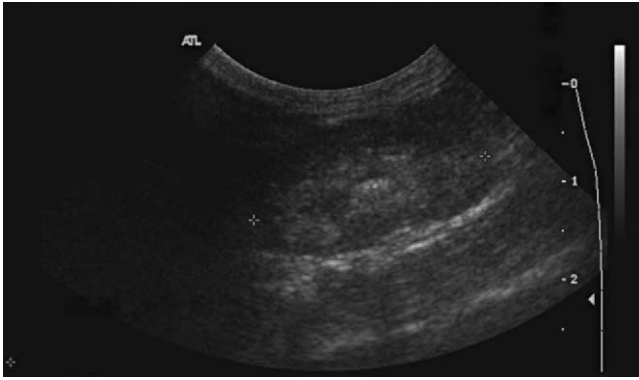


Figure 17-18 Ultrasound image of a calculus in the right renal pelvis of a guinea pig. (Courtesy University of California–Davis.)

removed, the calculus and/or a portion of the bladder wall should be cultured. It may also be helpful to analyze the composition of the stone to help determine ways of preventing recurrence.

OVARIAN CYSTS

Ovarian cysts are a common finding in middle-aged to older female guinea pigs. This disorder has a reported prevalence of 76% in female guinea pigs aged 1.5 to 5 years.^{13,21} Multiple cysts can be present on one or both ovaries. Clinical signs related to cystic ovaries can include abdominal distention, lethargy, and anorexia related to the space-occupying nature of the cysts. Ovarian cysts that are actively producing hormones can produce bilaterally symmetrical alopecia of the flanks.

Ovarian cysts can be quite large (up to several centimeters) and can often be identified on physical examination. Abdominal ultrasound is the most useful diagnostic tool for a definitive diagnosis. The most definitive treatment for cystic ovaries is ovariectomy or ovariectomy, curing the current problem and preventing recurrence. In animals where surgery is not a viable option, ultrasound-guided percutaneous aspiration of ovarian cysts can be performed as a palliative treatment. However, without removal of the ovaries, the cysts will recur, requiring repeated procedures.

PREGNANCY TOXEMIA

Pregnancy toxemia typically occurs in pregnant sows during the last 2 weeks of gestation. As with other species, pregnancy toxemia is the result of a negative energy balance and the metabolism of fat. Sows that experience pregnancy toxemia are typically overweight and become anorexic. Clinical signs include lethargy, dyspnea, and anorexia, usually progressing to death within a few days.¹³ Therapy of affected sows should center on providing nutritional support, correcting electrolyte imbalances, and preventing opportunistic infections. Prognosis is generally considered poor, as many sows fail to respond to treatment.

REPRODUCTIVE NEOPLASMS

Neoplasia of the reproductive tract is not commonly reported in guinea pigs, but several tumor types have been described. Of the described reproductive neoplasms, the vast majority occur in female guinea pigs. Uterine leiomyoma (often associated with ovarian cysts)²² and leiomyosarcoma, ovarian teratoma, and granulosa cell tumor are reported neoplasms of the reproductive tract.²¹ Diagnosis, as in any other patient, should be based on the results of cytologic or histopathologic sampling. Benign neoplasms may be resolved with ovariohysterectomy, but further diagnostics to determine the extent of local invasion should be performed before surgery takes place. A thorough diagnostic work-up, including imaging techniques (e.g., abdominal ultrasound, thoracic radiographs), should be performed to look for metastases of malignant tumor types.

MYCOPLASMA CAVIAE

Mycoplasma caviae has been isolated from the reproductive tracts of guinea pigs.¹⁵ These guinea pigs are often unaffected by the organism, but metritis has been suspected to be associated with infection. As with other species, *Mycoplasma* spp. is suspected to cause reproductive problems (e.g., abortion and decreased fertility).

Respiratory PNEUMONIA

Respiratory disease is a common presenting complaint in guinea pig patients. Clinical signs can vary from sneezing and upper respiratory signs to severe dyspnea and death.

Bordetella bronchiseptica is one of the most common respiratory bacterial agents associated with pneumonia in guinea pigs.¹⁵ Many guinea pigs are carriers of the organism, which will cause clinical disease if the animal is stressed. A thorough history, obtained from the patient's owner, often reveals interactions with other species that are also subclinical carriers of *B. bronchiseptica* (e.g., rabbits, dogs).¹³ Clinical signs noted in guinea pigs infected by the *Bordetella* organism include nasal discharge, dehydration, tachypnea, and lethargy.²³ Diagnosis should be based on clinical and radiographic signs and history. Confirmation of the diagnosis can be determined with enzyme-linked immunosorbent assay (ELISA) and indirect immunofluorescence diagnostic tests, or culture of exudates.²⁴ Treatment/preventive options for *B. bronchiseptica* infections in guinea pigs include an autogenous bacterin vaccine as well as three commercially available vaccines for *Bordetella* spp. (porcine *B. bronchiseptica* and human *B. pertussis*), which were found to offer some protection against the development of bronchopneumonia in experimentally infected guinea pigs.²⁵

STREPTOCOCCUS PNEUMONIAE

Streptococcus pneumoniae can cause pleuropneumonia, pleuritis, and peritonitis in guinea pigs.²⁶ Serologic detection of *S. pneumoniae* antibodies using ELISA have been described in

previously published papers.²⁶ On postmortem examination, lesions found to be associated with *S. pneumoniae* infection included pleuritis, pleural effusion, lung abscessation, otitis media, pericarditis, and others.²⁰

Streptococcus pneumoniae was also identified from septic arthritis lesions in a group of guinea pigs.²⁶ Five guinea pigs in a laboratory colony demonstrated multiple enlarged joints from which pure cultures of *S. pneumoniae* were isolated. Several other individuals in this colony had previously died with typical *S. pneumoniae* lesions (e.g., pleuritis, pericarditis) and lesions consistent with hypovitaminosis C. The group with septic arthritis also had scorbutic changes on necropsy.²⁶

STREPTOBACILLUS MONILIFORMIS

Streptobacillus moniliformis, the causative agent of rat-bite fever in humans, was isolated from a laboratory guinea pig with pneumonia. This organism is of particular importance because of its zoonotic potential.²⁷

ADENOVIRUS

Adenovirus has been shown to cause necrotizing bronchopneumonia in guinea pig populations, although it can also produce a transient, subclinical infection.^{28,29} Clinical signs include depression and dyspnea, but guinea pigs often die acutely without clinical signs.³⁰ Identification of adenovirus DNA from diseased lung tissue was achieved using a polymerase chain reaction technique in one study.²⁸ Development of this PCR assay for identification of the virus has determined that the guinea pig adenovirus is distinct.²⁸ Histopathologic examination of affected tissues of animals infected with adenovirus will reveal the presence of characteristic intranuclear inclusion bodies.²⁹

BRONCHOGENIC PAPILLARY ADENOMA

The most commonly reported neoplasm of the respiratory tract in guinea pigs is bronchogenic papillary adenoma. The prevalence of the tumor is as high as 30% in guinea pigs over the age of 3 years.¹³ Given the relatively more common occurrence of pneumonia in guinea pigs, bronchogenic papillary adenoma can often be misdiagnosed. For this reason, thoracic radiographs of guinea pigs with respiratory disease are highly recommended.

YERSINIA PSEUDOTUBERCULOSIS

Yersinia pseudotuberculosis can cause septicemic pneumonia in guinea pigs.¹⁵ Death usually occurs rapidly, after the development of coughing and dyspnea. At necropsy, severe congestion of the lungs is found grossly and through histologic evaluation of the tissues.

Integument ECTOPARASITES

Trixacarus caviae are sarcoptoid mites that commonly affect guinea pigs (Figure 17-19). Affected guinea pigs are intensely

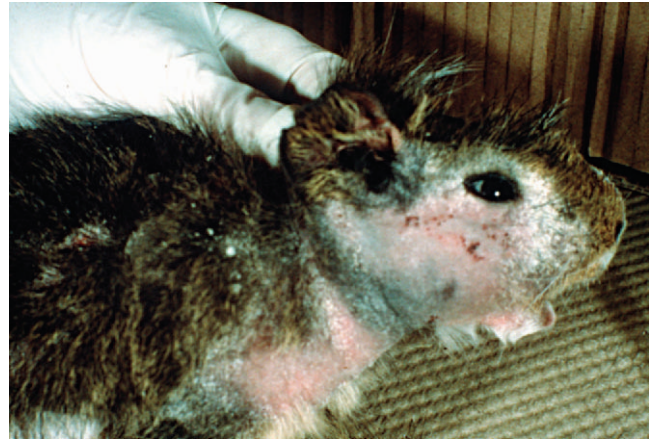

Figure 17-19 A guinea pig patient with severe *Trixacarus caviae* infestation. (Courtesy Stephen D. White, DVM, DACVD.)



Figure 17-20 Microscopic view of an egg of the louse *Gliricola porcelli* adhered to a shaft of hair. (Courtesy Stephen D. White, DVM, DACVD.)

pruritic, sometimes to the extent of seizure development. As with other mite infestations, diagnosis is based on the identification of the parasites on skin scrapings. Once definitive diagnosis has been made, treatment with ivermectin and selamectin (6 mg/kg q2-4wk) is usually effective. *Chirodiscoides caviae* are fur mites diagnosed in guinea pigs. Because it rarely causes clinical disease, treatment is usually unnecessary.^{20,31}

Gyropus ovalis and *Gliricola porcelli* are species of lice that are commonly identified in guinea pigs (Figure 17-20). Infested guinea pigs may be pruritic, but are usually unaffected.²⁰ Guinea pigs severely infested with these mites may demonstrate poor coat quality and alopecia.

DERMATOPHYTES

Patchy hair loss without associated pruritus may be attributed to dermatophytosis, most commonly *Trichophyton mentagrophytes*² (Figure 17-21). Lesions are circular and scaled and usually occur on the face and head.²⁰ The diagnosis of dermatophytosis is made by a positive fungal culture. Because of the zoonotic potential of these fungal organisms, care should be

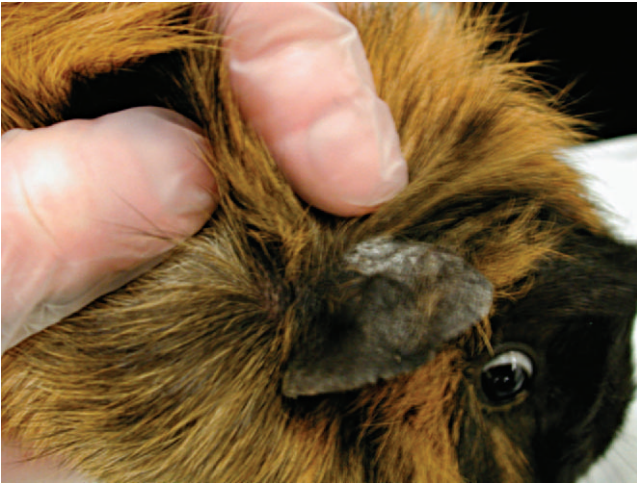

Figure 17-21 A guinea pig with a crusted area on the dorsal pinna consistent with dermatophytosis. A *Trichophyton* organism was cultured from the site.

taken when handling guinea pig patients suspected of having dermatophytosis.

CERVICAL LYMPHADENITIS

Streptococcus zooepidemicus Lancefield's group C is the causative agent of cervical lymphadenitis. This disease will cause severe swellings of the lymph nodes in the cervical region in guinea pigs. Affected guinea pigs will frequently exhibit no other clinical signs but may become septicemic, with lesions affecting the heart, lungs, kidney, and skin.²⁰ The most effective treatment for cervical lymphadenitis is complete surgical excision of the affected lymph nodes, followed by appropriate antibiotic therapy based on culture and sensitivity testing. Lancing and draining the abscesses is often not curative, as the abscesses form thick capsules that harbor organisms, leading to recurrence.

Yersinia pseudotuberculosis has also been shown to cause cervical lymphadenitis in guinea pigs.¹⁷ Although the affected guinea pigs are usually not ill, the concern is that rupture of the abscesses will release large amounts of this potentially zoonotic organism into the environment. Another potential causal agent of cervical lymphadenitis is *Streptobacillus moniliformis*.³²

One report exists of a cervical mass, initially believed to be cervical lymphadenitis, which was histologically determined to be a thyroid papillary adenoma.³³ The mass was apparently nonfunctional and the guinea pig appeared otherwise healthy, but surgical resection was curative.

PODODERMATITIS

Guinea pigs housed in cages with wire flooring are predisposed to developing ulcerated lesions on the plantar surfaces of their feet. Mild lesions may appear as hyperemic, swollen areas of the weight-bearing surfaces. These lesions can progress to ulcerations with secondary infections (Figure 17-22). Vitamin C deficiency has also been considered a predisposing factor for

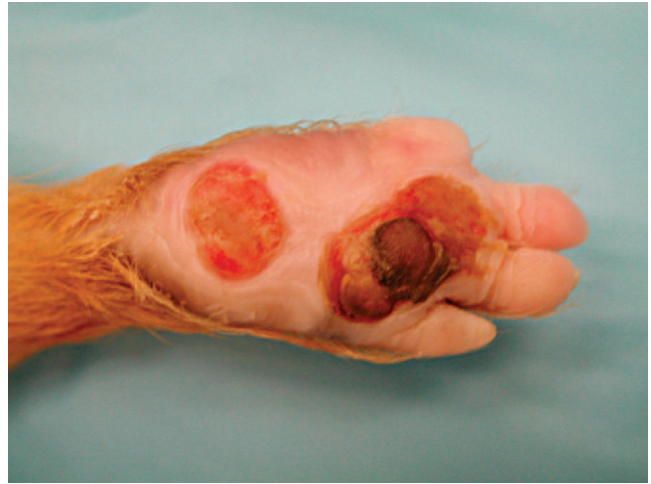

Figure 17-22 Severe, ulcerative pododermatitis in a guinea pig. (Courtesy Michelle G. Hawkins, VMD, DABVP [Avian].)

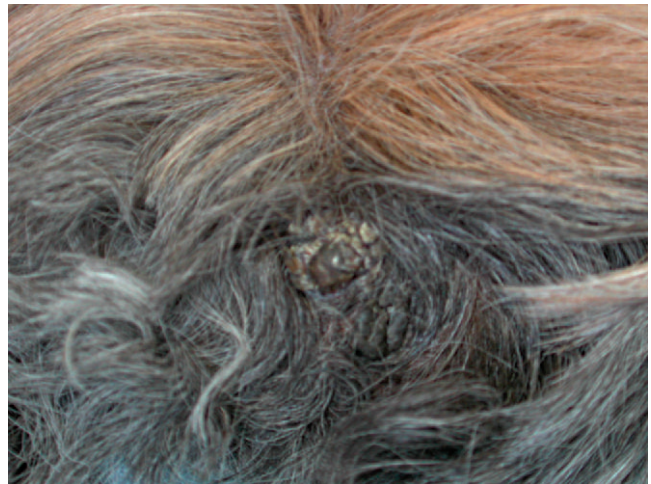

Figure 17-23 Trichofolliculoma on the dorsum of a guinea pig.

the development of pododermatitis, as affected animals may be in pain and reluctant to move, resulting in the development of pressure sores.²⁰ Ulcerated, infected lesions should be managed with appropriate antibiotics and antiinflammatory drugs, but the focus of treatment should be improving husbandry (e.g., providing appropriate flooring/bedding, vitamin C supplementation).

TRICHOFOLLICULOMA

Trichofolliculomas are the most common cutaneous tumor seen in guinea pigs.²⁰ These benign tumors often occur on the dorsum and are typically round and hairless (Figure 17-23).

CUTANEOUS VASCULAR MALFORMATION

Another cutaneous abnormality that has been described in guinea pigs is cutaneous vascular malformation.³⁴ The lesion described was a raised, ulcerated plaque on the animal's flank, which bled intermittently. Ultimately, the cutaneous vascular malformation resulted in fatal hemorrhage. Histologically, the

lesion was described as an expansile mass extending into the skeletal muscle and consisting of multiple vascular spaces of varying sizes. These vascular spaces were lined with endothelial cells.

Neoplasia

Compared to the incidence of neoplasia in other mammalian species, the incidence of neoplasia in guinea pigs appears low or is underreported. However, there have been several reported cases of neoplasia in guinea pigs. As more guinea pig owners seek quality veterinary care for their pets, reports of neoplasia will increase.

LYMPHOMA

Lymphoma is the most commonly reported neoplasia in guinea pigs.²⁰ Clinical signs associated with guinea pig neoplasia include lymphadenopathy, splenomegaly, and hepatomegaly. Leukemic and aleukemic forms of guinea pig lymphoma have been identified.

THYROID CARCINOMA

Thyroid carcinoma has been reported in an adult guinea pig that demonstrated multiple masses in the ventral cervical region.³⁵ As there was no evidence of neoplastic disease elsewhere on postmortem examination, this was considered a primary tumor.

MESOTHELIOMA

Mesothelioma has been reported in the abdomen of an adult guinea pig.³⁶ The guinea pig had died of complications associated with pneumonia, and the mesothelioma was diagnosed through a necropsy examination. The mass consisted of diffuse nodules on the serosal surfaces of numerous organs in the abdominal cavity.

Miscellaneous

HEAT STROKE

Guinea pigs are native to cooler regions of South America and are therefore relatively intolerant of temperatures above 80° F, lower if the environment is also humid. Guinea pigs should be housed in well-ventilated enclosures at temperatures between 65° and 75° F to prevent heat stress.

Clinical signs of heat stress include rapid, shallow respirations, lethargy, poor peripheral perfusion, and ptialism.¹³ Treatment includes reducing the animal's core body temperature with cool water baths or applying alcohol to the feet and ears; in addition, fluid therapy (either intravenous or subcutaneous) is recommended to improve perfusion. The prognosis for this condition is guarded.

INCLUSION-BODY CONJUNCTIVITIS

Chlamydophila psittaci has been identified as a disease-causing agent in guinea pigs; it usually causes a mild, self-limiting conjunctivitis. This intracellular bacterial disease usually occurs in young guinea pigs 4 to 8 weeks of age but has been reported

in adults as well.³⁷ In one outbreak, the typical conjunctival abnormalities were present with other, more significant, clinical signs, such as rhinitis, abortion, and pneumonia.³⁸ A definitive diagnosis can be achieved through Giemsa staining, immunofluorescent antibody testing of conjunctival scrapings, and serologic testing.³⁷

PROLIFERATIVE UROCYSTICA AND ADENOMA

Guinea pigs have been reported to develop pathologic changes related to ingestion of Forssk fern.^{39,40} In these studies, guinea pigs fed fresh fern developed hematuria and hemorrhage of the bladder wall.⁴⁰ One guinea pig fed dried fern developed proliferative urocystica and adenoma of the bladder, a finding sometimes considered precancerous in human patients. This guinea pig did not show clinical signs associated with the bladder abnormalities.³⁹

RABIES

Rabies virus infection is uncommon in rodent species, but it has been described and should be considered a differential diagnosis for an ill guinea pig with suspect contact to wildlife, especially raccoons. A recent report of a rabies in a privately owned guinea pig described abnormal behavior (biting the owner) 26 days after the guinea pig had possible interactions with a raccoon.⁴¹ In this guinea pig, rabies virus antigen was detected by immunofluorescent antibody testing in the sublingual salivary gland, tongue, and buccal tissues, implying that the guinea pig could have transmitted the virus via a bite wound.

THERAPEUTICS

Fluids

Sick guinea pigs are often anorexic and therefore dehydrated. Restoration of normal hydration status is crucial for the successful treatment of many disease processes. Replacement of fluid deficit and maintenance of normal hydration can be achieved by administering crystalloids substances through subcutaneous, intraperitoneal, intravenous, or intraosseous routes. Because of the difficulty in placing and maintaining catheters in peripheral veins and bones, the most common route for fluid administration is subcutaneous.

Subcutaneous fluid administration is generally well tolerated. Fluids are administered under the skin of the cranial, dorsal thorax (Figure 17-24). Butterfly catheter needles are useful because they allow the patient to move around without pulling out the injection needle. Maintenance fluid rates for guinea pigs are 80-100 mL/kg/day.

Feeding

Another important aspect of management for the sick guinea pig is nutritional support. Anorexic guinea pigs can experience a change in their normal GI flora in as little as 8 to 12 hours. This change of GI flora can lead to ileus, colic, overgrowth of

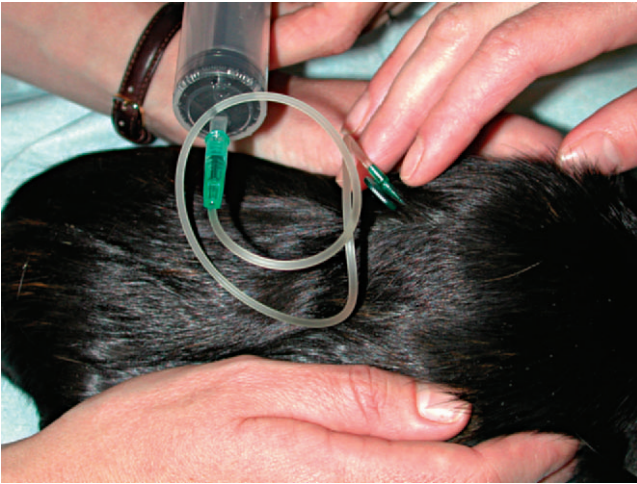


Figure 17-24 Subcutaneous fluid administration to a guinea pig using a butterfly catheter.

pathogenic bacteria, and enterotoxemia. Commercial products are available that are palatable and high in fiber. These products help to maintain gut motility (Oxbow Critical Care for Herbivores, Oxbow Hay Company, Murdock, NE).

Patients will often eat directly from a dish or 60-ml catheter tip syringe. For patients that are more resistant to eating, a technique that is useful, in my experience, is to remove the plungers from 1-ml or 3-ml syringes and fill them individually using a catheter tip syringe. Although this method may seem tedious, it allows the delivery of small boluses of food to be incrementally dispensed.

Antibiotics

The GI tract of guinea pigs can be very sensitive to the effects of certain classes of antibiotics. The GI flora of guinea pigs is primarily Gram positive, and administration of antibiotics with a primarily Gram-positive spectrum can result in overgrowth of Gram-negative and anaerobic organisms. Enteral administration of penicillins (e.g., amoxicillin, ampicillin), macrolides (e.g., erythromycin, lincomycin), and first-generation cephalosporins can result in overgrowth of opportunistic pathogens.²⁰ Ampicillin administered subcutaneously at doses of 8 and 10mg/kg three times a day resulted in mortality rates of 20% and 30%, respectively, in a group of guinea pigs. At necropsy, *Clostridium difficile* was cultured from the ceca of all fatalities.⁴² Twenty-five percent of guinea pigs administered 100 mg/kg of cefazolin, a first-generation cephalosporin, intramuscularly died of enterocolitis after several injections.⁴³ All antibiotics should be used with caution in guinea pigs because of the possibility of disruption of the GI flora (Table 17-2).

SURGERY

Anesthesia

Guinea pigs can be induced using isoflurane or sevoflurane administered by mask or induction chamber (Figure 17-25).

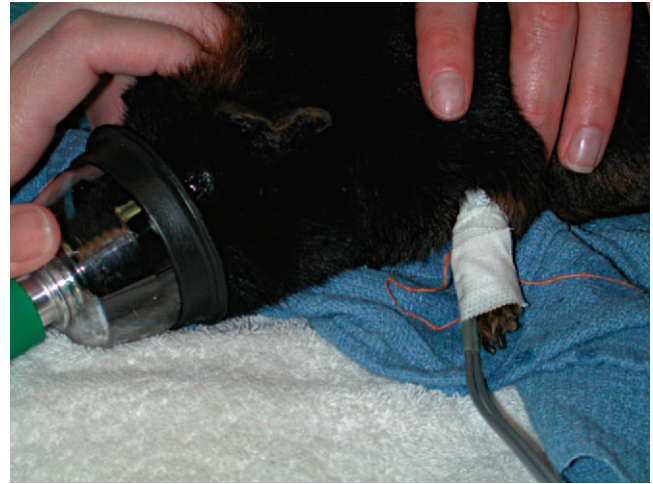

Figure 17-25 Mask induction of a guinea pig. A Doppler has been placed on the right forelimb to monitor heart rate.

For lengthy or potentially painful procedures, preanesthetic medications may be used before induction of the inhalant anesthetic agent. As a preanesthetic, an injectable combination, midazolam (0.2-0.5 mg/kg) and butorphanol (0.2-0.5 mg/kg), has been used with success. The administration of premedications will also decrease the stress of induction. Isoflurane and sevoflurane are both acceptable inhalant anesthetics for guinea pigs. The advantage of sevoflurane is that it does not appear to have as noxious a scent as isoflurane, thereby reducing breath holding during induction and producing a smoother anesthetic episode. After induction, the inhalant anesthetic may be switched to isoflurane if cost is an issue. Guinea pigs should not be fasted more than 2 to 3 hours before anesthesia. Because these animals are hindgut fermenters, withholding food for longer periods of time may disrupt GI flora.

Careful monitoring during anesthesia is essential. The number of respirations must be visually monitored for depth and character. Heart rate and rhythm should also be monitored continuously using a pediatric stethoscope or Doppler unit, which can be placed on a peripheral artery. Changes in heart rate or respiratory rate can occur rapidly, so it is advantageous to have precalculated doses of emergency drugs (e.g., glycopyrrolate, epinephrine, atropine, dopram) drawn and available for use before anesthetic induction.

Intubation

Intubation of guinea pigs is generally considered to be very difficult. The long, narrow oral cavity makes visualization of the glottis difficult. The soft tissues of the tongue and soft palate are continuous in the caudal oropharynx, leaving only a small aperture, the *palatal ostium*. Intubation must be performed through this opening in the mucosal tissues. Several techniques have been described for visualizing the glottis to assist with intubation. These usually involve alterations of laryngoscope blades so that they may be introduced into

TABLE 17-2 Selected Drug Dosages, Dosing Frequencies, and Routes of Administration

Drug	Route(s) of administration	Dose(s) ⁴⁴⁻⁴⁶	Dose frequency
Analgesic/anesthetic agents			
Atropine	IM	0.1-1.0 mg/kg	–
Buprenorphine	SC, IV	0.05 mg/kg	q8-12h
Butorphanol	SC, IM	0.4-2.0 mg/kg	q4-12h
Carprofen	PO, SC	1-4 mg/kg	q12-24h
Diazepam	IM	0.5-3.0 mg/kg	–
Glycopyrrolate	SC, IM	0.01-0.02 mg/kg	–
Ketamine	IM	10-44 mg/kg	–
Ketamine/diazepam	IM	20-30 mg/kg(K)/1-2 mg/kg(D)	–
Ketamine/midazolam	IM	5-10 mg/kg(K)/0.5-1.0 mg/kg(M)	–
Ketoprofen	SC, IM	1 mg/kg	q12-24h
Midazolam	IM	1-2 mg/kg	–
Nalbuphine	IM	1-2 mg/kg	q3h
Antibiotic agents			
Chloramphenicol	PO, SC, IM, IV	20-50 mg/kg	q6-12h
Ciprofloxacin	PO	5-20 mg/kg	q12h
Enrofloxacin	PO, SC, IM	5-15 mg/kg	q12h
Metronidazole	PO	25 mg/kg	q12h
Trimethoprim-sulfa	PO, SC, IM	15-30 mg/kg	q12h
Antifungal agents			
Griseofulvin	PO	5-25 mg/kg	q24h
Itraconazole	PO	5 mg/kg	q24h
Ketoconazole	PO	10-40 mg/kg	q24h
Antiparasitic agents			
Fenbendazole	PO	20 mg/kg	q24h
Ivermectin	SC	0.2-0.4 mg/kg	q7-14days
Lime sulfur dip	Topical	–	q7days
Metronidazole	PO	25 mg/kg	q12h
Praziquantel	PO, SC, IM	5-10 mg/kg	q10-14days
Selamectin	Topical	6 mg/kg	q28days
Sulfadimethoxine	PO	25-50 mg/kg	q24h
Miscellaneous agents			
Cimetidine	PO, SC, IM, IV	5-10 mg/kg	q6-12h
Cisapride	PO	0.1-0.5 mg/kg	q8-12h
Diphenhydramine	PO, SC	5-7.5 mg/kg	–
Epinephrine	IV	0.003 mg/kg	–
Furosemide	PO, SC	2-10 mg/kg	q12h
Lactated Ringer's	SC, IV	50-100 ml/kg	q24h
Metoclopramide	PO, SC, IM	0.2-1.0 mg/kg	q12h
Sucralfate	PO	25-100 mg/kg	q8-12h
Vitamin C	PO, SC, IM	10-100 mg/kg	q24h

IM, intramuscular; IV, intravenous; PO, per os; SC, subcutaneous.

the oral cavity without traumatizing the delicate buccal mucosa.^{47,48}

Another possible intubation technique utilizes a stethoscope altered so that an appropriately sized endotracheal tube can be affixed to the end. The endotracheal tube is then inserted into the caudal oropharynx. The anesthetist will then listen through the ear pieces of the stethoscope for expiration.

The tube is then gently introduced into the trachea. This technique requires practice to perfect but, once the procedure has been performed several times, is a reliable way to intubate guinea pigs. Application of a small amount of lidocaine to the *rima glottis* can ease intubation. Rigid endoscopes and otoscopes, when available, are also very helpful in visualizing the glottis for intubation.

Ovariohysterectomy

Indications for an ovariohysterectomy procedure in guinea pigs include routine sterilization, dystocia, and reproductive tract disease (e.g., neoplasia, muco/hydro/pyometra, ovarian cysts). In general, the surgical approach and technique are similar to those used with domestic species. The patient is placed in dorsal recumbency, and a ventral midline incision is made through the *linea alba*. Care must be taken upon entering the abdomen to avoid incising the large cecum, which is often situated along the ventral body wall. The body of the uterus can be located dorsal to the bladder. The ovaries lie caudally and laterally to the kidneys and are 6 to 8 mm in length.⁴⁹ The abdomen of the guinea pig is deep, and the ovaries can be difficult to exteriorize. Care must be taken to avoid tearing the short ovarian vessels. Once the ovaries are removed, the uterus is ligated and transected in a manner similar to that used with other mammals.

Ovariectomy

Another method of sterilization that is reported in guinea pigs is ovariectomy. The incidence of uterine disease compared with ovarian disease in guinea pigs is quite low. The approach for removal of the ovaries is through small incisions of the dorsal-lateral body wall caudal to the last rib. The advantage of this approach is that the sensitive GI tract is not manipulated to reach the structures to be excised.

Orchiectomy

Orchiectomy is typically performed to prevent reproduction, to decrease undesirable sexual behavior, and to treat reproductive tract disease. The orchiectomy procedure in guinea pigs is performed by making an incision through the scrotum over each testicle. A closed technique or open technique, whereby the vaginal tunic is incised, may be performed. Although herniation of abdominal contents through the inguinal canal does not commonly occur with open castration, it is still advisable to close the inguinal ring if this technique is used. The incisions may be closed with either an intradermal suture pattern or with tissue glue.

Suture Reaction

Reactions to suture material are relatively common in guinea pigs after surgical procedures. These reactions can vary in severity from mild local irritation to abscessation. Suture materials that cause a large amount of inflammation, such as chromic gut, should never be used in guinea pigs. In general, monofilament suture materials that are degraded by hydrolysis are preferred.

REFERENCES

- Verstraete FJM: Advances in diagnosis and treatment of small exotic mammal dental disease, *Semin Av Exot Pet Med* 12(1):37-48, 2003.
- Flecknell PA: Guinea pigs. In Beynon PH, Cooper JE, editors: *Manual of Exotic Pets*, Cheltenham, Gloucestershire, 1991, British Small Animal Veterinary Association.
- Harkness JE: Biology and husbandry: guinea pigs. In Harkness JE, editor: *A Practitioner's Guide to Domestic Rodents*, Lakewood, Colo, 1993, American Animal Hospital Association.
- Quesenberry KE, Donnelly TM, Hillyer EV: Biology, husbandry, and clinical techniques. In Quesenberry KE, Carpenter JW, editors: *Ferrets, Rabbits, and Rodents: Clinical Medicine and Surgery*, ed 2, St Louis, 2003, WB Saunders.
- Carpenter JW: Hematologic and serum biochemical values of rodents. In Carpenter JW, editor: *Exotic Animal Formulary*, ed 3, St Louis, 2005, WB Saunders.
- Campbell TW: Mammalian hematology: laboratory animals and miscellaneous species. In Thrall MA, editor: *Veterinary Hematology and Clinical Chemistry*, Baltimore, 2004, Lippincott Williams and Wilkins.
- Eremin O, Coombs RRA, Ashby J et al: Natural cytotoxicity in the guinea-pig: the natural killer (NK) cell activity of the Kurloff cell, *Immunol* 41:367-378, 1980.
- Revell PA: The Kurloff cell, *Int Rev Cytol* 51:275-314, 1977.
- Silverman S, Tell LA: Radiology equipment and positioning techniques. In Silverman S, Tell LA, editors: *Radiology of Rodents, Rabbits, and Ferrets: An Atlas of Normal Anatomy and Positioning*, St Louis, 2006, WB Saunders.
- Gibson SV, Wagner JE: Cryptosporidiosis in guinea pigs: a retrospective study. *JAVMA* 189(9):1033-1034, 1986.
- Wobeser G: Tyzzer's disease. In Williams ES, Barker IK, editors: *Infectious Diseases of Wild Mammals*, ed 3, Ames, Iowa, 2001, Blackwell.
- Motzel SL, Riley LK: Subclinical infection and transmission of Tyzzer's disease in rats, *Lab Anim Sci* 42:439-443, 1992.
- O'Rourke DP: Disease problems of guinea pigs. In Quesenberry KE, Carpenter JW, editors: *Ferrets, Rabbits, and Rodents: Clinical Medicine and Surgery*, ed 2, St Louis, 2003, WB Saunders.
- Jaax GP, Jaax NK, Petrali JP et al: Coronavirus-like virions associated with a wasting syndrome in guinea pigs, *Lab Anim Sci* 40(4):375-378, 1990.
- Rigby C: Natural infections of guinea pigs, *Lab Anim* 10:119-142, 1976.
- Haberman RT, Williams FP: Salmonellosis in laboratory animals, *J Natl Cancer Inst* 20: 933-947, 1958.
- Paterson JS: The guinea pig or cavy, *The UFAW Handbook on the Care and Management of Laboratory Animals*, ed 4, Edinburgh and London, 1972, Churchill Livingstone.
- Ganguly R, Durieux MF, Waldman RH: Macrophage function in vitamin c-deficient guinea pigs, *Am J Clin Nutr* 29:762-765, 1976.
- Steiger SM, Wenker C, Zeigler-Gohm D et al: Ureterolithiasis and papilloma formation in the ureter of a guinea pig, *Vet Radiol Ultrasound* 44(3):326-329, 2003.
- Quesenberry KE: Guinea pigs, *Vet Clin North Am Small Anim Pract* 24(1):67-86, 1994.
- Bishop CR: Reproductive medicine of rabbits and rodents. In Speer BL, editor: *The Veterinary Clinics of North America, Exotic Animal Practice: Reproductive Medicine* 5:3, Philadelphia, 2002, WB Saunders.
- Greenacre CB: Spontaneous tumors of small mammals. In Graham JE, editor: *The Veterinary Clinics of North America, Exotic Animal Practice: Oncology* 7:3, Philadelphia, 2004, WB Saunders.
- Trahan CJ, Stephenson EH, Ezzell JW et al: Airborne-induced experimental *Bordetella bronchiseptica* pneumonia in strain 13 guinea pigs, *Lab Anim* 21:226-232, 1987.
- Wullenweber M, Boot R: Interlaboratory comparison of enzyme-linked immunosorbent assay (ELISA) and indirect immunofluorescence (IIF) for detection of *Bordetella bronchiseptica* antibodies in guinea pigs, *Lab Anim Sci* 28:335-339, 1994.
- Matherne CM, Steffen EK, Wagner JE: Efficacy of commercial vaccines for protecting guinea pigs against *Bordetella bronchiseptica* pneumonia, *Lab Anim Sci* 37(2):191-194, 1987.
- Matsubara J, Kamiyama T, Miyoshi H et al: Serodiagnosis of *Streptococcus pneumoniae* infection in guinea pigs by an enzyme-linked immunosorbent assay, *Lab Anim* 22:304-308, 1988.
- Kirchner BK, Lake SG, Wightman SR: Isolation of *Streptobacillus moniliformis* from a guinea pig with granulomatous pneumonia, *Lab Anim Sci* 42(5):519-521, 1992.
- Pring-Åkerblom P, Blažek K, Schramlová J et al: Polymerase chain reaction for detection of guinea pig adenovirus, *J Vet Diagn Invest* 9:232-236, 1997.

29. Butz N, Ossent P, Homberger FR: Pathogenesis of guinea pig adenovirus infection: *Lab Anim Sci* 49(6):600-604, 1999.
30. Harris IE, Portas BH: Adenoviral bronchopneumonia of guinea pigs, *Aust Vet J* 62(9):317, 1985.
31. Lumeij JT, Cremers HJWM: Anorexia and *Chirodiscoides caviae* infection in a guinea pig (*Cavia porcellus*), *Vet Rec* 119:432, 1986.
32. ILAR: A guide to infectious diseases in guinea pigs, gerbils, hamsters, and rabbits, part II, diseases outlines, *Inst Lab Anim Res News* 17:ID7-ID15, 1974.
33. LaRegina MC, Wightman SR: Thyroid papillary adenoma in a guinea pig with signs of cervical lymphadenitis, *JAVMA* 175(9):969-971, 1979.
34. Osofsky A, De Cock HEV, Tell LA et al: Cutaneous vascular malformation in a guinea pig (*Cavia porcellus*), *Vet Dermatol* 15:47-52, 2004.
35. Zarrin K: Thyroid carcinoma of a guinea pig: a case report, *Lab Anim* 8:145-148, 1974.
36. Wilson TM, Brigman G: Abdominal mesothelioma in an aged guinea pig, *Lab Anim Sci* 32(2):175-176, 1982.
37. Deeb BJ, DiGiacomo RF, Wang SP: Guinea pig inclusion conjunctivitis (GPIC) in a commercial colony, *Lab Anim* 23:103-106, 1989.
38. Schmeer VN, Weiss R, Reinacher M et al: Verlauf einer *Chlamydia*-bedingten "Meerschweinchen-Einschluß Körperchen-Konjunktivitis" in einer Versuchstierhaltung, *Zeitschrift für Versuchstierkunde* 27:233-240, 1985.
39. Somvanshi R, Sharma VK: Proliferative urocystica and adenoma in a guinea pig, *J Comp Pathol* 133:277-280, 2005.
40. Somvanshi R, Sharma VK: Preliminary studies on *Christella dentate* (Forssk) fern toxicity in guinea pigs, *J Lab Med* 5:6-15, 2004.
41. Eidson M, Matthews SD, Willsey AL et al: Rabies virus infection in a pet guinea pig and seven pet rabbits, *JAVMA* 227(6):932-935, 2005.
42. Young JD, Hurst WJ, White WJ et al: An evaluation of ampicillin pharmacokinetics and toxicity in guinea pigs, *Lab Anim Sci* 37(5):652-656, 1987.
43. Fritz PE, Hurst WJ, White WJ et al: Pharmacokinetics of cefazolin in guinea pigs, *Lab Anim Sci* 37(5):646-651, 1987.
44. Ness RD: Rodents. In Carpenter JW, editor: *Exotic Animal Formulary*, ed 3, Philadelphia, 2005, WB Saunders.
45. Morrisey JK, Carpenter JW: Formulary. In Quesenberry KE, Carpenter JW, editors: *Ferrets, Rabbits, and Rodents: Clinical Medicine and Surgery*, ed 2, St Louis, 2003, WB Saunders.
46. Plumb DC: *Veterinary Drug Handbook*, ed 4, Ames, Iowa, 2002, Iowa State Press.
47. Blouin A, Cormier Y: Endotracheal intubation in guinea pigs by direct laryngoscopy, *Lab Anim Sci* 37(2):244-245, 1987.
48. Turner MA, Thomas P, Sheridan DJ: An improved method for direct laryngeal intubation in the guinea pig, *Lab Anim* 26:25-28, 1992.
49. Breazile JE, Brown EM: Anatomy. In Wagner JE, Manning PJ, editors: *Biology of the Guinea Pig*, New York, 1976, Academic Press.