



ELSEVIER

Contents lists available at [ScienceDirect](https://www.sciencedirect.com)

Respiratory Medicine Case Reports

journal homepage: www.elsevier.com/locate/rmcr

A patient case demonstrating the efficacy of benralizumab in uncontrolled severe eosinophilic asthma refractory to omalizumab and mepolizumab treatment

John Davison, Simon Doe^{*}

Newcastle Severe Asthma Service, Newcastle upon Tyne Hospitals NHS Foundation Trust, United Kingdom

ARTICLE INFO

Keywords:

Benralizumab
Severe eosinophilic asthma
Biologics
Eosinophilia
Quality of life

ABSTRACT

Severe eosinophilic asthma is associated with a heavy burden and impact on daily living in patients experiencing uncontrolled symptoms, exacerbations, and treatment side effects. This case study reports a 49-year-old woman who presented to the severe asthma center with uncontrolled severe asthma despite multiple maintenance medications and omalizumab treatment. On presentation, the patient had experienced two to three hospitalizations per year, frequent asthma exacerbations requiring courses of oral corticosteroids, and symptoms that impacted her quality of life. Omalizumab was previously discontinued, and bronchial thermoplasty was also unsuccessful. The patient stabilized on injectable steroids and commenced mepolizumab once available on prescription. Owing to continued exacerbations and an inability to reduce steroid treatment without exacerbating, mepolizumab was discontinued and the patient commenced benralizumab (30 mg subcutaneously every 4 weeks for the first three doses, every 8 weeks thereafter) under the sole care of the severe asthma center. Benralizumab treatment resulted in a reduction in steroid treatment, zero asthma exacerbations, improved asthma control and lung function, and a marked improvement in activity levels that allowed the patient to participate in a long-distance running event. Additionally, 7 months following the initiation of benralizumab treatment, her blood eosinophils were completely depleted. These findings support the use of benralizumab in patients with refractory uncontrolled severe eosinophilic asthma despite previous biologic treatment with omalizumab and mepolizumab, as improvements in clinical and patient outcomes, including quality of life, can be achieved in difficult-to-treat cases.

1. Introduction

Severe asthma is defined as asthma that is uncontrolled despite adherence with optimized high-dose inhaled corticosteroids (ICS) plus long-acting β_2 -agonist (LABA) treatment and management of contributory factors, or asthma that worsens when high-dose treatment is decreased [1,2]. Globally, asthma has a prevalence of 1–18%, with severe asthma affecting ~5–10% of the total asthma population [1,2]. Symptoms, exacerbations, and medication side effects, such as those associated with long-term corticosteroid use (eg obesity, diabetes, pneumonia, osteoporosis, cataracts, cardio-cerebrovascular diseases, adrenal suppression, renal impairment,

Abbreviations: ACQ, Asthma Control Questionnaire; BID, twice daily; FeNO, fractional exhaled nitric oxide; FEV₁, forced expiratory volume in 1 second; FVC, forced vital capacity; ICS, inhaled corticosteroid(s); Ig, immunoglobulin; IL, interleukin; IM, intramuscular; LABA, long-acting β_2 -agonist; OCS, oral corticosteroid(s); Q4W, every 4 weeks; Q8W, every 8 weeks; QD, once daily; SAC, severe asthma center; SC, subcutaneously.

^{*} Corresponding author.

E-mail addresses: john.davison4@nhs.net (J. Davison), simon.doe@nhs.net (S. Doe).

<https://doi.org/10.1016/j.rmcr.2021.101557>

Received 6 July 2021; Received in revised form 18 August 2021; Accepted 13 November 2021

Available online 17 November 2021

This is an open access article under the CC BY-NC-ND license (<http://creativecommons.org/licenses/by-nc-nd/4.0/>).

depression/anxiety, and sleep apnea), can be burdensome to day-to-day living in patients with severe asthma [2–4].

Treatment of severe asthma often requires controller medications (ICS plus LABA), reliever medications (ICS-formoterol or short-acting β_2 -agonist), and add-on therapy, such as oral corticosteroids (OCS) or biologics, when symptoms persist [2]. Currently approved biologics for use as an add-on treatment for severe asthma include omalizumab (XOLAIR®, Genentech, Inc.; Novartis Pharmaceuticals GmbH; anti-IgE), dupilumab (DUPIXENT®, Sanofi Genzyme; Regeneron Pharmaceuticals, Inc.; anti-IL-4R α), mepolizumab (NUCALA®, GlaxoSmithKline LLC; anti-IL-5), reslizumab (CINQAIR®/CINQAERO®, Teva Respiratory, LLC; anti-IL-5), and benralizumab (FASENRA®, AstraZeneca AB; anti-IL-5R α) [2,5–14]. In 2017 and 2018, benralizumab was approved in the USA and Europe, respectively, for use as an add-on maintenance treatment in patients aged ≥ 12 years (USA) and ≥ 18 years (Europe) with severe eosinophilic asthma that is inadequately controlled while on high-dose ICS and LABA [5,6]. Severe eosinophilic asthma is a subset of severe asthma, and high levels of eosinophils in the blood and/or sputum, as well as high-dose ICS and/or frequent OCS use, are indicative of type 2 inflammation [2]. The efficacy and safety of benralizumab (30 mg every 4 weeks/8 weeks [Q4W/Q8W]) was assessed in the SIROCCO and CALIMA Phase 3, randomized, multicenter, double-blind, placebo-controlled trials that reported near complete depletion of blood eosinophils, significant exacerbation rate reduction, and improved lung function and symptoms (Q8W only) in patients with uncontrolled severe asthma [15,16]. Moreover, benralizumab has demonstrated a significant OCS-sparing effect in patients with severe eosinophilic asthma in the ZONDA randomized controlled trial [17]. In addition to its approved indication, the objective of this real-world case study is to report the efficacy of benralizumab in uncontrolled severe eosinophilic asthma refractory to other treatments, including omalizumab, mepolizumab, and bronchial thermoplasty.

2. Case report

A 49-year-old woman was referred to the severe asthma center (SAC) in Newcastle, United Kingdom, in July 2015 by her local asthma team. The patient was a non-smoker with no family history of asthma and presented with uncontrolled severe asthma and monthly exacerbations requiring up to 12 OCS courses and two to three hospital admissions per year. Having been diagnosed with asthma in 2002, her symptoms had impacted her physical activity. Her asthma was treated with multiple maintenance medications, including salbutamol (>20 puffs/week), salmeterol xinafoate/fluticasone propionate (50/500 μg one puff twice daily [BID]), theophylline (200 mg BID), cetirizine (10 mg once daily [QD]), montelukast (10 mg QD), tiotropium bromide (18 μg QD), and previously omalizumab from 2012 to 2013, with limited therapeutic benefit. In addition, the patient had undergone three bronchial thermoplasty procedures by August 2012, with high-dose prednisolone cover, but the improvements seen were short lived (<6 months).

On presentation, the patient had difficult-to-control asthma symptoms and diffuse wheezing throughout her chest while receiving prednisolone and theophylline treatment. Comorbidities included anxiety and depression that were managed in primary care, and hay fever that was treated with cetirizine (10 mg QD). Oxygen saturation was 94%, forced expiratory volume in 1 second (FEV₁) was 40% of predicted normal, and blood eosinophil levels had been previously recorded at 810 cells/ μL ($0.81 \times 10^9/\text{L}$) in March 2015. The patient’s blood eosinophil levels over time are shown in Fig. 1. Owing to a lack of clinical improvement, changes were made to her treatment regimen, including switching her OCS to betamethasone (4.5 mg QD for 1 week) with the aim to reduce the steroid dose by 750 μg every 2 weeks until stopped completely.

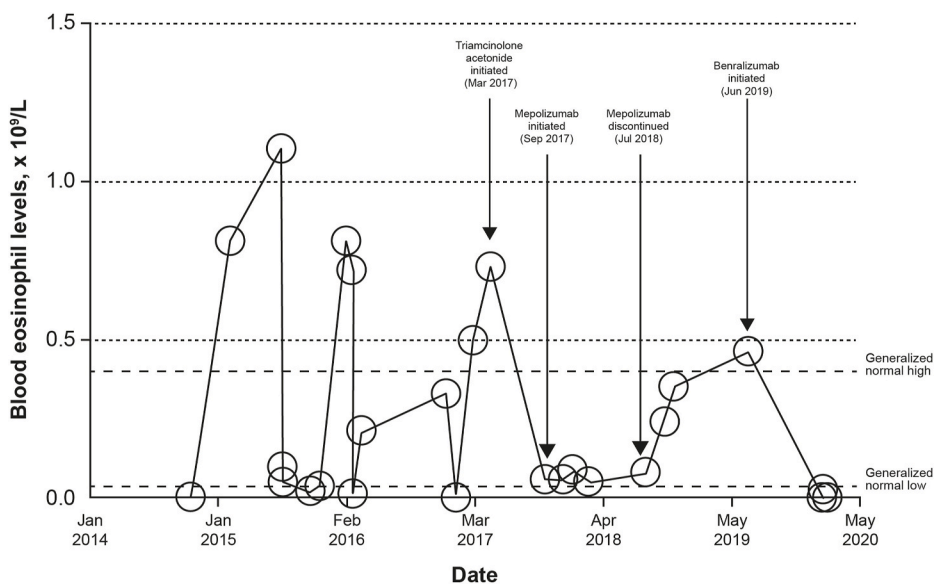


Fig. 1. Blood eosinophil levels over time.

In 2016, the patient had three asthma exacerbations, two of which required hospital admission. Notably, in March 2016, the patient was admitted to hospital with worsening asthma symptoms and triamcinolone acetonide (40 mg intramuscular [IM]) was commenced. Owing to an excellent response with substantial improvement in symptoms, triamcinolone acetonide (40 mg) treatment was continued on a monthly basis and daily maintenance dose of prednisolone was reduced from 30 mg to 10 mg. It proved possible to reduce the monthly dose of triamcinolone acetonide to 30 mg in October 2016 because of further improvement in the patient's asthma (FEV₁, 1.8 L; fractional exhaled nitric oxide [FeNO], 42 ppb). However, following a significant exacerbation 6 months later (FEV₁, 1.4 L; oxygen saturation, 92% on air ventilation), the triamcinolone acetonide dose was increased to 40 mg Q4W. In May 2017, treatment adherence was confirmed by the medication possession ratio and the decision was made to continue with triamcinolone acetonide (40 mg Q4W) until mepolizumab became available for National Health Service prescription.

Approximately 4 months later, in September 2017, the patient commenced mepolizumab treatment (100 mg subcutaneously [SC] Q4W) with her secondary-care provider under the supervision of the SAC, in addition to her existing treatment regimen (triamcinolone acetonide 40 mg IM Q4W, salmeterol xinafoate/fluticasone propionate, salbutamol, theophylline, cetirizine, and prednisolone [10 mg QD]). One month later, triamcinolone acetonide was reduced to 30 mg Q4W because of an improvement in the markers of type 2 inflammation (FeNO levels, 20 ppb; blood eosinophil level, 60 cells/ μ L [0.06×10^9 /L]); however, the patient's asthma deteriorated, type 2 inflammation worsened (FeNO, 67 ppb), and the monthly dose was increased back to 40 mg before a gradual reduction to 20 mg in early 2018 (FeNO, 39 ppb; blood eosinophil level, 90 cells/ μ L [0.09×10^9 /L]). The patient also requested that all of her treatment be directed by the SAC and discontinued her care with the local secondary-care provider – the patient preferred the continuity and expertise within the SAC. Treatment adherence was confirmed verbally with the patient during monthly visits to the SAC. In addition, serum theophylline and cortisol levels were measured to assess treatment adherence and the patient attended monthly visits to assess her inhaler technique and compliance was addressed, if necessary. No evidence of airway infection or other comorbidities, such as sleep apnea, breathing pattern disorder, or inducible laryngeal obstruction, was identified that could be responsible for the poor treatment response observed with mepolizumab treatment. Owing to continued exacerbations, underlying type 2 inflammation (indicated by a FeNO level of 87 ppb), and an ongoing high symptom/disease burden (shortness of breath, cough, a recent chest infection, and an emergency admission to hospital), mepolizumab was discontinued in July 2018. The patient remained on triamcinolone acetonide (40 mg IM Q4W), plus her existing maintenance medication, until initiation of benralizumab treatment in June 2019; treatment adherence was confirmed during this time by the medication possession ratio. Benralizumab was started at 30 mg SC (Q4W for the first three doses, Q8W thereafter) under the sole care of the SAC (blood eosinophil level, 460 cells/ μ L [0.46×10^9 /L], FEV₁, 1.7 L [55% of predicted normal]; forced vital capacity [FVC], 3.0 L [83% of predicted normal]; Asthma Control Questionnaire [ACQ] score, 4.7). At this time, the patient was receiving 5 mg of prednisolone daily. Within 1 month, benralizumab resulted in a marked improvement in the patient's asthma resulting in zero nocturnal symptoms and a reduction in triamcinolone acetonide dose to 30 mg Q4W. Over the next 3 months, the patient's asthma continued to improve while self-administering benralizumab, with zero asthma exacerbations (FeNO 18 ppb in October 2019) and a marked improvement in activity levels reported. Notably, the patient was able to participate in a long-distance running event while receiving benralizumab treatment. Gradually her triamcinolone acetonide dose was reduced until it was discontinued in December 2019 (FEV₁, 2.1 L [66% of predicted normal]; FVC, 3.7 L [98% of predicted normal]; FeNO, 57 ppb; ACQ score, 1.4), and an OCS wean was started following an additional month on benralizumab treatment (blood eosinophil levels, 0 cells/ μ L [0×10^9 /L]).

In May 2020, 11 months following initiation of benralizumab treatment, the patient's prednisolone dose had reduced to 3 mg QD while waiting for a Synacthen test to be completed to rule out adrenal insufficiency. Although the patient was diagnosed with asymptomatic COVID-19 in September 2020, the patient has had no asthma exacerbations since starting benralizumab treatment and is currently in full-time employment. The patient discontinued OCS treatment in April 2021 following a positive short Synacthen test and subsequent weaning program.

3. Discussion

This case report showed that benralizumab treatment resulted in marked improvements in asthma exacerbations, lung function, asthma control, and quality of life in a patient with uncontrolled severe eosinophilic asthma while on multiple maintenance medications, including long-term systemic corticosteroids, where previous biologic treatment with omalizumab and mepolizumab had failed to have significant benefit. In addition, previous bronchial thermoplasty, which aims to reduce smooth muscle mass and constriction of the airway [18], resulted in a short-lived response.

Biologics can be used to treat type 2 inflammation, including severe allergic and eosinophilic asthma [2]. Omalizumab (anti-IgE) and mepolizumab (anti-IL-5) are recommended as add-on treatments for severe asthma where there is evidence of an allergic or eosinophilic phenotype, respectively [2,19,20]. Omalizumab and mepolizumab have been reported in Phase 3 trials to reduce severe exacerbations and improve asthma control in patients with severe allergic or eosinophilic asthma [21–24]. Furthermore, omalizumab and mepolizumab have demonstrated an OCS-sparing effect, albeit a modest reduction versus placebo was reported in omalizumab studies [23,25]. Despite this, in this case study, asthma exacerbations persisted, and OCS use remained a requirement while on omalizumab or mepolizumab treatment.

Following unsuccessful treatment with omalizumab and mepolizumab, benralizumab was administered, and complete depletion of blood eosinophils was recorded. The mechanism of action of benralizumab differs from that of omalizumab and mepolizumab, as benralizumab binds to the alpha subunit on IL-5 receptors, inhibits IL-5 cytokines from binding, and leads to antibody-dependent cell-mediated cytotoxicity of eosinophils via natural killer cells [2,5,6]. This dual response to benralizumab treatment may be responsible for the marked reduction in blood eosinophil levels and improvements in exacerbation rates and asthma control in this study. These

findings are consistent with those reported by Phase 3 trials for benralizumab in severe eosinophilic asthma [15,16]. Additionally, in a Phase 3 trial of mepolizumab, blood eosinophils were not depleted to the same extent as reported with benralizumab herein [24]. As omalizumab treatment was provided before presentation at the SAC, the patient's asthma was likely considered to be of an atopic phenotype. While a poor treatment response was observed with omalizumab in this case study, benralizumab showed efficacy, which supports previous reports of improved lung function and exacerbation rates with benralizumab in patients with severe eosinophilic asthma regardless of atopic status and serum IgE concentrations [26].

Furthermore, benralizumab demonstrated a steroid-sparing effect in this case study. These findings are consistent with the Phase 3 ZONDA trial for benralizumab in severe eosinophilic asthma [17]. Although corticosteroids are important in the management of asthma and have been shown to be effective at reducing asthma exacerbations at a low cost [27], they are associated with unwanted side effects [4]. In addition, a dose-response relationship exists between steroid dose intensity and the risk of developing complications [28]. Therefore, increasing awareness of OCS-sparing strategies that are effective may help to positively change prescribing patterns moving forward [29].

This case study has also highlighted that establishing a positive relationship between patient and healthcare provider can enhance outcomes through the early identification of treatment failure and prompt initiation of alternative treatment options; this was the case under the sole care of the SAC in this study. The patient requested that her treatment was managed solely by the SAC owing to confidence in biologic administration and steroid weaning procedures, and the benefit of having a single point of contact for asking questions about her severe asthma. Building trust and patient confidence in the asthma team was considered pivotal in the successful outcome reported. Currently, many patients with suspected severe asthma are not referred to specialist centers, and without a formal diagnosis or referral, they are unable to access potentially life-changing biologic treatment [30]. Barriers to receiving biologic treatments include underestimation of asthma severity, overestimation of a patient's asthma control, poor communication between clinicians, and a lack of awareness about alternative treatment options [31].

This case study shows that if patients are responding poorly to one biologic, clinicians could consider switching to an alternative biologic with a different mechanism of action that may improve patient outcomes [2,32–34]. Of note, there is a growing body of evidence on real-life experiences with biologic switching from mepolizumab to benralizumab that has shown benefit for some patients with severe eosinophilic asthma by reducing blood eosinophil levels and OCS use, and improving exacerbation rates, asthma control, and quality of life [32–34]. In our experience, SACs that can recognize failure to respond adequately to current biologic therapy, have strategies in place to discuss alternative treatment options, and act promptly can improve patient outcomes and promote a positive relationship between the patient and asthma team. It is paramount that patients failing to respond to treatments, or patients receiving repeated/long-term steroid courses, are referred to an SAC where there are services and alternative treatments available, such as biologics, that may help to improve outcomes for some patients [31]. Primary and secondary care clinicians have a responsibility to ensure a timely referral in these cases [31,35].

4. Conclusion

In summary, this case study reports substantial improvements in asthma exacerbations, lung function, asthma control, steroid use, and quality of life in a patient with uncontrolled severe eosinophilic asthma treated with benralizumab, despite previous biologic treatment and bronchial thermoplasty. While benralizumab is indicated for use as an add-on maintenance treatment in patients aged ≥ 12 years (USA) and ≥ 18 years (Europe) with severe eosinophilic asthma that is inadequately controlled while on high-dose ICS and LABA [5,6], these findings also support its use as a potential efficacious treatment option in difficult-to-treat cases refractory to omalizumab, mepolizumab, and bronchial thermoplasty treatment.

Informed consent statement

Written informed consent was obtained from the patient.

Data sharing statement

All data requests should be submitted to the corresponding author for consideration. Access to anonymized data may be granted following review.

Author contributions

J.D. and S.D. analyzed and interpreted the patient data, and provided critical review of the manuscript drafts.

Role of the funding source

This research did not receive any specific grant from funding agencies in the public, commercial, or not-for-profit sectors.

Declaration of competing interest

J.D. has received consultant fees from AstraZeneca plc and Teva Pharmaceutical Industries Ltd., and speaker fees from GlaxoSmithKline plc; S.D. has received financial support to attend national and international conferences from AstraZeneca plc, GlaxoSmithKline plc, Sanofi Genzyme, and Teva Pharmaceutical Industries Ltd.

Acknowledgments

Medical writing and editing support, including preparation of the draft manuscript in accordance with GPP3 under the direction and guidance of the authors, incorporating author feedback and manuscript submission, was provided by Lauren Oswald MSc, of Helios Medical Communications, Alderley Park, Cheshire, UK, and Syed Ali of AstraZeneca, UK. This support was funded by AstraZeneca, UK.

References

- [1] K.F. Chung, S.E. Wenzel, J.L. Brozek, A. Bush, M. Castro, P.J. Sterk, I.M. Adcock, E.D. Bateman, E.H. Bel, E.R. Bleecker, L.P. Boulet, C. Brightling, P. Chaney, S. E. Dahlen, R. Djukanovic, U. Frey, M. Gaga, P. Gibson, Q. Hamid, N.N. Jajour, T. Mauad, R.L. Sorkness, W.G. Teague, International ERS/ATS guidelines on definition, evaluation and treatment of severe asthma, *Eur. Respir. J.* 43 (2014) 343–373, <https://doi.org/10.1183/09031936.00202013>.
- [2] (GINA) Global Initiative for Asthma, Global strategy for asthma management and prevention 2021. <https://ginasthma.org/wp-content/uploads/2021/05/GINA-Main-Report-2021-V2-WMS.pdf>, 2021. (Accessed 30 July 2021).
- [3] J.M. Foster, V.M. McDonald, M. Guo, H.K. Reddel, “I have lost in every facet of my life”: the hidden burden of severe asthma, *Eur. Respir. J.* 50 (2017) 1700765, <https://doi.org/10.1183/13993003.00765-2017>.
- [4] D.B. Price, F. Trudo, J. Voorham, X. Xu, M. Kerkhof, J. Ling Zhi Jie, T.N. Tran, Adverse outcomes from initiation of systemic corticosteroids for asthma: long-term observational study, *J. Asthma Allergy* 11 (2018) 193–204, <https://doi.org/10.2147/JAA.S176026>.
- [5] European Medicines Agency, FASENRA (benralizumab) summary of product characteristics. https://www.ema.europa.eu/en/documents/product-information/fasenra-epar-product-information_en.pdf, 2021. (Accessed 30 July 2021).
- [6] (FDA) U.S. Food & Drug Administration, FASENRA (benralizumab) highlights of prescribing information. https://www.accessdata.fda.gov/drugsatfda_docs/label/2017/761070s000lbl.pdf, 2021. (Accessed 30 July 2021).
- [7] European Medicines Agency, XOLAIR (omalizumab) summary of product characteristics. https://www.ema.europa.eu/en/documents/product-information/xolair-epar-product-information_en.pdf, 2020. (Accessed 30 July 2021).
- [8] (FDA) U.S. Food & Drug Administration, XOLAIR (omalizumab) highlights of prescribing information. https://www.accessdata.fda.gov/drugsatfda_docs/label/2020/103976s52351bl.pdf, 2020. (Accessed 30 July 2021).
- [9] European Medicines Agency, DUPIXENT (dupilumab) summary of product characteristics. https://www.ema.europa.eu/en/documents/product-information/dupixent-epar-product-information_en.pdf, 2021. (Accessed 30 July 2021).
- [10] (FDA) U.S. Food & Drug Administration, DUPIXENT (dupilumab) highlights of prescribing information. https://www.regeneron.com/downloads/dupixent_fpi.pdf, 2021. (Accessed 30 July 2021).
- [11] European Medicines Agency, NUCALA (mepolizumab) summary of product characteristics. https://www.ema.europa.eu/en/documents/product-information/nucala-epar-product-information_en.pdf, 2021. (Accessed 30 July 2021).
- [12] (FDA) U.S. Food & Drug Administration, NUCALA (mepolizumab) highlights of prescribing information. https://gskpro.com/content/dam/global/hcpportal/en_US/Prescribing_Information/Nucala/pdfs/NUCALA-PI-PIL-IFU-COMBINED.PDF, 2020. (Accessed 30 July 2021).
- [13] European Medicines Agency, CINQAERO (reslizumab) summary of product characteristics. https://www.ema.europa.eu/en/documents/product-information/cinqaero-epar-product-information_en.pdf, 2018. (Accessed 30 July 2021).
- [14] (FDA) U.S. Food & Drug Administration, CINQAIR (reslizumab) highlights of prescribing information. <https://www.cinqair.com/globalassets/cinqair/prescribinginformation.pdf>, 2020. (Accessed 30 July 2021).
- [15] E.R. Bleecker, J.M. FitzGerald, P. Chaney, A. Papi, S.F. Weinstein, P. Barker, S. Sproule, G. Gilmartin, M. Aurivillius, V. Werkström, M. Goldman, Efficacy and safety of benralizumab for patients with severe asthma uncontrolled with high-dosage inhaled corticosteroids and long-acting β_2 -agonists (SIROCCO): a randomised, multicentre, placebo-controlled phase 3 trial, *Lancet* 388 (2016) 2115–2127, [https://doi.org/10.1016/S0140-6736\(16\)31324-1](https://doi.org/10.1016/S0140-6736(16)31324-1).
- [16] J.M. FitzGerald, E.R. Bleecker, P. Nair, S. Korn, K. Ohta, M. Lommatzsch, G.T. Ferguson, W.W. Busse, P. Barker, S. Sproule, G. Gilmartin, V. Werkström, M. Aurivillius, M. Goldman, Benralizumab, an anti-interleukin-5 receptor α monoclonal antibody, as add-on treatment for patients with severe, uncontrolled, eosinophilic asthma (CALIMA): a randomised, double-blind, placebo-controlled phase 3 trial, *Lancet* 388 (2016) 2128–2141, [https://doi.org/10.1016/S0140-6736\(16\)31322-8](https://doi.org/10.1016/S0140-6736(16)31322-8).
- [17] P. Nair, S. Wenzel, K.F. Rabe, A. Bourdin, N.L. Lugogo, P. Kuna, P. Barker, S. Sproule, S. Ponnarambil, M. Goldman, Oral glucocorticoid-sparing effect of benralizumab in severe asthma, *N. Engl. J. Med.* 376 (2017) 2448–2458, <https://doi.org/10.1056/NEJMoa1703501>.
- [18] National Institute for Health and Care Excellence, Bronchial thermoplasty for severe asthma. <https://www.nice.org.uk/guidance/ipp635/resources/bronchial-thermoplasty-for-severe-asthma-pdf-1899874044788677>, 2018. (Accessed 30 July 2021).
- [19] National Institute for Health and Care Excellence, Omalizumab for treating severe persistent allergic asthma, Technology appraisal guidance [TA278], <https://www.nice.org.uk/guidance/ta278>, 2019. (Accessed 30 July 2021).
- [20] National Institute for Health and Care Excellence, Mepolizumab for treating severe eosinophilic asthma. Technology appraisal guidance [TA671]. <https://www.nice.org.uk/guidance/TA671>, 2021. (Accessed 30 July 2021).
- [21] N.A. Hanania, O. Alpan, D.L. Hamilos, J.J. Conde, I. Reyes-Rivera, J. Zhu, K.E. Rosen, M.D. Eisner, D.A. Wong, W. Busse, Omalizumab in severe allergic asthma inadequately controlled with standard therapy: a randomized trial, *Ann. Intern. Med.* 154 (2011) 573–582, <https://www.acpjournals.org/doi/full/10.7326/0003-4819-154-9-201105030-00002>.
- [22] I.D. Pavord, S. Korn, P. Howarth, E.R. Bleecker, R. Buhl, O.N. Keene, H. Ortega, P. Chaney, Mepolizumab for severe eosinophilic asthma (DREAM): a multicentre, double-blind, placebo-controlled trial, *Lancet* 380 (2012) 651–659, [https://doi.org/10.1016/S0140-6736\(12\)60988-x](https://doi.org/10.1016/S0140-6736(12)60988-x).
- [23] E.H. Bel, S.E. Wenzel, P.J. Thompson, C.M. Prazma, O.N. Keene, S.W. Yancey, H.G. Ortega, I.D. Pavord, Oral glucocorticoid-sparing effect of mepolizumab in eosinophilic asthma, *N. Engl. J. Med.* 371 (2014) 1189–1197, <https://doi.org/10.1056/NEJMoa1403291>.
- [24] H.G. Ortega, M.C. Liu, I.D. Pavord, G.G. Brusselle, J.M. FitzGerald, A. Chetta, M. Humbert, L.E. Katz, O.N. Keene, S.W. Yancey, P. Chaney, Mepolizumab treatment in patients with severe eosinophilic asthma, *N. Engl. J. Med.* 371 (2014) 1198–1207, <https://doi.org/10.1056/NEJMoa1403290>.
- [25] R. Normansell, S. Walker, S.J. Milan, E.H. Walters, P. Nair, Omalizumab for asthma in adults and children, *Cochrane Database Syst. Rev.* 1 (2014) CD003559, <https://doi.org/10.1002/14651858.CD003559.pub4>.
- [26] B.E. Chipps, P. Newbold, I. Hirsch, F. Trudo, M. Goldman, Benralizumab efficacy by atopy status and serum immunoglobulin E for patients with severe, uncontrolled asthma, *Ann. Allergy Asthma Immunol.* 120 (2018) 504–511, <https://doi.org/10.1016/j.ana.2018.01.030>.
- [27] P.W. Sullivan, V.H. Ghushchyan, G. Globe, M. Schatz, Oral corticosteroid exposure and adverse effects in asthmatic patients, *J. Allergy Clin. Immunol.* 141 (2018) 110–116, <https://doi.org/10.1016/j.jaci.2017.04.009>.
- [28] A.A. Dalal, M.S. Duh, L. Gozalo, M.N. Robitaille, F. Albers, S. Yancey, H. Ortega, M. Forshag, X. Lin, P. Lefebvre, Dose-response relationship between long-term systemic corticosteroid use and related complications in patients with severe asthma, *J. Manag. Care Spec. Pharm.* 22 (2016) 833–847, <https://doi.org/10.18553/jmcp.2016.22.7.833>.
- [29] L.P. Chung, J.W. Upham, P.G. Bardini, M. Hew, Rational oral corticosteroid use in adult severe asthma: a narrative review, *Respirology* 25 (2019) 161–172, <https://doi.org/10.1111/resp.13730>.
- [30] U.K. Asthma, Living in limbo: the scale of unmet need in difficult and severe asthma. <https://www.asthma.org.uk/69841483/globalassets/get-involved/external-affairs-campaigns/publications/living-in-limbo/living-in-limbo—the-scale-of-unmet-need-in-difficult-and-severe-asthma.pdf>, 2019. (Accessed 30 July 2021).
- [31] U.K. Asthma, Do no harm. Safer and better treatment options for people with asthma. https://www.asthma.org.uk/418cbc36/globalassets/campaigns/publications/severe-asthma_report_final.pdf, 2020. (Accessed 30 July 2021).

- [32] O. Matsuno, S. Minamoto, Eosinophils depletion therapy for severe asthma management following favorable response to mepolizumab, *Respir. Med. Case Rep.* 28 (2019) 100899, <https://doi.org/10.1016/j.rmcr.2019.100899>.
- [33] N. Drick, K. Milger, B. Seeliger, J. Fuge, S. Korn, R. Buhl, M. Schuhmann, F. Herth, B. Kendziora, J. Behr, N. Kneidinger, K.C. Bergmann, C. Taube, T. Welte, H. Suhling, Switch from IL-5 to IL-5-receptor α antibody treatment in severe eosinophilic asthma, *J. Asthma Allergy* 13 (2020) 605–614, <https://doi.org/10.2147/JAA.S270298>.
- [34] J.E. Kavanagh, A.P. Hearn, J. Dhariwal, G. d'Ancona, A. Douiri, C. Roxas, M. Fernandes, L. Green, L. Thomson, A.M. Nanzer, B.D. Kent, D.J. Jackson, Real-world effectiveness of benralizumab in severe eosinophilic asthma, *Chest* 159 (2021) 496–506, <https://doi.org/10.1016/j.chest.2020.08.2083>.
- [35] U.K. Asthma, Slipping through the net: the reality facing patients with difficult and severe asthma. <https://www.asthma.org.uk/6fc29048/globalassets/get-involved/external-affairs-campaigns/publications/severe-asthma-report/auk-severe-asthma-gh-final.pdf>, 2018. (Accessed 30 July 2021).