

To assess the feasibility and diagnostic accuracy of preoperative ultrasound and ultrasound-guided fine needle aspiration cytology of axillary lymph nodes in patients of breast carcinoma

Somendra P. Singh¹, Shashi P. Mishra², Vipin Gupta¹, Shailendra P. Singh¹, Poonam Gupta¹, Ram L. Verma¹, Nadeem Akram³

¹Department of Surgery, Uttar Pradesh University of Medical Sciences, Saifai, Etawah, Uttar Pradesh, ²Department of General Surgery, Institute of Medical Sciences, Banaras Hindu University, Varanasi, Uttar Pradesh, ³Department of Surgery, Integral Institute of Medical Sciences and Research, Lucknow, Uttar Pradesh, India

ABSTRACT

Background: Metastasis of the lymph node is one of the most significant prognostic factors for breast cancer (BC). **Aim:** To predict positivity of the lymph node in BC patients with help of USG and USG-guided FNAC and thus to prevent unnecessary morbidity. **Methods:** 50 patients of incisional/true cut biopsy-proven BC patients were included. All were subjected to mammography, USG and FNAC of the lump breast. USG-guided FNAC of the axillary lymph node was done in 25 of these patients. These findings were assessed by histological examination following dissection of the axillary lymph node. **Results:** Axillary lymph node (ALN) metastasis was present in 42 patients on histopathology; 21 patients suspicious of malignancy on preoperative USG were confirmed by HPE. Out of 88 confirmed lymph nodes evaluated on ultrasonography, 4 were benign, 18 were indeterminate and 66 were suspicious. The most promising features were tumour length/depth ratio of <1.5 in 81, absent fatty hilum in 73% and hypoechoic cortex in 74%. Assessment of axilla with USG had a sensitivity of 50%, a specificity of 100%, a PPV of 100%, an NPV of 27.59% and a diagnostic accuracy of 58%. Preoperative USG-guided FNAC had a sensitivity of 91.67%, a specificity of 100%, a PPV of 100%, an NPV of 33.33% and a diagnostic accuracy of 92%. **Conclusion:** USG can detect non-palpable axillary lymph nodes and FNAC can increase the sensitivity and specificity of this technique, which makes this procedure very promising in detecting axillary metastases in BC patients.

Keywords: Axillary lymph nodes, axillary metastasis, breast cancer, fine needle aspiration cytology, ultrasonography

Introduction

Breast cancer (BC) has been the focus of intensive study in relationship to its etiopathogenesis, early diagnosis, therapeutic

modalities and prognosis. BC is the most common site-specific cancer among women and the cause of cancer death among women aged 20–59 years.^[1] It represents 26% of all newly diagnosed female cancers and is responsible for 15% of deaths due to female cancer.^[2] A primary care physician or family physician is often the first person of contact for a patient with a breast lump and hence it is desired for a primary contact physician or family physician to remain aware of the basic diagnostic modalities for evaluation of a breast lump and to

Address for correspondence: Dr. Shashi P. Mishra,

Department of General Surgery, Institute of Medical Sciences, Banaras Hindu University, Varanasi, Uttar Pradesh - 221 005, India.
E-mail: sprakashsurgery@gmail.com

Received: 22-12-2020

Revised: 20-07-2021

Accepted: 30-07-2021

Published: 31-01-2022

Access this article online

Quick Response Code:



Website:
www.jfmpc.com

DOI:
10.4103/jfmpc.jfmpc_2521_20

This is an open access journal, and articles are distributed under the terms of the Creative Commons Attribution-NonCommercial-ShareAlike 4.0 License, which allows others to remix, tweak, and build upon the work non-commercially, as long as appropriate credit is given and the new creations are licensed under the identical terms.

For reprints contact: WKHLRPMedknow_reprints@wolterskluwer.com

How to cite this article: Singh SP, Mishra SP, Gupta V, Singh SP, Gupta P, Verma RL, *et al.* To assess the feasibility and diagnostic accuracy of preoperative ultrasound and ultrasound-guided fine needle aspiration cytology of axillary lymph nodes in patients of breast carcinoma J Family Med Prim Care 2022;11:133-8.

help in picking a malignant lump in early stages. In the current era, ultrasound is one of the most readily available diagnostic modalities available even in rural areas; hence, it can be used as an important modality for the above purpose. In BC, ALN status is a significant prognostic factor,^[3] and preoperative detection of lymph node metastasis is useful in determining the patient's choice of therapy and survival. Preoperative identification of lymph node metastasis is therefore essential when undertaking a reduction in lymphadenectomy or preparing induction chemotherapy.^[4] The axillary dissection for the removal of axillary tumour in patients with positive nodes has been found to be a key source of morbidity in patients with early-stage BC. Immediate complications include acute discomfort, need for hospitalisation, restricted range of movement and the need for one week or more drain in the surgical bed. Long-term complications that arise from axillary dissection include ipsilateral arm lymphedema, tingling, chronic pain and decreased motion range.^[5]

The sentinel node biopsy technique was then introduced in patients without visible axillary nodes in an attempt to reduce the morbidity associated with axillary procedure. In recent years, nodal staging has been replaced by sentinel lymph node biopsy for axillary lymph node (ALN) dissection.^[6-8] Sluggish or faulty delivery of radiotracers, longer procedural time and reporting capability of pathologist testing frozen sections are the challenges associated with SLNB. SLNB has 1%–15% false-negative findings, which lead to ALND not being done in cases with negative SLNB but who do have axillary metastases.^[9]

USG has become the most commonly used technique for lymph node assessment.^[10] Additionally, high diagnostic accuracy is achieved by preoperative USG lymph node staging and a guided biopsy.^[11,12]

Preoperative axillary ultrasound is used as feasible diagnostic criteria for assessing axillary node status, size, morphology, cortical thickness and vascularity. Of such criteria, the most accurate parameters for predicting metastatic lymph nodes are the L/D ratio, localised or eccentric cortical thickening, and absent or displaced fatty hilum on USG.^[13,14] USG can detect non-palpable axillary lymph nodes and its sensitivity can be improved by combining with FNAC. FNAC will increase the technique's specificity, making the procedure very promising for the detection of axillary metastases in BC patients. It can be used to lessen the need for the lymph node sentinel procedure.^[15]

The study, therefore, aims to predict the positivity of the lymph node in BC patients with the help of USG and USG-guided FNAC and thus to prevent unnecessary morbidity to the patients.

Methods

The proposal of this study was submitted and approved by the Institutional Ethical Committee. The duration of the study was around 18 months, from January 2017 to July 2018. The study protocol has been registered in the Clinical Trial Registry of India.

A total of 50 patients with incisional/true cut biopsy-proven BC admitted during the duration of the study were included. The study design is showed in Figure 1. This scientific work complies with the guidelines for reporting quality, formatting and reproducibility set out by the EQUATOR Network, and the manuscript was prepared in accordance with the STROBE Statement checklist.

The patients in the study were enrolled after informed and written consent. All the patients were subjected to triple assessment and were staged clinically. As protocol, written informed consent was taken at the beginning of the diagnostic procedures, i.e., mammography, USG and FNAC of the breast lump. If a single FNAC was inconclusive, a repeat FNAC was done. In cases where even a repeat FNAC did not yield any result, the patient underwent true cut biopsy and a definitive diagnosis was made before subjecting the patients to any operative procedure.

All the patients underwent USG of the breast and axilla. Additional time was allotted to obtain the axillary information in the form of the number of lymph nodes seen and individual lymph nodes were then assessed for their sonographic characteristics such as shape (round/oval), long and short axis measurements, presence or absence of fatty hilum and cortex for echogenicity (hypo/hyper). Depending on these sonographic characteristics, lymph nodes were categorised as benign (if lymph node show ratio of length to depth of >1.5 , with fatty hilum present and hyperechoic cortex), indeterminate (if ratio of length to depth was <1.5 or >1.5 with absence of fatty hilum or hyperechoic cortex) and suspicious (if ratio of length to depth was <1.5 with absence of fatty hilum and hypoechoic cortex).

The lymph nodes suspicious on USG were subjected to guided FNAC as well. Local anaesthesia was achieved using 2% lignocaine; thereafter, a 22-gauge needle attached to a 10-ml syringe was introduced in the similar direction as the local anaesthesia. Once the tip of the needle was confirmed in the abnormal region inside the lymph node (usually in the cortex) and aspiration was done with numerous back and forth movements

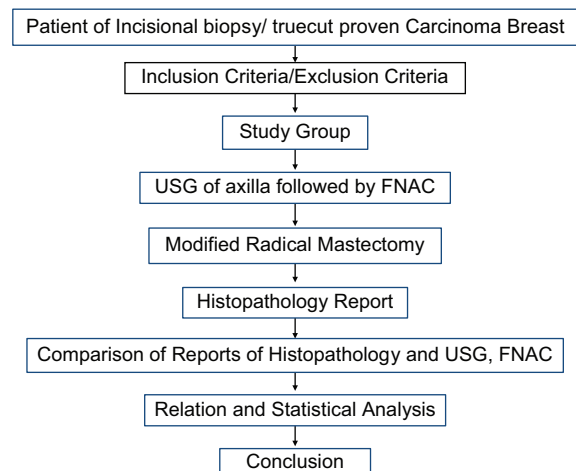


Figure 1: Study design

of the needle as suction was applied under continuous ultrasonic guidance. Multiple smears were then prepared from the aspirate obtained and were air-dried. Smear was then labelled and sent for cytopathological opinion.

After preoperative USG and USG-guided FNA, the patients were operated (modified radical mastectomy) and the specimens were sent for histopathological examination. The final pathology report from ALN dissection was obtained and then correlated with US-guided FNAC results.

Results

Our study included 50 patients with biopsy-proven BC, having a mean age of 45.48 ± 10.98 years (range: 23–75 years). Thirty-three of our patients were post-menopausal and 17 were pre-menopausal [Table 1]. Out of these patients, 13 patients had T1 clinical stage, 25 had T2 and 12 had T3 clinical stage. Thirty-one patients had involvement of left breast, for which left MRM was done, and the remaining had right MRM. On histopathological examination, the majority ($n = 49$) of patients had infiltrating ductal carcinoma and only one patient had adenocarcinoma; 42 patients had histologically proven ALN metastasis.

A total of 21 patients declared suspicious of malignancy on preoperative USG; all were confirmed to be having lymph nodal metastasis by HPE. Out of 88 confirmed lymph nodes evaluated on ultrasonography, 4 were benign, 18 were indeterminate and 66 were suspicious. The most promising features were the ratio of length to depth of <1.5 in 81, absent fatty hilum in 73% and hypoechoic cortex in 74% [Table 2].

A total of 29 patients were either reported benign, intermediate or the ones in which no axillary lymph nodes were seen preoperatively, whereas HPE confirmed 8 of them to be negative for axillary metastasis. Four patients were designated benign or intermediate and out of them, 3 were having lymph nodal metastasis [Table 3]. Therefore, the results of our study suggest that for assessment of axilla, ultrasound has a sensitivity of 50%, a specificity of 100%, a PPV of 100%, an NPV of 27.59% and a diagnostic accuracy of 58%.

Preoperative USG-guided FNAC of axilla performed in 25 patients showed metastasis on FNAC of axillary lymph nodes, which was also confirmed by histopathology, whereas 2 out of 3 patients declared benign on FNAC were found to be having lymph nodal metastasis [Table 4]. This suggests that ultrasound-guided FNAC of axillary lymph nodes has a sensitivity, specificity, PPV, NPV and diagnostic accuracy of 91.67%, 100%, 100%, 33.33% and 92%, respectively.

Discussion

The treatment strategy for this disease has undergone significant change starting from radical procedures to now a more conservative approach with regards to the breast as well as axilla.

Table 1: Demographic and clinical characteristics of patients

Parameter	Value
Characteristics	
Age, years (mean \pm SD) ($n=50$)	45.48 \pm 10.98 (range: 23-75)
Menopausal status ($n=50$)	
Pre-menopausal	17 (34.0)
Post-menopausal	33 (66.0)
Clinical staging ($n=50$)	
T1	13 (26.0)
T2	25 (50.0)
T3	12 (24.0)
Operation performed ($n=50$)	
Left MRM	31 (62.0)
Right MRM	19 (38.0)
Final histopathology ($n=50$)	
Infiltrating ductal carcinoma	49 (98.0)
Adenocarcinoma	1 (2.0)

Table 2: Ultrasonographic findings

USG features	No. of malignant lymph nodes ($n=88$)	Percentage
L/D Ratio		
<1.5	81	92.05
>1.5	7	7.95
Fatty hilum		
Present	15	17.05
Absent	73	82.95
Cortex echogenicity		
Hypoechoic cortex	74	84.09
Hyperechoic cortex	14	15.91
Inference		
Benign	4	4.55
Indeterminate	18	20.45
Suspicious to malignancy	66	75.0

Table 3: Correlation between axillary nodal status by US and histopathology finding ($n=50$)

	Histopathology Positive	Histopathology Negative
USG positive	21	0
USG negative	21	8

Table 4: Correlation between axillary nodal status by US-guided FNAC and histopathology finding ($n=25$)

	Histopathology Positive	Histopathology Negative
USG-guided FNAC positive	22	0
USG-guided FNAC negative	2	1

Management of axillary spread forms an integral part of this. We tried to keep one step further by studying the concept of sentinel node biopsy before doing axillary dissection through a newer approach by USG and USG-guided FNAC. We assessed the number of lymph node metastases before surgery by ultrasound of axilla and USG-guided FNAC of suspected axillary lymph

nodes and analysed them in a one-to-one correlation between preoperative and histological diagnosis.

The axillary lymph nodes also undergo changes over time; thus, the mode of analysis needs to be age-specific. Giuliano *et al.*^[17] described that the majority of patients were in the age range 45.48 + 10.9 years with a median age of 56.6 years. Another study by Bonnema *et al.*^[16] described the mean age as 57 years (range: 30–80 years), which is similar to our study. As BC is more prevalent in females, examination of male lymph nodes does not contribute to the findings of the analysis. Sasco *et al.*^[17] reported less than 1% incidence of BC in males, whereas in our study, all the patients were females.

Giuliano *et al.*^[17] reported a higher incidence of BC in post-menopausal women (58.9%), which increased further in those using hormone replacement therapy. In our study, the majority of patients (66%) were post-menopausal; out of them, 51.61% of patients showed axillary metastases.

Before surgery, we measured the number of lymph node metastases by ultrasound of axilla and USG-guided FNAC of suspected ALNs and analysed them in a one-to-one correlation between preoperative and histological diagnosis. There was an important association between the number of lymph node metastases identified prior to surgery and the histology.

In our study, the USG of axilla predicted lymph nodes in 25 out of 50 axillae. Out of which, 21 were designated suspicious of malignancy and 3 were designated benign, i.e. detected 42% of cases as malignant. Lymph nodes have been assessed for specific characteristics of the USG, such as L/D ratio, presence or absence of fatty hilum and echogenicity.

Out of the total 88 confirmed malignant lymph nodes evaluated, the most promising features were the ratio of length to depth of <1.5 seen in 81 (92.05%), absent fatty hilum seen in 73 (82.95%) followed by hypoechoic cortex in 74 (84.09%). Mainiero *et al.*^[18] found that the most predictive sonographic feature of a positive USG-guided FNA outcome was the absence of a fatty hilum. Bedi *et al.*^[19] suggested that the most predictive indicator of malignancy is the hypoechoic cortex with a focal cortical thickening. In a study by Dragoni *et al.*^[20], nodes were scanned in two planes, measuring the length (long axis) and the diameter (shortest axis). Again, a value of 2 was classified as the cut-off mark for the lymph nodes being benign. Yang *et al.*^[21] mentioned the mean L/W axis ratio in malignant nodes as being significantly lower than in benign nodes. Based on these particular USG features, lymph nodes were graded as positive, indeterminate and suspicious. USG labelled 4 (4.55%) lymph nodes as benign, 18 (20.45%) as indeterminate and 66 (75.0%) lymph nodes as suspect of malignancy in our study of 88 lymph nodes.

Kebudi *et al.*^[22] found that the sensitivity, specificity, PPV, NPV were 79.1%, 77.7%, 82.6% and 73.6%, respectively, for predicting axillary metastases in USG, while Yuko *et al.* found

a preoperative ultrasound accuracy of 79.7%. Jung Hee Shin *et al.*^[23] found 75% sensitivity, 82.6% specificity and 78.7% diagnostic accuracy of USG. However, the appearance of metastatic disease in the USG often overlaps with those of benign reactive changes, limiting its ability to stage the axilla accurately alone. So, FNAC was considered to improve the diagnostic performance of USG.

Couto *et al.*^[24] examined the diagnostic potential of USG in BC patients for ALN metastases. They achieved 71.4% sensitivity, 71.4% specificity, 80.6% NPV and 60.0% PPV. Using USG-guided FNAC from suspicious metastatic lymph nodes, the above findings have been further evaluated.

Total 572 lymph nodes were dissected; of these, 102 were found to be malignant on HPE in our study. These 102 lymph nodes were present in 42 patients who were hence positive for axillary metastasis, whereas 66 lymph nodes in 21 patients were suspicious on USG; all were confirmed by the HPE.

In our study, the evaluation of axilla by USG had 50% sensitivity, 100% specificity, 100% PPV, 27.59% NPV and 58% diagnostic accuracy. The sensitivity of 91.67%, specificity of 100%, PPV of 100%, NPV of 33.33% and diagnostic accuracy of 92% were achieved by adding USG-guided FNA. Alkuwari *et al.*^[25] found the overall sensitivity was 65% and the specificity was 100% for axillary lymph node FNA. In the sentinel lymph node group, the sensitivity of FNA was lower than that in the full lymph node dissection group (16% vs. 88%, respectively). Moore *et al.*^[26] stated in their study in 112 patients that for sonography alone, the overall sensitivity was 81% and the specificity was 69%. Adding FNA increased the specificity of USG to 100%, leaving the sensitivity unchanged (82%). Oz *et al.*^[27] studied preoperative axillary metastases with a USG-guided FNA biopsy. The sensitivity of USG-guided FNA biopsy was 88.46%; specificity was 100%, PPV was 100% and NPV was 66.6%.

The most common histological subtype found in the present study was infiltrating duct carcinoma in 98% of patients followed by adenocarcinoma (2%). Saxena *et al.*^[28] showed a higher proportion of invasive ductal carcinoma in 88.2% cases and invasive lobular carcinoma (ILC) in only 3.7% cases. Topps *et al.*^[29] reported that ILC metastases are assumed to be difficult to identify because cytologically the cells are small and resemble lymphocytes. Topps *et al.*^[29] stated that ILC metastases are thought to be difficult to detect because the cells are small and resemble lymphocytes on cytology. Thus, FNA biopsy of abnormal axillary nodes in the ILC group is clearly less sensitive.

USG can identify non-palpable axillary lymph nodes, and FNAC can enhance the sensitivity and specificity of this approach, making this approach very effective in identifying axillary metastases in BC patients.

Due to the obvious decreases in complications caused by the use of SLNB, there are different challenges in these patients

who no longer undergo complete ALND at the time of the definitive breast procedure and who are found to have a positive SLNB. Despite the advent of more accurate intraoperative SLN assessment tools, some patients still undergo SLNB followed by ALND at a later phase. Scar tissue and oedema can obstruct the detection of neurovascular structures in patients undergoing a second stage axillary procedure versus a single stage axillary procedure, leading to higher levels of complications. Thus, only those patients with benign or indeterminate characteristics of the lymph node on USG and with negative USG-guided FNAC of suspicious lymph nodes will require SLNB as the stage procedure. The majority of the patients who showed clear features of lymph node involvement on USG, and positive USG-guided FNA may perform ALND directly as part of primary breast surgery, thereby reducing the time and also avoiding SLNB-related morbidities as discussed above.

Chang J M *et al.*^[30] have also reported that in the setting of invasive BC, imaging of the axilla helps to determine the presence of metastatic disease with moderate accuracy, which is further improved with the use of US-guided biopsy of suspicious nodes.

Sun SX^[31] concluded that lymph node staging is a crucial step in the workup of patients with newly diagnosed invasive BC and that preoperative imaging of the axilla plays an important role in clinical staging.

Conclusion

Our data suggest that increasing the sensitivity of this technique will be very helpful in reducing the need for sentinel lymph node procedures. To sum up, axillary USG and USG-guided FNAC is a fast, non-morbid procedure of axillary staging in BC patients. This new procedure should be used as a staging procedure in BC patients and can be helpful in assessing the treatment option for particular patients and predicting their prognosis, which would save many patients from experiencing SLND and needless ALND.

The one-line message from this article can be that evaluation of axilla using ultrasound can be added as a routine part of work up in patients with BC.

Key points

1. Evaluation of axilla is a crucial step in the management of axilla in patients with BC.
2. Axillary USG and USG-guided FNAC is a fast, non-morbid procedure of axillary staging in BC patients.
3. Conscious use of this modality has potential to avoid unwarranted axillary intervention and thereby avoiding related comorbidities in BC patients.

Financial support and sponsorship

Nil.

Conflicts of interest

There are no conflicts of interest.

References

1. Sun YS, Zhao Z, Yang ZN, Xu F, Lu HJ, Zhu ZY, *et al.* Risk factors and preventions of breast cancer. *Int J Biol Sci* 2017;13:1387-97.
2. Ferlay J, Soerjomataram I, Ervik M. Cancer incidence and mortality worldwide: Sources, methods and major patterns in GLOBOCAN 2012. *Int J Cancer* 2015;136:359-86.
3. Carter CL, Allen C, Henson DE. Relation of tumour size, lymph node status and survival in 14,740 breast cancer cases. *Cancer* 1989;63:181-7.
4. Wolmark N, Wang J, Mamounas E, Bryant J, Fisher B. Preoperative chemotherapy in patients with operable breast cancer: Nine-year results from National Surgical Adjuvant Breast and Bowel Project B-18. *J Natl Cancer Inst Monogr* 2001;96:102. doi: 10.1093/oxfordjournals.jncimonographs.a003469.
5. Wernicke AG, Shamis M, Sidhu KK, Turner BC, Goltser Y, Khan I, *et al.* Complication rates in patients with negative axillary nodes 10 years after local breast radiotherapy after either sentinel lymph node dissection or axillary clearance. *Am J Clin Oncol* 2013;36:12-9.
6. Giuliano AE, Kirgan DM, Guenther JM, Morton DL. Lymphatic mapping and sentinel lymphadenectomy for breast cancer. *Ann Surg* 1994;220:391-8; discussion 398-401.
7. Giuliano AE, Jones RC, Brennan M, Statman R. Sentinel lymphadenectomy in breast cancer. *J Clin Oncol* 1997;15:2345-50.
8. Somasundaram SK, Chicken DW, Keshtgar MRS. Detection of the sentinel lymph node in breast cancer. *Br Med Bull* 2007;84:117-31.
9. Fraile M, Rull M, Julián FJ, Fusté F, Barnadas A, Llatjós M, *et al.* Sentinel node biopsy as a practical alternative to axillary lymph node dissection in breast cancer patients: An approach to its validity. *Ann Oncol* 2000;11:701-5.
10. Michel SCA, Keller TM, Fröhlich JM, Fink D, Caduff R, Seifert B, *et al.* Preoperative breast cancer staging: MR imaging of the axilla with ultrasmall superparamagnetic iron oxide enhancement. *Radiology* 2002;225:527-36.
11. Tate JJ, Lewis V, Archer T, Guyer PG, Royle GT, Taylor I. Ultrasound detection of axillary lymph node metastases in breast cancer. *Eur J Surg Oncol* 1989;15:139-41.
12. de Kanter AY, van Eijck CHJ, van Geel AN, Kruijt RH, Henzen SC, Paul MA, *et al.* Multicentre study of ultrasonographically guided axillary node biopsy in patients with breast cancer. *Br J Surg* 1999;86:1459-62.
13. Damera A, Evans AJ, Cornford EJ, Wilson ARM, Burrell HC, James JJ, *et al.* Diagnosis of axillary nodal metastases by ultrasound-guided core biopsy in primary operable breast cancer. *Br J Cancer* 2003;89:1310-3.
14. Abe H, Schmidt RA, Sennett CA, Shimauchi A, Newstead GM. US-guided core needle biopsy of axillary lymph nodes in patients with breast cancer: Why and how to do it. *Radiographics* 2007;27(Suppl 1):S91-9.
15. Deurloo EE, Tanis PJ, Gilhuijs KG, Muller SH, Kröger R, Peterse JL, *et al.* Reduction in number of sentinel lymph node procedure by preoperative ultrasonography of axilla in breast cancer. *Eur J Cancer* 2003;39:1068-73.

16. Yang WT, Metreweli C. Colour Doppler flow in normal axillary lymph nodes. *Br J Radiol* 1998;71:381-3.
17. Sasco AJ, Lowenfels AB, Pasker-de Jong P. Review article: Epidemiology of Male Breast Cancer. A meta-analysis of published case-control studies and discussion of selected etiological factors. *Int J Cancer* 1993;53:538-49.
18. Mainiero MB, Cinelli CM, Koelliker SL, Graves TA, Chung MA. Axillary ultrasound and fine-needle aspiration in the preoperative evaluation of the breast cancer patient: An algorithm based on tumor size and lymph node appearance. *AJR Am J Roentgenol* 2010;195:1261-7.
19. Bedi DG, Krishnamurthy R, Krishnamurthy S, Edeiken BS, Le-Petross H, Fornage BD, *et al.* Cortical morphologic features of axillary lymph nodes as a predictor of metastasis in breast cancer: *In vitro* sonographic study. *AJR Am J Roentgenol* 2008;191:646-52.
20. Dragoni F, Cartoni C, Pescarmona E, Chiarotti F, Puopolo M, Orsi E, *et al.* The role of high resolution pulsed and Colour Doppler Ultrasound in the differential diagnosis of benign and malignant lymphadenopathy. *Cancer* 2000;85:2485-90.
21. Yang WT, Chang J, Metreweli C. Patients with breast cancer: Differences in color Doppler flow and gray-scale US features of benign and malignant axillary lymph nodes. *Radiology* 2000;215:568-73.
22. Kebudi A, Caliřkan C, Yetkin G, Celebi S, Iřgör A, Mesrur Halefoęlu A, *et al.* The role of pre-operative B mode ultrasound in the evaluation of the axillary lymph node metastases in the initial staging of breast carcinoma. *Acta Chir Belg* 2005;105:511-4.
23. Shin JH, Hwang A, Choi HY, Baek SY. The value of ultrasonographic detection for metastatic axillary lymph nodes in breast cancer. *J Korean Radiol Soc* 2005 ;52:45-9.
24. Couto D, Dias M, Gonalo M, Pinto E, de Oliveira CF. Diagnostic value of ultrasound and colour Doppler in identifying axillary lymph node metastases in patients with breast cancer. *Eur J Gynaecol Oncol* 2004;25:568-70.
25. Alkuwari E, Auger M. Accuracy of fine-needle aspiration cytology of axillary lymph nodes in breast cancer patients: A study of 115 cases with cytologic-histologic correlation. *J Cancer* 2008;114:89-93.
26. Moore A, Hester M, Nam MW, Brill YM, McGrath P, Wright H, *et al.* Distinct lymph nodal sonographic characteristics in breast cancer patients at high risk for axillary metastases correlate with the final axillary stage. *Br J Radiol* 2008;81:630-6.
27. Oz A, Demirkazik FB, Akpınar MG, Soyğur I, Baykal A, Onder SC, *et al.* Efficiency of ultrasound and ultrasound-guided fine needle aspiration cytology in preoperative assessment of axillary lymph node metastases in breast cancer. *J Breast Cancer* 2012;15:211-7.
28. Saxena S, Rekhi B, Bansal A, Bagga A, Chintamani, Murthy NS. Clinico-morphological patterns of breast cancer including family history in a New Delhi hospital, India--A cross-sectional study. *World J Surg Oncol* 2005;3:67.
29. Topps A, Clay V, Absar M, Howe M, Lim Y, Johnson R, *et al.* The sensitivity of pre-operative axillary staging in breast cancer: Comparison of invasive lobular and ductal carcinoma. *Eur J Surg Oncol* 2014;40:813-7.
30. Chang JM, Leung JWT, Moy L, Ha SM, Moon WK. Axillary nodal evaluation in breast cancer: State of the Art. *Radiology* 2020;295:500-15.
31. Sun SX, Moseley TW, Kuerer HM, Yang WT. Imaging-based approach to axillary lymph node staging and sentinel lymph node biopsy in patients with breast cancer. *AJR Am J Roentgenol* 2020;214:249-58.