

Progressive Devascularization: A Novel Surgical Approach for Placenta Previa

Antonio F. Saad, MD¹ Nathan Kirsch, BS¹ George R. Saade, MD¹ Gary D. V. Hankins, MD¹

¹Division of Maternal-Fetal Medicine, Department of Obstetrics and Gynecology, The University of Texas Medical Branch at Galveston, Galveston, Texas

Address for correspondence Antonio F. Saad, MD, Division of Maternal-Fetal Medicine, Department of Obstetrics and Gynecology, The University of Texas Medical Branch at Galveston, 301 University Boulevard, Galveston, TX 77555-0587 (e-mail: afsaad@utmb.edu).

Am J Perinatol Rep 2018;8:e223–e226.

Abstract

Background The gold standard for antenatal diagnosis of placenta previa is the transvaginal ultrasonography. In placenta previa cases, separation of placental and uterine tissues is challenging even for the most experienced surgeons. Life-threatening obstetrical complications from cesarean deliveries with placenta previa include peripartum hemorrhage, coagulopathy, blood transfusion, peripartum hysterectomy, and multiple organ failure.

Cases We detailed the 3 cases of placenta previa that underwent bilateral uterine artery ligation; if hemostasis was not achieved, horizontal mattress sutures were placed in the lower uterine segment. All patients were discharged with minimal morbidity.

Conclusion For patients with placenta previa and low risk for placenta creta, counseling should include the risk for maternal morbidity and criteria for pursuing peripartum hysterectomy. Our devascularization, a stepwise surgical approach, shows promising outcomes in placenta previa cases.

Précis We propose a novel surgical approach, using a progressive devascularization surgical technique, for management of women with placenta previa, undergoing cesarean delivery.

Keywords

- ▶ previa
- ▶ devascularisation
- ▶ hemorrhage
- ▶ cesarean

The incidence of placenta previa ranges between 0.4 and 0.5% of all pregnancies.¹ Antenatal diagnosis of placenta previa is typically achieved via transvaginal ultrasound. Ultrasonography generally allows for appropriate planning, with the goal to reduce maternal morbidity and mortality. Placenta previa is defined as, when the placental edge covers the internal cervical os.² In uncomplicated pregnancies, hemostasis in a cesarean delivery is achieved through myometrial contraction, which leads to compression of spiral arteries. Women with placenta previa are at an increased risk of peripartum hemorrhage, which is believed to occur secondary to lack of contractile myometrium in the lower uterine segment, resulting in ineffective compression of the spiral arteries and insensitivity to standard administration of uterotonics. Management of uncomplicated placenta previa consists of delivery by cesarean between 36⁰ and 37⁶ weeks.³ In these cases, hemostasis is

generally attempted with the administration of standard medications, such as uterotonics, and with operative techniques, like balloon tamponade, uterine packing, compression sutures, and uterine artery embolization.⁴ Recently, hemostatic drugs, such as tranexamic acid and topical factor VII, have been suggested as promising therapeutic agents for obstetric hemorrhage.^{5,6}

In this manuscript, we describe a stepwise devascularization technique that we developed and achieved hemostasis in the 3 cases of placenta previa with minimal maternal comorbidities.

Cases

In the 3 cases chronicled below, we describe a novel surgical approach that may be applied to the cases of placenta previa

received
June 20, 2018
accepted after revision
June 29, 2018

DOI <https://doi.org/10.1055/s-0038-1673373>.
ISSN 2157-6998.

Copyright © 2018 by Thieme Medical Publishers, Inc., 333 Seventh Avenue, New York, NY 10001, USA.
Tel: +1(212) 584-4662.

License terms



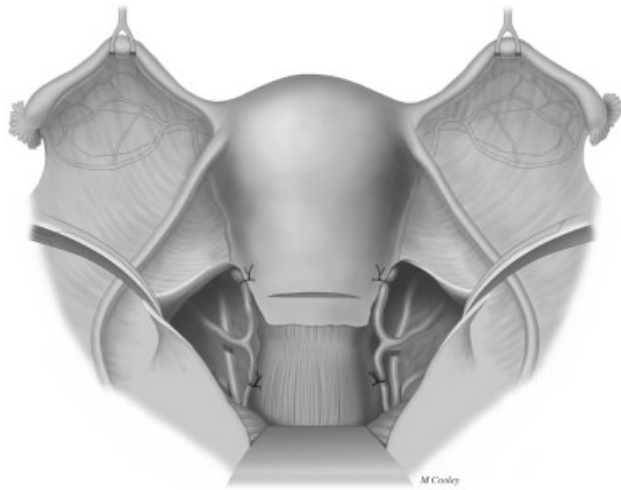


Fig. 1 Bilateral uterine artery ligation proximal/distal to the hysterotomy incision site.

(→Figs. 1–3). In each case, we performed a stepwise approach of surgical devascularization (→Table 1) that consists of bilateral uterine artery ligation, both proximal and distal to the uterine incision (→Fig. 1). If this procedure failed to achieve hemostasis, we ligated individual arterial bleeders in series with figure-of-eight sutures and then controlled the remaining brisk bleeding in the placental bed with transmural horizontal mattress sutures (→Figs. 2 and 3). The cases are summarized in →Table 2.

Case 1

A 29-year-old gravida (G) 5/para (P) 3/abortus (A) patient, with anterior complete placenta previa at 36 weeks of gestation, underwent a scheduled cesarean delivery under general anesthesia via a midline infraumbilical vertical skin incision through the anterior abdominal wall. The hysterotomy was performed via a low-transverse incision and extended laterally and cephalad via the Manu-Kerr technique. The amniotic cavity was entered with a spontaneous rupture of membranes, and the fetus was noted to be cephalic in presentation. The placenta was delivered through

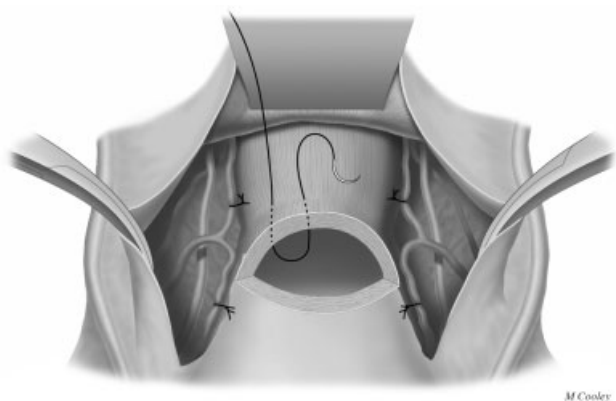


Fig. 2 Series of transmural horizontal mattress suturing over lower uterine segment below hysterotomy incision site.

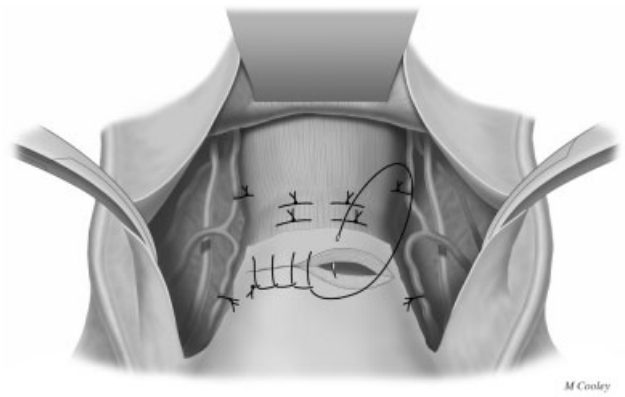


Fig. 3 Series of transmural horizontal mattress suturing over lower uterine segment below hysterotomy incision site.

manual extraction. Closure of the hysterotomy was complicated by lower uterine segment bleeding from the placental bed, requiring bilateral uterine artery ligation proximal and distal to the hysterotomy, ligation of arterial bleeders using figure-of-eight sutures, and transmural horizontal mattress sutures through the anterior surface of the cervix and the lower uterine segment to achieve hemostasis. Preoperatively, the patient’s hemoglobin level was 12.9 g/dL, and postoperatively her hemoglobin level was 6.9 g/dL. Intraoperative blood loss was estimated to be 2,000 mL.

The patient did not require any blood product transfusions during her hospital stay and was discharged on postoperative day (POD) #2, after receiving standard postpartum care with no complications.

Case 2

A 32-year-old G4/P2/A1 patient, at 34 weeks of gestation with anterior complete placenta previa, underwent a cesarean delivery under general anesthesia via an infraumbilical vertical skin incision through the anterior abdominal wall. The hysterotomy was performed via a low-transverse incision. The amniotic cavity was entered, and the fetus was noted to be in footling breech. The placenta was delivered through manual extraction. Upon closure of the hysterotomy,

Table 1 Stepwise approach for achieving hemostasis in patients with placenta previa undergoing cesarean delivery

Sequence of steps to progressive devascularization Indication: continued dwelling of blood from the placental insertion site ^a	
Step 1	Bilateral uterine artery ligation proximal / distal to the hysterotomy incision site
Step 2	Ligation of individual arterial bleeders using figure-of-eight technique
Step 3	Series of transmural horizontal mattress suturing over lower uterine segment below hysterotomy incision site

^aIf hemostasis is achieved at any point between steps 1 and 3 in the sequence, the sequence is terminated.

Table 2 Summary of cases

	Skin incision	Operative findings	Fetal presentation	Bleeding description	Hemostasis technique
Case 1	Midline infraumbilical vertical	Low-transverse hysterotomy	Cephalic	Lower uterine segment bleeding	Bilateral uterine artery ligation proximal and distal to the hysterotomy, ligation of arterial bleeders using the figure-of-eight sutures, and transmural horizontal mattress sutures through the anterior surface of the cervix and the lower uterine segment
Case 2	Midline infraumbilical vertical	Low-transverse hysterotomy	Footling breech	Uterine atony	Bilateral uterine artery ligation proximal and distal to the hysterotomy
Case 3	Low transverse	Low-transverse hysterotomy	Cephalic	Profuse bleeding from the anterior, inferior, and lower uterine segments bilaterally	Bilateral uterine artery ligation proximal and distal to the hysterotomy

brisk bleeding was noted, and a decision was made to perform a bilateral uterine artery ligation, proximal and distal, to the hysterotomy. Hemostasis was achieved and it was decided to proceed with further devascularization. Concomitant administration of uterotonics (methylergonovine and prostaglandin F_{2α}) was administered as well. Intraoperative blood loss was estimated to be 2,000 mL. The patient's preoperative hemoglobin level was 12.1 g/dL, and postoperatively her hemoglobin level was 8.9 g/dL.

The patient developed symptomatic anemia and opted to receive 1 unit of packed red blood cells postoperatively. The patient was discharged on POD #3 after receiving standard postpartum care with no complications.

Case 3

A 40-year-old G5/P4/A0 patient, at 36 weeks of gestation with anterior complete placenta previa, underwent a cesarean delivery under general anesthesia via a low-transverse skin incision through the anterior abdominal wall. The low-transverse incision was extended laterally and cephalad via the Manu-Kerr technique. The amniotic cavity was entered bluntly with an Allis clamp, and the fetus was noted to be cephalic. The placenta was delivered through manual extraction. Upon closure of the hysterotomy, profuse bleeding from the anterior, inferior, and lower uterine segments was noted, and a decision was made to perform a bilateral uterine artery ligation, proximal and distal, to the hysterotomy. Hemostasis was achieved and no further devascularization procedures were required. Intraoperative blood loss was estimated to be 2,000 mL. The patient's preoperative hemoglobin level was 12.1 g/dL, and postoperatively her hemoglobin level was 7.7 g/dL.

Postoperatively, the patient developed symptomatic anemia and opted to receive 2 units of packed red blood cells. The patient was discharged on POD #3, after receiving standard postpartum care with no complications.

On POD #15, the patient presented to the emergency department with yellow-mucoid wound discharge consistent with wound infection. The patient was prescribed a 7-day

course of antibiotics and instructed to follow up as an outpatient in 3 weeks.

Discussion

Placenta previa affects up to 5 out of every 1,000 pregnancies.⁷ It may be a major source of intrapartum morbidity and is often associated with profuse hemorrhage, intensive care unit admission, and peripartum hysterectomy.^{8,9} Nowadays, the diagnosis of placenta previa is mainly based on the transvaginal ultrasonography.² Ultrasound findings suggestive of placenta previa include placental edge above the cervical os; if the edge is within 2 cm of the cervical os, the term "low lying placenta" is used instead.

Antenatal diagnosis of placenta previa typically allows for adequate preoperative arrangements to be made, as an effort to reduce maternal morbidity. Patients should be counseled regarding potential complications, including third-trimester bleeding, need for cesarean delivery, intrapartum hemorrhage, abnormal placentation (3% and above), and the risk for peripartum hysterectomy. Patients with a history of prior cesarean deliveries should be informed that the increasing number of cesarean deliveries is associated with an increased risk of maternal comorbidities and complications¹⁰

The opinions expressed in the literature regarding other procedures using uterine compressive sutures, balloon tamponade, and uterine packing are highly variable.¹¹ The available evidence comes mainly from case reports and case series.¹¹ In some cases, selective arterial embolization has been reported. There are limited data as, which uterine conservative modality is superior.¹² Moreover, most of these cases involved severe cases of placenta accreta spectrum (PAS) disorders (percreta) and were later complicated by delayed hysterectomy, septic shock, and hemorrhage.¹³⁻¹⁶

Since in all three cases described, placenta removal was not easy (manual extraction was performed) and histological diagnosis for PAS disorders could not be obtained for obvious reasons, placenta creta could not be confirmed. Hence, it is

important to mention that the present described technique can be useful in such cases, especially when it is “focal”.

Our surgical approach seemed to carry little additional morbidity as compared with traditional management of placenta removal, tamponade, or other conservative strategies. We have used this approach in 3 patients and achieved hemostasis in each. For patients with placenta previa and a low risk for placenta creta, counseling should include the risk for maternal morbidity and criteria for pursuing a peripartum hysterectomy; it should also include our surgical approach. For clinicians who struggle to achieve hemostasis in these types of cases, we recommend consideration of our devascularization approach.

Conflict of Interest

The authors report no conflicts of interest.

References

- 1 Iyasu S, Saftlas AK, Rowley DL, Koonin LM, Lawson HW, Atrash HK. The epidemiology of placenta previa in the United States, 1979 through 1987. *Am J Obstet Gynecol* 1993;168(05):1424–1429
- 2 Reddy UM, Abuhamad AZ, Levine D, Saade GR. Fetal Imaging Workshop Invited Participants. Fetal imaging: executive summary of a joint Eunice Kennedy Shriver National Institute of Child Health and Human Development, Society for Maternal-Fetal Medicine, American Institute of Ultrasound in Medicine, American College of Obstetricians and Gynecologists, American College of Radiology, Society for Pediatric Radiology, and Society of Radiologists in Ultrasound Fetal Imaging workshop. *Obstet Gynecol* 2014;123(05):1070–1082
- 3 Spong CY, Mercer BM, D’alton M, Kilpatrick S, Blackwell S, Saade G. Timing of indicated late-preterm and early-term birth. *Obstet Gynecol* 2011;118(2, Pt 1):323–333
- 4 Ahonen J, Stefanovic V, Lassila R. Management of post-partum haemorrhage. *Acta Anaesthesiol Scand* 2010;54(10):1164–1178
- 5 WOMAN Trial Collaborators. Effect of early tranexamic acid administration on mortality, hysterectomy, and other morbidities in women with post-partum haemorrhage (WOMAN): an international, randomised, double-blind, placebo-controlled trial. *Lancet* 2017;389(10084):2105–2116
- 6 Schjoldager BTBG, Mikkelsen E, Lykke MR, et al. Topical application of recombinant activated factor VII during cesarean delivery for placenta previa. *Am J Obstet Gynecol* 2017;216(06):608.e1–608.e5
- 7 Faiz AS, Ananth CV. Etiology and risk factors for placenta previa: an overview and meta-analysis of observational studies. *J Matern Fetal Neonatal Med* 2003;13(03):175–190
- 8 Robinson BK, Grobman WA. Effectiveness of timing strategies for delivery of individuals with placenta previa and accreta. *Obstet Gynecol* 2010;116(04):835–842
- 9 Frederiksen MC, Glassenberg R, Stika CS. Placenta previa: a 22-year analysis. *Am J Obstet Gynecol* 1999;180(6, Pt 1):1432–1437
- 10 Grobman WA, Gersnoviez R, Landon MB, et al, National Institute of Child Health and Human Development (NICHD) Maternal-Fetal Medicine Units (MFMU) Network. Pregnancy outcomes for women with placenta previa in relation to the number of prior cesarean deliveries. *Obstet Gynecol* 2007;110(06):1249–1255
- 11 Montufar-Rueda C, Rodriguez L, Jarquin JD, et al. Severe postpartum hemorrhage from uterine atony: a multicentric study. *J Pregnancy* 2013;2013:525914
- 12 Steins Bisschop CN, Schaap TP, Vogelvang TE, Scholten PC. Invasive placentation and uterus preserving treatment modalities: a systematic review. *Arch Gynecol Obstet* 2011;284(02):491–502
- 13 Alkazaleh F, Geary M, Kingdom J, Kachura JR, Windrim R. Elective non-removal of the placenta and prophylactic uterine artery embolization postpartum as a diagnostic imaging approach for the management of placenta percreta: a case report. *J Obstet Gynaecol Can* 2004;26(08):743–746
- 14 Butt K, Gagnon A, Delisle MF. Failure of methotrexate and internal iliac balloon catheterization to manage placenta percreta. *Obstet Gynecol* 2002;99(06):981–982
- 15 Teo SB, Kanagalingam D, Tan HK, Tan LK. Massive postpartum haemorrhage after uterus-conserving surgery in placenta percreta: the danger of the partial placenta percreta. *BJOG* 2008;115(06):789–792
- 16 Dinkel HP, Dürig P, Schnatterbeck P, Triller J. Percutaneous treatment of placenta percreta using coil embolization. *J Endovasc Ther* 2003;10(01):158–162