

## Review

**Clinical review: Percutaneous dilatational tracheostomy**Mariam A Al-Ansari<sup>1</sup> and Mohammed H Hijazi<sup>2</sup><sup>1</sup>Consultant Intensivist, Salmaniya Medical Complex, Ministry of Health, Manama, Kingdom of Bahrain<sup>2</sup>Assistant Professor of Medicine, Consultant Intensivist, Section of Critical Care Medicine, Department of Medicine, King Faisal Specialist Hospital and Research Centre, Riyadh, Kingdom of Saudi ArabiaCorresponding author: Mariam A Al-Ansari, [dr\\_mariam5@hotmail.com](mailto:dr_mariam5@hotmail.com)

Published: 26 October 2005

This article is online at <http://ccforum.com/content/10/1/202>

© 2005 BioMed Central Ltd

*Critical Care* 2006, **10**:202 (doi:10.1186/cc3900X)**Abstract**

As the number of critically ill patients requiring tracheotomy for prolonged ventilation has increased, the demand for a procedural alternative to the surgical tracheostomy (ST) has also emerged. Since its introduction, percutaneous dilatational tracheostomies (PDT) have gained increasing popularity. The most commonly cited advantages are the ease of the familiar technique and the ability to perform the procedure at the bedside. It is now considered a viable alternative to (ST) in the intensive care unit. Evaluation of PDT procedural modifications will require evaluation in randomized clinical trials. Regardless of the PDT technique, meticulous preoperative and postoperative management are necessary to maintain the excellent safety record of PDT.

**Introduction**

Tracheostomy is one of the oldest surgical procedures, described in ancient books of medicine [1]. The standard operative tracheostomy technique presented by Jackson [2] remains little changed more than 100 years on. Several tracheostomy techniques have been described as percutaneous [3,4]. A technique of performing percutaneous dilatational tracheostomy (PDT) over a guidewire was first described by Ciaglia in 1985. It is increasingly being performed in intensive care units (ICUs) at the bedside. The Ciaglia technique, including its modifications, has become the most widely used procedure for the performance of PDT.

In the first part of this review we consider general issues related to PDT. In the second section we focus on evidence-based recommendations, using the best available evidence, regarding issues such as modifications to PDT procedures designed to enhance patient safety and timing of performance in the ICU [5]. We conducted searches of Medline, the National Electronic Library for Health, the Cochrane Database of Systematic Reviews and the TRIP Database for reports published between 1985 and 2005, using the following key words: 'percutaneous', 'tracheostomy'

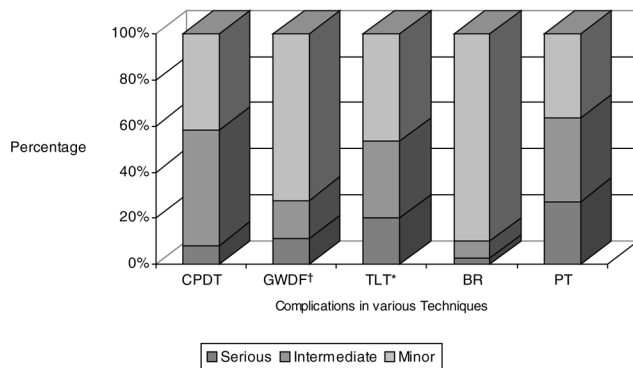
and 'intensive care units'. Evidence is weighted according to the following rating scheme: A = scientific evidence provided by randomized and nonrandomized trials with statistically significant results; B = scientific evidence provided by observational studies or by controlled trials; and C = expert opinion with lack of scientific evidence.

**Percutaneous dilatational tracheostomy techniques**

Various types of PDT techniques are available. They all require puncture of the trachea and insertion of a guidewire into the trachea. The puncture should be performed between the first and second or between the third and fourth tracheal rings. There is some evidence that a puncture between the third and fourth tracheal rings is associated with the lowest rate of accidental injury to aberrant vessels and other structures if there are anatomical abnormalities [6]. In most techniques the guidewire is then advanced toward the carina; however, in the Fantoni translaryngeal tracheostomy (TLT) method the guidewire is fed upward through the vocal cords. The Ciaglia method uses increasing sizes of hydrophilic coated dilators, ultimately allowing the tracheal cannula to be inserted into the trachea.

Since Ciaglia's first report [5], the technique has undergone three major modifications: the tracheal interspace for cannulation has been moved one or two tracheal interspaces caudal from the cricoid cartilage; routine use of video fiberoptic bronchoscopy has been advocated; and a single, bevelled and curved dilator (Blue Rhino) has been substituted for multiple dilators. In a prospective, randomized trial of trauma patients [7] use of a single dilator was compared with multiple dilators in PDT. There were no major complications with either technique. The single-step dilator has the advantage of not requiring a change in dilator, thereby reducing tidal volume loss until the tracheostomy tube is ready to be inserted.

COPA = cuffed oropharyngeal airway; ETT = endotracheal tube; ICU = intensive care unit; LMA = laryngeal mask airway; PDT = percutaneous dilatational tracheostomy; PEEP = positive end-expiratory pressure; TLT = translaryngeal tracheostomy.

**Figure 1**

A comparison of perioperative complications with five different PDT techniques. \* $P < 0.05$  versus any other technique; † $P < 0.05$  versus PDT, TLT and BR. BR, Blue Rhino; CPDT, Ciaglia's percutaneous dilatational tracheostomy; GWDF, guidewire dilating forceps; TLT, translaryngeal tracheostomy; PDT, percutaneous dilatational tracheostomy; PT, PercuTwist technique.

A technique described by Griggs and coworkers in 1990 [8] uses a specially designed forceps (grooved Howard-Kelly forceps), in which the guidewire passes through a hole in the tip of the closed forceps, thus leading them in the right direction. Spreading the forceps dilates the trachea to the point at which the chosen cannula can be inserted. Nates and coworkers [9] and Van Heurn and colleagues [10] reported that the Ciaglia PDT technique was associated with a significantly lower rate of complications than was the technique proposed by Griggs.

Finally, the TLT method is a pure dilatational and bronchoscopically visualized method of PDT. It uses a specially designed cannula that consists of a flexible plastic cone with a pointed metal tip at its end to dilate the trachea from its lumen outward to the skin, which allows less tissue trauma and enhances safety. The guidewire in this case is not only used to guide a tool but also to dilate the stoma. After dilatation the cannula must be turned toward the carina using a specially designed obturator. Its indications include cases in which PDT may be difficult, such as patients with short and thick necks.

Frova and Quintel [11] recently described another PDT technique. Their new technique requires the use of a single-step screw-type dilator (PercuTwist; Rüschi, Kern, Germany). The device is a dilator that is threaded into the tracheal stoma using a lifting motion. In the preliminary study reported by Frova and Quintel, there was no significant bleeding or other relevant procedure-related complications.

At the Annual Meeting of the American Society of Anesthesiology in 2003, Byhahn and coworkers [12] presented their findings (in abstract form) from a descriptive study of five PDT techniques in terms of perioperative

complications over a 5-year period (Fig. 1). A total of 144 complications were observed (overall complication rate: 23.5%). All tracheostomies were performed by the same team at the patient's bedside in the ICU. Based on their data, TLT and Blue Rhino are equally safe PDT techniques for use in the ICU. Because of its technical simplicity compared with TLT, the Blue Rhino method was recommended as the technique of choice.

### Advantages of percutaneous dilatational tracheostomy techniques

The main advantage of PDT is the ability to perform it at the bedside in the ICU, thus avoiding a potentially hazardous transfer of critically ill patients to the operating room. Although surgical tracheostomy can be performed at bedside (overcoming the transport risk), the savings in cost are lost by using operating room personnel and equipment in the ICU. Because PDT is a bedside procedure, it avoids the inconvenience of long waiting lists for operating room scheduling. With PDT there is a shorter delay between the time a decision is made to perform a tracheostomy and the time of the actual procedure [13]. PDT has been shown to reduce significantly the cost of tracheostomy compared with surgical tracheostomy (US\$1569 ± 157 for PDT versus US\$3172 ± 114 for surgical tracheostomy) [14]. This is predominantly a result of avoiding operating room charges. Further cost reductions may be attained by eliminating the routine use of flexible bronchoscopy during the performance of PDT. In our hospital the waiting time for a surgical tracheostomy can extend for up to 1 week, costing about US\$1000/week to US\$7500/week for an unnecessary ICU stay.

Other advantages of PDT pertain to the different operative techniques applied in PDT versus surgical tracheostomy. The incision in PDT is small, the tracheostomy tube is fitted tightly against the stoma, and less dissection and damage to tissue occur. These advantages are probably responsible for the favourable outcomes described in short-term and long-term follow-up studies of patients undergoing PDT [15-17], including fewer wound complications (such as bleeding and infection) and an aesthetically more favourable scar.

### Disadvantages of percutaneous dilatational tracheostomy techniques

Complications of PDT, including bleeding, infection and hypoxia, are infrequent. Most are minor, with no serious sequelae. Kearney and associates [18] examined the complications of 827 PDT procedures performed over 8 years. The mortality rate was 0.6% and the perioperative complication rate was 6%, with premature extubation being the most common problem. Early postoperative complications occurred in 5% of patients, with bleeding being the most common. Tracheal stenosis was seen in only 1.6% of patients who survived their ICU stay and were subsequently decannulated (average follow up: 461 days). This incidence of complications compares favourably with that with modern

surgical tracheostomy [19]. PDT is a closed procedure and has unique risks that are not encountered with surgical tracheostomy, including paratracheal insertion of the tracheostomy tube and posterolateral tracheal wall laceration. However, the rate of these complications is low and death rarely occurs. Lin and coworkers [20] reviewed 134 cases of PDT retrospectively and found three cases of extensive posterolateral longitudinal tracheal laceration; all were managed successfully with surgical repair.

Our hospital experience with PDT is similar to that presented in many previously published papers [21]. A retrospective review of PDT procedures over 20 months (June 2002 to January 2004) identified 52 cases, in which there were only four reported complications (minor bleeding); there were no deaths. All procedures were conducted using bronchoscopic guidance.

### **Conditions in which surgical tracheostomy may be safer than percutaneous dilatational tracheostomy**

The following are situations in which an inexperienced physician might feel that it is safer to conduct a surgical tracheostomy than a PDT: emergency tracheostomy tube placement; anatomical landmarks that are difficult to palpate (very obese, short or bull neck, enlarged thyroid, nonpalpable cricoid cartilage, or gross deviation of the trachea); and malignancy at the site of tracheostomy.

### **Areas requiring special considerations**

#### **Cervical spine clearance**

Inability to extend the neck because of lack of cervical spine clearance is considered a relative contraindication to PDT. A success rate of 96% and complication rate of 7.1% were reported in a case series of 28 patients without cervical spine clearance who underwent PDT [22]. In another series 16 patients with anterior cervical fusions following spinal cord injury were randomly assigned to undergo surgical tracheostomy or ultrasound-guided PDT [23]. In terms of complications, ultrasound-guided PDT was as safe as surgical tracheostomy, and it was much quicker.

#### **Obesity**

In morbidly obese patients, difficult airway management, obscured surface landmarks and requirement for tracheostomy tubes not designed for PDT may make the procedure problematic. Byhahn and coworkers [24] studied the safety of percutaneous tracheostomy in 73 obese patients (body mass index  $27.5 \text{ kg/m}^2$ ) in a cohort of 474 adults. They were found to be at 2.7-fold increased risk for perioperative complications and had a 4.9-fold increased risk for serious complications. Mansharamani and colleagues [25] performed PDT in 13 consecutive patients with a body mass index of  $28\text{--}62 \text{ kg/m}^2$ . In their prospective study, a vertical skin incision was used to allow for the changed level of entry into the trachea without need for reincision, followed by blunt dissection of the tissues to the level of the trachea. The cricoid

cartilage and tracheal rings were then identified by palpation, the needle was inserted followed by guidewire placement, and the stoma dilated. Routinely, a modified tracheostomy tube with extra horizontal length was placed to accommodate the difference in anatomy (thick subcutaneous tissue). All procedures were performed with anaesthesia standby at the bedside. This study confirmed that anatomical landmarks in most obese patients are not difficult to identify and can be discerned with adequate neck flexion. Coatesworth [26] described a technique in which a standard endotracheal tube (ETT) may be used as a long tracheostomy tube in patients with large necks. The technique is recommended because it is cheap, simple, safe and potentially life saving.

#### **Previous tracheostomy**

Previous tracheostomy has long been considered a contraindication in patients who require a new tracheostomy [27]. This is also included in the guidelines from many of the tracheostomy tube manufacturers. Again, there are no published data to support this. Several case reports have described the successful placement of PDT in patients with a partially closed site. The largest was that performed by Meyer and coworkers [28], in which PDT was performed in 14 consecutive patients who had undergone previous tracheostomy. In all patients the stoma had healed completely without any identifiable opening. The previous scar was excised and the needle was placed through the tracheal defect, followed by dilatation and tracheostomy tube placement. There were no complications and the procedure was judged to be technically simple in all patients. This report encourages performance of PDT in patients who have previously undergone tracheostomy. Many authors believe that it is an attractive alternative to the open surgical procedure because of its technical simplicity [29].

#### **Hypoxic respiratory failure**

Beiderlinden and coworkers [30] compared the impact of bronchoscopically guided PDT on oxygenation in 88 patients with hypoxic respiratory failure requiring high positive end-expiratory pressure (PEEP) ( $>10 \text{ cmH}_2\text{O}$ ) with that in 115 patients with low PEEP requirement ( $<10 \text{ cmH}_2\text{O}$ ). Bronchoscopically guided PDT in patients requiring high PEEP did not jeopardize oxygenation 1 hour and 24 hours after the procedure. Accordingly, those investigators did not believe that high PEEP requirement and hypoxic respiratory failure should be considered a contraindication for PDT. Shah and Morgan [31] were able to perform PDT safely in five patients with acute respiratory distress syndrome during high-frequency oscillatory ventilation.

#### **Severe thrombocytopenia**

Severe thrombocytopenia has been described as a contraindication to PDT. Kluge and coworkers [32] assessed the safety of PDT in mechanically ventilated patients with severe thrombocytopenia (platelet count  $<50 \times 10^9 \text{ cells/l}$ ) in a retrospective, single-centre cohort study (grade B

**Table 1**

**Summary of trials comparing surgical tracheostomy and PDT in intensive care patients**

Study characteristics/findings	Procedure	
	Standard tracheostomy	PDT
Total number of patients (n)	260	272
Procedural time (min; range [mean])	4.3–41 (23)	6.5–25 (15)
Complications (n)	54	18
Cases of significant bleeding (n)	6	4
Infections (n)	19	10
Deaths related to the procedure (n)	4	2

Shown is a summary of eight prospective randomized controlled clinical trials comparing surgical tracheostomy and PDT in the intensive care unit setting from 1999 to 2002 [39]. PDT, percutaneous dilatational tracheostomy.

evidence). They concluded that bronchoscopically guided PDT has a low complication rate when it is performed by experienced ICU medical staff; when platelet transfusions are given before the procedure; and when heparin therapy, even in those patients at very high risk for thromboembolic events, is temporarily interrupted during the procedure. Few other studies and case reports support these findings.

**Emergency percutaneous dilatational tracheostomy**

In the early reports, most authors considered the need for emergency airway management an absolute contraindication to PDT. In our opinion, this recommendation remains appropriate for those lacking experience. Gradually, the contraindications to PDT have expanded. Several recent case series [33-36] reported on the feasibility and safety of emergency PDT in experienced hands (grade C evidence).

**Percutaneous dilatational tracheostomy in a residency program**

Donaldson and coworkers [37] studied complication rates and outcomes of PDT after its introduction in an otolaryngology residency teaching program. A total of 54 consecutive PDTs were reviewed retrospectively and compared with 29 consecutive standard open tracheostomies. Complications, operative time and total procedure time were significantly reduced in the PDT group as compared with the standard tracheostomy group (grade B). Gardiner and colleagues [38] reported on the role of surgical simulation (using pig) in providing an opportunity to practise the PDT procedure without placing patients at risk.

**Comparison of percutaneous dilatational tracheostomy and surgical tracheostomy**

When significant clinical end-points are considered, PDT is a cost-effective and safe alternative to surgical tracheostomy in

**Table 2**

**Complications: surgical tracheostomy versus PDT**

Complications	OR (95% CI)
Perioperative bleeding	0.14 (0.02–0.39)
All postoperative complication	0.15 (0.07–0.29)
Stomal infection	0.02 (0.01–0.07)

Shown is a summary of risks for developing a complication in surgical tracheostomy versus PDT [40]. CI, confidence interval; OR, odds ratio; PDT, percutaneous dilatational tracheostomy.

critically ill patients in the ICU when it is performed by skilled and experienced practitioners. Important advantages of PDT may include eliminating the need for operating room facilities and personnel by performing the procedure at the bedside, and significantly decreasing the delay between the decision to perform tracheostomy and the actual procedure.

Table 1 provides a summary of eight prospective randomized controlled clinical trials comparing surgical tracheostomy and PDT in an ICU setting from 1999 to 2002 (grade A) [39]. Freeman and coworkers [40] conducted another meta-analysis of five prospective controlled studies (236 patients) comparing PDT and surgical tracheostomy in critically ill patients (grade A evidence; Table 2). No difference was identified in days intubated before tracheostomy, overall procedure-related complications, or death. Wu and colleagues [41] found no impact of age, sex, or days of intubation before tracheostomy in terms of complications.

Dulguerov and coworkers [42], in their meta-analysis, were unable to corroborate the positive findings summarized above. Both the report by Freeman and coworkers [40] and that by Dulguerov and colleagues [42] were meta-analyses, so how could such different conclusions have been drawn by the two groups? The conclusions reached in meta-analytical studies are completely dependent on the quality of the data analyzed. Dulguerov and coworkers included both prospective and observational studies, utilizing several PDT techniques. In contrast, Freeman and colleagues analyzed only prospective studies that employed the Ciaglia procedure. This renders the latter analysis more sound.

Multiple prospective trials have arrived at conclusions similar to those drawn by Freeman and coworkers (grade B) are present. The report by Melloni and coworkers [43] is of particular interest because their trial was not only prospective but also randomized, and evaluated long-term follow up. The authors concluded that PDT is simpler and quicker than surgical tracheostomy, and that it has a lower rate of postoperative complications. They found that late tracheal complications were more prevalent in the PDT group, but these did not reach statistical significance.



## Use of adjuncts

### Preoperative ultrasound

Ultrasound of the neck may identify structures at risk for haemorrhage, such as aberrant blood vessels [44]. It may be particularly useful before PDT is undertaken in selected patients with variant arterial anatomy [45]. Bleeding was attributed to vessels that could be imaged by ultrasound in four cases out of 497 PDT procedures in which the vessels were neither visible nor palpable on physical examination [46]. Kollig and coworkers [47] performed PDT in 72 ICU patients as a bedside procedure using initial ultrasound of the neck followed by bronchoscopy. Based on prior ultrasound findings, the site of tracheal puncture had to be changed in 24% of patients. There were no cases of miscannulation, penetration of the posterior tracheal wall, or major bleeding requiring intervention or conversion. However, randomized clinical trials are required before evidence-based recommendations for routine ultrasound before PDT may be made.

### Bronchoscopy

Bronchoscopy may provide certain benefits, such as confirmation of needle placement, dilatation and tube placement. No study has yet examined whether the addition of bronchoscopy leads to a decrease in procedural complications. On the other hand, several reports on the use of bronchoscopy raised concern about potential unwanted side effects.

Measurable increases in intracranial pressure may be noted with bronchoscopic guidance due to increase in partial carbon dioxide tension [48]. In susceptible individuals partial oxygen tension may decrease, leading to derecruitment.

The two most commonly quoted studies advocating the use of endoscopy are those reported by Barba [49] and Marelli [50] and their groups. These studies were not designed to assess the impact of bronchoscopy, because all PDT patients underwent endoscopy. Despite this, general use of bronchoscopy was still recommended. In a further two comparative studies [51,52], no significant differences in terms of major complications could be found. More recently, Paran and coworkers [53] found that a modified PDT technique (in which the subcutaneous tissue is bluntly dissected using a haemostat down to the pretracheal fascia), without routine bronchoscopy, is simple and safe. We have recently been conducting PDT without bronchoscopy, and thus far there have been no complications (neither major nor minor) in about 100 cases managed (unpublished data).

### Use of laryngeal mask airway to maintain ventilation during percutaneous dilatational tracheostomy

Inadvertent puncture of the ETT cuff and accidental tracheal extubation are potentially life-threatening complications that may occur during PDT. As an alternative to ETT, the laryngeal mask airway (LMA) has been used. Ambesh and coworkers [54] randomly allocated patients to two groups of 30 each

(receiving controlled ventilation of lungs either through ETT or LMA; grade A). Potentially catastrophic complications (e.g. loss of airway, inadequate ventilation of lungs leading to significant hypoxia, gastric distension and regurgitation) occurred in 33% of patients in the LMA group, rendering some patients at considerable risk for hypoxia and gastric regurgitation/aspiration. In the ETT group cuff puncture occurred in 6.6% and accidental tracheal extubation in 3.3%, making the ETT technique basically safe.

In another prospective, randomized clinical trial, Dosemeci and coworkers [55] evaluated the safety and efficiency of the use of LMA during PDT under bronchoscopic guidance compared with ventilation via ETT (grade A). Hypercapnia was noted in 38.5% in the LMA group and 56.7% in the ETT group. The decrease in pH related to hypercapnia was noted in both groups, but it was more significant in the ETT group ( $P < 0.05$ ). Those investigators concluded that, because of better visualization of the trachea and larynx during fiberoptically assisted PDT, LMA could represent an effective and valuable ventilatory device during PDT. It prevents the difficulties associated with the use of ETTs, such as cuff puncture, tube transection by the needle and accidental extubation.

We believe that the applicability and safety of the LMA in ICU patients, some of whom require high degrees of ventilatory support, are questionable. With the evidence currently available, one cannot draw a firm conclusion.

In a meeting abstract, Kahveci and coworkers [56] reported the result of their prospective randomized study conducted to compare use of the cuffed oropharyngeal airway (COPA) and LMA devices during PDT to maintain ventilation (grade A). Either a COPA or a LMA device was inserted before PDT after administering propofol, fentanyl and mivacurium anaesthesia in a total of 47 patients. If patent airway could not be provided, then the devices were removed and endotracheal intubation was performed. Both COPA and LMA were inserted simply and with a high rate of success, but airway manipulations (such as chin lift) to maintain a patent airway were more frequently required in the COPA group.

### Use of capnography versus bronchoscopy during percutaneous tracheostomy

A crucial step toward successful percutaneous tracheostomy is the introduction of the needle and guidewire into the trachea. Capnography was recently proposed as one way to confirm tracheal needle placement. In their randomized controlled study, Mallick and coworkers [57] used capnography in 26 patients and bronchoscopy in 29 patients to confirm needle placement for percutaneous tracheostomy using the Blue Rhino kit (grade A). The operating times and the incidence of perioperative complications were similar for both groups. Capnography proved to be as effective as bronchoscopy in confirming correct needle placement.

**Table 3**

**Early and late post-PDT complications and management**

Period	Complication	Management	Prevention
Early (days 1–7)	Paratracheal placement and posterior wall injury (ventilation problems and high pressure alarms)	Reposition the tube	Avoid excessively deep introduction of the dilator into the airway, excessive downward force when advancing the tracheostomy-loaded dilator, and maintaining a flush fit of the tracheostomy tube to the dilator
	Malpositioned tubes causing airway obstruction (possible with tapered percutaneous tube tips) manifests as pressure alarms or acute dyspnoea and may be indistinguishable from mucus plugging (ventilation problems and high pressure alarms)	Exchanging the tube for another with a blunt tip opening	Rotation of the tube to bring the distal tip away from contact with the tracheal wall
	Pneumothorax; errant needle puncture and barotrauma due to alveolar overdistention during the procedure are the most common causes	Immediate tube thoracostomy	–
	Subcutaneous emphysema	Typically disappears within 24 hours	–
	Bleeding (minor venous oozing)	Increased frequency of dressing changes; if bleeding persists, then silver nitrate can be applied to the wound edge for chemical cauterization	Preoperative correction of coagulopathy, and careful identification and control of bleeding points during the procedure; avoid overdistention and creation of large stoma
Late (beyond day 7)	Subglottic stenosis	Interventional bronchoscopic techniques (cryoprobe therapy, Nd:YAG and argon plasma coagulation)	Maintain cuff pressure <30 cmH <sub>2</sub> O
	Unplanned decannulation	Keep decannulated or replace the tube. If airway is needed urgently, then perform immediate translaryngeal intubation. If there is no urgent need to secure the airway then the tracheostomy tube may either be guided into the trachea by bronchoscopically observing the introduction from a translaryngeal vantage point, or the scope itself may be used as an introducer	Careful patient mobilization
	Stomal infection	–	Limited disruption of tissue and minimal bleeding
	Infections of lower respiratory tract	Early appropriate antibiotic	Early tracheostomy when indicated; reduction in bacterial colonization (aggressive aseptic tracheostomy care, proper nutrition, early treatment of infections)

Data from Wright and VanDahm [59]. PDT, percutaneous dilatational tracheostomy.

**Routine chest radiography after percutaneous dilatational tracheostomy**

Current practice after PDT is to conduct chest radiography to rule out complications such as pneumothorax or tube malposition. The utility of chest radiography after PDT was recently evaluated by Hoehne and coworkers [58]. A retrospective chart review was conducted in patients who

had undergone PDT between January 1999 and December 2003 (grade B). Seventy-three charts were reviewed for clinical outcome as well as the radiologist’s interpretation of the postprocedure chest radiograph. There were no complications identified on postprocedure chest radiography. The investigators concluded that routine chest radiography after PDT is unnecessary.

## Early and late problems after percutaneous dilatational tracheostomy and their management

Tracheostomy aftercare is divided into early and late periods. The early period is somewhat arbitrarily defined as days 1–7 [59]. Late period designation is based on a 'mature' stoma, which can be said to exist any time after the first postoperative week. The tendency for certain procedural complications to occur earlier than others is well documented. Table 3 summarizes these problems and their management.

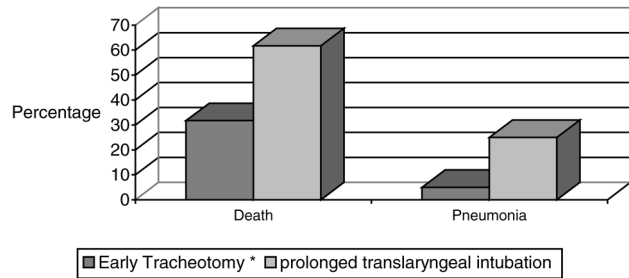
### Timing of tracheotomy

Previous recommendations to avoid tracheotomy for as long as 14–21 days have become obsolete [60]. Only one recent report [61] (in which the authors noted methodological limitations) did not support the use of early tracheostomy. The need for early tracheostomy is frequently questioned [62,63]. Despite this, there appears to be accumulating evidence favouring early tracheostomy (grade A). Rumbak and colleagues [64] defined early tracheostomy as placement of PDT by day 2. In their study, 60 patients underwent tracheostomy in each group. There was a significant difference between the early tracheostomy groups and the prolonged translaryngeal intubation group in outcome measures (Figs 2 and 3). The study by Rumbak and colleagues yielded important evidence suggesting that early tracheostomy should be considered in any patient who is unlikely to wean early. Their study was strengthened by standard weaning and sedation practices. The authors reported remarkable findings in support of early tracheostomy, safety of PDT and lack of complications when the procedure is performed by qualified clinicians.

More recently, in their systematic review and meta-analysis (grade A), Griffiths and coworkers [65] concluded that tracheostomy should be performed earlier in critically ill patients. Five trials with a combined study population of 406 patients were included. The results showed that length of stay in the ICU and duration of artificial ventilation were significantly lower in the 'early tracheostomy' group. However, the timing of tracheostomy had no effect on mortality or on development of pneumonia. In our opinion, the number of the studies included in this meta-analysis is small, leading to greater weight attributed to each individual trial. This leads to risks associated with generalizing the differences between studies, resulting in unacceptable heterogeneity and over-scoring of the effect under study. Sufficiently powered studies are needed before firm conclusions on the timing of tracheostomy can be drawn. Three large randomized trials comparing early versus late tracheostomy are currently being performed: a randomized controlled trial in the UK (TracMan), a multicentre study in The Netherlands, and a study in France.

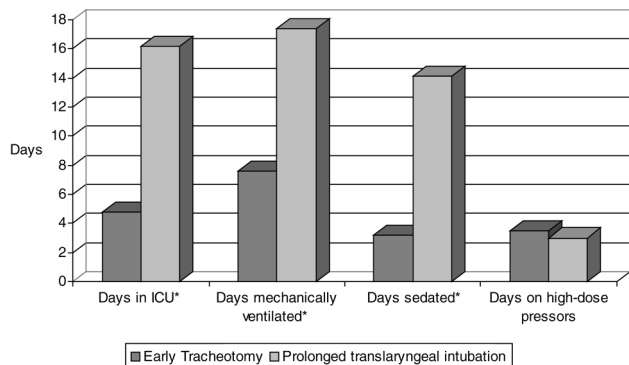
Moller and coworkers [66] found that patients who required prolonged mechanical ventilation had a lower incidence of

**Figure 2**



Death and pneumonia. Shown is a summary of death and pneumonia as outcome measures in the early tracheostomy group versus the prolonged translaryngeal intubation group. Data from Rumbak and coworkers [64]. \* $P < 0.005$ .

**Figure 3**



Other outcome measures. Shown is a summary of other outcome measures in the early tracheostomy group versus the prolonged translaryngeal intubation group. Data from Rumbak and coworkers [64]. \* $P < 0.001$ .

ventilator-associated pneumonia, less ventilator time, and lower length of stay in the ICU when tracheostomy was performed within 7 days after admission to the surgical ICU. A similar finding was reported by Arabi and coworkers [67]. However, these studies are observational studies, and the findings reports are ranked grade B evidence.

### Conclusion

Tracheostomy is among the most frequently performed procedures in critically ill patients. PDT is a safe bedside procedure that can be performed with very low morbidity by skilled practitioners. It is hoped that technical adjuncts will improve patient safety. Any technique that will reduce the morbidity and mortality associated with PDT is welcome. Knowing one's level of expertise, and ability to choose and reject patients and procedures accordingly, is the key to maintaining PDT's excellent safety record. As experience with PDT grows, current contraindications will disappear.

Evidence to guide PDT practice is limited. It is possible that we did not identify all available published research, but by performing a comprehensive and repeated literature search we minimized this risk. Limitations include heterogeneity between the studies included in this review because the exclusion and inclusion criteria differed across trials and because each trial used different definitions. Also, most trials included relatively small study populations. In addition, the critical care populations studied also differed because the trials were undertaken in different specialist rather than general critical care units. The appropriate timing of the tracheostomy (day 2 versus day 7) in intubated patients is yet to be defined.

Given the limitations of our review and the generalizability of findings, one must follow the current best evidence, whenever applicable, until further stronger evidence becomes available.

### Competing interests

The author(s) declare that they have no competing interests.

### References

1. Frost EA: **Tracing the tracheostomy.** *Ann Otolaryngol* 1976, **85**: 618-624.
2. Jackson C: **Tracheotomy.** *Laryngoscope* 1909, **19**:285-290.
3. Shelden CH, Pudenz RH, Tichy FY: **Percutaneous tracheostomy.** *JAMA* 1957, **165**:2068-2070.
4. Toye FJ, Weinstein JD: **A percutaneous tracheostomy device.** *Surgery* 1969, **65**:384-389.
5. Ciaglia P, Firsching R, Syniec C: **Elective percutaneous dilational tracheostomy; a new simple bedside procedure; preliminary report.** *Chest* 1985, **87**:715-719.
6. Muhammad JK, Major E, Wood A, Patton DW: **Percutaneous dilational tracheostomy: haemorrhagic complications and the vascular anatomy of the anterior neck. A review based on 497 cases.** *Int J Oral Maxillofac Surg* 2000, **29**:217-222.
7. Johnson JL, Cheatham ML, Sagraves SG, Block EF, Nelson LD: **Percutaneous dilational tracheostomy: a comparison of single- versus multiple dilator techniques.** *Crit Care Med* 2001, **29**:1251-1254.
8. Griggs WM, Worthley LIG, Gilligan JE, Thomas PD, Myberg JA: **A simple percutaneous tracheostomy technique.** *Surg Gynecol Obstet* 1990, **170**:543-545.
9. Nates NL, Cooper DJ, Myles PS, Scheinkestel CD, Tuxen DV: **Percutaneous tracheostomy in critically ill patients: a prospective, randomized comparison of two techniques.** *Crit Care Med* 2000, **28**:3734-3739.
10. Van Heurn LW, Mastboom WB, Scheeren CI, Brink PR, Ramsay G: **Comparative clinical trial of progressive dilational and forceps dilational tracheostomy.** *Intensive Care Med* 2001; **27**:292-295.
11. Frova G, Quintel M: **A new simple method for percutaneous tracheostomy: controlled rotating dilation. A preliminary report.** *Intensive Care Med* 2002, **28**:299-303.
12. Byhahn C, Kessler P, Lischke V, Bremerich DH, Westphal K: **Perioperative complications of percutaneous tracheostomy: a single center 5-year evaluation of five different techniques [abstract].** *Anesthesiology* 2003; **99**:A480.
13. Friedman Y, Fildes J, Mizock B, Samuel J, Patel S, Appavu S, Roberts R: **Comparison of percutaneous and surgical tracheostomies.** *Chest* 1996, **110**:480-485.
14. Freeman BD, Isabella K, Cobb JP, Boyle WA III, Schmiege RE Jr, Koloff MH, Lin N, Saak T, Thompson EC, Buchman TG: **A prospective, randomized study comparing percutaneous with surgical tracheostomy in critically ill patients.** *Crit Care Med* 2001, **29**:926-930.
15. Stoekli SJ, Breitbach T, Schmid S: **A clinical and histologic comparison of percutaneous dilational versus conventional surgical tracheostomy.** *Laryngoscope* 1997, **107**:1643-1646.
16. Walz MK, Peitgen K, Thurauf N, Trost HA, Wolfhard U, Sander A, Ahmadi C, Eigler FW: **Percutaneous dilational tracheostomy: early results and long-term outcome of 326 critically ill patients.** *Intensive Care Med* 1998, **24**:685-690.
17. Gysin C, Dulguerov P, Guyot JP, Perneger TV, Abajo B, Chevrolet JC: **Percutaneous versus surgical tracheostomy.** *Ann Surg* 1999, **230**:708-714.
18. Kearney PA, Griffen MM, Ochoa JB, Boulanger BR, Tseui BJ, Mentzer RM Jr: **A single-center 8-year experience with percutaneous dilational tracheostomy.** *Ann Surg* 2000, **231**:701-709.
19. Fernandez L, Norwood S, Roettger R, Gass D, Wilkins H III: **Bedside percutaneous tracheostomy with bronchoscopic guidance in critically ill patients.** *Arch Surg* 1996, **131**:129-132.
20. Lin JC, Maley RH Jr, Landreneau RJ: **Extensive posterior-lateral tracheal laceration complicating percutaneous dilational tracheostomy.** *Ann Thorac Surg* 2000, **70**:1194-1196.
21. Hameed AA, Mohamed H, Ghuloom AE: **Experience with percutaneous dilational tracheostomy.** *Clin Intensive Care* 2004, **15**: 87-91.
22. Mayberry JC, Wu IC, Goldman RK, Chestnut RM: **Cervical spine clearance and neck extension during percutaneous tracheostomy in trauma patients.** *Crit Care Med* 2000, **28**:3436-3440.
23. Sustic A, Krstulovic B, Eskinja N, Zelic M, Ledic D, Turina D: **Surgical tracheostomy versus percutaneous dilational tracheostomy in patients with anterior cervical spine fixation: preliminary report.** *Spine* 2002, **27**:1942-1945.
24. Byhahn C, Lischke V, Meininger D, Halbig S, Westphal K: **Perioperative complications during percutaneous tracheostomy in obese patients.** *Anaesthesia* 2005, **60**:12-15.
25. Mansharamani NG, Koziel H, Garland R, LoCicero J III, Critchlow J, Ernst A: **Safety of bedside percutaneous percutaneous dilational tracheostomy in obese patients in the ICU.** *Chest* 2000, **117**:1426-1429.
26. Coatesworth AP: **Use of a customized endotracheal tube for tracheostomy in the large neck.** *Int J Clin Pract* 2002, **56**:52.
27. Hazard P, Jones C, Benitone J: **Comparative clinical trial of standard operative tracheostomy with percutaneous tracheostomy.** *Crit Care Med* 1991, **19**:1018-1024.
28. Meyer M, Critchlow J, Mansharamani N, Angel LF, Garland R, Ernst A: **Repeat bedside percutaneous dilational tracheostomy is a safe procedure.** *Crit Care Med* 2002, **30**:986-988.
29. Ernst A, Critchlow J: **Percutaneous tracheostomy: special considerations.** *Clin Chest Med* 2003, **24**:409-412.
30. Beiderlinden M, Groeben H, Peters J: **Safety of percutaneous dilational tracheostomy in patients ventilated with high positive end-expiratory pressure (PEEP).** *Intensive Care Med* 2003, **29**:944-948.
31. Shah S, Morgan P: **Percutaneous dilation tracheostomy during high-frequency oscillatory ventilation.** *Crit Care Med* 2002, **30**: 1762-1764.
32. Kluge S, Meyer A, Kuhnelt P, Baumann HJ, Kreymann G: **Percutaneous tracheostomy is safe in patients with severe thrombocytopenia.** *Chest* 2004, **126**:547-551.
33. Klein M, Weksler N, Kaplan DM, Weksler D, Chorny I, Gurman GM: **Emergency percutaneous tracheostomy is feasible in experienced hands.** *Eur J Emerg Med* 2004, **11**:108-112.
34. Clarke J, Jaffery A: **How we do it: emergency percutaneous tracheostomy: a case series.** *Clin Otolaryngol Allied Sci* 2004, **29**: 558-561.
35. Ben-Nun A, Altman E, Best LA: **Emergency percutaneous tracheostomy in trauma patients: an early experience.** *Ann Thorac Surg* 2004, **77**:1045-1047.
36. Ault MJ, Ault B, Ng PK: **Percutaneous dilational tracheostomy for emergent airway access.** *J Intensive Care Med* 2003, **18**: 222-226.
37. Donaldson DR, Emami AJ, Wax MK: **Endoscopically monitored percutaneous dilational tracheotomy in a residency program.** *Laryngoscope* 2000, **110**:1142-1146.
38. Gardiner O, White PS, Carson D, Shearer A, Frizelle F, Dunkley P: **Technique training: endoscopic percutaneous tracheostomy.** *Br J Anaesth* 1998, **81**:401-403.
39. Angel LF, Simpson CB: **Comparison of surgical and percutaneous dilational tracheostomy.** *Clin Chest Med* 2003, **24**:423-429.



40. Freeman BD, Isabella K, Natatia N, Buchman TG: **A meta-analysis of prospective trials comparing percutaneous and surgical tracheostomy in critically ill patients.** *Chest* 2000, **118**:1412-1418.
41. Wu JJ, Huang MS, Tang GJ, Shih SC, Yang CC, Kao WF, Huang MH, Lee CH: **Percutaneous dilatational tracheostomy versus open tracheostomy. A prospective, randomized, controlled trial.** *J Chin Med Assoc* 2003, **66**:467-473.
42. Dulguerov P, Gysin C, Perneger TV, Chevrolet JC: **Percutaneous or surgical tracheostomy: a meta-analysis.** *Crit Care Med* 1999, **27**:1617-1625.
43. Melloni G, Muttini S, Gallioli G, Carretta A, Cozzi S, Gemma M, Zannini P: **Surgical tracheostomy versus percutaneous dilatational tracheostomy: a prospective randomized study with long-term follow-up.** *J Cardiovasc Surg (Torino)* 2002, **43**:113-121.
44. Hartfield A, Bodenham A: **Portable ultrasonic scanning of the anterior neck before percutaneous dilatational tracheostomy.** *Anaesthesia* 1999, **54**:660-663.
45. Farmery AD, Shlugman D, Anslow P: **How high do the subclavian arteries ascend into the neck? A population study using magnetic resonance imaging.** *Br J Anaesthesia* 2003, **90**:452-456.
46. Muhammad JK, Patton DW, Evans RM, Major E: **Percutaneous dilatational tracheostomy under ultrasound guidance.** *Br J Oral Maxillofac Surg* 1999, **37**:309-311.
47. Kollig E, Heydenreich U, Roetman B, Hopf F, Muhr G: **Ultrasound and bronchoscopic controlled percutaneous tracheostomy on trauma ICU.** *Injury* 2000, **31**:663-668.
48. Reilly PM, Anderson HL III, Sing RF, Schwab CW, Bartlett RH: **Occult hypercarbia. An unrecognized phenomenon during percutaneous endoscopic tracheostomy.** *Chest* 1995, **107**:1760-1763.
49. Barba CA, Angood PB, Kauder DR, Latenser B, Martin K, McGonigal MD, Phillips GR, Rotondo MF, Schwab CW: **Bronchoscopic guidance makes percutaneous tracheostomy a safe, cost-effective, and easy-to-teach procedure.** *Surgery* 1995, **118**:879-883.
50. Marelli D, Paul A, Manolidis S, Walsh G, Odum JN, Burdon TA, Shennib H, Vestweber KH, Fleischer DM, Mulder DS: **Endoscopic guided percutaneous tracheostomy: early results of a consecutive trial.** *J Trauma* 1990, **30**:433-435.
51. Johnson JL, Cheatham ML, Sagraves SG, Block EF, Nelson LD: **Percutaneous dilatational tracheostomy: a comparison of single- versus multiple-dilator techniques.** *Crit Care Med* 2001, **29**:1251-1254.
52. Maddali MM, Pratap M, Fahr J, Zarroug AW: **Percutaneous tracheostomy by guidewire dilating forceps technique: review of 98 patients.** *J Postgrad Med* 2001, **47**:100-103.
53. Paran H, Butnaru G, Hass I, Afanasov A, Gutman M: **Evaluation of a modified percutaneous tracheostomy technique without bronchoscopic guidance.** *Chest* 2004, **126**:868-871.
54. Ambesh SP, Sinha PK, Tripathi M, Matreja P: **Laryngeal mask airway vs endotracheal tube to facilitate bedside percutaneous tracheostomy in critically ill patients: a prospective comparative study.** *J Postgrad Med* 2002, **48**:11-15.
55. Dosemeci L, Yilmaz M, Gurpinar F, Ramazanoglu A: **The use of the laryngeal mask airway as an alternative to the endotracheal tube during percutaneous dilatational tracheostomy.** *Intensive Care Med* 2002, **28**:63-67.
56. Kahveci SF, Kelebek N, Yavascaoglu B, Kutlay O: **Comparison of the laryngeal mask airway (LMA) and cuffed oropharyngeal airway (COPA) during percutaneous tracheostomy (PCT) in ICU patients.** *Critical Care* 2002, **6**(Suppl 1):P34.
57. Mallick A, Venkatanath D, Elliot SC, Hollins T, Nanda Kumar CG: **A prospective randomized controlled trial of capnography vs. bronchoscopy for Blue Rhino percutaneous tracheostomy.** *Anaesthesia* 2003, **58**:864-868.
58. Hoehne F, Ozaeta M, Chung R: **Routine chest X-ray after percutaneous tracheostomy is unnecessary.** *Am Surg* 2005, **71**:51-53.
59. Wright SE, VanDahm K: **Long-term care of the tracheostomy patient.** *Clin Chest Med* 2003, **24**:473-487.
60. Marsh HM, Gillespie DJ, Baumgartner AE: **Timing of tracheostomy in the critically ill patient.** *Chest* 1989, **96**:190-193.
61. Sugerman HJ, Wolfe L, Pasquale MD, Rogers FB, O'Malley KF, Knudson M, DiNardo L, Gordon M, Schaffer S: **Multicenter, randomized, prospective trial of early tracheostomy.** *J Trauma* 1997, **43**:741-747.
62. Heffner JE: **Tracheotomy application and timing.** *Clin Chest Med* 2003, **24**:389-398.
63. Ahrens T, Kollef MH: **Early tracheostomy: has its time arrived?** *Crit Care Med* 2004, **32**:1796-1797.
64. Rumbak MJ, Newton M, Truncale T, Schwartz SW, Adams JW, Hazard PB: **A prospective, randomized study comparing early percutaneous dilatational tracheostomy to prolonged translaryngeal intubation (delayed tracheostomy) in critically ill medical patients.** *Crit Care Med* 2004, **32**:1689-1694.
65. Griffiths J, Barber VS, Morgan L, Young JD: **Systematic review and meta-analysis of studies of the timing of tracheostomy in adult patients undergoing artificial ventilation.** *BMJ* 2005, **330**:1243.
66. Moller MG, Slaikeu JD, Bonelli P, Davis AT, Hoogeboom JE, Bonnell BW: **Early tracheostomy versus late tracheostomy in the surgical intensive care unit.** *Am J Surg* 2005, **189**:293-296.
67. Arabi Y, Haddad S, Shirawi N, Al Shimemeri A: **Early tracheostomy in intensive care trauma patients improves resource utilization: a cohort study and literature review.** *Crit Care* 2004, **8**:R347-R352.