

United in Prevention—Electrocardiographic Screening for Chronic Obstructive Pulmonary Disease

Biljana Lazovic¹, Sanja Mazic^{2,3}, Zoran Stajic¹, Marina Djelic^{2,3}, Mirjana Zlatkovic-Svenda⁴, Biljana Putnikovic^{1,2}
Clinical Hospital Center Zemun, Department of Internal Medicine, Belgrade, Serbia¹

Faculty of Medicine, University of Belgrade, Belgrade, Serbia²

Institute of Physiology, School of Medicine, University of Belgrade, Serbia³

Clinical Rheumatology, Institute of Rheumatology, Belgrade, Serbia⁴

Corresponding author: Biljana Lazovic, PhD. Milutina Milankovica 122. 11070 Belgrade, Telephone: 062212040. E-mail: lazovic.biljana@gmail.com

Original paper

ABSTRACT

Introduction: P-wave abnormalities on the resting electrocardiogram have been associated with cardiovascular or pulmonary disease. So far, “Gothic” P wave and verticalization of the frontal plane axis is related to lung disease, particularly obstructive lung disease. **Aim:**

We tested if inverted P wave in aVL as a lone criteria of P wave axis $>70^\circ$ could be screening tool for emphysema. **Material and method:** 1095 routine electrocardiograms (ECGs) were reviewed which yielded 478 (82,1%) ECGs with vertical P-axis in sinus rhythm. Charts were reviewed for the diagnosis of COPD and emphysema based on medical history and

pulmonary function tests. **Conclusion:** Electrocardiogram is very effective screening tool not only in cardiovascular field but in chronic obstructive pulmonary disease. The verticality of the P axis is usually immediately apparent, making electrocardiogram rapid screening test for emphysema.

Key words: inverted P wave, ECG, emphysema

1. INTRODUCTION

Chronic obstructive pulmonary disease (COPD) presents an immense and serious global public health problem worldwide. It is a four leading cause of mortality and it has a tendency to increase. Current epidemiological data suggest that by 2020, COPD will be the third leading cause of death throughout the world (1). The major problem in prevention of COPD is its incomplete knowledge about the risks of its development. Cigarette smoking and air pollution are the most important and best recognizable risk factors for COPD. The basic clinical care of COPD includes avoidance of polluted air, regular influenza vaccinations, and rigorous programs for smoking cessation. Electrocardiogram was not used as a screening and prevention tool in COPD. COPD patients very often are not usually assessed by electrocardiogram in routine medical practice, for not known particular reason, especially in developing countries where is the greatest number of patients.

It has been known for some time that emphysema of any etiology, mostly due to chronic obstructive pulmonary disease, produce a state of ab-

normal lung hyperinflation leading to vertical frontal P-wave axis especially in adults, exceeding 60° (2, 3). A vertical P wave axis (>60 degrees) on a surface 12-lead electrocardiogram during sinus rhythm can be easily determined by observing P wave amplitude in limb leads I and III or aVL. If a P wave amplitude in lead III is equal as in lead I it amplifies that P axis is 60° , while if it is greater or smaller, P axis is $>60^\circ$ or $<60^\circ$ respectively. A negative P wave in aVL indicates P axis $>60^\circ$, while a flat or equiphasic P wave in aVL indicates a P axis of 60° and positive P wave in aVL indicates a P axis $<60^\circ$ (4). Several studies have related that electrocardiographic monitoring of P wave in aVL, could be a single screening tool for emphysema. Therefore, the present study was conducted to evaluate its diagnostic values in screening for COPD patients.

2. METHOD

A 12-lead electrocardiograms at rest and pulmonary function test were analyzed routinely in all unselected hospitalized patients in pulmonary ward on the discharge day. Only ECGs with sinus rhythm were obtained. Electrocar-

diograms were read by two authors independently without knowing a reason of hospitalization. The study included all patients older than 45 years, because vertical P wave axis is normal finding in younger patients.

ECGs were classified as P axis $\geq 70^\circ$ (clearly negative p wave in aVL) and P axis $\leq 50^\circ$ (clearly positive p wave in aVL). ECGs with biphasic and flat p wave in aVL were excluded, because p axis of $+60^\circ$ is borderline and could be questionable. At the end of reviewing of ECGs, there was no disagreement in ECG analysis between authors. Upon analysis of ECGs, a direct comparison of the FEV1 value and P-wave axis was done. The diagnosis of chronic obstructive pulmonary disease was made according to the pulmonary function tests following the guidelines of Global Initiative for Chronic Obstructive Lung Disease (GOLD) (5). All spirometry manoeuvres were repeated at least three times, the highest value being accepted when the operator was satisfied that a maximum effort was obtained.

3. RESULTS

We analyzed 1095 ECGs. 480 ECGs belonged to women, average age 62, $99 \pm 0,69$ and 615 to men, average age

63,74±9,48 (Graphic 1, 2)

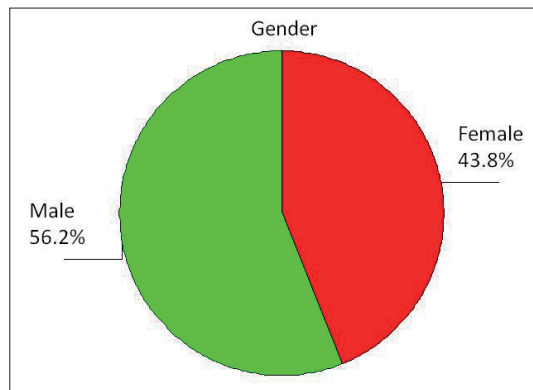
A P wave axis more than 70° was found in 478 (82,1%) patients with demonstrated obstructive pulmonary disease (GOLD 2, 3, 4). 17,9 % patients with normal analysis of spirometry had P wave axis more than 70°. There is statistical significant correlation between inverted p wave in AVI and GOLD stadium- as the obstruction is harder, the axis is more vertical (Table 1).

4. DISCUSSION

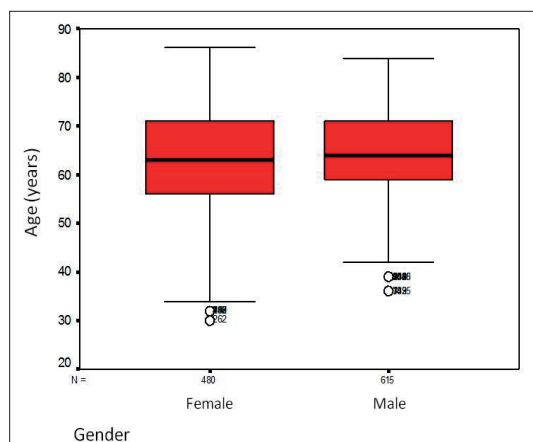
Previous studies have showed strong correlation between vertical P wave axis and emphysema. Furthermore, increasing verticality of the frontal P axis correlates with severity of airflow obstruction, degree of lowering diaphragm level and radiological finding of hyperinflation (6). The mechanisms producing these changes are not definitely known.

One of the possible physiological mechanism which could explain verticalization of heart axis in COPD is that the right atrium is firmly connected to the diaphragm by a dense pericardial ligament around the inferior vena cava (2, 6). Air trapping and consecutive hyperexpansion in COPD and more specifically emphysema result in flattening of the diaphragm contracts inwards instead of downwards, pulling the inferior ribs inwards with its movement and causing a significant rightward deviation (verticalization) of the P wave axis.

Usually first symptoms of obstructive disease are manifested late when disease is already in progressive form (FEV1<50%). There are only few studies which tested inverted p wave in AVI as a single tool in emphysema screening. In the study by Chhabra et al (6), sensitivity and specificity of a vertical P axis for diagnosis emphysema was 94,7% and 86,4%, respectively, while in another study by Baljepally and al (7), it



Graph 1. Gender distribution



Graph 2. Age and gender

	Stadium	P wave >70°		
		No Nb (%)	Yes Nb (%)	All Nb (%)
GOLD	1	96 (18.7)	104 (17.9)	200 (18.3)
	2	157 (30.6)	260 (44.7)	417 (38.1)
	3	204 (39.8)	178 (30.6)	382 (34.9)
	4	56 (10.9)	40 (6.9)	96 (8.8)
	All	513 (100.0)	582 (100.0)	1095 (100.0)

Table 1. P wave >70° and GOLD stadium. χ^2 test: 25,953 (df=3); p= 0.000

was 89% and 96% respectively. Both studies used combined electrocardiographic criteria- P wave amplitude in lead III greater than in lead I and/or dominantly negative P wave in aVL, to define P wave verticalization. We tried to define a single criteria using aVL lead and showed that it could be adequately in screening for emphysema.

According to our study, it could be used for quick and fast orientation and help patient to prevent lung disease on time.

In clinical study such as this, one could not be certain of the state of the myocardium and one could not exclude the effects of underlying primary cardiac disease on the relationships discussed. Nevertheless, the ECG may be used in conjunction with other bedside or office procedures for

the initial assessment of the degree of pulmonary impairment in patients with COPD.

5. LIMITATIONS

The ECGs were obtained from inpatients in pulmonary ward. We do not have the specific reasons for why the ECGs were obtained. Also, pulmonary function test was done in situations where it was not necessary such as respiratory infection, pneumonia, common cold, so our results represent a very broad range of patients.

6. CONCLUSION

Patients with COPD, especially emphysema, if it is not treated (either medically or stopping smoking) have the low survival rate and the silent, but rapid decline in pulmonary function. Patients usually pay a visit to doctor when symptoms occur. Thus, it is clinically relevant to detect on time and prevent further progression and developing other comorbidities.

In routine practice, physicians are usually confronted with p wave abnormalities which are mostly considered non specific and widely disregarded. According to this and other similar studies, P wave abnormalities are not so rare findings in ECG and thus should be ignored.

Since ECG could routinely be done in mostly every patient visit to doctor, it could be considered as a cheap, easy applicable method for COPD screening.

REFERENCES

- Rycroft CE, Heyes A, Lanza L, Becker K. Epidemiology of chronic obstructive pulmonary disease: a literature review. Int J Chron Obstruct Pulmon Dis. 2012; 7: 457-494.
- Thomas AJ, Apiyasawat S, Spodick DH. Electrocardiographic detection of emphysema. Am J Cardiol. 2011; 107(7): 1090-1092.
- Spodick DH. Pulmonary emphysema: classic, quasi-diagnostic ECG. Am J Geriatr Cardiol. 2006; 15(3): 193.
- Madias JE. Vertical P-wave axis and narrow QRS complexes: a diagnostic dyad for emphysema. Am J Cardiol. 2011; 108(3): 475-476.
- Global Initiative for Chronic Obstructive Lung Disease. Global strategy for the diagnosis, management and prevention of COPD.
- Chhabra L, Sareen P, Perli D, Srinivasan I, Spodick DH. Vertical P-wave axis: the electrocardiographic synonym for pulmonary emphysema and its severity. Indian Heart J. 2012; 64(1): 40-42.
- Baljepally R, Spodick DH. Electrocardiographic screening for emphysema: the frontal plane P axis. Clin Cardiol. 1999; 22(3): 226-228.