

Contents lists available at [ScienceDirect](https://www.sciencedirect.com)

Respiratory Medicine Case Reports

journal homepage: <http://www.elsevier.com/locate/rmcr>

Case report

Endobronchial metastasis of ovarian cancer rescued by tumor ablation and a self-expanding hybrid stent: A case report and review of the literature

Daisuke Himeji^{a,*}, Gen-ichi Tanaka^a, Chikara Fukuyama^a, Ritsuya Shiiba^a, Takeshi Murakami^b, Moriguchi Sayaka^c, Kousuke Marutsuka^c^a Department of Internal Medicine, Miyazaki Prefectural Miyazaki Hospital, 5-30 Kitatakamatsu-chou, Miyazaki-shi, Miyazaki, 880-8510, Japan^b Department of Obstetrics and Gynecology, Miyazaki Prefectural Miyazaki Hospital, 5-30 Kitatakamatsu-chou, Miyazaki-shi, Miyazaki, 880-8510, Japan^c Department of Anatomic Pathology, Miyazaki Prefectural Miyazaki Hospital, 5-30 Kitatakamatsu-chou, Miyazaki-shi, Miyazaki, 880-8510, Japan

ARTICLE INFO

Keywords:

Endobronchial metastasis
Hybrid stent
Bronchoscopy
Ovarian cancer
Tracheal stenosis

ABSTRACT

Tracheal stenosis caused by malignancy is a life-threatening complication. Herein, we performed tumor ablation and airway stenting using a hybrid stent on a patient with upper tracheal stenosis caused by endobronchial metastasis of ovarian cancer. To date, only 9 cases of endobronchial metastasis of ovarian cancer have been reported. This is the first reported case of endobronchial metastasis in the upper part of the trachea, which had a favorable outcome after tumor ablation as a sequential treatment and use of a hybrid stent. In addition, 10 cases of endobronchial metastasis of ovarian cancer, including ours and other case reports, were reviewed.

1. Introduction

The occurrence of endobronchial metastasis from extrapulmonary malignancies is well known in carcinomas of the kidney, breast, and colon. However, it is rarely observed in patients with ovarian cancer [1].

To date, only 9 cases of endobronchial metastasis of ovarian cancer have been reported. The diagnosis of endobronchial metastasis of ovarian cancer during the course of treatment may be long, and a specific prognosis can be expected even after detection in some cases. Thus, it is important to cautiously select the treatment regimen. Herein, we report a case of severe tracheal stenosis caused by endobronchial metastasis of ovarian cancer that was successfully treated with tumor reduction as a sequential therapy and placement of an AERO stent, which is a hybrid stent. In addition, 10 cases of endobronchial metastasis of ovarian cancer, including ours and other case reports, were reviewed.

2. Case report

A 47-year-old woman was referred to Miyazaki Prefectural Miyazaki Hospital for treatment of a tracheal tumor detected on chest computed tomography (CT). She was allergic to the contrast medium and was unable to have a contrast CT. The patient had undergone total

hysterectomy, bilateral appendectomy, and partial omentectomy for stage 4A ovarian cancer at 41 years of age. Thereafter, she received seven cycles of TC (paclitaxel and carboplatin) therapy as adjuvant chemotherapy. Ovarian cancer reoccurred 43 years of age. Thus, she received six cycles of TC therapy. However, she again experienced recurrence 44 years of age. The recurrence sites included the left clavicle or lymph nodes, mediastinal lymph nodes, and abdominal lymph nodes. Therefore, she received another seven cycles of TC therapy and was followed up since then. At 46 years of age, exacerbation was detected on the same sites, and the patient received four cycles of TC therapy. Chest CT revealed a tumorous lesion slightly protruding in the trachea (Fig. 1). The size of the mass increased, and the patient was referred to our department (Fig. 2a–c).

She only complained of cough; her vital signs were as follows: temperature, 36.8 °C; blood pressure, 132/83 mmHg; pulse, 107 beats/min; and respiratory rate, 20 cycles/min with an O₂ saturation of 96% on room air. No anomalies were noted upon auscultation. Hemogram results revealed a normal leucocyte count of 11150/μL. Furthermore, renal and liver function tests had normal results. However, her CA125 levels were high (387 IU/L).

Chest CT revealed the presence of a tumor in the posterior wall of the upper portion of the trachea (Fig. 2a–c). The most restricted part of the

* Corresponding author.

E-mail addresses: himeji@pref-hp.miyazaki.miyazaki.jp (D. Himeji), gatanaka@moon.so-net.jp (G.-i. Tanaka), chkara2258@yahoo.co.jp (C. Fukuyama), ritsuya-shiiba@med.miyazaki-u.ac.jp (R. Shiiba), murakami820421@yahoo.co.jp (T. Murakami), sayams@pref-hp.miyazaki.miyazaki.jp (M. Sayaka), kmaru@pref-hp.miyazaki.miyazaki.jp (K. Marutsuka).

<https://doi.org/10.1016/j.rmcr.2020.101132>

Received 26 May 2020; Received in revised form 11 June 2020; Accepted 11 June 2020

Available online 12 June 2020

2213-0071/© 2020 The Authors.

Published by Elsevier Ltd.

This is an open access article under the CC BY-NC-ND license

(<http://creativecommons.org/licenses/by-nc-nd/4.0/>).

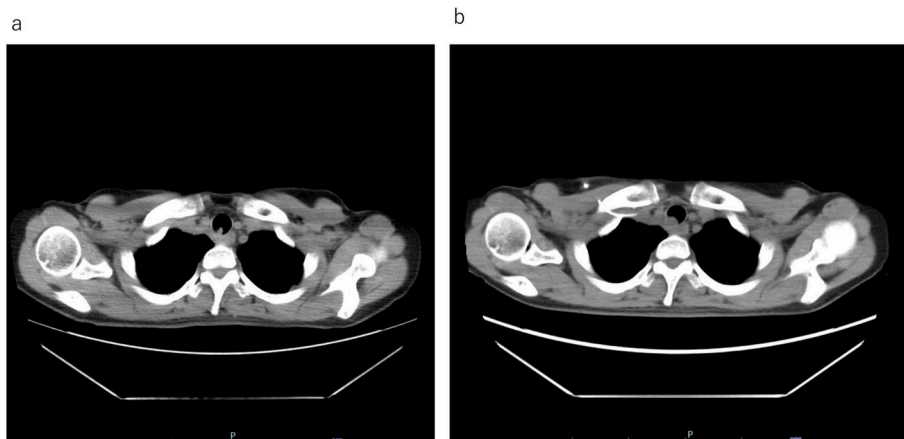


Fig. 1. Computed tomography (CT). a. Chest CT image obtained after the initial diagnosis of endobronchial metastasis. CT revealed the presence of a tumor in the posterior wall of the upper portion of the trachea. b. Chest CT image obtained 3 months after the initial diagnosis of endobronchial metastasis. CT revealed that the size of the tumor had increased.

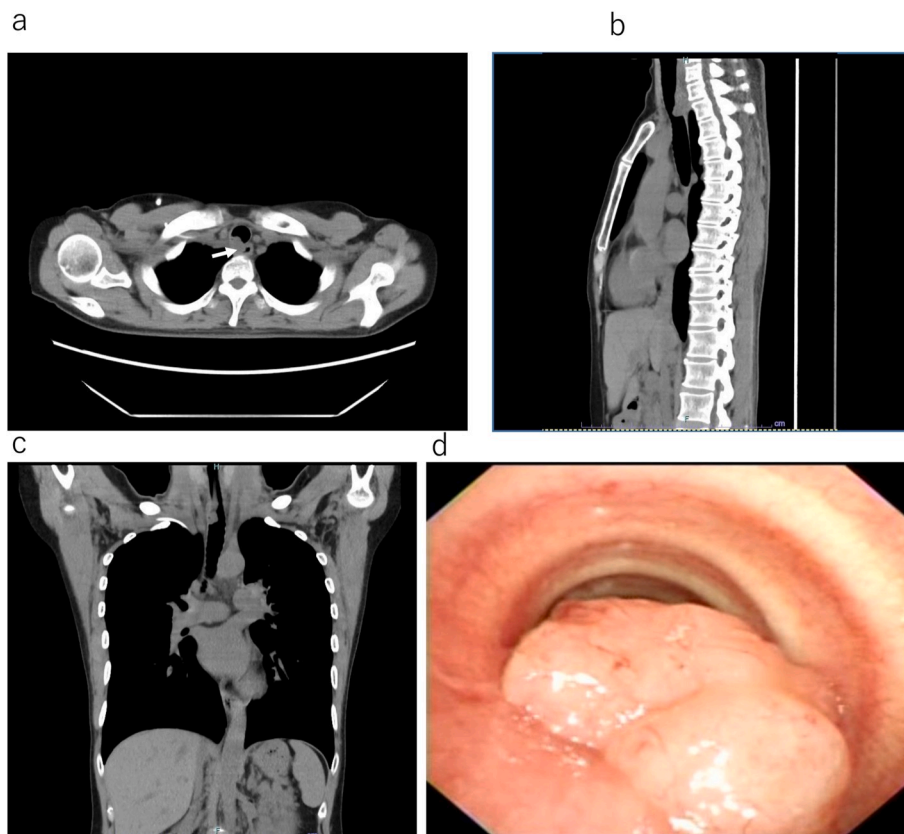


Fig. 2. Computed tomography (CT) and endoscopic images obtained 6 months after the initial diagnosis of endobronchial metastasis. a. Horizontal section view of chest CT image. The border between the tumor and esophagus is unclear and tumor invasion to the esophagus is suspected (a white arrow). b. Sagittal section view. c. Frontal section view. CT revealed tumor progression. d. Endoscopic view. The tumor caused narrowing of the tracheal lumen by about two-third. The tumor appeared to be pedunculated and had developed in the right side of the tracheal membranous portion.

trachea was approximately 10 mm in diameter and 10 mm in length. In addition, the part of the border between the trachea and esophagus was not distinct (Fig. 2a–c). Bronchoscopy confirmed a soft tissue mass obstructing the upper trachea. However, the distal part of trachea could still be examined (Fig. 2d). The tumor was pedunculated, with promising long-term prognoses according to the gynecologist. Therefore, tumor volume reduction was performed. The tumor was cauterized using microwave coagulation and balloon dilation of the stenosis via rigid bronchoscopy under general anesthesia. Finally, tumor reduction was completed using a polypectomy snare (Fig. 3a–c). The patient was diagnosed with ovarian serous adenocarcinoma via biopsy of tissue samples obtained from the lesion.

After treatment, the patient received another five cycles of TC therapy and was followed up thereafter. However, exacerbation was detected on the same sites 6 months after treatment (Fig. 4a and b).

Bronchoscopy revealed a soft tissue mass obstructing the upper trachea at the same site (Fig. 4c and d).

Because we believed that the patient was at high risk of suffocation, tracheal stenting was performed. The AERO stent was used owing to the following reasons: chemotherapy was not effective; the stent could be removed from the lesion site after the patient underwent treatments, including radiation; and it was solid enough to support tracheal lesions.

Balloon dilation of the stenosis was performed via rigid bronchoscopy under general anesthesia, which improved airway stenosis by

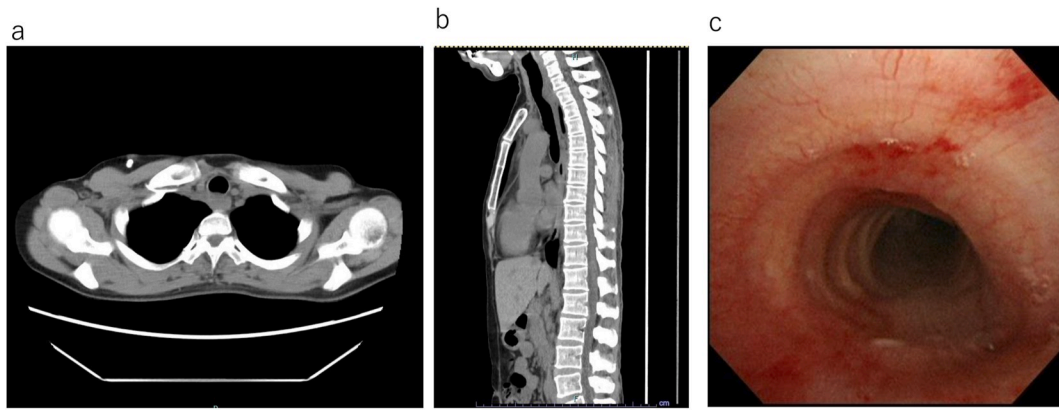


Fig. 3. Computed tomography (CT) and endoscopic images obtained 2 months after the initial bronchial intervention. a. Horizontal section view of chest CT image. b. Sagittal section view. CT revealed that most of the tumor had been removed. c. Endoscopic view. The tracheal lumen was re-established via bronchial intervention.

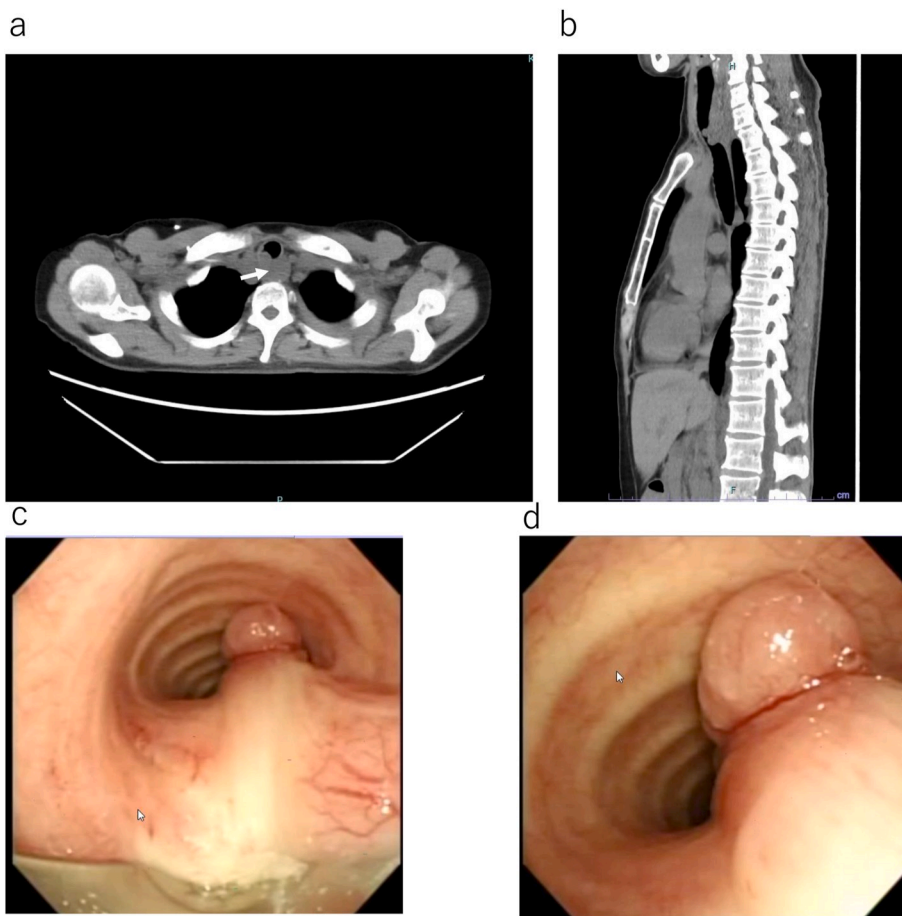


Fig. 4. Computed tomography (CT) and endoscopic images obtained 8 months after the initial bronchial intervention. a. Horizontal section view of chest CT image. The border between the tumor and esophagus remains unclear and tumor invasion to the esophagus is also suspected (a white arrow). b. Sagittal section view. CT revealed that the size of the tumor had increased again. c. Endoscopic view. The tracheal lumen was narrowed by the tumor, and the endotracheal tumor was of mixed type.

approximately 80%. Then, the AERO stent (16 × 60 mm, over-the-wire delivery system) was placed (Fig. 5a–e) using a previously described method [2].

Six months after placing the stent, the patient is still alive, and the occurrence of neither stent migration nor bleeding has been reported. Appropriate written informed consent has been obtained for the publication of this case report and accompanying images.

3. Discussion

Herein, we reported the case of a patient with severe tracheal

stenosis caused by endobronchial metastasis of ovarian cancer who was successfully treated with tumor reduction as sequential therapy and AERO stent placement. This study first reported about the use of stent placement for the treatment of endobronchial metastasis of ovarian cancer.

Endobronchial metastasis is defined as metastasis to the endobronchus within a bronchoscopically visible range due to extrathoracic malignancies [3]. The most common primary malignancies that have potential to metastasize to the endobronchial site are breast, renal, endometrial, and colon cancers [4]. The occurrence of endobronchial metastases of ovarian cancer is quite rare. In addition, metastasis to the

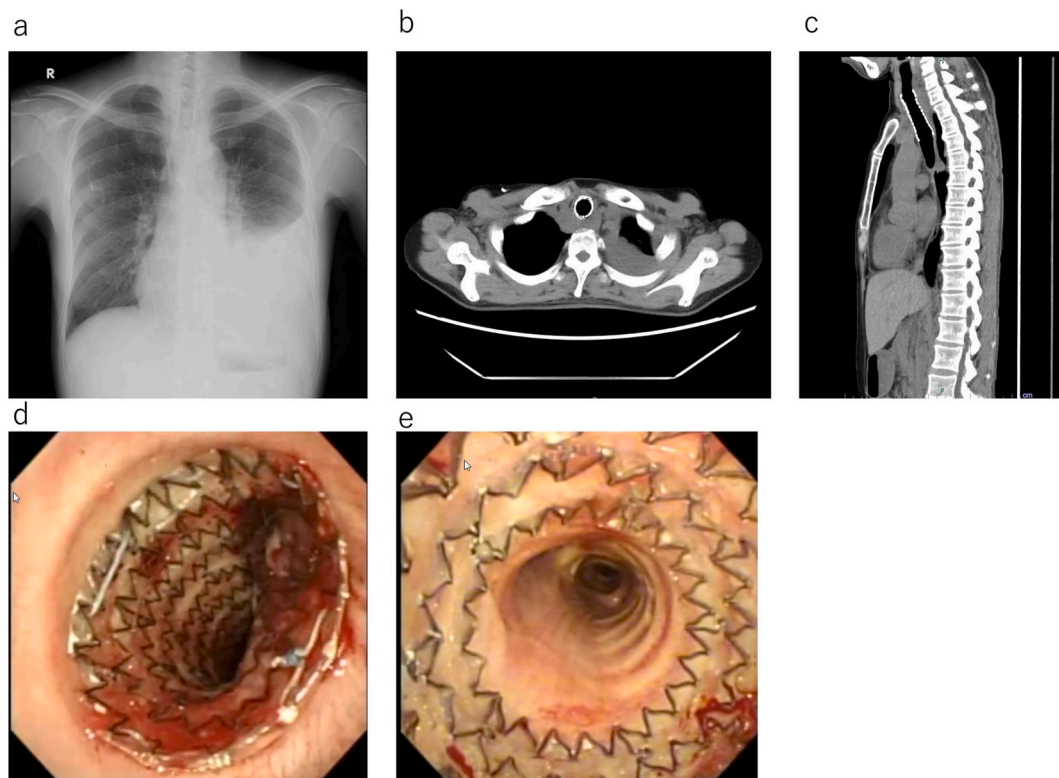


Fig. 5. Chest radiography, computed tomography (CT), and endoscopic images obtained after the stent was placed. a. The stent had expanded sufficiently in the trachea. b. Horizontal section view of chest CT image. b. Sagittal section view. Chest CT revealed that the stent had expanded adequately and that the airway was patent. d. Endoscopic view, proximal view. e. Distal view. The stent had expanded sufficiently in the trachea.

trachea is even rarer. While several case reports on endobronchial metastasis of ovarian cancer are available, there are few reports that have been published regarding its clinical characteristics. In this study, we reviewed 10 cases of endobronchial metastasis of ovarian cancer, including our own and some other case reports [5–12]. Table 1 shows the main clinical characteristics of the patients at presentation.

The average age of the reviewed cases was 53.2 years. The period between the diagnosis of primary ovarian cancer and significant development of endobronchial metastasis based on clinical and radiological examinations varied from 0 to 21 (median: 4) years. All patients except one presented with respiratory symptoms, such as cough and dyspnea. The site of endobronchial metastasis was the trachea in 2 patients (20%), carina in 2 (20%), main bronchus in 2 (20%), and lobar bronchus in 4 (40%). Similar to the selection of treatment, surgery, chemotherapy, and radiation treatment, tumor ablation was selected for carinal and main bronchial lesions.

The interval between the diagnosis of the primary malignancy and detection of endobronchial metastases may be long. That is, the mean time between the diagnosis of the primary tumor and development of endobronchial metastases is 50 months [13], which is consistent with the 4-year interval observed in our study. In our case, the condition was easily detected due to the presence of other metastatic lesions, and the patient received intermittent chemotherapy. Moreover, chest CT was regularly performed. However, this imaging test may not always be performed during follow up, particularly in patients who undergo complete resection. Therefore, chest CT should be considered if a patient with ovarian cancer presents with cough, dyspnea, or any other anomalies, including atelectasis, on chest radiography.

Endobronchial metastasis is a life-threatening condition, particularly when the site of metastasis is the trachea. In our review, only 2 patients had endobronchial metastases to the trachea (Table 1). Endobronchial metastases observed in the trachea, carina, and main bronchus are generally difficult to excise. For these lesions, tumor ablation was

selected in 2 patients and radiotherapy in 1 patient. However, these treatments require additional treatment procedures if the patient survives for a long period of time. Furthermore, the condition is life-threatening if there is a recurrence. In our case report, invasion to the esophagus was also suspected, and surgery was considered impossible. Unlike lung cancer, endobronchial metastasis in multiple organs can have a specific prognosis. The mean survival time from the diagnosis of endobronchial metastasis is 15.2 (range: 0–150) months [5]. In our review about endobronchial metastasis, the median survival time from the diagnosis of endobronchial metastasis was 5 (range: 4–22) months. In our patient, only ablation was initially performed owing to promising long-term prognosis and pedunculated-type tumor. However, in the second treatment, stent placement therapy was selected because the tumor was of mixed type and chemotherapy was considered ineffective. None of the previous case reports considered stent placement for the treatment of endotracheal metastasis of ovarian cancer. The treatment of endobronchial metastases is challenging, and thus, should be individualized according to histopathological diagnosis, size and site of metastases, post-intervention treatment, prognosis, and general condition of the patient. To improve the prognosis of ovarian cancer, stent therapy can be considered as it is less invasive than surgery, and an increase in the number of cases is expected in the future.

For the re-establishment of the airway, silicone stents (e.g., DUMON and TM) and self-expanding metallic (SEM) stents are widely used [14]. Silicone stents have good expansion power and can be easily removed; thus, they have been the primary choice. However, when placement of silicone stents is performed, general anesthesia is used, and rigid bronchoscopy is performed for placement. At our institution, as a rule, we perform airway stenting using rigid bronchoscopy because we believe that obstructive or hemorrhagic complications can be more rapidly controlled using rigid bronchoscopy than using flexible bronchoscopy. However, in Japan, rigid bronchoscopy is conducted in only 18.5% of the institutions [15]. On the other hand, SEM stents can be placed with

Table 1
Summary of previously published literature on ovarian cancer with endobronchial metastasis.

Case(ref.)	Age at primary diagnosis	Interval to endobronchial metastasis(years)	Respiratory Symptoms	Histology	Bronchoscopic Findings	Treatment	Survival after diagnosis of bronchial metastasis
1(5)	68	7	Dyspnea	Not reported	Tracheal tumor		Well at 5 months
2(6)	45	12	Cough	Serous cystadenocarcinoma	Tumor arising from right B6	Radiotherapy Lobectomy	Not reported
3(7)	83	Simultaneous	Dyspnea, dysphagia, hoarseness of voice	Pap. adenocarcinoma	Right main bronchus tumor	Tumor ablation(Laser)	Expired at 4 months
4 (8)	62	5	Respiratory insufficiency	Serous cystadenocarcinoma	Tumor obstructing the RUL and B6 of LLL	Chemotherapy Radiotherapy	Expired at 22 months
5(9)	49	2	Dyspnea	Not reported	Right subcarinal tumor	Not reported	Not reported
6(10)	62	21	Dyspnea, cough	adenocarcinoma	Left main bronchus tumor and RLL tumor	Chemotherapy	Not reported
7(10)	53	8	Dyspnea, cough	Serous adenocarcinoma	Carinal tumor	Tumor ablation (Electrocautery)	Not reported
8(11)	22	Simultaneous	Hemoptysis	Papillary adenocarcinoma	Tumor arising from RLB	Supportive care	Not reported
9(12)	45	0.5	None	endometrioid adenocarcinoma	Left lower bronchus	Lobectomy	Well at 60 months
10(Present)	43	3	Cough	Serous adenocarcinoma	Tracheal tumor	Tumor ablation Airway stenting	Well at 6 months

bronchoscopic guidance under local anesthesia. However, the expansion power of metallic stents is weak. In addition, SEM stents are less readily removable.

The AERO stent (Alveolus, Inc., NC, the USA), which is an SEM hybrid stent, has the best features of both silicone and metal stents, with a completely covered nitinol framework, and the use of this type of stent is gradually increasing in Japan [2,16]. The following are the potential advantages of using this stent: (1) insertion via flexible bronchoscopy, (2) ease of removal, and (3) strong expansion properties [2]. Rigid bronchoscopy is not available at all centers that treat patients with ovarian cancer. Thus, this stent, which can be inserted with a flexible bronchoscope, may be an effective treatment for endobronchial metastasis of ovarian cancer.

4. Conclusions

Herein, we report the case of a patient with severe tracheal stenosis caused by endobronchial metastasis of ovarian cancer who was successfully treated with tumor reduction as sequential therapy and placement of the AERO stent. This study is the first to report the use of stent placement for the treatment of endobronchial metastasis of ovarian cancer. In addition, 10 cases of endobronchial metastasis of ovarian cancer, including ours and other case reports, were reviewed. The treatment of endobronchial metastases is challenging; therefore, it should be individualized according to histopathological diagnosis, size and site of metastases, post-intervention treatment, prognosis, and general condition of the patient.

Funding

This research did not receive any specific grant from funding agencies in the public, commercial, or not-for-profit sectors.

Declaration of competing interest

None.

CRediT authorship contribution statement

Daisuke Himeji: Conceptualization, Writing - original draft, Writing - review & editing. **Gen-ichi Tanaka:** Resources. **Chikara Fukuyama:** Resources, Resources. **Takeshi Murakami:** Resources. **Moriguchi Sayaka:** Resources. **Kousuke Marutsuka:** Resources, Writing - review & editing.

Acknowledgments

None.

Appendix A. Supplementary data

Supplementary data to this article can be found online at <https://doi.org/10.1016/j.rmcr.2020.101132>.

References

- [1] H.C. Grillo, D.J. Mathisen, Primary tracheal tumors: treatment and results, *Ann. Thorac. Surg.* 49 (1990) 69–77.
- [2] D. Himeji, T. Kawaguchi, K. Setoguchi, et al., Successful treatment of life-threatening tracheal stenosis caused by malignancy with a self-expanding hybrid stent, *Intern. Med.* 57 (2018) 259–263.
- [3] A. Marchioni, A. Lasagni, A. Busca, et al., Endobronchial metastasis: an epidemiologic and clinicopathologic study of 174 consecutive cases, *Lung Canc.* 84 (2014) 222–228.
- [4] M. Breta, S. Arava, K. Madan, et al., Endobronchial metastasis from extrathoracic malignancies: a clinicopathological study of 11 cases, *Lung India* 36 (2019) 212–215.
- [5] D.E. Westerman, J.S. Urbanetti, R.A. Rudders, et al., Metastatic endotracheal tumor from ovarian carcinoma, *Chest* 77 (1980) 798–800.

- [6] C.R. Merrill, J.A. Hopkirk, Late endobronchial metastasis from ovarian tumour, *Br. J. Dis. Chest* 76 (1982) 253–254.
- [7] O. Merimsky, J. Greif, S. Chaitchik, et al., Endobronchial metastasis of ovarian cancer. A case report, *Tumori* 76 (1990) 614–615.
- [8] F. Mateo, E. Serur, P.R. Smith, Bronchial metastases from ovarian carcinoma. Report of a case and review of the literature, *Gynecol. Oncol.* 46 (1992) 235–238.
- [9] M.H. Wholey, G.E. Meyerrose, W.P. McGuire, et al., Endobronchial lesion from metastatic ovarian carcinoma resulting in partial right mainstem obstruction demonstrated by lung scintigraphy, *Clin. Nucl. Med.* 20 (1995) 465–466.
- [10] A. Upadhyay, V. Goel, U. Batra, et al., Two cases of ovarian carcinoma with endobronchial metastases: rare presentation, *South Asian J. Canc.* 4 (2015) 149.
- [11] Ayub II, D. Thangaswamy, L.D. Joseph, Lung parenchymal and endobronchial metastases from ovarian carcinoma, *J. Bronchol. Intervent. Pulmonol.* 25 (2018) 235–238.
- [12] R.M. Franco, M.D. Guimaraes, B.L. Moreira, et al., Enhancing survival with early surgical resection of endobronchial metastasis in a follow-up of ovarian carcinoma, *Radiol. Bras.* 48 (2015) 130.
- [13] J.B. Sørensen, Endobronchial metastases from extrapulmonary solid tumors, *Acta Oncol.* 43 (2004) 73–79.
- [14] D.F. Kopman, A.C. Mehta, M.M. Wahidi, Therapeutic bronchoscopy. Murray and Nadel's Textbook of Respiratory Medicine, sixth ed., Elsevier, London, 2015, pp. 383–392.
- [15] F. Asano, M. Aoe, Y. Ohsaki, Y. Okada, S. Sasada, S. Sato, et al., Bronchoscopic practice in Japan: a survey by the Japan society for respiratory endoscopy in 2010, *Respirology* 18 (2013) 284–290.
- [16] A. Ishida, M. Oki, H. Saka, Fully covered self-expandable metallic stents for malignant airway disorders, *Respir. Investig.* 7 (2019) 49–53.