

Corneal ulcer due to a rare pleosporalean member of the genus *Bipolaris* following cow tail injury to the eye: A case report and review of literature

H Vijaya Pai, Esha Jamal,
Prakash Peralam Yegneswaran¹

Aspergillus and *Fusarium* are the most common fungi causing mycotic keratitis. Injury to the eye with vegetable matter, cow tail injury, long-term use of topical steroids are some of the risk factors for mycotic keratitis. There are few case reports of keratitis caused by *Bipolaris*. The human pathogenic species in the genus are *Bipolaris spicifera*, *Bipolaris hawaiiensis*, *Bipolaris papendorfii*, and *Bipolaris australiensis*. Most commonly reported keratitis is caused by *B. hawaiiensis*, followed by *B. spicifera*. Literature review showed only one case report of keratitis due to *B. australiensis* reported from Australia. We present a first case report of keratitis due to *B. australiensis* (currently *Curvularia australiensis*) from India.

Key words: *Bipolaris australiensis*, corneal ulcer, keratomycoses, phaeoid fungi

The genus *Bipolaris* are ubiquitous, saprophytic ascomycetous fungi of the order pleosporales. Most of the species of this large genus are pathogenic to graminicolous plants and found in dead plant material and soil. The human pathogenic species in the genus are *Bipolaris spicifera*, *Bipolaris hawaiiensis*, *Bipolaris papendorfii*, and *Bipolaris australiensis* are pathogenic to humans. *B. australiensis* has been known to be involved in humans causing peritonitis, subcutaneous phaeohyphomycoses fungal sinusitis, and disseminated infection. We report a case of keratitis caused by *B. australiensis* (currently *Curvularia australiensis*) following cow tail injury to the eye.

Case Report

A 59-year-old man presented to our hospital, with redness, pain, and defective vision in the left eye (LE) of 15-day duration. He gave a history of injury to the LE with a cow's

tail while milking the cow. Further, he consulted a local ophthalmologist and was prescribed topical moxifloxacin thrice a day, natamycin thrice a day, and ointment moxifloxacin thrice a day. There was no history of diabetes mellitus or using steroid eye drops. As there was no relief, he subsequently visited our hospital.

On examination, his best-corrected visual acuity was 6/12 improving with pinhole to 6/6 in the right eye (RE) and 6/36 in the LE. RE examination was normal. Slit-lamp evaluation of the LE revealed ciliary congestion with the corneal infiltrate measuring 3.5 mm × 3 mm [Fig. 1]. There was no hypopyon.

Scrapings were taken from the corneal lesion under topical anesthesia for Gram's staining and 10% potassium hydroxide (KOH) mount. Additional scrapings were taken to inoculate 5% sheep blood agar (SBA) and Sabouraud dextrose agar (SDA) plates (Hi-Media Laboratories Pvt. Ltd, Mumbai, India).

The patient was started on topical natamycin Q 1 hourly, fluconazole Q 1 hourly, ciprofloxacin Q 1 hourly, and atropine eye drops three times a day.

The KOH mount of the corneal scrapings showed phaeoid, septate, branching, filamentous mold suggestive of keratomycoses due to phaeoid fungi. The SBA and SDA plates were incubated at 37°C and 25°C, respectively. The blood agar plates after 24 h incubation had no bacterial growth. Fungal growth was observed following 4 days of incubation of the SDA plates. KOH microscopy with phaeoid fungal elements and SDA media with growth consistent with phaeoid fungi confirmed the fungal etiology for the case. Subsequently the fungi were identified as *B. australiensis* based on macroscopic and microscopic characters. The colonies on SDA after 7 days of incubation at 25°C showed spreading, gray to brownish black, velvety texture colonies [Fig. 2]. The reverse of the fungal colonies showed brown pigmentation. The slide culture mount in lactophenol cotton blue mount showed solitary, smooth-walled conidiophore with characteristic geniculate and verruculose nodes. The conidia in clusters were smooth-walled, ellipsoidal, rounded ends, pale brown, straight, and 4–5 distoseptation [Fig. 3]. The morphological identification of the isolate was carried out based on conidial structure, presence of an inconspicuous to slightly protuberant hilum, formation of germ tubes from polar cells, and ontogeny of conidial septum.^[1] The identity was further confirmed by matrix-assisted laser desorption ionization-time of flight mass spectrometry analysis and internal transcribed spacer 2 sequencing region rDNA gene compared with GenBank DNA sequences database.

Access this article online	
Quick Response Code:	Website: www.ijjo.in
	DOI: 10.4103/ijjo.IJO_836_16

Department of Ophthalmology, Kasturba Medical College, Manipal University, ¹Department of Microbiology, Medical Mycology Division, Kasturba Medical College, Manipal University, Manipal, Karnataka, India

Correspondence to: Dr. H Vijaya Pai, Department of Ophthalmology, Kasturba Medical College, Manipal University, Manipal - 576 104, Karnataka, India. E-mail: paivijaya@yahoo.co.in

Manuscript received: 22.03.17; Revision accepted: 03.04.17

This is an open access article distributed under the terms of the Creative Commons Attribution-NonCommercial-ShareAlike 3.0 License, which allows others to remix, tweak, and build upon the work non-commercially, as long as the author is credited and the new creations are licensed under the identical terms.

For reprints contact: reprints@medknow.com

Cite this article as: Pai HV, Jamal E, Yegneswaran PP. Corneal ulcer due to a rare pleosporalean member of the genus *Bipolaris* following cow tail injury to the eye: A case report and review of literature. Indian J Ophthalmol 2017;65:403-5.

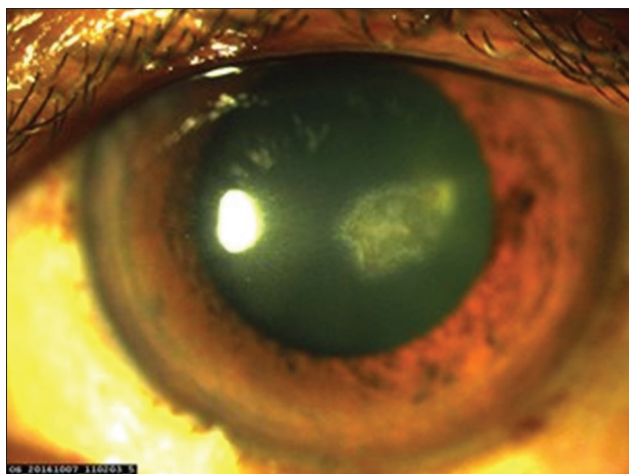


Figure 1: Slit-lamp examination revealing the corneal infiltrate measuring 3.5 mm x 3 mm

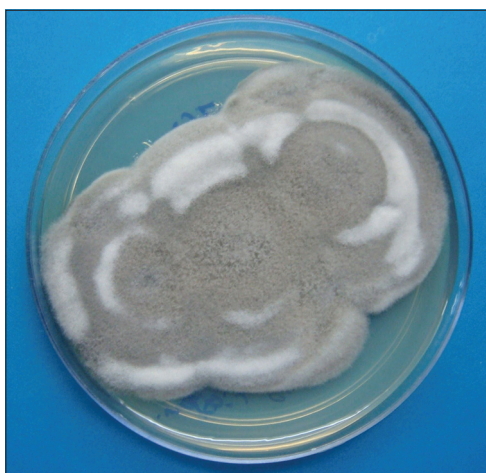

Figure 2: Obverse macroscopic colony morphology of *Bipolaris australiensis* on Sabouraud dextrose agar after 7 days of incubation at 25°C showed spreading, gray to brownish black, velvety texture colonies

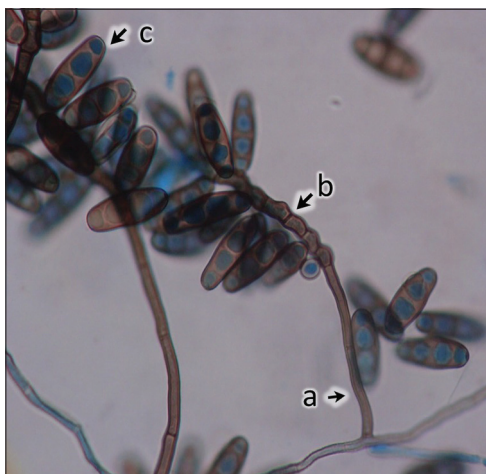

Figure 3: Slide culture mount in lactophenol cotton blue mount showing (a) solitary, smooth-walled conidiophore (b) geniculate and verruculose nodes in conidiophores (c) smooth-walled, ellipsoidal, rounded ends, pale brown, straight, 4–5 distoseptate conidia in clusters (400)

He responded well to the topical therapy. On follow-up, the ulcer was seen regressing and the vision improved to 6/9. Ulcer healed completely by 4 weeks.

Discussion

Bipolaris species are a dematiaceous fungus, part of the hyphomycetes group of fungi. The common species inciting human disease include *B. australiensis*, *B. hawaiiensis*, and *B. spicifera*. Colonies are woolly, gray to black. Conidial germination is from both poles and/or end cells and hence the genus "*Bipolaris*."

Bipolaris is a genus of dematiaceous fungi known to cause disease in both immunocompetent and immunocompromised humans. *B. spicifera* and *B. hawaiiensis* are the most commonly recovered pathogenic species from human disease. *B. australiensis* is a relatively rare clinical isolate form cutaneous and subcutaneous lesions. *B. hawaiiensis* is an aggressive species and is isolated from cases of invasive sinusitis, brain lesions, sputum samples, and lung tissue. *B. australiensis* has been known to be involved in humans causing peritonitis, subcutaneous phaeohyphomycoses, fungal sinusitis, and disseminated infection.^[2] Ophthalmologic manifestations include keratitis, optic neuropathy from contiguous sinusitis, and endogenous endophthalmitis. Most common cause of mycotic keratitis is trauma in agricultural workers. Our patient sustained injury with cow tail. The three most common species – *B. spicifera*, *B. hawaiiensis*, and *B. australiensis* have all been reported as causative agents of mycotic keratitis.^[3–5] Most common isolate from the corneal lesion was *B. hawaiiensis*.^[3,4,6,7] and *B. spicifera* in two cases.^[5,8] Literature search showed only one report of keratitis due to *B. australiensis*.^[9] There was one case of keratitis due to *B. oryzae*.^[10]

Therapeutic options for *Bipolaris* infections are limited because many dematiaceous fungi are resistant to amphotericin B. Itraconazole shows consistent and potent activity against these organisms. *Bipolaris* is sensitive to topical natamycin. Our patient responded well to topical therapy with natamycin and ketoconazole. As the patient was responding well to combination of natamycin and ketoconazole, we did not change to itraconazole. Delay in the diagnosis led to endophthalmitis following *Bipolaris* keratitis in a case reported by Bashir *et al.*^[6] One patient underwent penetrating keratoplasty as there was no response to medical therapy.^[7] Of the eight reports of *Bipolaris* keratitis [Table 1], five reports were from India. However, none of them were caused by *B. australiensis*. Our patient is the first case report of *B. australiensis* keratitis from India. In 2012, genus *Bipolaris*, which comprises over 45 species had undergone taxonomic revisions based on molecular phylogenetic studies wherein the pathogen *B. australiensis* has now been shifted to the genus *Curvularia*.^[11]

In summary, although it is rare, *B. australiensis* can be implicated in ophthalmic infection. It should be considered as a potential pathogen, especially in high-risk group patients, such as farmers, who come in contact with cattle and are susceptible to cow tail injury of the eye. Early diagnosis and prompt therapy resulted in a favorable outcome in our patient.

Financial support and sponsorship

Nil.

Table 1: Global review of keratomycoses cases due to members of the genus *Bipolaris* with the site of involvement, ocular presentation, mode of penetrating injury, management, and outcome

Etiological agent	Site of involvement	Clinical presentation	History, mode of injury	Management	Outcome	Reference
<i>B. hawaiiensis</i>	RE	Corneal ulcer with hypopyon	Trauma, leprosy	Nystatin ointment	Resolved, no improvement in visual acuity due to opacity	Anandi <i>et al.</i> ^[3]
<i>B. hawaiiensis</i>	Both eyes	RE: Punctate keratitis LE: Corneal ulcer with hypopyon	RE: No trauma (lagophthalmos) LE: Trauma with paddy (history of borderline leprosy)	Topical ketoconazole	Resolved, thick corneal opacities in both eyes	Gopalakrishnan <i>et al.</i> ^[4]
<i>B. spicifera</i>	LE	Corneal ulcer with hypopyon	Spontaneous	5% topical natamycin, Nystatin C ointment, atropine, oral itraconazole, and diamox	Resolved, penetrating keratoplasty for corneal opacity	Saha and Das ^[5]
<i>B. hawaiiensis</i>	LE	Corneal ulcer with hypopyon	Trauma with rice stalk	Oral itraconazole, topical natamycin	Endophthalmitis, requiring evisceration	Bashir <i>et al.</i> ^[6]
<i>B. australiensis</i>	RE	Corneal ulcer with anterior chamber reaction	Spontaneous	Natamycin	Resolved	Durkin <i>et al.</i> ^[9]
<i>B. spicifera</i>	RE	Corneal abscess with hypopyon	Trauma with sugarcane	Natamycin and atropine	Resolved	Patil <i>et al.</i> ^[8]
<i>B. oryzae</i>	RE	Corneal ulcer	Splash of diesel oil from farming machine	Oral fluconazole, anterior lamellar keratoplasty, then oral itraconazole, Amphotericin B, ofloxacin, topical fluconazole	Resolved	Wang <i>et al.</i> ^[10]
<i>B. hawaiiensis</i>	LE	Corneal ulcer 63/male	Trauma with sawdust	Nystatin, atropine, sodium hyaluronate, subconjunctival fluconazole	No improvement, penetrating keratoplasty done	Chaidaroon <i>et al.</i> ^[7]

B. hawaiiensis: *Bipolaris hawaiiensis*, *B. spicifera*: *Bipolaris spicifera*, *B. australiensis*: *Bipolaris australiensis*, *B. oryzae*: *Bipolaris oryzae*, RE: Right eye, LE: Left eye

Conflicts of interest

There are no conflicts of interest.

References

- Manamgoda DS, Cai L, McKenzie EH, Crous PW, Madrid H, Chukeatirote E, *et al.* A phylogenetic and taxonomic re-evaluation of the *Bipolaris*-*Cochliobolus*-*Curvularia* complex. *Fungal Divers* 2012;56:131-44.
- Flanagan KL, Bryceson AD. Disseminated infection due to *Bipolaris australiensis* in a young immunocompetent man: Case report and review. *Clin Infect Dis* 1997;25:311-3.
- Anandi V, Suryawanshi NB, Koshi G, Padhye AA, Ajello L. Corneal ulcer caused by *Bipolaris hawaiiensis*. *J Med Vet Mycol* 1988;26:301-6.
- Gopalakrishnan K, Daniel E, Jacob R, Ebenezer G, Mathews M. Bilateral *Bipolaris* keratomycosis in a borderline lepromatous patient. *Int J Lepr Other Mycobact Dis* 2003;71:14-7.
- Saha R, Das S. *Bipolaris* keratomycosis. *Mycoses* 2005;48:453-5.
- Bashir G, Hussain W, Rizvi A. *Bipolaris hawaiiensis* keratomycosis and endophthalmitis. *Mycopathologia* 2009;167:51-3.
- Chaidaroon W, Supalaset S, Tananuvat N, Vanittanakom N. Corneal phaeohyphomycosis caused by *Bipolaris hawaiiensis*. *Case Rep Ophthalmol* 2016;7:364-71.
- Patil S, Kulkarni S, Gadgil S, Joshi A. Corneal abscess caused by *Bipolaris spicifera*. *Indian J Pathol Microbiol* 2011;54:408-10.
- Durkin SR, Henderson T, Raju R, Ellis D. Successful treatment of phaeohyphomycotic keratitis caused by *Bipolaris australiensis*. *Clin Exp Ophthalmol* 2008;36:697-9.
- Wang L, Al-Hatmi AM, Lai X, Peng L, Yang C, Lai H, *et al.* *Bipolaris oryzae*, a novel fungal opportunist causing keratitis. *Diagn Microbiol Infect Dis* 2016;85:61-5.