

Occurrence of vernal keratoconjunctivitis in children infected with human immunodeficiency virus

Vaishali L Une, Sourabh M Jadhav

Purpose: To study the occurrence of vernal keratoconjunctivitis (VKC) as an ocular manifestation of human immunodeficiency virus (HIV) in pediatric patients. **Methods:** A retrospective study was done on the observations of cases of HIV-positive children. All seropositive patients from the Anti-Retroviral Therapy clinic were referred to the department of ophthalmology for evaluation. Retrospective correlation of CD4 count with active cases of VKC was done. All patients underwent a comprehensive ophthalmic evaluation including visual acuity, slit lamp and dilated fundus examination. **Results:** A total of 72 children were included, 70 males and 2 females. Of these, 63 (87.5%) had VKC, three (4.2%) had cataract, two (2.8%) had cytomegalovirus retinitis, and four (5.5%) had no ophthalmic findings. **Conclusion:** There is an evident association of HIV, VKC cases, and reduced CD4 count. More research is required on this topic.

Key words: HIV, pediatric patients, vernal keratoconjunctivitis

Ocular involvement in human immunodeficiency virus (HIV) patients is now a known fact. HIV retinopathy, characterized by cotton wool spots, retinal hemorrhages, and microaneurysms are the most common ocular findings.^[1] Cytomegalovirus (CMV) retinitis is the most commonly seen opportunistic ocular infection in 15-40% of HIV patients and usually develop when the CD4 cell count is below 50 cells/cumm.^[2] There are several studies on vernal keratoconjunctivitis (VKC) in children. The mean incidence is 7.2/10,000.^[3] VKC children present with antinuclear antibodies (ANA positive) and 50% have familiar history of autoimmune disorders.^[4] Our research found only a single case report of association of VKC in HIV-positive children. In this study we included seropositive children who had vertical transmission of HIV.

Methods

This study was carried out in Government Medical College and Hospital, Aurangabad, India. It caters to various districts of central Maharashtra.

The study was undertaken after getting consent from Institutional Research Ethical committee and Department of Medicine, which is in charge of Anti-Retroviral Therapy centre at the institute.

The original study was aimed to find out the incidence of various ocular manifestations in children attending tertiary care center. It was observed that pediatric patients who were referred from Anti-Retroviral Therapy centre (sero-positive

children) for ophthalmic evaluation presented with complaints of itching, redness, and watering, and were diagnosed as VKC. All pediatric patients (upto 18 years of age) who were diagnosed as HIV positive referred from Anti-Retroviral Therapy clinic for ocular examination were included in the study. Adults and sero-negative children with VKC were excluded. Detailed anterior and posterior segment evaluation was done.

Examination

Ocular examination included visual acuity, slit-lamp examination, binocular indirect ophthalmoscopy, and refraction. Systemic examination included hemoglobin, total leukocyte count, differential leukocyte count, liver and kidney function tests, and serial CD4 counts. All the laboratory investigations were done as per Anti-Retroviral Therapy guidelines.

Symptoms

1. Mild Symptoms were itching and redness
2. Moderate symptoms were itching, redness, and watering
3. Severe symptoms were swollen lids, photophobia, and watering.

Ocular findings were conjunctival congestion in mild type, Horner Tranta's spots and large papillae and follicles in moderate and severe cases.

This is an open access journal, and articles are distributed under the terms of the Creative Commons Attribution-NonCommercial-ShareAlike 4.0 License, which allows others to remix, tweak, and build upon the work non-commercially, as long as appropriate credit is given and the new creations are licensed under the identical terms.

For reprints contact: WKHLRPMedknow_reprints@wolterskluwer.com

Cite this article as: Une VL, Jadhav SM. Occurrence of vernal keratoconjunctivitis in children infected with human immunodeficiency virus. Indian J Ophthalmol 2022;70:497-9.

Access this article online

Website:
www.ijo.in

DOI:
10.4103/ijo.IJO_1853_21

Quick Response Code:



Department of Ophthalmology, Shri Bhausaheb Hire Government Medical College, Dhule, Maharashtra, India

Correspondence to: Dr. Vaishali L Une, 'Salonika', B-6, Khinvasara Nilgiris, Ulkanagri, Aurangabad, Maharashtra, India. E-mail: lvaishali_53@rediffmail.com

Received: 09-Jul-2021

Revision: 14-Jul-2021

Accepted: 07-Oct-2021

Published: 27-Jan-2022

Grading of VKC

The children were clinically graded into the severity according to their symptoms. (Fig. 1 shows the clinical presentations). The children in our study had Grade 2, 3 and 4 VKC.^[5]

Grade 0: Quiescent

Grade 1: Papillae

Grade 2: Papillae + conjunctival hyperemia

Grade 3: Severe conjunctival hyperemia + Horner Tranta's spots

Grade 4: Corneal complications

Grade 5: Conjunctival Fibrosis.

Results

A total of 72 pediatric patients were included in the study. There were more number of children in 10–15 years of age ($n = 41$, 58.4%). The youngest patient was 6 years old and the oldest was 18 years old [Table 1]. Two (2.8%) had CMV Retinitis, and both were male. Four (5.5%) patients had no findings, and all were male patients [Table 2]. In this study, out of 72 cases, 63 (87.5%) patients had VKC, 61 patients were male and two females [Table 3]. Three boys (4.2%) had cataract.

Out of 63 patients with VKC, 23 belonged to 5–10-year age group, 38 belonged to 10–15-year age group, and two patients belonged to 15–18-year age group. All the three boys having cataract were in the various age categories. Both patients with CMV Retinitis belonged to 5–10-year age group. Out of 63 cases with VKC, 12 (19%) cases had mild VKC, 22 (35%) had moderate VKC, and 29 (46%) cases had severe VKC [Table 4]. Serial CD4 counts of patients ranged from 70 to 500 cu mm and low CD4 counts were associated with severe grade of VKC.

CMV retinitis in our study was found in 2.8%. This was associated with a drop of CD4 count below 50 cells/cumm.^[6] They were treated with anti-viral medications in consultation with the pediatrician.

We compared the incidences of VKC, cataract, and CMV retinitis with the non-HIV population. Our study had 87.5% of VKC as against 7.5% in the non-HIV group [Table 5]. On comparison with the published data on HIV and VKC, our study had the largest number of HIV-positive children with VKC [Table 6].

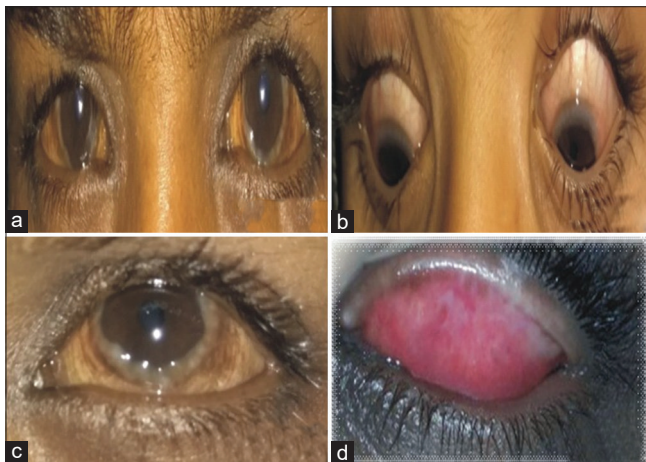


Figure 1: (a) conjunctival hyperemia (b) Horner Tranta spots (c) bulbar variety (d) palpebral variety

Discussion

Although VKC is commonly seen in children, its occurrence in sero-positive cases is alarming. Literature on the association of HIV seropositivity and VKC is scanty.^[9] However, Kritzinger *et al.*^[10] have published the data regarding the association of HIV and VKC-like disease in adults.

VKC in HIV children is more common in males as can be seen in our study with Male:Female ratio of 61:2. Agarwal *et al.*^[9] reported a single case of a 9-year-old male child. They have co-related the role of TH1 to TH2 shift.

Table 1: Age Distribution

Age group (Years)	Male	Female	Percentage
0-5	-	-	0
>5-10	26	1	37.5
>10-15	41	1	58.4
>15-18	03	0	4.1
Total	70	2	100

Table 2: Ocular Manifestations in HIV patients

Ocular Manifestations	Cases	Percentage
Vernal Keratoconjunctivitis	63	87.5
Cataract	3	4.2
CMV Retinitis	2	2.8
No findings	4	5.5
Total	72	100

Table 3: Gender-wise distribution of Ocular Manifestations

Ocular Manifestations	Male	Female
Vernal Keratoconjunctivitis ($n=63$)	61 (96.83%)	2 (31.74%)
Cataract ($n=3$)	3 (100%)	0
CMV Retinitis ($n=2$)	2 (100%)	0
No findings ($n=4$)	4 (100%)	0
Total	70	2

Table 4: Severity of Vernal Keratoconjunctivitis

Vernal Keratoconjunctivitis	Cases
Mild	12 (19%)
Moderate	22 (35%)
Severe	29 (46%)
Total	63

Table 5: Comparative data in HIV and non-HIV groups

	Our study HIV	Non-HIV	P
Vernal Keratoconjunctivitis	87.5%	7.5% ^[7]	0.000001
Cataract	4.2%	0.0001%	
CMV retinitis	5%	0% ^[8]	

Chi-square value=42.34

Table 6: Comparison of published data of HIV and VKC

Published studies	Authors	Materials and methods	Clinical features	Investigations
Vernal keratoconjunctivitis in HIV-the possible role of T-helper 1-t-helper 2 shift	Agarwal <i>et al.</i> ^[9]	Case report of a 9-year-old male	VKC associated with reduced CD4 and subsequent cataract	CD 4 counts
The role of HIV in the pathogenesis of VKC -like disease in adults: A demographic and epidemiological study	Kritzinger <i>et al.</i> ^[10]	33 patients (15-56 years old) 3 patients were <20 years old	VKC and decreased CD4 counts, pterygium and papilloma	ANA, CD4, IgE
Our study	Vaishali Une	72 children below 18 years of age	VKC with reduced CD4 counts, cataracts and CMV retinitis	CD4

Pediatric cataract in HIV-positive patients have also not been reported the best of our knowledge Adhikari *et al.*^[11] reported 0.0003% prevalence of congenital cataract in their study.

There is a steady decline in cases of vertical transmission due to setting up of Anti-Retroviral Therapy centers and easy availability of medications and treatment.

Over the years, there is a drastic reduction in vertical transmission due to better screening at antenatal care and treatment with antivirals, which has significantly reduced the rate of positivity in children born of HIV-positive mothers. Prevention of mother to child transmission programs are helpful in achieving the goal of zero transmission.^[12]

The HIV prevalence in general population (Antenatal Care clinic attendees) was 0.29% in 2014–15 and 0.25% in a study done by Radhika *et al.*^[13] In this present study, we had 87.5% cases of VKC in HIV-positive children, as compared to 7.5% cases of VKC in non-HIV children, which is statistically significant (P value = 0.000001) [Table 5]. 4.2% cases of cataract in HIV-positive children as compared to 0.0001% cases in non-HIV children.^[7]

Conclusion

VKC is highly prevalent in children who are HIV sero-positive. (87.5% cases in our present study). Males are predominantly infected with VKC as compared to females. It is associated with decreased immune status (reduced CD4 cell counts <500 cumm). Severe form of VKC is associated with depleted CD4 counts. Cataract was also associated with pediatric HIV patients (4.2%). This was the second most common ophthalmic finding in our present study. This is the first reported study on correlation between VKC and HIV positive children.

Acknowledgment

- Dr. Bhaskar Khaire, Professor and Head, Department of Ophthalmology
- Dr. Varsha Nandedkar, Professor and Head, Department of Ophthalmology, Government Medical College, Aurangabad
- Dr. Meenakshi Bhattacharya, Professor and Head, Department of Medicine, Government Medical College, Aurangabad
- Dr. Ruhi Shaikh, Assistance Professor, Anti-Retroviral Treatment Centre, Government Medical College,

Financial support and sponsorship

Nil.

Conflicts of interest

There are no conflicts of interest.

References

1. Holland GN, Pepose JS, Pettit TH, Gottlieb MS, Yee RD, Foos RY, *et al.* AIDS: Ocular manifestations. *Ophthalmology* 1983;90:859-73.
2. Henderly DE, Freeman WR, Smith RE, Causey D, Rao NA. Cytomegalovirus retinitis as the initial manifestation of the acquired immune deficiency syndrome. *Am J Ophthalmol* 1987;103:316-20.
3. Leonardi A, Busca F, Motterle L, Cavarzeran F, Fregona IA, Plebani M, *et al.* Case series of 406 vernal keratoconjunctivitis patients: A demographic and epidemiological study. *Acta Ophthalmol Scand* 2006;84:406-10.
4. Occasi F, Zicari AM, Petrarca L, Nebbioso M, Salvatori G, Duse M. Vernal Keratoconjunctivitis and immune-mediated diseases: One unique way to symptom control? *Pediatr Allergy Immunol* 2015;26:289-91.
5. Bonini S, Sacchetti M, Mantelli F, Lambiase A. Clinical grading of vernal keratoconjunctivitis. *Curr Opin Allergy Clin Immunol* 2007;7:436-41.
6. Viganó A, Principi N, Crupi L, Onorato J, Vincenzo ZG, Salvaggio A. Elevation of IgE in HIV-infected children and its correlation with the progression of disease. *J Allergy Clin Immunol* 1995;95:627-32.
7. Khokhar SK, Pillay G, Dhull C, Agarwal E, Mahabir M, Aggarwal P. Pediatric cataract. *Indian J Ophthalmol* 2017;65:1340-9.
8. Wren SM, Fielder AR, Bethell D, Lyall EG, Tudor-Williams G, Cocker KD, *et al.* Cytomegalovirus retinitis in infancy. *Eye (Lond)* 2004;18:389-92.
9. Agarwal S, Srinivasan B, Iyer G, Sudharshan S, Kalaivani K. Vernal keratoconjunctivitis in human immunodeficiency virus - The possible role of T-helper 1-T-helper 2 shift. *Indian J Ophthalmol* 2018;66:1004-6.
10. Kritzinger A, Zaborowski AG, Sibanda W, Visser L. The role of human immunodeficiency virus in the pathogenesis of vernal keratoconjunctivitis-like disease in adults: A demographic and epidemiological study. *Indian J Ophthalmol* 2020;68:1551-4.
11. Adhikari P, Chetty P. Cataract, strabismus and chorioretinal coloboma in paediatric HIV infection. *J Optom* 2017;10:268-70.
12. Tamir H, Krupp K, Stephens DP, Zohourian T, Dorcius PM, Arun A, *et al.* Addressing prevention among HIV-uninfected women in PMTCT programs in South India. *J Assoc Nurses AIDS Care* 2018;29:45-52.
13. Radhika AG, Chawla S, Bhaskaran S. Prevention of parent to child transmission of HIV: Single centre experience of 14 years at tertiary care hospital in Delhi, India. *J Clin Diagn Res* 2017;11:QC04-7.