

Epidural hematoma after caudal epidural pulsed radiofrequency stimulation

A case report

Sang Woo Kim, MD^a, Min Cheol Chang, MD^{b,*}

Abstract

Rationale: Epidural hematoma is a possible complication after neuraxial procedures. Recently, caudal epidural pulsed radiofrequency (PRF) stimulation was reported as an effective method for controlling several types of chronic pain. Herein, we report on a patient who developed a lumbar epidural hematoma after receiving caudal epidural PRF stimulation.

Patient concerns: A 75-year-old woman, who was taking oral warfarin (2 mg/d), received caudal epidural PRF stimulation for symmetrical neuropathic pain in both legs due to chronic idiopathic axonal polyneuropathy. She did not discontinue warfarin use before undergoing the procedure. Three days and 12 hours after the procedure, motor weakness suddenly manifested in the right leg (manual muscle testing [MMT] = 2–3).

Diagnoses: Lumbar magnetic resonance imaging (MRI) performed 7 days after the PRF procedure showed a spinal epidural hematoma at the L1 to L5 levels, compressing the thecal sac. The international normalized ratio was 6.1 at the time of the MRI.

Interventions: Decompressive laminectomy from L1 to L5 with evacuation of the hematoma was performed.

Outcomes: Three months postoperatively, the motor weakness in the patient's right leg improved to MMT = 4 to 5.

Lessons: This case suggests that clinicians should carefully check if patients are taking an anticoagulant medication and ensure that it is discontinued for an appropriate length of time before a caudal epidural PRF procedure is performed.

Abbreviations: CIAP = chronic idiopathic axonal polyneuropathy, INR = international normalized ratio, MMT = manual muscle testing, MRI = magnetic resonance image, PRF = pulsed radiofrequency.

Keywords: caudal epidural stimulation, chronic idiopathic axonal neuropathy, epidural hematoma, pulsed radiofrequency

1. Introduction

Recently, pulsed radiofrequency (PRF) stimulation has been used for managing several types of chronic pain.^[1–6] Although the mechanism of its pain-relieving effects has not been clearly elucidated, the electrical field generated by PRF has been suggested to be responsible for its clinical effect.^[7] Typically, PRF is applied to nerve tissues like the dorsal root ganglia and medial branch nerves of the spine^[1,5]; however, depending on the origin of pain, various PRF stimulation methods, such as

intraarticular, interfascial, and caudal epidural stimulations, are being applied.^[3,4,6] Caudal epidural PRF stimulation is used for alleviating chronic idiopathic axonal polyneuropathy (CIAP), coccygodynia, and postherpetic neuralgia.^[4,8,9] Previous studies reported the effectiveness of PRF for managing several kinds of chronic pain^[4,8,9]; however, the complications have not been reported.

Epidural hematoma is one complication that can occur after neuraxial procedures, such as interlaminar epidural and caudal steroid injections.^[10–13] The damage of neural structures from an epidural hematoma results from the expansion of the hematoma within the enclosed space of the spinal canal and can be devastating if early decompression is not performed.^[14] Anticoagulation with heparin and warfarin is known to be one of the most important risk factors for epidural hematoma after neuraxial procedures.^[15]

In the present study, we report a case involving the development of an epidural hematoma after a caudal epidural PRF stimulation in a patient who was taking warfarin.

2. Case report

A 75-year-old woman underwent caudal epidural PRF stimulation at the rehabilitation department in our hospital to alleviate chronic neuropathic leg pain due to CIAP lasting for 9 years. She had symmetrical neuropathic pain rated as a 6 on a numeric rating scale localized to the bilateral legs below knees. The electrophysiologic findings were compatible with a diagnosis of axonal sensory polyneuropathy.

Editor: N/A.

This work was supported by the National Research Foundation of Korea (NRF) grant funded by the Korea government (MSIT) (NRF-2017R1C1B5017714).

The authors have no conflicts of interest to disclose.

^aDepartment of Neurosurgery, ^bDepartment of Physical Medicine and Rehabilitation, Spine Center, College of Medicine, Yeungnam University, Namku, Daegu, Republic of Korea.

*Correspondence: Min Cheol Chang, Department of Physical Medicine and Rehabilitation, College of Medicine, Yeungnam University, 317-1 Daemyungdong, Namku, Daegu 705-717, Republic of Korea (e-mail: wheel633@gmail.com).

Copyright © 2018 the Author(s). Published by Wolters Kluwer Health, Inc. This is an open access article distributed under the terms of the Creative Commons Attribution-Non Commercial-No Derivatives License 4.0 (CCBY-NC-ND), where it is permissible to download and share the work provided it is properly cited. The work cannot be changed in any way or used commercially without permission from the journal.

Medicine (2018) 97:45(e13090)

Received: 17 July 2018 / Accepted: 11 October 2018

<http://dx.doi.org/10.1097/MD.0000000000013090>

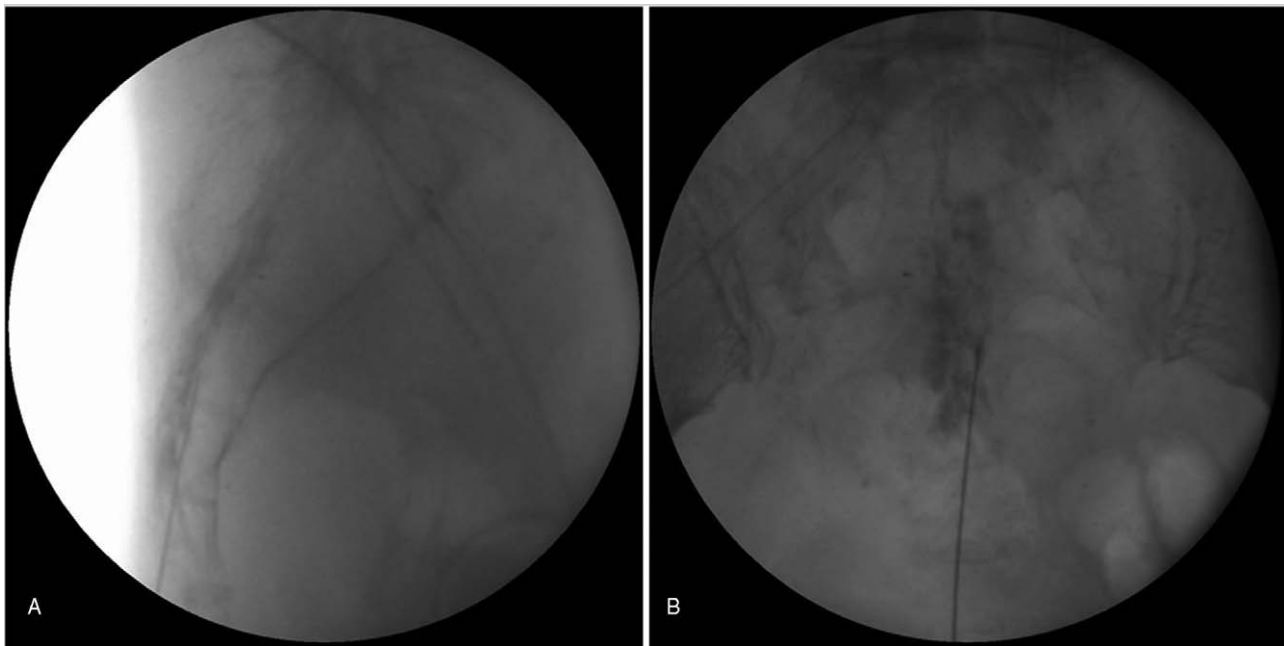


Figure 1. Fluoroscopy-guided caudal epidural pulsed radiofrequency (PRF) stimulation procedure. (A) Lateral view. (B) Anteroposterior view. A 22-gauge curved-tip cannula was inserted into the epidural space (S3 vertebral level) through the sacral hiatus and the caudal epidural space was confirmed using contrast.

The caudal epidural PRF stimulation was performed under fluoroscopy guidance (Fig. 1). A 22-gauge cannula (SMK pole needle, 150 mm with a 20 mm active tip; Cotop International BV, Amsterdam, the Netherlands) was inserted to the epidural space through the sacral hiatus.^[4] The needle tip was advanced to the S3 vertebral body level. After confirming correct needle placement with contrast dye, an electrode was connected to the cannula and stimulation was conducted (Cosman G4 radiofrequency generator, Cosman Medical, Burlington, MA). PRF was administered at 5 Hz using a 5-ms pulse width for 600 s at 55 V so as not to exceed an electrode tip temperature of 42°C. Three days and 12 hours after the PRF procedure, the patient developed motor weakness in the right leg. During the next 3.5 days, the patient observed her symptoms by herself without any treatment. One week after the PRF procedure, she visited our department due to the motor weakness. On the physical examination, her motor power was as follows (manual muscle testing [MMT]): hip flexor 2/5, knee extensor 2/5, ankle dorsiflexor 3/5, and extensor hallucis longus 3/5. In addition, decreased sensation with light touch and pinprick was noted in the right L2-4 dermatomes. Motor weakness and sensory deficits were not found on the left leg, and bladder and bowel symptoms were not present. Based on the medical history, she reported that she was taking oral warfarin (2 mg/d) for preventing recurrent pulmonary embolism, and the international normalized ratio (INR) was 6.1.

A lumbar magnetic resonance image (MRI) was urgently obtained, which showed a spinal epidural hematoma from the L1 to L5 levels, which was large enough to cause thecal sac compression (Fig. 2). Posterior approach and decompressive subtotal laminectomy on L1 and total laminectomy on L2 to L5 with evacuation of the hematoma were performed. During the operation, neither a bleeding focus nor an abnormal vessel was not found. Three months after the operation, the patient's motor weakness in the right hip flexor and knee extensor had improved to MMT 4. Motor weakness in right ankle dorsiflexor and

extensor hallucis longus and sensory deficits in right leg were not observed. Written informed consent was obtained from the patient for publication of this case report. The study was approved by the local Institutional Review Board of our hospital.

3. Discussion

We report a patient who had an epidural hematoma after a caudal epidural PRF stimulation procedure. Kreppel et al performed the meta-analysis, and reported that idiopathic, anticoagulant therapy, vascular malformation, and spinal procedure are the most common causes of epidural hematoma.^[16] Considering the fact that a bleeding focus or abnormal vessel was not observed in our patient during the operation, and the history of the PRF procedure 3 to 4 days before the diagnosis of epidural hematoma, there is a high possibility that epidural hematoma occurred due to the caudal epidural PRF stimulation procedure. We believe that the epidural hematoma resulted from the piercing or injury of the plexus of epidural veins or the epidural arteries which surround the epidural space. The blood from the injured vessels in the sacral epidural space seems to have risen to the L1 to L5 level on the spinal canal.

In our patient, before the procedure, the bleeding risk was not evaluated despite the fact that she was taking oral warfarin daily. Because patients taking anticoagulants are at risk for bleeding during spinal procedure, Spine Intervention Society stated that anticoagulants should be discontinued ≥ 4 days before spinal procedures with a normalized INR level.^[17] Therefore, in our case, we should have instructed the patient to stop oral warfarin ≥ 4 days before the procedure and perform the PRF procedure after the INR level was normalized.

In addition, in our patient, although the outcome of neurological recovery was relatively complete, diagnosis and treatment were delayed by 3.5 days. Several studies reported that rapid diagnosis and emergency surgical treatment could minimize nerve injury and maximize neurological recovery.^[14,18,19]

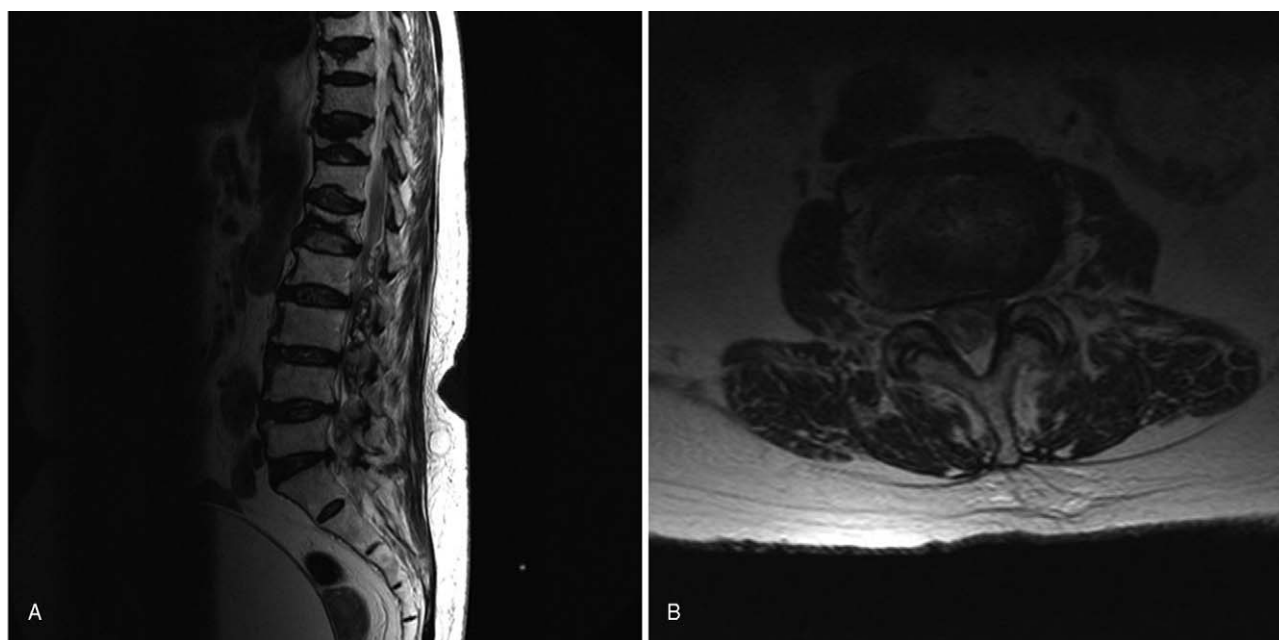


Figure 2. Magnetic resonance image one week after the PRF procedure shows (A) spinal epidural hematoma at L1 to L5 in sagittal T2-weighted image and (B) thecal sac compression by hematoma at the L3 to L4 level in the axial T2-weighted image.

Delayed diagnosis and delayed treatment of an epidural hematoma can lead to a poor outcome, thus it is necessary to inform patients who have risk factors for bleeding of the possibility of epidural hematoma after the procedure and to explain the need to visit the hospital emergently if neurological symptoms occur. Moreover, the epidural venous plexus is gathered in the anterior part of the sacral canal and usually ends at the S4 level or lower.^[20] Therefore, a caudal epidural PRF stimulation procedure can injure the venous plexus and cause a spinal epidural hematoma. Use of small-gauge cannulas would help in decreasing the possibility of vessel trauma.

So far, several studies reported the occurrence of epidural hematoma after spinal procedures^[10–13]; however, regarding the procedure performed through the sacral hiatus, only 1 study has reported an epidural hematoma. In 2017, Choi reported a lumbar epidural hematoma from the L2-S1 levels with concomitant central canal compromise at the L2/L3 and L3/L4 levels about 6 hours after caudal epidural steroid injection.^[11] The patient's symptoms were completely resolved after an emergent operation.

In the present study, we reported a patient who had a lumbar epidural hematoma and presented with motor weakness and sensory deficits in right leg after caudal epidural PRF stimulation. This is the first study to report the occurrence of an epidural hematoma after a caudal epidural PRF stimulation. Clinicians should carefully check whether a patient is taking an anticoagulant medication and discontinue the medication ≥ 4 days before spinal procedure. Also, clinicians should be mindful of the possibility of this complication when performing neuraxial procedures, such as caudal epidural PRF stimulation.

Author contributions

Conceptualization: Sang Woo Kim.
Data curation: Sang Woo Kim.
Methodology: Min Cheol Chang.
Resources: Sang Woo Kim.

Writing – original draft: Sang Woo Kim, Min Cheol Chang.
Writing – review and editing: Min Cheol Chang.

References

- [1] Arsanious D, Gage E, Koning J, et al. Pulsed dose radiofrequency before ablation of medial branch of the lumbar dorsal ramus for zygapophysial joint pain reduces post-procedural pain. *Pain Physician* 2016;19:477–84.
- [2] Chang MC. Efficacy of pulsed radiofrequency stimulation in patients with peripheral neuropathic pain: a narrative review. *Pain Physician* 2018;21:E225–34.
- [3] Cho IT, Cho YW, Kwak SG, et al. Comparison between ultrasound-guided interfascial pulsed radiofrequency and ultrasound-guided interfascial block with local anesthetic in myofascial pain syndrome of trapezius muscle. *Medicine (Baltimore)* 2017;96:e6019.
- [4] Lee DG, Chang MC. The effect of caudal epidural pulsed radiofrequency stimulation in patients with refractory chronic idiopathic axonal polyneuropathy. *Pain Physician* 2018;21:E57–62.
- [5] Lee DG, Cho TW, Ahn SH, et al. The effect of bipolar radiofrequency treatment on chronic lumbosacral radicular pain refractory to monopolar pulsed radiofrequency treatment. *Pain Physician* 2018;21:E97–103.
- [6] Sluijter ME, Teixeira A, Serra V, et al. Intra-articular application of pulsed radiofrequency for arthrogenic pain—report of six cases. *Pain Pract* 2008;8:57–61.
- [7] Van Zundert J, de Louw AJ, Joosten EA, et al. Pulsed and continuous radiofrequency current adjacent to the cervical dorsal root ganglion of the rat induces late cellular activity in the dorsal horn. *Anesthesiology* 2005;102:125–31.
- [8] Atim A, Ergin A, Bilgiç S, et al. Pulsed radiofrequency in the treatment of coccygodynia. *Agri* 2011;23:1–6.
- [9] Rohof OJ. Caudal epidural of pulsed radiofrequency in post herpetic neuralgia (PHN); report of three cases. *Anesth Pain Med* 2014;4:e16369.
- [10] Alkhudari AM, Malk CS, Rahman A, et al. Epidural hematoma after routine epidural steroid injection. *Surg Neurol Int* 2016;7:55.
- [11] Choi JJ, Chang YJ, Jung WS, et al. Discordant lumbar epidural hematoma after caudal steroid injection: a case report (CARE-compliant). *Medicine (Baltimore)* 2017;96:e7127.
- [12] Page J, Moisi M, Oskouian RJ. Lumbar epidural hematoma following interlaminar fluoroscopically guided epidural steroid injection. *Reg Anesth Pain Med* 2016;41:402–4.

- [13] Sanders RA, Bendel MA, Moeschler SM, et al. Epidural hematoma following interlaminar epidural injection in patient taking aspirin. *Reg Anesth Pain Med* 2018;43:310–2.
- [14] Goodman BS, Posecion LW, Mallempati S, et al. Complications and pitfalls of lumbar interlaminar and transforaminal epidural injections. *Curr Rev Musculoskelet Med* 2008;1:212–22.
- [15] Morse K, Weight M, Molinari R. Extensive postoperative epidural hematoma after full anticoagulation: case report and review of the literature. *J Spinal Cord Med* 2007;30:282–7.
- [16] Kreppel D, Antoniadis G, Seeling W. Spinal hematoma: a literature survey with meta-analysis of 613 patients. *Neurosurg Rev* 2003;26:1–49.
- [17] Bogduk N. *Practice Guidelines for Spinal Diagnostic and Treatment Procedures*. San Francisco. International Spine Intervention Society, 2nd ed. 2013:9–17.
- [18] Baek BS, Hur JW, Kwon KY, et al. Spontaneous spinal epidural hematoma. *J Korean Neurosurg Soc* 2008;44:40–2.
- [19] Yu HP, Fan SW, Yang HL, et al. Early diagnosis and treatment of acute or subacute spinal epidural hematoma. *Chin Med J (Engl)* 2007;120:1303–8.
- [20] Ogoke BA. Caudal epidural steroid injections. *Pain Physician* 2000;3:305–12.