

Evaluation of three different tooth preparation techniques for metal ceramic crowns by comparing preparation depths: An *in vitro* study

Hardik K. Ram, Rupal J. Shah¹, Hemal S. Agrawal¹

Department of Prosthodontics, Siddhpur Dental College and Hospital, Siddhpur, ¹Department of Prosthodontics, Government Dental College and Hospital, Ahmedabad, Gujarat, India

Abstract

Aim: To determine the effect of three different tooth preparation techniques had on operator's ability to appropriately and consistently prepare teeth for metal ceramic crowns.

Materials and Methods: Ninety maxillary left central incisor typodont teeth were allocated to three equal groups (A, B and C) of thirty and mounted in standard working model one at a time. A freehand approach was used to prepare the teeth in Group A, which acted as a control. Groups B and C were prepared with the assistance of silicon index and suitable depth gauge burs, respectively. A silicon index of unprepared teeth, into which contrasting colored silicon injected to occupy the space created by tooth preparation, was sectioned in the midline. Images of sectioned index were captured with optical microscope attached to a personal computer. A calibrated image analysis software was used to measure the depth of preparation (in millimeters) at five points (labial-cervical, mid-labial, incisal, mid-palatal and palatal cervical) on two occasions. These results were pooled and averaged to give a mean labial, incisal and palatal preparation depths in mm. The data were analyzed by one-way analysis of variance and Scheffe's *post-hoc* statistical test.

Results: The mean depth of labial and incisal preparation for Groups A, B and C was 1.23 and 1.72 mm, 1.45 and 1.96 mm, 1.47 and 1.95 mm, respectively. The difference between the groups' labial preparation depth was significant as well as the difference between groups' incisal preparation depth. The mean palatal preparation was 0.46 mm for Group A, 0.54 mm for Group B and 0.59 mm for Group C.

Conclusion: Teeth preparation for metal ceramic crowns without any assistance can lead to under-preparation of labial and incisal surface.

Clinical Significance: Whenever possible, considerable importance should be given to the use of index or depth gauge burs for preparing teeth for receiving metal ceramic crowns.

Key Words: Comparison, depth gauge bur, experimental, *in vitro*, silicon index

Address for correspondence:

Dr. Hardik Keshubhai Ram, L.I.G-1, 2/13, Gokul Flats, GIDC, Naroda, Ahmedabad - 382 330, Gujarat, India. E-mail: drhkram@gmail.com

Received: 14th January, 2015, **Accepted:** 28st April, 2015

Access this article online	
Quick Response Code:	Website: www.j-ips.org
	DOI: 10.4103/0972-4052.159961

This is an open access article distributed under the terms of the Creative Commons Attribution-NonCommercial-ShareAlike 3.0 License, which allows others to remix, tweak, and build upon the work non-commercially, as long as the author is credited and the new creations are licensed under the identical terms.

For reprints contact: reprints@medknow.com

How to cite this article: Ram HK, Shah RJ, Agrawal HS. Evaluation of three different tooth preparation techniques for metal ceramic crowns by comparing preparation depths: An *in vitro* study. J Indian Prosthodont Soc 2015;15:162-7.

INTRODUCTION

In spite of the increasing popularity of all-ceramic restorations, general dental practitioners still consider the metal ceramic crown an established treatment for extensively restored teeth, particularly where a combination of durability and esthetics are required.^[1] In many dental practices, it is one of the most widely used fixed restorations.

The restoration consists of a complete coverage cast metal crown (or substructure) that is veneered with a layer of fused porcelain to mimic the appearance of the natural tooth.^[2] Preparation features for metal ceramic crowns have been periodically reported in the dental literature, and it is universally accepted that finish line configuration and position in relation to the gingival tissues can influence the longevity and esthetics of the final restoration.^[3-5] The minimum thickness of porcelain and metal required for metal ceramic crowns, dependent on the alloy used, is 0.7 and 0.5 mm, respectively; it is accepted that a labial reduction of 1.5 mm is required to achieve this.^[3-5]

Chandler^[6] reported that a 1.5 mm reduction left more than a quarter (25%) of teeth with <0.5 mm of peripulpal dentin, leaving little room for operator error during tooth preparation. Excessive reduction led to pulpal exposure and subsequent loss of vitality, which can lead to early failure of the restored unit. A minimal incisal reduction of 2 mm is recommended to prevent an excessively long crown or a blunt incisal table.

Successful technical reproduction of anatomic contours and profiles in metal ceramic crowns is dependent on adequate tooth preparation. Under-reduction will result in inappropriate labial and palatal contours, leading to compromised esthetics.^[7] Overbulking of the crown at the gingival margin may be necessary to allow for adequate material strength, which results in a poor emergence profile. Several studies considered an improper emergence profile as a significant etiologic factor in the marginal inflammation associated with crowns.^[8] Insufficient labial reduction, particularly near the finish line, may also result in distortion of the metal substructure during fabrication and clinical service. This leads to poor marginal adaptation, debonding, and long-term cement failure, all of which have been cited as major factors in the failure of metal ceramic crowns.^[8,9]

A failed crown has been described as one that was unserviceable, thus requiring repair or replacement.^[10] Inadequate tooth preparation can lead to esthetic failures.^[11] Biological failures such as caries, periodontal disease, and endodontic or periapical pathology may also result from inappropriate tooth preparation.^[12] Thus, inadequate quality of tooth preparation

seems to be a common threat contributing to metal ceramic crown failure.

The marginal configuration and geometry of metal ceramic crowns have been reviewed recently. Several designs have been advocated to optimize esthetics, minimize marginal openings, and reduce stress concentration at the marginal aspect. The flat shoulder margin provides the required esthetics and marginal stability necessary during porcelain firing, and it is the most suitable for a labial finish line for anterior crowns.^[3,4] A chamfer finish provides the least stress and marginal opening for a metal-only finish and is therefore indicated for the lingual/palatal aspect where esthetics are not a primary concern, allowing for the preservation of tooth structure.^[3]

In vitro studies evaluating preparations completed by dentists for metal ceramic crowns have been reported.^[13] All studies reported a tendency for clinicians to underprepare teeth when a freehand approach was used. This tendency occurred in spite of the better access and visibility afforded by an *in vitro* experimental setup. In most of the studies carried out in the past, teeth were mounted in individual plaster block so there were no adjacent and opposing teeth for comparison. Tooth preparation in the presence of adjacent and opposing teeth will more closely mimic the clinical situation. The use of indexes or suitable depth gauge burs are two recognized methods of improving the accuracy of preparation features.

Aim

To investigate the effect an index and a depth gauge bur had on an operator's ability to appropriately and consistently prepare teeth for metal ceramic crowns. The null hypothesis was that the use of an index or depth gauge bur had no effect on practitioner's ability to appropriately and consistently prepare teeth for metal ceramic crowns.

MATERIALS AND METHODS

To determine the exact sample size, pilot study was conducted on five maxillary left central incisor typodont teeth for two different groups (Group A freehand preparation and Group B use of silicon putty index as a guide). The labial preparation was done, and the mean and standard deviation of labial preparation for Group A and Group B were calculated. The result of the pilot study showed that the mean difference was 0.02 between two groups, considering this mean difference and 80% power of study at 95% confidence interval the sample size estimated was 26 in each group. This figure was rounded, and the final sample size was taken as 30 samples in each group. It was parallel study so 1:1:1 treatment was assigned randomly to subjects in three independent groups. Accordingly, 90 maxillary left central incisor typodont teeth used in the

study were allocated to three equal groups (A, B and C) of 30. Teeth were mounted in the Frasaco standard working model A-3 (Frasaco USA, Prexicon Inc.,) [Figure 1] one at a time to standardize the angulation and before starting preparation sectional index that could be reconstructed over the original tooth was produced using an addition cured silicone impression material (Aquasil, Dentsply Detrey GmbH, Germany) [Figure 2]. Teeth were prepared for metal ceramic crown requiring shoulder finish line on the labial aspect for metal ceramic finish and chamfer finish line palatally for metal finish using standard tooth preparation burs (Shofu Inc., Kyoto, Japan).

Teeth allocated in Group A were prepared with freehand approach without using any extra guide for preparation. Before starting tooth preparation for Group B, one more silicon putty index was prepared including one tooth on either side of the tooth being prepared. This index was sectioned vertically and horizontally using scalpel. This sectioned index was used as a guide during tooth preparation procedure to check and recheck

at each step whether the required amount of tooth preparation is achieved or not [Figures 3 and 4]. For teeth allocated in Group C, the labial and incisal reduction were done with depth gauge burs (Shofu Inc., Kyoto, Japan) (1.5 mm). Palatal reduction in this group was completed using freehand approach.

After the tooth preparation for each group was completed, silicon putty index made prior to tooth preparation was reconstructed and a light body addition cured silicone of contrasting color, injected into the index to occupy the space created by tooth preparation. The index was then sectioned axially along the midline of the prepared tooth with a scalpel and the left-hand side mounted on a microscope slide. An optical microscope (Olympus), with a resolution of ± 0.02 mm, attached to a personal computer was used to capture an image of the sectioned relined index [Figure 5]. The magnification used for the measurement was $\times 10$. Images captured by optical microscope were subsequently analyzed by image analysis software (Klonk Image Measurement) by [image measurement corporation].

Measurement protocol

As shown in Figure 6, contrasting colored light bodied silicon thickness gave the actual amount of preparation depth. After transferring images for each specimen to computer, image

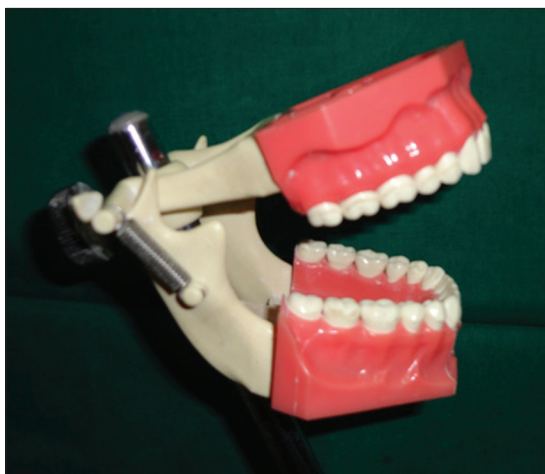

Figure 1: Frasaco standard working model A-3



Figure 3: Silicon putty index used as a guide for preparation of Group B samples

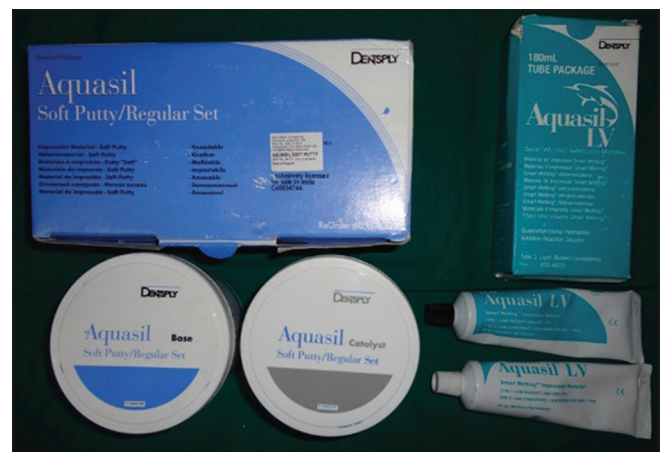

Figure 2: Addition cured silicon impression material – soft putty and light-bodied consistency

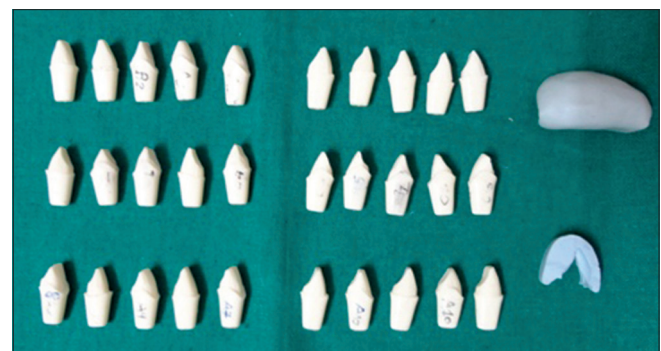


Figure 4: Group B samples prepared with silicon putty index as a guide

analysis software (Klonk Image measurement) was set for millimeter unit measurement. After unit setting for particular image, line was drawn across the thickness of the light-bodied silicon that we wanted to measure. When we completed the line and left the cursor, software gave the length of that line in mm [Figure 6]. After dividing that reading by magnification factor 10, we got the preparation depth for that area. This procedure was repeated at five sites namely the labial-cervical, mid-labial, incisal, mid-palatal and palatal-cervical aspects on two occasions. These results were averaged to give a mean labial, incisal and palatal reduction for each preparation.

Statistical analysis

Statistical analysis was performed using analysis of variance and then Tukey honestly significantly different tests for comparisons among groups at the 0.05 level significance [Tables 1 and 2].

RESULTS

The mean depths of labial, incisal and palatal preparation for Groups A, B and C are summarized in Table 1 and Figure 7.

For labial and incisal preparation, mean values of Group A were significantly lower than the mean values in Group B and Group C ($P < 0.001$) and Group B and Group C were nonsignificant to each other ($P > 0.05$) [Table 2].

For palatal preparation, mean values of Group A were significantly lower than the mean values in Group B and Group C ($P < 0.001$) and mean values of Group B were significantly lower than the mean values in Group C ($P < 0.001$) [Table 2].

Table 1: Mean and SD of labial, incisal and palatal preparation for Groups A, B and C in mm where ** is equal to highly significant

Groups	Labial preparation	Incisal preparation	Palatal preparation
A (n=30)	1.23±0.03	1.72±0.05	0.46±0.02
B (n=30)	1.45±0.02	1.96±0.03	0.54±0.03
C (n=30)	1.47±0.01	1.95±0.03	0.59±0.02
F (P)	687.14 (<0.001**)	289.65 (<0.001**)	155.69 (<0.001**)

**Highly significant $P < 0.001$. SD: Standard deviation

Table 2: Post-hoc statistical analysis by Tukey HSD test for multiple comparisons among groups where ** is equal to highly significant

Preparation	Groups	Mean difference
Labial	A versus B	-0.22**
	A versus C	-0.23**
	B versus C	-0.02
Incisal	A versus B	-0.23**
	A versus C	-0.22**
	B versus C	0.01
Palatal	A versus B	-0.07**
	A versus C	-0.12**
	B versus C	-0.05**

**Highly significant $P < 0.001$. HSD: Honestly significantly different

DISCUSSION

The predictability and consistency of positive clinical results, validated by long-term scientific evidence, the ease and




Figure 5: Microscopic view: Relined and sectioned index of Group B sample




Figure 6: How to measure preparation depths on image captured from microscope

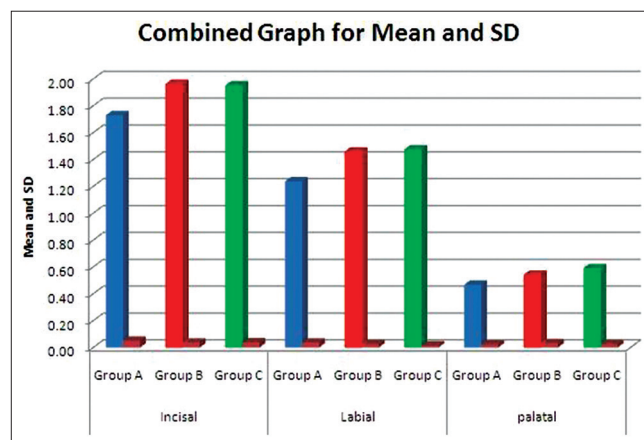


Figure 7: Comparison of preparation depths for incisal, labial and palatal preparations between Groups A, B and C through graphical presentation

accuracy of the conventional casting procedures, as well as the findings of rare adverse reactions to precious alloys have made porcelain-fused-to-metal crowns and bridges more and more popular and widespread over time.^[14] This study found that under-preparation of the labial aspect of teeth occurred when a freehand approach was adopted for the preparation of teeth to receive metal ceramic crowns. This finding is in favor of the studies done by Aminian and Brunton^[15] which stated that when teeth were prepared using freehand approach, under-preparation is common on labial aspect.

If there is to be the sufficient bulk of porcelain for appearance and metal for strength, adequate reduction of the labial surface is essential. The exact amount of reduction will depend to some extent on the physical properties of the alloy used for the substructure as well as on the manufacturer and the shade of the porcelain. A minimum reduction of 1.5 mm typically is required for optimal appearance. The adequate thickness of porcelain is needed to create a sense of color depth and translucency. Shade problems are frequently encountered in maxillary incisor crowns at the incisal and cervical thirds of the restoration, where direct light reflection from the opaque layer can make the restoration appear very noticeable.^[2]

The labial aspect of the preparation, particularly in the cervical region, requires careful consideration during tooth preparation to prevent under-preparation. This will affect the emergence profile of the restoration and cause technical difficulties when the restoration is produced, possibly with insufficient porcelain or metal or an over bulbous crown. Parkinson^[16] in his study concluded that the creation of artificial crown contours that are greater than natural tooth convexities must be considered a parameter promoting endemic plaque niches. Under-reduced finish lines may also predispose the restoration to technical failure arising from metal flexure and subsequent porcelain fracture or cement loss.

In this study, under-preparation of the incisal surfaces of teeth occurred when a freehand approach was adopted for the preparation of teeth to receive metal ceramic crowns. This finding is not in favor of study done by Aminian and Brunton^[15] according to which over reduction of incisal surfaces of teeth occurred when teeth were prepared with freehand approach to receive metal ceramic crowns. However, it may be due to the fact that Brunton *et al.* had carried out their study on typodont teeth mounted in individual plaster block without any adjacent teeth for visual comparisons whereas this study was carried out on typodont teeth mounted on working model where adjacent and opposing teeth were present for visual comparisons even during freehand approach.

The incisal edge of a metal ceramic restoration has no metal backing and can be made with a translucency similar to that

of natural tooth structure. An incisal reduction of 2 mm is recommended for good esthetics. Labial and incisal reduction was found to be accurate and consistent when teeth were prepared with the aid of depth gauge burs and silicone indices; consequently, the null hypothesis was rejected.

Results of this study showed over reduction of palatal surfaces of teeth when prepared with depth gauge burs and with the use of putty index as guide compared with freehand approach that showed nearly ideal palatal reduction. This finding is also in favor of the study done by Aminian and Brunton^[15] according to which over reduction of palatal surfaces of teeth occurred when teeth were prepared with depth gauge burs.

Tooth surfaces prepared with a freehand approach in this study (all surfaces of Group A teeth and palatal surfaces of Group C teeth) relied solely on visual acuity to assess the amount of tissue removal. Comparing the prepared tooth with an adjacent unprepared tooth may assist this visual decision making. Visual perception is also necessary for directly assessing preparation depths when indexes are used. When replacing the index over the prepared tooth, the depth of preparation must be evaluated and adjusted accordingly. The potential limitations of visual assessment of preparations may account for the underprepared labial aspects of the preparations performed with a freehand approach. A freehand approach was used for the preparation of the palatal aspect of teeth in Group A, and accurate reduction was achieved. Further research is necessary to investigate why freehand preparation of palatal surfaces appears to be more accurate than freehand reduction of the labial surface.

Group B teeth prepared with the use of a silicone index displayed accurate labial and incisal depth of preparation, although the palatal reduction tended to be somewhat excessive. Similarly, the palatal surface was over prepared to a statistically significant level when a depth gauge bur was used. Further research is necessary to investigate a possible pattern of palatal over preparation when index and depth gauge burs are used to aid in assessing tooth removal.

In comparing the depth of preparation at the labial cervical and mid-labial aspects, it is possible to evaluate each technique in terms of maintaining the 2 or 3 anatomic planes of the labial profile. This is an important consideration, because failure to reproduce the anatomic planes of the natural tooth during tooth preparation will create further technical limitations in terms of providing the best esthetic result, as well as needlessly sacrifice further tooth tissue and cause loss of retention and resistance form. Anatomic preparation of the labial aspect of the tooth may be more readily achieved with the use of indexes or depth gauge burs, but further research is needed to establish this.

In this study, tooth preparation was done by single operator and there is a scope for further research in future by two dentists one of which should be relatively inexperienced and the other should have good experience of this field to check whether experience makes any difference to the results of freehand preparation or not.

Clinical implications

The major factors in the failure of metal ceramic crowns like compromised esthetics, poor emergence profile, distortion of the metal substructure during fabrication can be overcome by achieving adequate preparation depths using putty index and depth gauge burs during tooth preparation. The different methods of preparation techniques discussed in this study must be selected according to the clinical situation. The presence and degree of tooth surface loss (particularly erosion) may affect the choice of the preparation technique. In such instances, a freehand technique or the use of indexes may be considered more appropriate to prevent over-preparation, which is likely to occur if a depth gauge bur graduated to a depth of 1.5 mm is used routinely. The replacement of an existing crown will also influence the choice of technique. A depth gauge bur will be of limited use in this situation and will only prove effective if the preexisting crown is replaced with one of a provisional or temporary material. An index would provide the best means of comparing and assessing depth of removal between the preexisting and replacement crown.

Possible limitations

Visual perception is necessary for directly assessing preparation depths when indexes are used. Reliance on visual examination provides a subjective element to the analysis of preparations, which could lead to inaccuracy and variation. Studies evaluating the accuracy of visual perception report a tendency for clinicians to underestimate the size of shoulder widths and caliper test sizes of 1 mm.^[13,17] The nature of a depth gauge bur, however, allows tooth removal in sagittal and transverse planes. Depths of reduction in a sagittal section were the only points of analysis in this study, and further research is necessary to analyze and compare the effects of depth gauge burs and sectioned indexes on transverse and sagittal planes other than in the midline. In this study preparation depth was used to check the accuracy and consistency of tooth preparation but preparation depth is not the sole criteria and clinician should also consider the other factors like resistance and retention form, convergence angle, marginal integrity, structural durability and complete preparation geometry as a whole to achieve the best possible results.

CONCLUSION

Within the limitation of this study, it can be concluded that tooth preparation for metal ceramic crown with

freehand approach is not reliable because of the tendency to underprepare tooth on labial and incisal surface. Therefore, whenever the clinical situation permits, considerable importance should be given to the use of putty index and depth gauge burs.

Acknowledgments

We are very thankful to Dr. Girish Parmar the Dean of Government Dental College and Hospital Ahmedabad for his constant support and motivation in the research work. We are also thankful to Dr. Sunilkumar Research Scientist, National Institute of Occupational Health, Ahmedabad for allowing us to carry out some part of this study in their institute.

Financial support and sponsorship

Nil.

Conflicts of interest

There are no conflicts of interest.

REFERENCES

1. Albers HF. Ceramometal bonded inlays and onlays. *J Esthet Dent* 2000;12:122-30.
2. Rosenstiel SF, Land MF. Contemporary Fixed Prosthodontics. 4th ed. St. Louis, Missouri. Mosby publications; 2006. p. 272.
3. Shillingburg HT, Hobo S, Whitsett LD, Jacobi R, Brackett SE. Fundamentals of Fixed Prosthodontics. 3rd ed. Chicago: Quintessence Publishing Co, Inc.; 1997. p. 119-33.
4. Hobo S, Shillingburg HT Jr. Porcelain fused to metal: Tooth preparation and coping design. *J Prosthet Dent* 1973;30:28-36.
5. Miller LL. Framework design in ceramo-metal restorations. *Dent Clin North Am* 1977;21:699-716.
6. Chandler NP. The radiographic assessment of pulp size: Validity and clinical implications. *N Z Dent J* 1989;85:23-6.
7. Brunton PA, Wilson NH. Preparations for porcelain laminate veneers in general dental practice. *Br Dent J* 1998;184:553-6.
8. Reeves WG. Restorative margin placement and periodontal health. *J Prosthet Dent* 1991;66:733-6.
9. Walton JN, Gardner FM, Agar JR. A survey of crown and fixed partial denture failures: Length of service and reasons for replacement. *J Prosthet Dent* 1986;56:416-21.
10. Schwartz NL, Whitsett LD, Berry TG, Stewart JL. Unserviceable crowns and fixed partial dentures: Life-span and causes for loss of serviceability. *J Am Dent Assoc* 1970;81:1395-401.
11. Bell AM, Kurzeja R, Gamberg MG. Ceramometal crowns and bridges. Focus on failures. *Dent Clin North Am* 1985;29:763-78.
12. Sorensen JA. A rationale for comparison of plaque-retaining properties of crown systems. *J Prosthet Dent* 1989;62:264-9.
13. Seymour K, Zou L, Samarawickrama DY, Lynch E. Assessment of shoulder dimensions and angles of porcelain bonded to metal crown preparations. *J Prosthet Dent* 1996;75:406-11.
14. Zarone F, Russo S, Sorrentino R. From porcelain-fused-to-metal to zirconia: Clinical and experimental considerations. *Dent Mater* 2011;27:83-96.
15. Aminian A, Brunton PA. A comparison of the depths produced using three different tooth preparation techniques. *J Prosthet Dent* 2003;89:19-22.
16. Parkinson CF. Excessive crown contours facilitate endemic plaque niches. *J Prosthet Dent* 1976;35:424-9.
17. Brunton PA, Aminian A, Wilson NH. Tooth preparation techniques for porcelain laminate veneers. *Br Dent J* 2000;189:260-2.