

Traumatic Partial Posterior Cord Brachial Plexus Injury in a Patient with Aberrant Innervation of the Long Head of the Triceps by the Axillary Nerve: Implications in Nerve Transfer Surgery

Abstract

Brachial plexus repair forms an unmet need in terms of posttraumatic rehabilitation, especially the young population, wherein the incidence of accidents is high. This leads to decrease in the number of functionally active years after the accident. We encountered an interesting case of posttraumatic posterior cord injury predominantly affecting the shoulder abduction beyond 15°. An electrodiagnostic study showed a complete lack of conduction within the axillary nerve with reduced conduction velocity in the radial nerve. We took the patient up for the long head of the triceps transfer to the anterior division of the axillary nerve transfer. Intraoperatively, we found that the long head branch was originating from the axillary nerve at the point of division. As it could not be used for neurotization, we transferred the medial head branch of the radial nerve to the axillary nerve. The patient started to show electroclinical improvement after 3 months of the surgery. A few similar cases have been published, as a cadaveric finding. We report this case to highlight the possibility and need for a high clinical suspicion and also to provide a possible treatment option, in such aberrant anatomy.

Keywords: Aberrant innervation, axillary nerve, brachial plexus injury, long head of triceps, Somsak procedure

Suyash Singh,
Kuntal Kanti Das,
Harsh Deora,
Awadhesh Kumar
Jaiswal,
Sanjay Behari

Department of Neurosurgery,
Sanjay Gandhi Postgraduate
Institute of Medical Sciences,
Lucknow, Uttar Pradesh, India

Introduction

Traumatic brachial plexus injury (TBPI) is an economical, functional, and psychological burden to the society. Recent advances in the understanding of molecular biology and widespread use of nerve transfer surgeries have started to show promising results. Posttraumatic isolated axillary nerve injury is very rare. Usually, it is a part of the larger picture of posterior cord injury with an additional injury to the radial nerve. Transfer of the long head of triceps (LHT) branch to the anterior division of the axillary nerve (Somsak procedure) has become a popular procedure in improving shoulder abduction in TBPI involving the upper trunk. The “modified Somsak’s procedure” where the medial head branch, rather than the long head branch is used, is also becoming popular of late. Through this report, we wish to highlight the rarity of isolated posterior cord injury as a part of TBPI as well as the clinical implications

of the aberrant innervation of the long head of triceps.

Case Report

Clinical history

A 21-year-old boy was referred to our center 8 months after a road traffic accident. He presented with the complaint of inability to abduct the left shoulder from the time of the accident. There was a displaced, nonunited fracture of the left clavicle for which no active intervention was suggested at that time. The patient was able to move the elbow, wrist, and fingers normally.

Clinical examination and investigation

At admission, there was atrophy of the left deltoid muscle. He was able to abduct the shoulder to around 20°–30° but not beyond. The power at the elbow and wrist were 4/5. Finger movements and handgrip were intact. Deep tendon reflexes in the left upper limb were diminished. There was 60%–90% sensory loss in the distribution

This is an open access journal, and articles are distributed under the terms of the Creative Commons Attribution-NonCommercial-ShareAlike 4.0 License, which allows others to remix, tweak, and build upon the work non-commercially, as long as appropriate credit is given and the new creations are licensed under the identical terms.

For reprints contact: reprints@medknow.com

How to cite this article: Singh S, Das KK, Deora H, Jaiswal AK, Behari S. Traumatic partial posterior cord brachial plexus injury in a patient with aberrant innervation of the long head of the triceps by the axillary nerve: Implications in nerve transfer surgery. *Asian J Neurosurg* 2020;15:391-3.

Submitted: 01-Jun-2019 Accepted: 21-Jan-2020
Published: 29-May-2020

Address for correspondence:
Dr. Kuntal Kanti Das,
Department of Neurosurgery,
Sanjay Gandhi Postgraduate
Institute of Medical Sciences,
Lucknow, Uttar Pradesh, India.
E-mail: drkuntalkantidas@gmail.com

Access this article online

Website: www.asianjns.org

DOI: 10.4103/ajns.AJNS_160_19

Quick Response Code:



of left C5 dermatome. Otherwise, the neurological examination was normal.

Magnetic resonance imaging of the brachial plexus did not show any evidence of pseudomeningocele. The nerve conduction velocity (NCV) showed low amplitude in the left musculocutaneous and left radial nerve, whereas the amplitude over axillary and suprascapular nerves were nonrecordable.

Surgical treatment

The aim was to augment the shoulder abduction beyond the initial 30°. Elbow and wrist functions were already satisfactory (4/5) and were not considered for surgical reinforcement. As the elbow extension was adequate, we planned a LHT branch of the radial nerve to the anterior division of the axillary nerve.

During the surgery, an aberrant innervation of the long head of the triceps muscle from the axillary nerve was noted [Figure 1]. At the same time, we could not find the long head branch in the triangular interval, confirming the abnormal innervation of the LHT in our patient. Therefore, we decided to utilize the medial head branch (both the fascicles) for neurotization and completed the anastomosis with a combination of 9-0 sutures and fibrin glue.

Postoperatively, the patient was kept on an arm sling for 3 weeks after which passive exercises were started along with transcutaneous electrical nerve stimulation. After around 3 months of the surgery, the patient started to show improvement in his shoulder abduction clinically. A similar

pattern was also evident in the NCV. At 8 months follow-up, the patient had excellent improvement in the deltoid function and a shoulder abduction to almost 90 degree.

Discussion

Posttraumatic brachial plexus is a devastating injury. Brachial plexus injury a part of multi-trauma in 54% of cases and 46% have isolated brachial plexus injury after trauma.^[1] These injuries may involve any part of the plexus but tend to be more common at the level of the roots and trunks.^[2] Cords of the brachial plexus lie beneath the clavicle and predominant retroclavicular injuries lead to the involvement of the cord. Our patient presented with features suggesting a posterior cord injury since trauma, but the axillary nerve did not show any improvement unlike the other components of the posterior cord. This type of isolated cord involvement as a part of the brachial plexus injury is very rare.

Could clavicle fracture have led to an isolated posterior cord injury? There are previous reports suggesting clavicle fracture, particularly in the mid-shaft area, leading to brachial plexus injury. All those cases had delayed manifestations of brachial plexus stretching due to the malunion, callus formation, etc. Although we could not demonstrate the clavicle fracture as the cause of posterior cord injury due to the lack of surgical exploration, we strongly believe the fracture ends might have caused the posterior cord injury. As the axillary division did not improve at all, we believe the impingement was predominantly on the fibers destined to go into the axillary nerve, not the radial nerve.

LHT is an expendable muscle. It is due to the presence of the other two heads of the triceps muscle, which are far stronger elbow extensors. Therefore, the LHT branch of the radial nerve, which arises in the axilla, is often utilized to gain shoulder abduction in the upper trunk TBPI with a preserved C7 root.

Advantages of using the nerve to the long head of the triceps are

- Sufficient in length and grafting are not needed
- Sufficient fascicular caliber and motor fibers (45% of the fascicular volume of the anterior axillary nerve)
- The functional loss to the triceps is negligible
- The function is synergistic to shoulder abduction and external rotation, thereby facilitating postoperative reeducation of the deltoid and teres minor muscle.^[3,4]

Lurje *et al.* is a pioneer in the field of neurotization, and triceps branches to the reinnervate axillary nerve.^[5] In 2003, Leechavengvongs *et al.* could be described that nerve to LHT can be used for the neutralization of the axillary nerve.^[6] A few authors advocated using two branches of the radial nerve to match the caliber diameter of the axillary nerve.^[6]

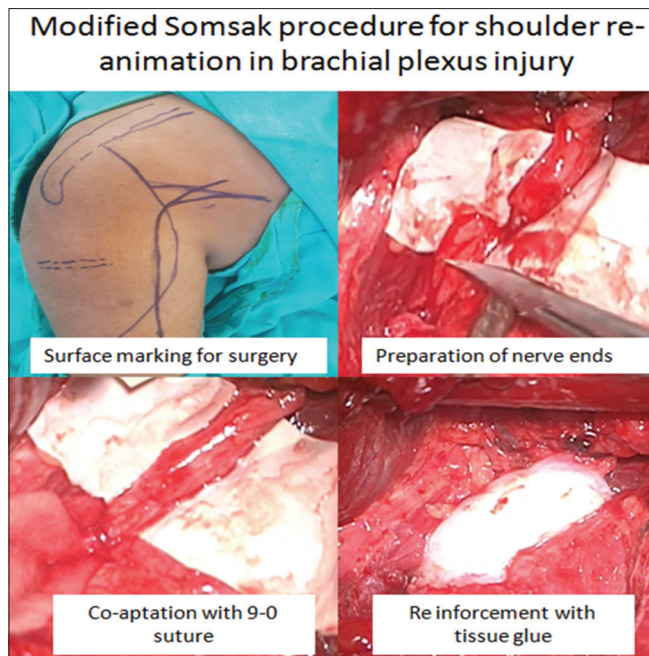


Figure 1: Intraoperative photos for modified Somsak procedure for shoulder reanimation in brachial plexus injury showing surface marking for surgery, preparation of nerve endings, co-aptation with 9-0 suture, and reinforcement with tissue glue

In our patient, we saw that the LHT branch arose from the axillary nerve. Hence, how common is this anatomical variation? There are cadaveric studies reporting the innervation of LHT through the axillary nerve.^[7,8,9] In a cadaveric study by Erhardt and Futterman, 3/22 specimens of the brachial plexus had the same anatomical variant as ours.^[10] Similarly, Aszmann *et al.* found a small branch of the axillary nerve supplying the tendinous portion of the triceps in 7/25 cadaver specimens.^[11] The cadaveric studies quoted variable incidence of the anatomical variant, depending on geographical distribution. Some series reported ulnar nerve innervating the triceps muscles.^[12,13] One must be aware of these variations in the nerve innervations to LHT. The LHT muscle is an embryological derivative of “dorsal muscle mass.” The branches of posterior cord, including axillary nerve, supply the derivatives of dorsal muscle mass. Hence, it is possible that during the time of formation of LHT from its mother “dorsal muscle mass,” the muscle retained the axillary nerve supply along with. To the best of our knowledge, ours is the first report of the anatomical variation being encountered during the surgical procedure in an actual patient.

Like we did, utilization of the medial head branch to the triceps (MHT) for axillary nerve neurotization is a well-described technique. Some people describe it as the modified Somsak technique. The MHT has two fascicles, and utilizing both the fascicles, one can obtain a perfect size match with the anterior division of the axillary nerve.^[3,14]

Finally, could we have just carried out a simple retroclavicular plexus exploration, the release of the nerve compression, and open reduction with fixation of the fractured clavicle? Retrospectively, it appears as a reasonably good option. However, our considerations were: a time lag of 6 months from injury, good function in the triceps and isolated axillary nerve dysfunction for which a good surgical procedure exists. Therefore, we chose to go ahead with nerve transfer surgery rather than a nerve reexploration.

Conclusion

Post-traumatic isolated posterior cord injury is rare but an associated clavicle fracture in the mid part might be responsible for the same. Nerve transfer from the LHT/MHT may be attempted if there is some delay since the injury. During such surgery, clear knowledge regarding the possible variations in the LHT innervation is necessary. The result of nerve transfer is good. Whether plexal exploration and neurolysis should be offered first in these cases remains a matter of debate, but patients presenting late are perhaps better treated using a nerve transfer surgery.

Declaration of patient consent

The authors certify that they have obtained all appropriate patient consent forms. In the form the patient(s) has/have

given his/her/their consent for his/her/their images and other clinical information to be reported in the journal. The patients understand that their names and initials will not be published and due efforts will be made to conceal their identity, but anonymity cannot be guaranteed.

Financial support and sponsorship

Nil.

Conflicts of interest

There are no conflicts of interest.

References

1. Sinha S, Khani M, Mansoori N, Midha R. Adult brachial plexus injuries: Surgical strategies and approaches. *Neurol India* 2016;64:289-96.
2. Mehta VS, Sinha S. Evolution of brachial plexus surgery at AIIMS – The last 4 decades. *Neurol India* 2019;67:4-6. Available from: <http://www.neurologyindia.com/text.asp?2019/67/7/4/250728>. [Last accessed on 2019 Jul 25].
3. McRae MC, Borschel GH. Transfer of triceps motor branches of the radial nerve to the axillary nerve with or without other nerve transfers provides antigravity shoulder abduction in pediatric brachial plexus injury. *Hand (N Y)* 2012;7:186-90.
4. Jácome DT, Alencar FH, Lemos MV, Kobig RN, Rocha JF. Axillary nerve neurotization by a triceps motor branch: Comparison between axillary and posterior arm approaches. *Rev Bras Ortop* 2018;53:15-21.
5. Lurje A. Concerning surgical treatment of traumatic injury of the upper division of the brachial plexus (Erb's-type). *Ann Surg* 1948;127:317-26.
6. Leechavengvongs S, Witoonchart K, Uerpairojkit C, Thuvasethakul P. Nerve transfer to deltoid muscle using the nerve to the long head of the triceps, part II: A report of 7 cases. *J Hand Surg Am* 2003;28:633-8.
7. Tung TH, Mackinnon SE. Nerve transfers: Indications, techniques, and outcomes. *J Hand Surg Am* 2010;35:332-41.
8. Bertelli JA, Kechele PR, Santos MA, Duarte H, Ghizoni MF. Axillary nerve repair by triceps motor branch transfer through an axillary access: Anatomical basis and clinical results. *J Neurosurg* 2007;107:370-7.
9. Nanjundaiah K, Jayadevaiah SM, Chowdapurkar S. Long head of triceps supplied by axillary nerve. *Int J Anat Var* 2012;5:35-7.
10. Erhardt AJ, Futterman B. Variations in the innervation of the long head of the triceps brachii: A cadaveric investigation. *Clin Orthop Relat Res* 2017;475:247-50.
11. Aszmann OC, Dellon AL, Birely BT, McFarland EG. Innervation of the human shoulder joint and its implications for surgery. *Clin Orthop Relat Res* 1996;330:202-7.
12. Pascual-Font A, Vazquez T, Marco F, Sañudo JR, Rodriguez-Niedenführ M. Ulnar nerve innervation of the triceps muscle: Real or apparent? An anatomic study. *Clin Orthop Relat Res* 2013;471:1887-93.
13. Bekler H, Wolfe VM, Rosenwasser MP. A cadaveric study of ulnar nerve innervation of the medial head of triceps brachii. *Clin Orthop Relat Res* 2009;467:235-8.
14. Bertelli JA, Ghizoni MF. Results and current approach for Brachial Plexus reconstruction. *J Brachial Plex Peripher Nerve Inj* 2011;6:2.