

LETTER TO THE EDITOR

AN ANOMALOUS MUSCLE IN THE FOREARM EXTENSOR COMPARTMENT

doi: 10.1590/S1807-59322009000300019

Soubhagya R. Nayak, Rajanigandha Vadgaonkar, Ashwin Krishnamurthy, Latha V. Prabhu

INTRODUCTION

The presence of additional muscles in the forearm extensor compartment is frequently encountered during surgical procedures and anatomical dissections. There are several types of anomalous muscles such as the extensor indicis proprius, the extensor digitorum brevis manus, the extensor medii proprius, and the extensor indicis et medii communis that have been previously reported in the medical literature.¹⁻⁴ In this case study, we have observed an anomalous muscle in the forearm extensor compartment that originated from the proximal one-third of the ulna and was found to be inserted into the tip of the styloid process of the radius. The probable clinical and embryological significance of the present case is discussed herein.

CASE DESCRIPTION

During a routine dissection of the right upper limb of a 60-year-old female cadaver, we observed an anomalous muscle in the extensor compartment of the forearm. The variant was a separate muscle that originated as a tendon from the posterior lateral aspect of the proximal one-third of the ulna, located 12.3 cm distal to the tip of the olecranon process. The tendon ran below the extensor pollicis longus (EPL) and was observed to be inserted between the EPL and the extensor pollicis brevis (EPB) muscles, parallel to EPL and EPB for a total length of 14.9 cm. The fleshy part of this anomalous muscle was 4.5 cm in length and 0.8 cm in width. The proximal tendon and distal tendon of the aforementioned muscle were 7.2 cm and 3.2 cm long, respectively. At the level of the extensor retinaculum, the distal tendon was observed to pass above the second synovial tunnel of the extensor carpi radialis longus (ECRL) and the extensor carpi

radialis brevis (ECRB) muscles and was inserted 1.5 cm proximal to the tip of the styloid process of the radius, distal to the insertion site of the brachioradialis tendon (Figure 1). Interestingly, no such anomalous muscle was present in the left forearm.

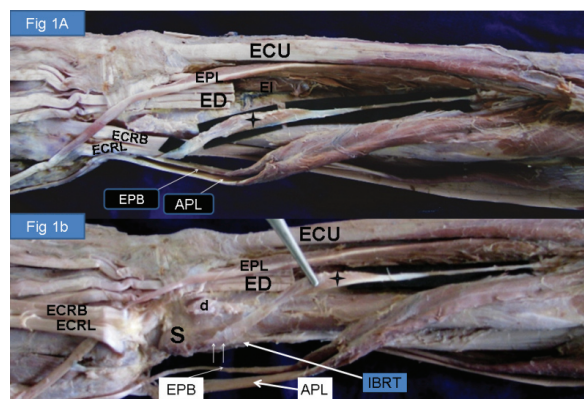


Figure 1 - The extensor compartment of the right forearm and hand, showing the anomalous muscle. A: abductor pollicis longus (APL); extensor carpi radialis brevis (ECRB); extensor carpi radialis longus (ECRL); extensor carpi ulnaris (ECU); extensor digitorum tendons (ED); extensor indicis (EI); extensor pollicis brevis (EPB); extensor pollicis longus (EPL); + indicates the anomalous muscle. B: The extensor carpi radialis brevis and the extensor carpi radialis longus tendons were cut to show the insertion site of the anomalous muscle. APL; dorsal tubercle of Lister (d); extensor carpi radialis brevis tendon reflected (ECRB); extensor carpi radialis longus tendon reflected (ECRL); extensor carpi ulnaris (ECU); extensor digitorum tendons (ED); extensor pollicis brevis (EPB); extensor pollicis longus (EPL); insertion of brachioradialis tendon (IBRT); styloid process of radius (S); + indicates the anomalous muscle. The white arrows indicate the insertion site of the anomalous muscle.

DISCUSSION

Anomalous muscles usually do not result in adverse symptoms but are of academic interest. However, these muscles can create surgical complications when they produce symptoms or are difficult to differentiate from soft-tissue tumors. The peculiarity in the present case was that the anomalous muscle did not cross the wrist joint but rather was confined to the forearm. We propose that this anomalous

muscle should be classified as an accessory muscle of the abductor pollicis longus, which has a similar orientation. Interestingly, this anomalous muscle also has an anomalous insertion site, located proximal to the styloid process of the radius. Although many anomalous muscles from the extensor compartment of the forearm have been reported,⁵ the present variation in the location of the muscle is unique, since it was not located under the additional muscles of the forearm extensor compartment, as previously reported.¹⁻⁵

From an embryological perspective, the extensor muscle mass of the forearm differentiates into three parts. The radial portion differentiates into the brachioradialis, ECRL, and ECRB. This portion then divides into a superficial portion and a deep portion. The superficial portion forms the extensor digitorum communis, the extensor carpi ulnaris, and the extensor digiti minimi. The deep portion, which is innervated by the posterior interosseous nerve (PIN), gives rise to the abductor pollicis longus and the EPB on the radial side and the EPL and the EPI on the ulnar side (Straus, 1941 cited by Tan and Smith, 1999).⁵ Comparative anatomy studies have suggested that the superficial portion exhibits

marked stability within the major divisions of the phylum of the animal species, while the deep portion appears to be highly variable and has undergone considerable evolutionary change, as is observed by the significant variation in its expression in different species of primates (Wood, 1946 cited by Tan and Smith, 1999).⁵ It is therefore not surprising that the greatest variations occur within the deeper portion.⁵ Based on the information provided above, the anomalous muscle reported in this case study may have developed from the deep portion of the forearm extensor muscle mass.

Although the overall volume of the anomalous muscle observed in the present case was not sufficient to facilitate or obstruct any kind of movement in the forearm region, the presence of such a rare anomalous muscle confined only to the forearm extensor compartment may lead to some confusion for surgeons operating in the forearm extensor region, and therefore, we believe that it is of clinical importance to report the observation of this muscle. In addition, the muscular variation reported herein should be of interest to clinicians, surgeons, and anatomists for academic purposes.

REFERENCES

1. Ritter MA, Inglis AE. The extensor indicis proprius syndrome. *J Bone Joint Surg.* 1969;51A:1645-8.
2. Rodríguez-Niedenführ M, Vázquez T, Golanó P, Parkin I, Sañudo JR. Extensor digitorum brevis manus: anatomical, radiological and clinical relevance. A review. *Clin Anat.* 2002;15:286-92.
3. Komiyama M, Nwe TM, Toyota N, Shimada Y. Variations of the extensor indicis muscle and tendon. *J Hand Surg.* 1999;24:575-8.
4. Yalçın B, Kutoglu T, Ozan H, Gürbüz H. The extensor indicis et medii communis. *Clin Anat.* 2006;19:112-4.
5. Tan ST, Smith PJ. Anomalous Extensor Muscles of the Hand: A Review. *J Hand Surg.* 1999;24:449-55.