

Proximal Junctional Kyphosis after Pediatric Angular Kyphotic Deformity Correction: Are we Missing Something?

Abstract

Purpose: Corrective maneuvers in an angular kyphotic deformity have its own problems including early complications such as neurological deficit and late complications such as proximal junctional kyphosis (PJK) and proximal junctional failure (PJF). This article discusses the probable mechanisms, leading to PJK in pediatric severe angular kyphotic deformities and preventive strategies for the same. We will also assess natural course of untreated PJK and its devastating consequences. **Materials and Methods:** Three patients, two 13-year males presented with progressive, painless thoracolumbar kyphoscoliotic deformity, with segmental kyphosis 100° and 140° and scoliosis of 33° and 78°, respectively, and one 14-year-old female presented with angular kyphotic deformity of 60° with apex at D11-12 level. **Results:** Posterior vertebral column resection with segmental deformity correction with good coronal and sagittal balance was done. In the follow-up, PJF was seen. Second surgery was done with the extension of instrumentation to D4 along with deformity correction in both the male patients. The female patient did not opt for a revision surgery, and we are following the natural history of this case. **Conclusion:** In severe thoracolumbar angular kyphotic deformities with normal or negative sagittal balance, it might be a safer option to select the sagittal stable vertebra as upper instrumented vertebra based on the C2 plumb line on the preoperative standing lateral radiographs. However, a study with a larger sample size is needed to validate our hypothesis.

Keywords: *Angular kyphosis, proximal junctional kyphosis, vertebral column resection*

Introduction

Congenital thoracolumbar deformities are caused by anomalous vertebral development. This results in an imbalanced longitudinal growth of vertebral column, which is most typically progressive in nature. Some minor congenital deformities remain undetected; thus, true incidence in population remains unknown. However, current estimates suggest that approximately one in 1000 persons is affected.^[1] The familial incidence in the congenital deformities is estimated between 1% and 5%, suggesting that most cases appear to be sporadic.^[2]

They rapidly increase in magnitude, especially during the period of adolescent growth spurt with a tendency to progress even after skeletal maturity.^[3] Toppling of vertebral column leading to an angular kyphotic deformity though classically described in tubercular spondylodiscitis can be seen in some congenital deformities also.^[4,5] The surgical options for congenital angular kyphosis depend on multiple

factors (skeletal maturity and number of congenitally malformed vertebral segments involved). Fusionless surgery is preferred in early-onset congenital kyphotic deformities involving more than three segments and early fusion surgery preferred for early onset congenital kyphotic deformities with the involvement of <3 segments and for congenital deformities presenting after 10 years of age.^[5]

Proximal junctional kyphosis (PJK) is a known complication after fusion or fusionless surgery for congenital angular kyphosis.^[6-8] Although there is abundant literature regarding PJK in adult spinal deformity (ASD), the literature on PJK following surgeries in congenital angular kyphotic deformities is scanty.^[9-11] We studied three cases of congenital kyphoscoliosis with spinal toppling following PJK and attempted to look into the possible causative factors and discuss preventive strategies for the same. We also analyze the natural history of PJK if left untreated.

Abhinandan Reddy Mallepally, Rajat Mahajan, Nandan Marathe, Ankur Nanda, Tarush Rustagi, Harvinder Singh Chhabra

Indian Spinal Injuries Centre, New Delhi, India

Address for correspondence:

Dr. Abhinandan Reddy Mallepally, Department of Spine Services, Indian Spinal Injuries Centre, Vasant Kunj, Sector C, New Delhi - 110 070, India. E-mail: mabhi28@gmail.com

Access this article online

Website: www.asianjns.org

DOI: 10.4103/ajns.AJNS_311_20

Quick Response Code:



This is an open access journal, and articles are distributed under the terms of the Creative Commons Attribution-NonCommercial-ShareAlike 4.0 License, which allows others to remix, tweak, and build upon the work non-commercially, as long as appropriate credit is given and the new creations are licensed under the identical terms.

For reprints contact: WKHLRPMedknow_reprints@wolterskluwer.com

How to cite this article: Mallepally AR, Mahajan R, Marathe N, Nanda A, Rustagi T, Chhabra HS. Proximal junctional kyphosis after pediatric angular kyphotic deformity correction: Are we missing something? *Asian J Neurosurg* 2021;16:106-12.

Submitted: 22-Jun-2020

Revised: 24-Sep-2020

Accepted: 13-Oct-2020

Published: 23-Feb-2021

Materials and Methods

Case 1

A 13-year-old boy presented with progressive, painless kyphoscoliotic deformity of mid to low back noticed at 5 years of age with no neurological complaints and normal development milestones. Examination revealed a nontender kyphoscoliotic deformity with convexity to the left side. There were no neurocutaneous markers or congenital limb abnormalities. His neurological examination was normal. His imaging, radiographs, and computed tomography (CT) scan showed toppling of D12 over L3 with the presence of a left posterolateral quadrant hemivertebra between L1 and L2 wedge vertebrae [Figure 1]. The segmental kyphosis was 100° and the scoliotic Cobbs angle was 33° with coronal imbalance of 3.6 cm to the right and a negative sagittal balance of 1.64 cm.

At surgery, pedicle screws were inserted from D10 to L5. This was followed by the resection of kyphotic segments including posterolateral quadrant hemivertebra and the L1, L2 wedge vertebrae, through posterior approach. Anterior column reconstruction was done using Harm's cage. The deformity was corrected by gradual shortening of the posterior column over the anterior cage (fulcrum) with sequential rod exchange technique.^[12] The postoperative course was uneventful. Following surgery, the segmental kyphosis reduced to 34° and scoliotic Cobbs to 8° with good coronal/sagittal alignment [Figure 2a and b]. Sixteen months later, the boy presented with a prominence of implants at the upper end of the construct. Imaging showed PJK and fatigue fracture of one of the rods with an increase in proximal junctional angle (PJA) from -20° (lordotic) to $+38^\circ$ (kyphotic) and increase in segmental kyphosis from 34° to 45° [Figure 2b-e]. Second surgery was done with the extension of instrumentation to D4 along with deformity correction utilizing multiple Smith Peterson osteotomies (from D5 to D10) and interbody fusion (at D9–10). We were able to achieve a good correction of the PJK which was maintained till the last follow-up (1 year) [Figure 3].

Case 2

A 13-year-old boy presented with a progressive, painless kyphoscoliotic deformity of the mid back noticed at 1 year of age with no neurological complaints and normal development milestones. Examination revealed a nontender kyphoscoliotic deformity with convexity to the right in the thoracolumbar region, with no neurocutaneous markers or congenital limb abnormalities. His neurological examination was normal. Imaging (radiographs and CT scan) revealed toppling of D12 over L1 (with the distal endplate of D12 lying on the anterior surface of L1) with the presence of a right posterolateral quadrant hemivertebra sandwiched between D12 and L1 [Figure 4]. The segmental thoracolumbar kyphosis was 140° , and the scoliotic Cobbs

angle was 78° with a coronal imbalance of 2 cm to the left and maintained sagittal balance.

At surgery, pedicle screws were passed from D10 to L4 level. This was followed by hemivertebra excision, anterior column reconstruction using Harm's cage with gradual deformity correction using a sequential rod exchange technique.^[12] The initial surgical plan was to instrument from D10 to L3 (three levels above and below the apex keeping in mind that the patient was Risser Grade 0). However, there was a screw pullout at L2, and hence the fixation was extended to L4. Postoperative imaging revealed the reduction of segmental kyphosis to 62° and scoliotic Cobbs to 32° with a preserved coronal and sagittal balance. The postoperative course was uneventful. Six months after the surgery, the patient was clinically asymptomatic, but the imaging showed an increased proximal junctional angle (PJA) from -18° (preoperative) to $+12^\circ$ (6 months postoperative) with no fracture or implant loosening at the upper instrumented vertebra (UIV) [Figure 5]. The construct was extended proximally to D4 level, and the correction was achieved through applying kyphosis contoured cobalt chrome rods on reduction screws with soft-tissue release and multiple Smith Peterson's osteotomies. At his last follow up (2 years), the patient was asymptomatic with good spinal alignment [Figure 6].

Case 3

A 14-year-old girl presented with gradually progressive deformity over the mid-back over a period of 2 years with progressive weakness of bilateral lower limbs. Her other developmental markers were normal. The patient was American Spinal Injury Association (ASIA) B neurology at the time of admission. Examination revealed nontender kyphotic deformity in the thoracolumbar region, with no neurocutaneous markers and congenital limb abnormalities. X-ray revealed an angular kyphotic deformity with apex at D11 vertebra [Figure 7].

The segmental kyphosis was 60° and the scoliotic Cobbs angle was 9° and a negative sagittal balance. Operative intervention was planned in view of the neurological deficit. Vertebral column resection (VCR) at D10 level and pedicle screw fixation from D7 to D12 was done [Figure 8]. Postsurgery course was uneventful, and the patient's neurology improved to ASIA D and was ambulating independently. One year after index surgery, the patient presented with PJK. She opted-out of a surgical intervention and at the present follow-up of 6 years is wheelchair bound with ASIA C neurology. Radiographs at the latest follow-up show a progressive increase in angular kyphosis [Figure 9]. The segmental kyphosis has increased to 81° ; the mesh cage has backed out with a broken rod on the right side.

Discussion

The aim of surgery for severe angular deformity in the pediatric population is fourfold: Achieving a straight spine

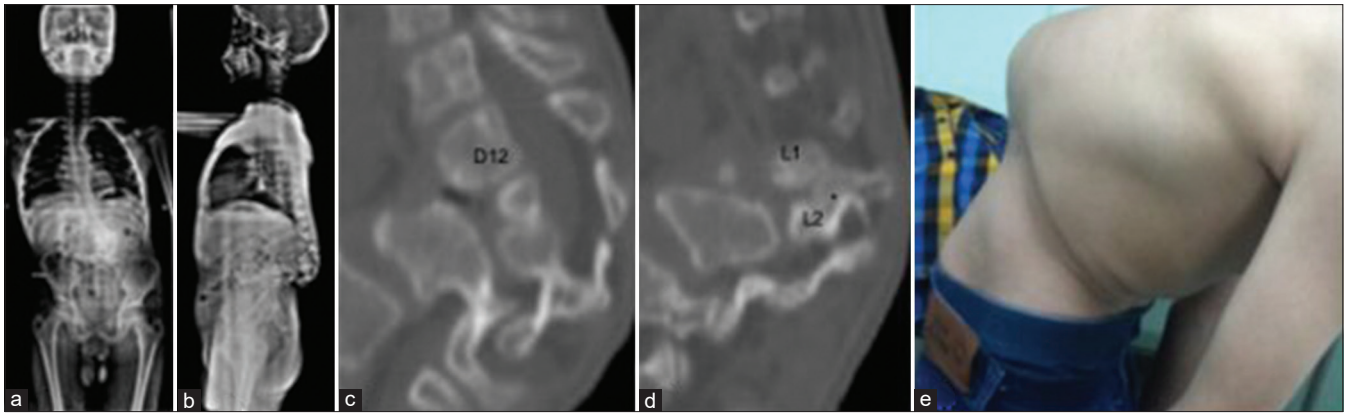


Figure 1: (a) Preoperative anteroposterior, (b) lateral standing radiographs, (c) computed tomography sagittal with toppling of D12 over L3, and (d) posterior mass constituted by posterolateral quadrant hemivertebra (*) sandwiched between L1 and L2 vertebrae and preoperative clinical image

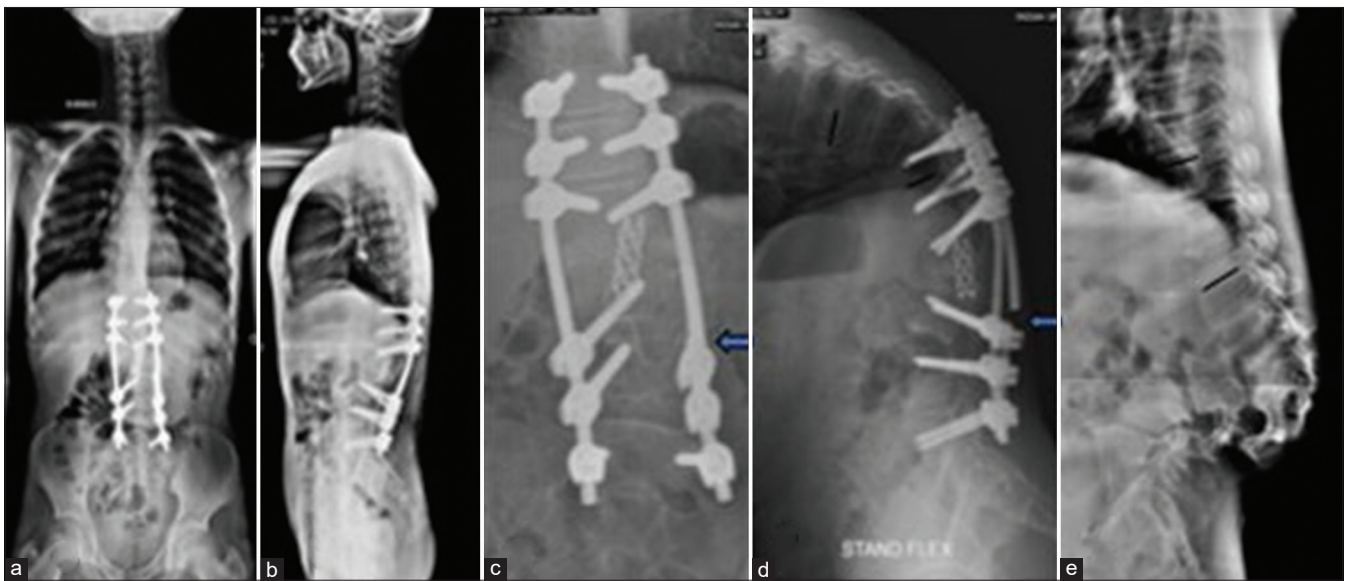


Figure 2: (a) First surgery immediate postoperative anteroposterior, (b) lateral standing radiographs, (c) 16-month postoperative anteroposterior view (broken rod indicated by block arrow), (d) 16-month postoperative lateral view with broken rod showing the proximal junctional angle of +38° when compared to (e) preoperative lateral with the proximal junctional angle of -20°

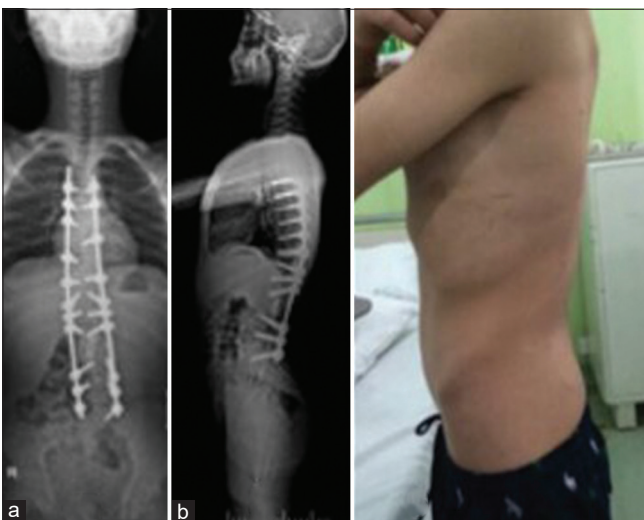

Figure 3: (a) Second surgery postoperative anteroposterior and (b) lateral views and postoperative clinical image

with the head being balanced over the pelvis; restoring a physiologic sagittal profile while maintaining range of motion; limiting curve progression; and preserve spinal growth as far as possible. However, a pressing problem accompanying the fusion procedures for these deformities in a growing spine is that of adjacent segment disease including PJK and proximal junctional failure (PJF).

PJK is a common finding on radiographs in the postoperative period following a spinal fusion. The mechanism of failure includes adjacent disc degeneration, adjacent vertebral subluxation, fracture at the UIV, fracture above the UIV, and failure of fixation at pedicle screw-bone interface.^[13] Although various methods exist for calculating PJK, Glatte's criteria of an increase in PJA measured between inferior endplate of UIV and superior endplate of UIV 2, by 10° is commonly accepted.^[14] PJF includes symptomatic PJK

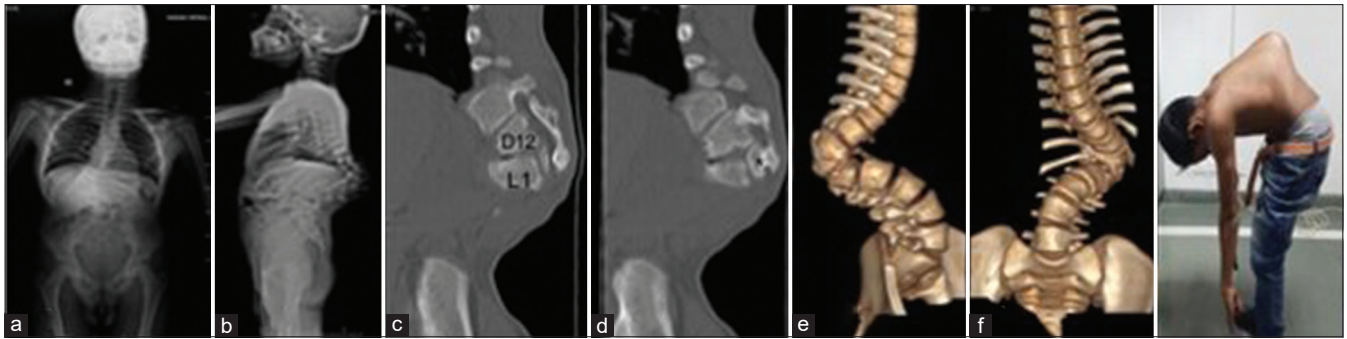


Figure 4: (a) Preoperative AP, (b) lateral standing radiographs, (c) sagittal computed tomography with toppling of D12 over L1 with, (d) posterolateral quadrant hemivertebra (*) sandwiched between D12 and L1 vertebrae, and (e and f) 3d reconstructed images and preoperative clinical image

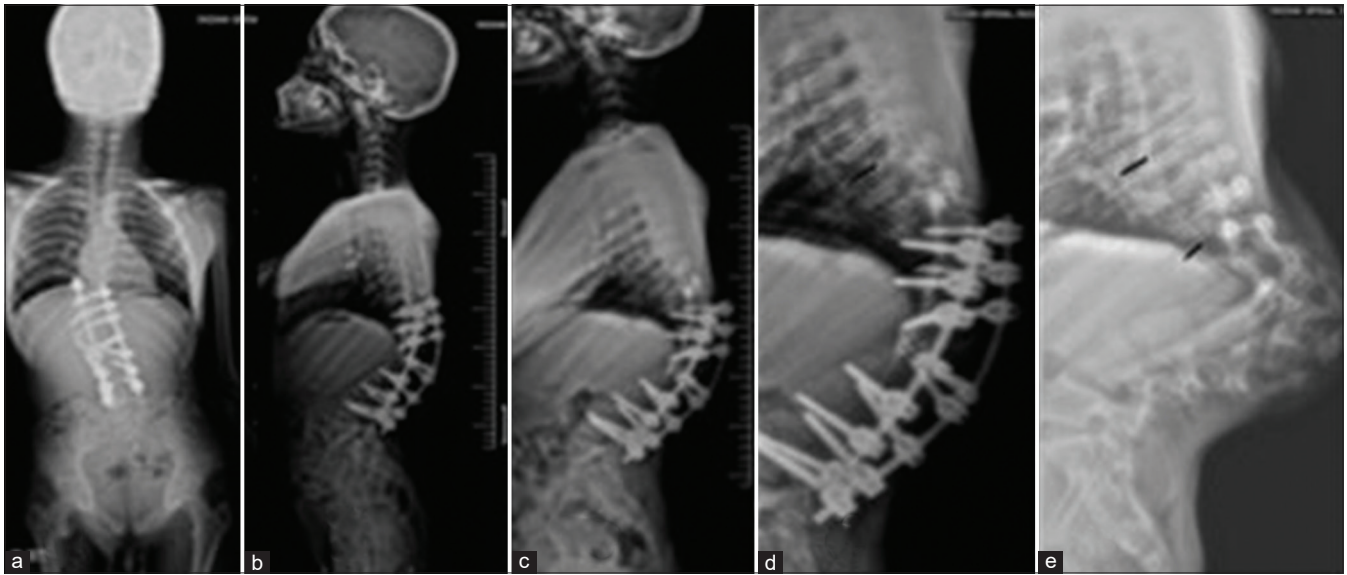


Figure 5: (a) First surgery immediate postoperative anteroposterior, (b) lateral standing radiographs, (c) 6-month postoperative lateral view showing, (d) proximal junctional angle of +12° when compared to (e) preoperative lateral view with proximal junctional angle of -18°

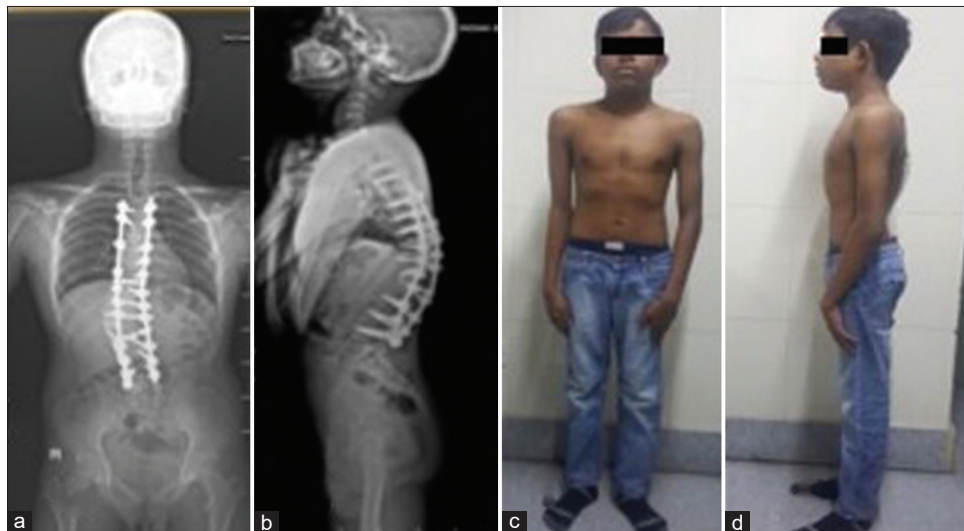


Figure 6: (a) Second surgery 6-month postoperative anteroposterior and (b) lateral views with well-maintained sagittal and coronal balance and (c and d) Clinical image

with a fracture of UIV or implant failure or posterior instability or spinal stenosis.^[14] PJK following ASD surgery is well described in literature. PJK following

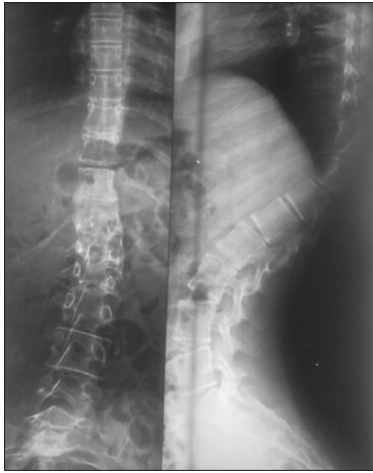

Figure 7: Preoperative anteroposterior and lateral standing X-ray showing thoracolumbar kyphosis with apex at D11 vertebra

pediatric and adolescent deformity correction is focused on adolescent idiopathic scoliosis, Scheuermann's kyphosis, and early onset scoliosis.^[15] However, there are only limited studies discussing PJK in angular kyphotic deformities.^[6,9,10,11,16] However, none of the articles focus on the pediatric age group.

Established risk factors leading to PJK include iatrogenic PLC disruption at UIV, lack of soft endpoint at UIV, pedicle screw malposition at UIV, failure to select the end vertebra as UIV, selecting UIV at apex of dorsal kyphosis, deformity at thoracolumbar junction, greater preoperative segmental pathological kyphosis, thoracic kyphosis, and change in lumbar lordosis after surgery which is $>30^\circ$.^[6,14,15] Except for the lack of soft end point at UIV and the presence of severe deformity at dorsolumbar junction, we could not find any other cause from literature for the occurrence of PJF in our cases. Although etiologies of PJK and PJF are multifactorial, no study has defined a single variable that consistently correlates with them.

Angular kyphotic deformities can be associated with a negative sagittal balance caused by compensatory hyperextension at the adjacent segments, which is also observed in our first case.^[6] In all three cases, we used "sequential rod exchange technique" for kyphosis correction after VCR^[12] and anterior column reconstruction with a mesh cage. On analyzing the cause for PJK, we retrospectively realized that, in our effort to limit the levels of instrumentation due to significant remnant growth potential, the UIV after the first surgery was away from C2 plumb line [Figures 2 and 5]. There is literature suggesting that farther the UIV from the C2 plumb line, higher is the chance of PJK.^[17] The possible reason for this could be that the gravity line, a true representative of axis of weight transmission, stays further anterior to the C2 plumb line, thus increasing the moment arm on the UIV and subjecting the UIV to greater forces because of the body weight.^[18,19] Although the concept

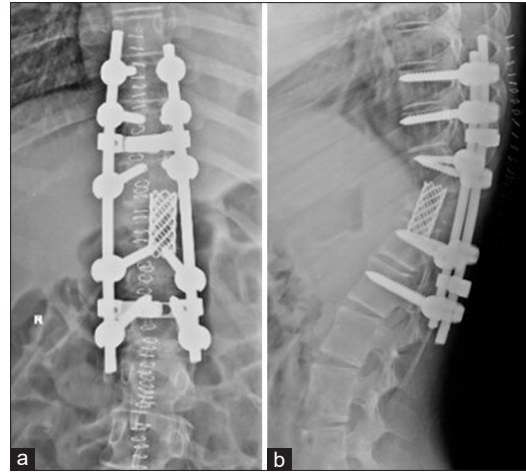


Figure 8: Immediate postoperative anteroposterior (a) and lateral (b) X-ray following vertebral column resection and correction of deformity. Focal kyphotic deformity still persisting at the vertebral column resection level can be appreciated.

of sagittal stable vertebra exists for selecting the lower instrumented vertebra, we hypothesize based on these findings that, in the presence of severe angular kyphotic deformity with spinal toppling, it would be a safer option to plan the UIV based on the C2 plumb line. In our cases, C2 plumb line on the preoperative radiograph was passing through D8, D4, and D5 vertebrae in first, second, and third cases, respectively [Figures 1 and 4]. The initial UIV in case 1 and case 2 was D10 and case 3 was D8, with the UIV being much far away from the sagittal stable vertebra in the second case when compared to that of the first and third case [Figures 2 and 5]. Moreover, it is concluded from biomechanical studies that work energy required for failure of kyphotic rod is lesser than that of a lordotic rod in a corpectomy model.^[20] We feel that the unaddressed PJK because of delayed follow-up in the first and third case could have led to more stress at the VCR zone causing rod breakage at the site of VCR.

Furthermore, we retrospectively realized that, in all cases, angular kyphotic deformity at affected level was not fully corrected. There was a remnant angular kyphosis of 45° , 62° , and 35° after the index surgery in the three cases, respectively, in the immediate postoperative period. The final rod was applied in fully contoured position as per normal thoracolumbar kyphosis. This creates a pseudocorrection of the deformity as it pulls the proximal segment into negative balance. This also could be a possible reason for PJK/PJF later.

The third case provides an insight into the course and devastating consequences of untreated PJK. The third patient opted out of revision surgery; pros and cons were explained. There was gradual progression of deformity with time along with the failure of the construct. There was breakage of rod on the right side along with back-out of mesh cage. The present focal angular deformity is 81° .

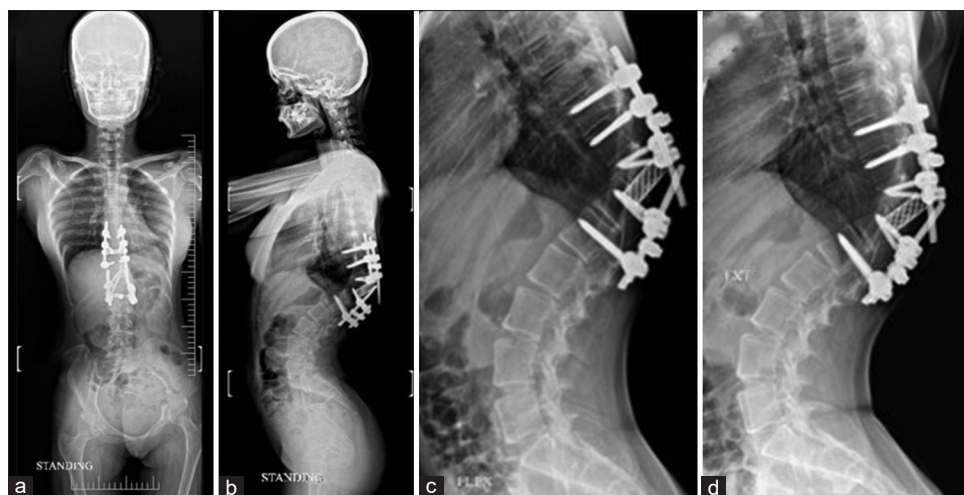

Figure 9: Anteroposterior (a) and lateral (b) whole spine X-rays at final follow-up of 6 years showing angular stable kyphotic deformity (81°) appreciated on flexion (c) and extension (d) radiographs

Neurology worsened, and presently, she is wheelchair bound with ASIA C neurology.

PJK in young children with angular kyphosis remains poorly understood, leading to significant morbidity. Abrupt transition from a rigid segment to mobile region causes greater stress concentration in junctional area. This is compounded by reciprocal regional alignment changes in the noninstrumented thoracic curve. In pediatric patients, PJK often manifests as a kyphotic change in the disc space above the fusion unlike in adult deformities as seen in our patients. In the light of these observations, we hypothesize that the improper selection of UIV could have contributed to PJK in all the cases and had we selected our UIV using the sagittal stable vertebra, PJK/PJF as a complication might have been mitigated. However, a larger sample size is needed to validate our proposed hypothesis.

Surgeons and researchers have devoted a good amount of time and efforts while defining optimal sagittal alignment. However, does sagittal balance only equate with sagittal alignment or there are other variables involved? Dubousset outlined multiple systems that interact with each other and contributing to normal bipedal stance. He stated, “Good alignment is preferable in order to obtain a good balance, but it is not sufficient.”^[21] Preventing PJK requires surgeons to move beyond a unidimensional view that finding an ideal sagittal alignment and softening transition zone proximal to UIV will solve the problem of PJK. The hypothesis suggested in our manuscript might be the missing link for solving the enigma of PJK in pediatric angular kyphosis!

Conclusion

In severe pediatric angular kyphotic deformities with normal or negative sagittal balance, selecting the sagittal stable vertebra as UIV based on the C2 plumb line on the preoperative standing lateral radiographs will give a better functional outcome and prevent PJK.

Declaration of patient consent

The authors certify that they have obtained all appropriate patient consent forms. In the form, the patients have given their consent for their images and other clinical information to be reported in the journal. The patients understand that their names and initials will not be published and due efforts will be made to conceal their identity, but anonymity cannot be guaranteed.

Financial support and sponsorship

Nil.

Conflicts of interest

There are no conflicts of interest.

References

1. Shands AR Jr., Bundens WD. Congenital deformities of the spine; an analysis of the roentgenograms of 700 children. *Bull Hosp Joint Dis* 1956;17:110-33.
2. Winter RB. Congenital scoliosis. *Orthop Clin North Am* 1998 19:395-408.
3. Marks DS, Qaimkhani SA. The natural history of congenital scoliosis and kyphosis. *Spine (Phila Pa 1976)* 2009;34:1751-5.
4. Rajasekaran S. Kyphotic deformity in spinal tuberculosis and its management. *Int Orthop* 2012;36:359-65.
5. Tikoo A, Kothari MK, Shah K, Nene A. Current concepts - Congenital scoliosis. *Open Orthop J* 2017;11:337-45.
6. Wang Y, Kawakami N, Tsuji T, Ohara T, Suzuki Y, Saito T, et al. Proximal junctional kyphosis following posterior hemivertebra resection and short fusion in children younger than 10 years. *Clin Spine Surg* 2017;30:E370-6.
7. Chang DG, Kim JH, Ha KY, Lee JS, Jang JS, Suk SI. Posterior hemivertebra resection and short segment fusion with pedicle screw fixation for congenital scoliosis in children younger than 10 years: Greater than 7-year follow-up. *Spine (Phila Pa 1976)* 2015;40:E484-91.
8. Bess S, Akbarnia BA, Thompson GH, Sponseller PD, Shah SA, El Sebaie H, et al. Complications of growing-rod treatment for early-onset scoliosis: Analysis of one hundred and forty patients. *J Bone Joint Surg Am* 2010;92:2533-43.

9. Atıcı Y, Sökücü S, Uzümcügil O, Albayrak A, Erdoğan S, Kaygusuz MA. The results of closing wedge osteotomy with posterior instrumented fusion for the surgical treatment of congenital kyphosis. *Eur Spine J* 2013;22:1368-74.
10. Javidan P, Kabirian N, Mundis GM Jr, Akbarnia BA. Delayed postoperative neurological complication in a patient with congenital kyphoscoliosis: Recovered by revision of the 4-rod instrumentation technique: Case report. *J Neurosurg Spine* 2013;19:595-9.
11. Wang S, Aikenmu K, Zhang J, Qiu G, Guo J, Zhang Y, *et al.* The aim of this retrospective study is to evaluate the efficacy and safety of posterior-only vertebral column resection (PVCR) for the treatment of angular and isolated congenital kyphosis. *Eur Spine J* 2017;26:1817-25.
12. Wang Y. History of spine osteotomy. In: *Spinal Osteotomy*. Dordrecht: Springer Netherlands; 2015. p. 1-0.
13. Maruo K, Ha Y, Inoue S, Samuel S, Okada E, Hu SS, *et al.* Predictive factors for proximal junctional kyphosis in long fusions to the sacrum in adult spinal deformity. *Spine (Phila Pa 1976)* 2013;38:E1469-76.
14. Lau D, Clark AJ, Scheer JK, Daubs MD, Coe JD, Paonessa KJ, *et al.* Proximal junctional kyphosis and failure after spinal deformity surgery: A systematic review of the literature as a background to classification development. *Spine (Phila Pa 1976)* 2014;39:2093-102.
15. Yan C, Li Y, Yu Z. Prevalence and consequences of the proximal junctional kyphosis after spinal deformity surgery. *Medicine (United States)* 2016;95:1-6.
16. Chen X, Chen ZH, Qiu Y, Zhu ZZ, Li S, Xu L, *et al.* Proximal junctional kyphosis after posterior spinal instrumentation and fusion in young children with congenital scoliosis: A preliminary report on its incidence and risk factors. *Spine (Phila Pa 1976)* 2017;42:E1197-203.
17. Kim DK, Kim JY, Kim DY, Rhim SC, Yoon SH. Risk factors of proximal junctional kyphosis after multilevel fusion surgery: More than 2 years follow-up data. *J Korean Neurosurg Soc* 2017;60:174-80.
18. Roussouly P, Gollogly S, Noseda O, Berthonnaud E, Dimnet J. The vertical projection of the sum of the ground reactive forces of a standing patient is not the same as the C7 plumb line: A radiographic study of the sagittal alignment of 153 asymptomatic volunteers. *Spine (Phila Pa 1976)* 2006;31:E320-5.
19. El Fegoun AB, Schwab F, Gamez L, Champain N, Skalli W, Farcy JP. Center of gravity and radiographic posture analysis: A preliminary review of adult volunteers and adult patients affected by scoliosis. *Spine (Phila Pa 1976)* 2005;30:1535-40.
20. Acar N, Karakasli A, Karaarslan AA, Ozcanhan MH, Ertem F, Erduran M. The mechanical effect of rod contouring on rod-screw system strength in spine fixation. *J Korean Neurosurg Soc* 2016;59:425-9.
21. Dubousset J, Challier V, Farcy JP, Schwab FJ, Lafage V. Spinal alignment versus spinal balance. In: Haid RW, Schwab FJ, Shaffrey CI, Youssef JA, editors. *Global Spinal Alignment: Principles, Pathologies, and Procedures*. St. Louis: Quality Medical Publishing; 2015. p. 3-9.