

Congenital hyperinsulinism caused by a *de novo* mutation in the ABCC8 gene – a case report

Zsuzsanna Molnár¹, Lídia Balogh², János Kappelmayer¹, László Madar¹,
Éva Gombos¹, István Balogh¹

¹ Department of Laboratory Medicine, University of Debrecen, Debrecen, Hungary

² First Department of Pediatrics, Semmelweis University, Budapest, Hungary

ARTICLE INFO

Corresponding author:

István Balogh, Ph.D.
Division of Clinical Genetics
Department of Laboratory Medicine
Faculty of Medicine
University of Debrecen
Hungary
Phone: +36 52-340-006
Fax: +36 52-417-631
E-mail: balogh@med.unideb.hu

Key words:

congenital hyperinsulinism, hypoglycaemia
with hyperinsulinism, ABCC8 genetic testing

Author contributions:

ZsM- molecular diagnosis of hyperinsulinism,
preparing manuscript;
LB- clinical diagnosis, collecting data,
revising the manuscript;
LM, ÉB- molecular diagnosis;
JK- revising the manuscript;
IB- molecular diagnosis of hyperinsulinism,
revising the manuscript

Funding: None

Conflicts of interest:

None declared

ABSTRACT

Congenital hyperinsulinism (CHI) is a rare genetic disorder characterized by inappropriate insulin secretion and severe hypoglycaemia. There are two histological subtypes: diffuse and focal form. Diffuse form is most common in autosomal recessive mutations in ABCC8/KCNJ11 gene, while focal CHI is caused a paternally inherited mutation and a somatic maternal allele loss.

Here we report a case of a term male infant presented with severe hyperinsulinaemic hypoglycaemia. Gene panel testing was performed to give rapid genetic diagnosis. We detected the c.4415-13G>A heterozygous mutation in the ABCC8 gene. Targeted genetic testing of the parents proved the *de novo* origin of the mutation. The mutation has been previously described. The infant received octreotide treatment and is prepared for 18-fluoro-dopa PET-CT examination in order to localize the lesion.

Rapid genetic testing might be crucial in the clinical management strategy, with decision algorithms taking into account of the genetic status of the patient.

INTRODUCTION

Congenital hyperinsulinism (CHI) is the most common cause of nonketotic persistent severe hypoglycaemia in neonates, and is caused by an inappropriate insulin secretion from pancreatic β cells. The estimated incidence of CHI is 1 in 50,000 live births (1). A number of different genetic causes has been associated with CHI. K_{ATP} channel subunits (ABCC8, KCNJ11) alterations are considered to be channelopathies, while metabolopathies are enzyme defects, transcription factor defects or metabolic defects (GLUD1, SLC16A1, HNF4A, GCK, HNF1A, HADH, UCP2) (2).

CHI shows considerable genetic heterogeneity, it can be inherited in a recessive or dominant manner (3). Of the several genes implicated, the most common ones are ABCC8 (ATP binding cassette subfamily C member 8) and KCNJ11 (potassium voltage-gated channel subfamily J member 11) being responsible for 40-50% of the cases. ATP sensitive K^+ (K_{ATP}) channels are composed of eight subunits from two different gene products, ABCC8 encoding SUR1 and KCNJ11 encoding Kir6.2 subunit (2). The K_{ATP} channel is a key component in the regulation of insulin secretion in response to elevating glucose level. The channels close as a consequence of glucose metabolism (increased ATP level) leading to membrane depolarization which ultimately results in the opening of a voltage-gated Ca^{2+} channel. The rise of the intracellular Ca^{2+} concentration stimulates exocytosis of insulin-containing granules from the pancreatic β cell (Figure 1). The K_{ATP} channel is a Janus-faced protein as gain-of-function mutations will lead to neonatal or maturity-onset diabetes while loss-of-function mutations will cause CHI (4).

Histologically 2 different types of congenital hyperinsulinism can be distinguished. In diffuse forms all β cells are affected, which is a result of an autosomal recessive CHI. In focal forms a

localized hyperplasia is present in the otherwise normal pancreatic tissue. These focal lesions might be the results of two different events. One possible event is a paternally inherited mutation in the ABCC8 or KCNJ11 gene that would remain silent, but if there is an acquired somatic deletion of the maternal allele, focal CHI will develop because of the loss of heterozygosity. The ABCC8 and KCNJ11 containing chromosome region also contains several imprinted genes, which are responsible for cell replication. The paternally expressed genes are involved in cell replication, proliferation. Normally they are compensated by the maternally expressed gene products, but in case of maternal allele loss, β cell hyperplasia will develop (8).

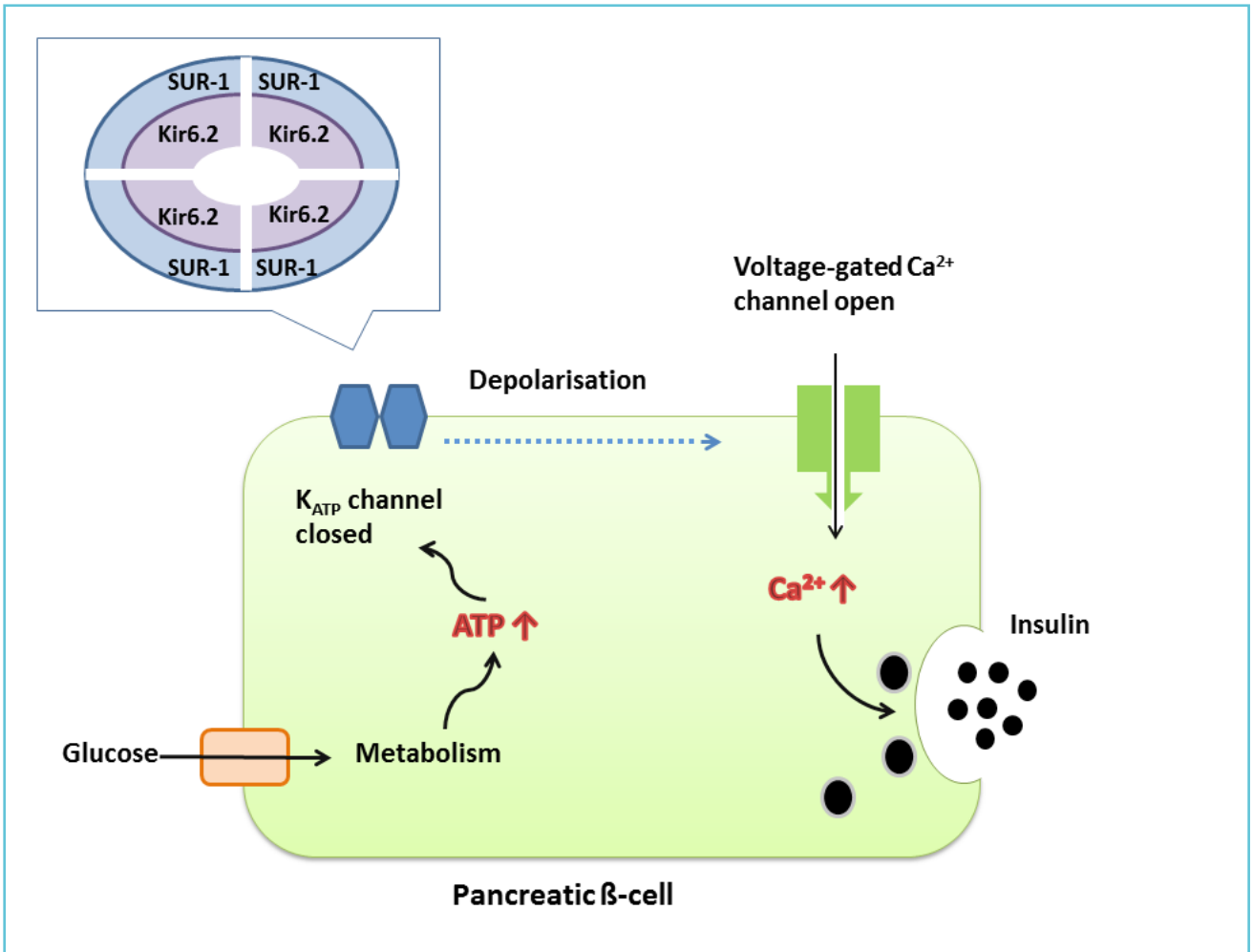
Diffuse CHI is suspected when the detected alterations are homozygous, compound heterozygous or in the case when only maternal heterozygous mutation is found.

Focal CHI is most commonly associated with paternal heterozygosity, but focal CHI has also been reported with mutations arising either *de novo* or of unknown parental origin. Although paternal heterozygosity has a higher probability for focal CHI, additional investigation such as 18-fluoro-dopa PET-CT scanning is necessary to localize the lesion in focal CHI (Figure 2) (9). According to some reports a proportion with paternal heterozygous mutations might have diffuse CHI which could be explained by dominant inheritance or inability to identify a maternal mutation in a recessively-inherited disease (2).

Rapid, high-throughput techniques for analysis of candidate genes have helped the care of patients with CHI. Genotyping guides further investigation of the patient and, because of the strong genotype-phenotype correlation, also the therapy (10,11).

The main goal of CHI treatment is to prevent brain damage. The nutritional approach includes glucose infusion and enteral feeding.

Figure 1 Mechanism of the K_{ATP} channel regulated insulin secretion in pancreatic β -cell. Model of the K_{ATP} channel protein subunits



Medical treatment includes administration of diazoxide, octreotide, nifedipine and glucagon. Diazoxide acts on the SUR1 subunit of the K_{ATP} channel. It keeps the channel open, halting insulin secretion. Octreotide is a somatostatin analogue that inhibits insulin secretion. Glucagon stimulates glycogenolysis and gluconeogenesis. Growing evidence of published cases suggest a novel treatment option, sirolimus therapy (12). When CHI patient fail to respond to medical treatment, surgery should be considered. For patients diagnosed with focal form, surgical resection of the lesion is the appropriate cure. In case of diffuse CHI subtotal pancreatectomy

may be necessary in severe, medically unresponsive cases (1).

CASE REPORT

A term male infant was born after uneventful pregnancy. His birth weight was 4050 g (95-97 percentile), Apgar scores at birth were 9 at 1 min and 10 at 5 min. The infant did not have any dysmorphic features or congenital anomalies. The mother was primipara and had no diabetes during pregnancy. Due to being large for gestational age blood glucose monitoring begun, and hypoglycaemia was detected at one hour of life.

Table 1 Glucose, insulin and C-peptide levels during treatment

	Upon admission	Day 1	Day 2	Reference range
Blood glucose (mmol/L)	1.6	2.1	5.6	3.6-6.0
Insulin (mU/L)	16.65	4.46	N.D.	2.6-24 (in normoglycaemia)
C-peptide (ng/mL)	2.43	0.76	N.D.	0.48-5 (in normoglycaemia)
Therapy	glucose infusion	diazoxide	octreotide	-

N.D.: not determined

Figure 2 Clinical diagnostic algorithm for management of congenital hyperinsulinism integrating molecular genetic testing

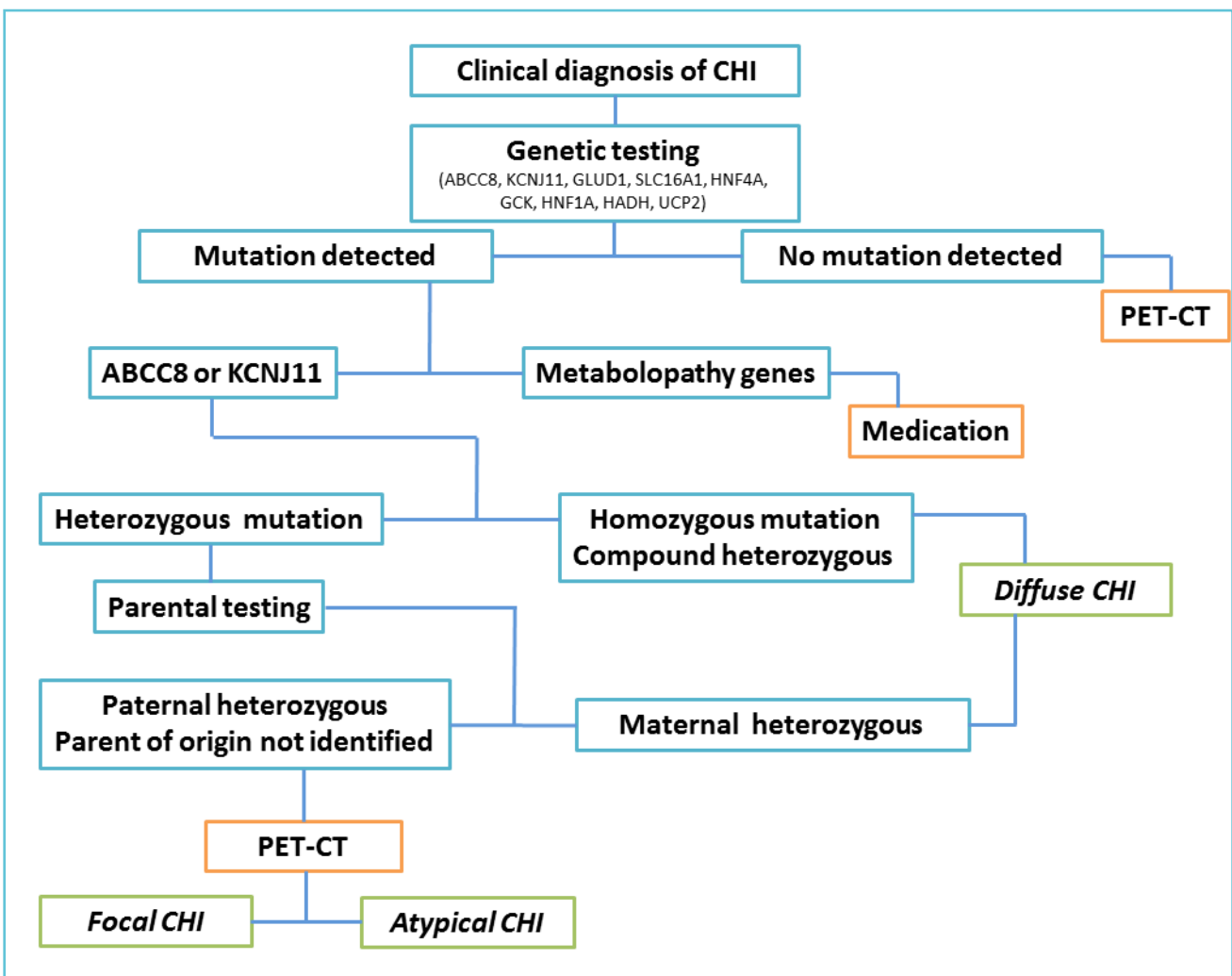
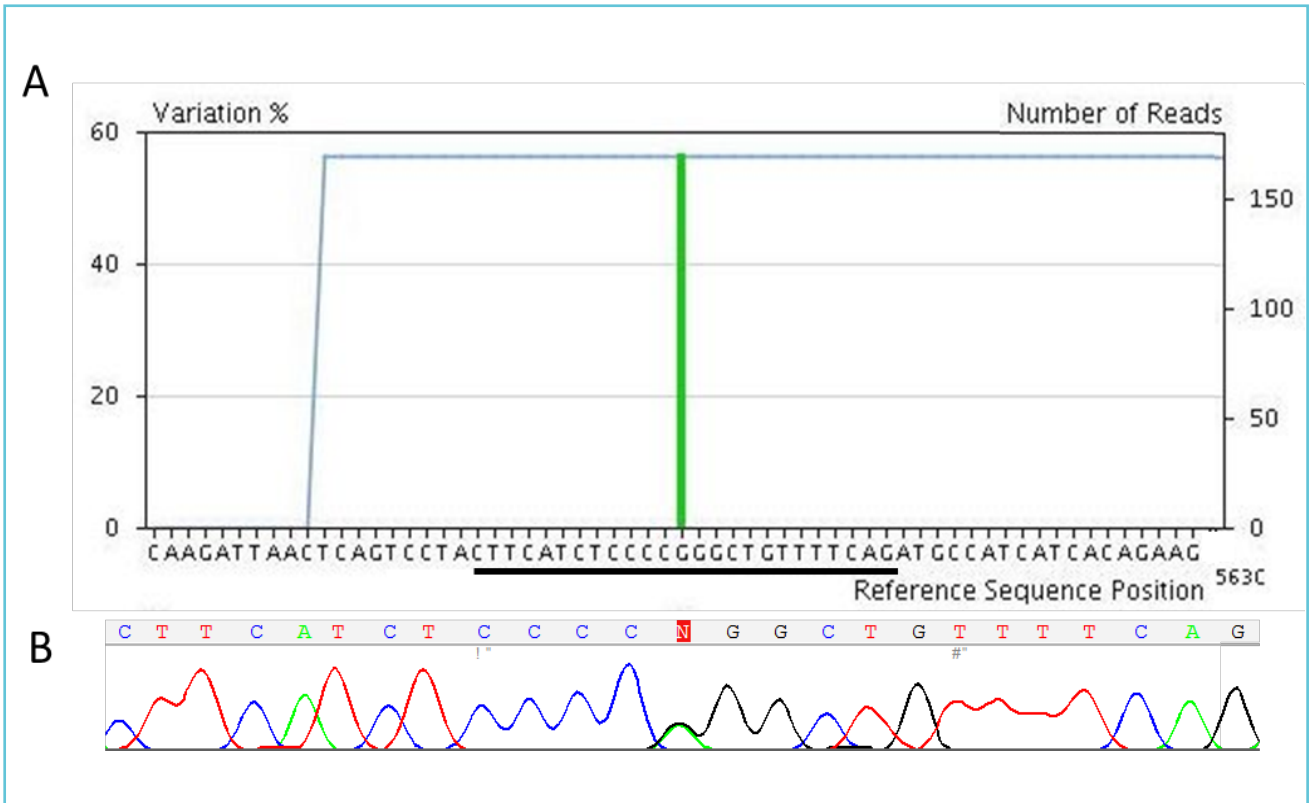


Figure 3 Genetic analysis revealed a heterozygous c.4415-13G>A mutation of the ABCC8 gene



Part A: Next-generation sequencing result
Left Y axis shows the percentage of the mutant allele
Right Y axis and the blue line show the coverage
Region of the ABCC8 gene containing the mutation site is shown

Part B: Sanger sequencing electropherogram

He was treated with i.v. glucose infusion and hydrocortisone. Adrenal insufficiency was excluded (cortisol level: 398 nmol/L, reference range: 140-690 nmol/L). After the sixth day of life the blood glucose normalized, the infant did not require any medication. A diagnosis of transient hypoglycaemia was made. At the age of two months, he was admitted to hospital because of frequent myoclonic movements of the lower and later the upper limbs, sweat and pallor was observed with episodes of hypoglycaemia (glucose: 1.1-1.9 mmol/L). In time of hypoglycaemia (glucose: 1.6 mmol/L) the insulin level was 16.65 mU/L, and C-peptide level was 2.43 ng/mL. Normoglycaemia could only be maintained by

continuous i.v. glucose load up to 20mg/kg/min. Insulin and C-peptide levels were elevated during hypoglycaemia.

Oral diazoxide was administered because of the hyperinsulinism at 13 mg/kg/day in divided doses. He had poor response to diazoxide, the glucose infusion was further administered. With this therapy the blood glucose could be maintained at 2.1-2.3 mmol/l. Insulin was 4.5 mU/L, C-peptide was 0.76 ng/mL (Table 1). Genetic testing was initiated. After starting octreotide therapy his blood glucose began to improve. Subcutaneously introduced octreotide was successfully replaced by lancreotide every four weeks.

Genomic DNA was extracted from peripheral blood leukocytes. Next-generation panel gene sequencing was performed on a Roche GS Junior DNA sequencer using a Multiplicom MODY MASTR Kit which contains the following genes: ABCC8, GCK, HNF1A, HNF4A, HNF1B, INS and KCNJ11. The detected mutation was confirmed by Sanger sequencing.

We detected the c.4415-13G>A heterozygous mutation in the ABCC8 gene (Figure 3). Targeted genetic testing of the parents proved the *de novo* origin of the mutation. The c.4415-13G>A mutation has been previously described, and was associated with octreotide responsive, focal histological forms (4). Although there is no functional study analyzing the consequence of the mutation, the c.4415-13G>A has been shown to be present in many CHI patients (5,6,7).

The infant received octreotide treatment and could be prepared for 18-fluoro-dopa PET-CT examination.

DISCUSSION

Early diagnosis and treatment is crucial for the appropriate management of CHI (1). The primary goal of treatment is to maintain normoglycaemia in order to prevent neurological damage. Rapid gene mutation analysis with short turnaround time is a key part of the clinical management strategy, as it is shown in the decision algorithm (Figure 2). Importantly, the finding of a paternal heterozygous mutation or a *de novo* mutation is a key step before 18-fluoro-dopa PET-CT scanning and the subsequent possible finding of a solitary focal lesion in the pancreas that can be cured by lesionectomy (8,9,10). Genotype-phenotype correlations is also helpful in the management of the patient (3,11). The treatment algorithm recommends the K_{ATP} agonist, diazoxide as first line therapy. Our patient was also octreotide responsive, similarly to the patient in the first literature report (4).

TAKE-HOME MESSAGES/LEARNING POINTS

1. CHI is a cause of severe hypoglycaemia in neonates.
2. The main pathophysiological characteristic of CHI is that insulin secretion is independent from the glucose concentration, showing elevated insulin and C-peptide levels even in the presence of hypoglycaemia.
3. Loss of function mutations in the ABCC8 or in the KCNJ11 gene can lead to CHI.
4. Rapid genetic testing in patients with CHI is crucial and guides further investigations.

REFERENCES

1. Arnoux JB, Verkarre V, Saint-Martin C, Montravers F, Brassier A, Valayannopoulos V, Brunelle F, Fournet JC, Robert JJ, Aigrain Y, et al. Congenital hyperinsulinism: current trends in diagnosis and therapy. *Orphanet J Rare Dis.* 2011;6:63. doi: 10.1186/1750-1172-6-63.
2. Nessa A, Rahman SA, Hussain K. Hyperinsulinemic Hypoglycemia - The Molecular Mechanisms. *Front Endocrinol.* 2016 Mar 31;7:29. doi: 10.3389/fendo.2016.00029.
3. Snider KE, Becker S, Boyajian L, Shyng SL, MacMullen C, Hughes N, Ganapathy K, Bhatti T, Stanley CA, Ganguly A. Genotype and phenotype correlations in 417 children with congenital hyperinsulinism. *J Clin Endocrinol Metab.* 2013;98(2):E355–E363.
4. Henquin JC, Nenquin M, Sempoux C, Guiot Y, Bellanné-Chantelot C, Otonkoski T, de Lonlay P, Nihoul-Fékété C, Rahier J. In vitro insulin secretion by pancreatic tissue from infants with diazoxide-resistant congenital hyperinsulinism deviates from model predictions. *J Clin Invest.* 2011;121(10):3932-42.
5. Aguilar-Bryan L, Bryan J. Molecular biology of adenosine triphosphate-sensitive potassium channels. *Endocr Rev.* 1999;20(2):101-35.
6. Del Roio Liberatore R, Ramos PM, Guerra G, Manna TD, Silva IN, Martinelli CE. Clinical and molecular data from 61 Brazilian cases of Congenital Hyperinsulinemic Hypoglycemia. *Diabetol Metab Syndr.* 2015;18;7:5. doi: 10.1186/1758-5996-7-5.
7. Bellanné-Chantelot C, Saint-Martin C, Ribeiro MJ, Vaury C, Verkarre V, Arnoux JB, Valayannopoulos V, Gobrecht S, Sempoux C, Rahier J, Fournet JC, Jaubert F, Aigrain Y, Nihoul-Fékété C, de Lonlay P. ABCC8 and KCNJ11 molecular spectrum of 109 patients with

diazoxide-unresponsive congenital hyperinsulinism. *J Med Genet.* 2010;47(11):752-9.

8. Saint-Martin C, Arnoux JB, de Lonlay P, Bellanné-Chantelot C. KATP channel mutations in congenital hyperinsulinism. *Semin Pediatr Surg.* 2011;20(1):18-22.

9. Banerjee I, Avatapalle B, Padidela R, Stevens A, Cosgrove K, Clayton P, Dunne M. Integrating genetic and imaging investigations into the clinical management of congenital hyperinsulinism. *Clin Endocrinol (Oxf)* 2013;78(6): 803–813.

10. Stanley CA. Perspective on the Genetics and Diagnosis of Congenital Hyperinsulinism Disorders. *J Clin Endocrinol Metab.* 2016;101(3):815-26.

11. Gonera A, Buraczewska M, Borowiec M, Barg E. Congenital hyperinsulinism: course and consequences - case report. *Pediatr Endocrinol Diabetes Metab.* 2015;21(1): 46-50.

12. Méder Ü, Bokodi G, Balogh L, Körner A, Szabó M, Pruhova S, Szabó AJ. Severe Hyperinsulinemic Hypoglycemia in a Neonate: Response to Sirolimus Therapy. *Pediatrics.* 2015;136(5):e1369-72.