



Received: 2016.04.30
Accepted: 2016.05.17
Published: 2017.01.06

Authors' Contribution:

- A** Study Design
- B** Data Collection
- C** Statistical Analysis
- D** Data Interpretation
- E** Manuscript Preparation
- F** Literature Search
- G** Funds Collection

Initial Fludeoxyglucose (18F) Positron Emission Tomography-Computed Tomography (FDG-PET/CT) Imaging of Breast Cancer – Correlations with the Primary Tumour and Locoregional Metastases

Sevin Ayaz^{1ABCDEF}, Salih Sinan Gültekin^{2ABCDEF}, Ümit Yaşar Ayaz^{3ABCDEF},
Alper Dilli^{4ABCDEF}

¹ Department of Nuclear Medicine, Mersin State Hospital, Mersin, Turkey

² Department of Nuclear Medicine, Hacettepe University, Kastamonu School of Medicine and Dışkapı Yıldırım Beyazıt Training and Research Hospital, Ankara, Turkey

³ Department of Radiology, Mersin Women's and Children's Hospital, Mersin, Turkey

⁴ Department of Radiology, Dışkapı Yıldırım Beyazıt Training and Research Hospital, Ankara, Turkey

Author's address: Sevin Ayaz, Mersin Devlet Hastanesi, Nükleer Tıp Bölümü, 33050 Mersin, Turkey,
e-mail: sevinayaz@yahoo.com

Summary

Background:

We aimed to evaluate initial PET/CT features of primary tumour and locoregional metastatic lymph nodes (LNs) in breast cancer and to look for potential relationships between several parameters from PET/CT.

Material/Methods:

Twenty-three women (mean age; 48.66±12.23 years) with a diagnosis of primary invasive ductal carcinoma were included. They underwent PET/CT imaging for the initial tumour staging and had no evidence of distant metastases. Patients were divided into two groups. The LABC (locally advanced breast cancer) group included 17 patients with ipsilateral axillary lymph node (LN) metastases. The Non-LABC group consisted of six patients without LN metastases. PET/CT parameters including tumour size, axillary LN size, SUV_{max} of ipsilateral axillary LNs (SUV_{max}-LN), SUV_{max} of primary tumour (SUV_{max}-T) and NT ratios (SUV_{max}-LN/SUV_{max}-T) were compared between the groups. Correlations between the above-mentioned PET/CT parameters in the LABC group as well as the correlation between tumour size and SUV_{max}-T within each group were evaluated statistically.

Results:

The mean values of the initial PET/CT parameters in the LABC group were significantly higher than those of the non-LABC group (p<0.05). The correlation between tumour size and SUV_{max}-T value within both LABC and non-LABC groups was statistically significant (p<0.05). In the LABC group, the correlations between the size and SUV_{max}-LN values of metastatic axillary LNs, between tumour size and metastatic axillary LN size, between SUV_{max}-T values and metastatic axillary LN size, between SUV_{max}-T and SUV_{max}-LN values, and between tumour size and SUV_{max}-LN values were all significant (p<0.05).

Conclusions:

We found significant correlations between PET/CT parameters of the primary tumour and those of metastatic axillary LNs. Patients with LN metastases had relatively larger primary tumours and higher SUV_{max} values.

MeSH Keywords:

Axilla • Carcinoma, Ductal, Breast • Lymph Nodes • Positron-Emission Tomography • Tomography, X-Ray Computed

PDF file:

<http://www.polradiol.com/abstract/index/idArt/899358>

Background

Breast cancer (BC) was reported to be the second most common cause of cancer death among women [1]. Invasive BC is a type of cancer that has spread from the ducts or lobules of the breast to the neighbouring tissue [2]. The most common BC type is the invasive type, and about 90% its cases have no special features. This cancer type used to be called ductal carcinoma [3]. Mammography, ultrasonography (US), magnetic resonance imaging (MRI), isotope bone scanning, preoperative lymphoscintigraphy-sentinel lymph node biopsy (SLNB) [4], axillary lymph node (LN) dissection (ALND) have been used as conventional methods in the diagnosis and staging of BC. Moreover, 18-fluorodeoxyglucose (FDG)-positron emission tomography/computed tomography (PET/CT) has also been used as a complementary method [5] and has now become an essential tool for the staging of BC. The prognosis and therapeutic decisions are based primarily on precise data on the real extent of the disease, which is directly related to the metastatic involvement of locoregional lymph nodes (LNs), including ipsilateral axillary, internal mamarian (IM), supraclavicular (SC) and infraclavicular (IC) LNs [6]. Axillary LN status was accepted as the most significant and reliable predictor of survival and disease recurrence in primary BC [5,7,8]. Gold-standard methods for the assessment of axillary nodal status are still ALND or SLNB [8]. These methods are performed according to the axillary LN status which is determined to be negative or positive during initial staging [9], but they are associated with surgical complications [10,11]. FDG-PET was reported to be more accurate in the diagnosis of axillary LN status than physical examination [12] and it can help identify patients with metastatic axillary LN involvement who are directed to ALND without requiring SLNB [8,13]. In addition to being a noninvasive imaging tool, FDG-PET/CT is also an indicator of glucose metabolism in BC [14], and a significant correlation was shown between the level of SUV and clinicopathological parameters in BC [15]. It was reported that BC patients with more advanced tumor grades or growth had higher FDG uptake values [14]. Therefore, in addition to the clinicopathological methods, FDG uptake can provide quantitative information on both the primary tumour and metastatic LNs [16]. In BC patients, FDG-PET was found to be useful and more accurate than the conventional TNM staging in the preoperative evaluation of prognosis [12], but the sensitivity of FDG-PET/CT for axillary LN metastasis was reported to be dependent on axillary tumour burden and the affinity of the BC to FDG [8,17].

In order to provide a minimally invasive breast surgery for cancer patients, proper interpretation of the status of the axillary LNs in PET/CT images is of utmost significance. It seems necessary that the relatively low sensitivity of FDG-PET/CT and its diagnostic value in staging or estimating the prognosis need to be improved, which requires further research. For this reason, we wanted to further evaluate PET/CT characteristics of invasive BC to find better and reproducible correlations between PET/CT parameters of primary tumour and metastatic axillary LNs. Therefore, we preoperatively grouped our patients into the locally advanced breast cancer (LABC) and non-LABC groups according to the presence or absence of locoregional

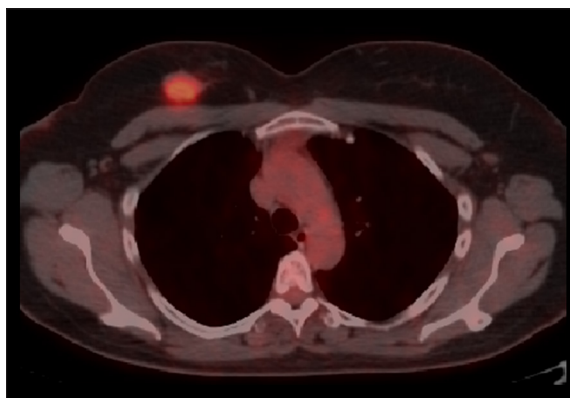


Figure 1. Axial FDG-PET/CT image of a right-sided breast cancer mass in a non-LABC patient without axillary lymph node metastases. Tumoural SUV_{max} was 5.0.

LN metastases, respectively. In our study group, the locoregional LN metastases primarily included axillary LNs and to a lesser extent extra-axillary (IM, SC, IC) LNs. We compared initial PET/CT features of these two groups and statistically evaluated the relationship between PET/CT features of BC mass and metastatic axillary LNs in the LABC group. We also compared PET/CT parameters of the patients in stages I–III. Moreover, we made a comparison between PET/CT features of the cases with and without remote metastases in the LABC group.

Material and Methods

Subjects

Our study was conducted between the years 2014 and 2015 and included the patients who underwent an oncological FDG-PET/CT imaging due to a known BC. The study population included initially 47 women. Twenty-four patients who underwent prior surgery/chemotherapy/radiotherapy and/or who were demonstrated to have distant metastases were excluded from the study. The remaining 23 patients with a diagnosis of primary invasive ductal carcinoma (IDC) who did not have the evidence of distant metastases and who underwent PET/CT imaging for their initial tumour staging on initial admission before surgery, chemotherapy and/or radiotherapy were included in this retrospective study. The mean age was 48.66 ± 12.23 years (range, 31–68 years). The patients were divided into two groups. The non-LABC group (control group) consisted of six LN-negative patients (Figure 1). The LABC group included 17 patients with known axillary LN metastases (Figures 2, 3), without any evidence of distant metastases on initial evaluation [18,19]. All the procedures were performed according to the World Medical Association Declaration of Helsinki (revised in 2000, Edinburgh). All the patients were informed of FDG-PET/CT examination procedures, and informed consent was obtained from them. After a PET/CT imaging, each patient underwent either modified radical mastectomy or breast conserving surgery based on the extent and location of the primary tumour. ALND was also performed in patients with clinically positive axillary LNs. All patients were discharged in good health. Five out of six patients from the non-LABC group and 12 out of 17 patients from the LABC group who

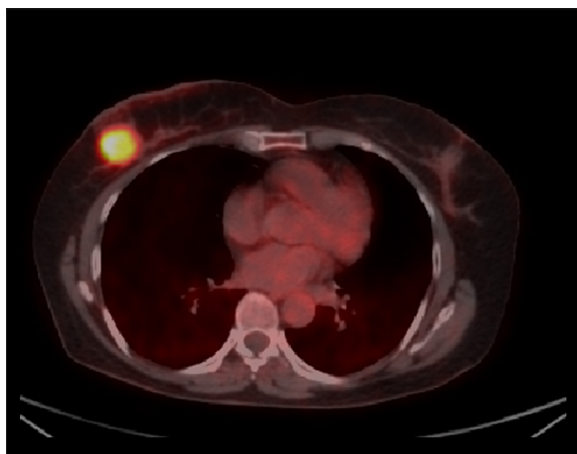


Figure 2. Axial FDG-PET/CT image of a LABC patient with a mass in the right breast. Tumoural SUV_{max} was 10.0.

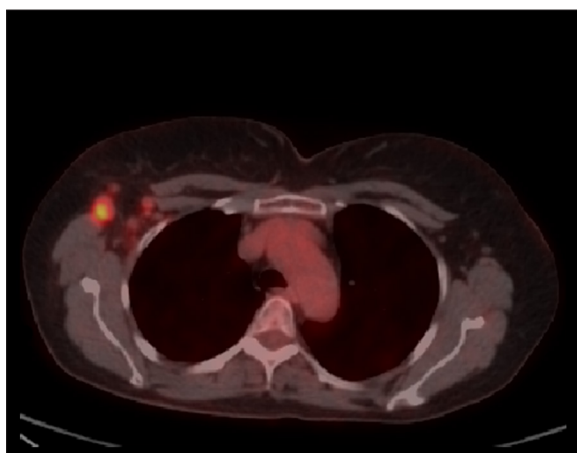


Figure 3. In the same patient, enlarged metastatic ipsilateral axillary lymph nodes with a SUV_{max} value of 8.4 were detected.

underwent chemotherapy and/or radiotherapy could be followed-up by PET/CT. Mean PET/CT follow-up time of the patients for the assessment of short-term prognosis as evidenced by remote metastasis development was 6.76 ± 2.38 months.

PET/CT protocol

Abdominal FDG-PET/CT images were used to evaluate the primary BC site and locoregional LNs. The patients fasted for at least 6 hours before the study, with a plasma glucose level within 150–200 mg/dL obtained at the time of FDG administration (mean plasma glucose level, 100 mg/dL). FDG was injected intravenously at a dose of 266.4–384.8 MBq (7.2–10.4 mCi). Whole-body emission scanning (7–14 bed positions; acquisition time, 3 min/bed position) was performed 50 minutes after FDG administration in supine position. Scanning was performed from the head to the proximal thigh. Hybrid imaging was performed using a Discovery 610 (General Electric Medical Systems, LLC, Waukesha, WI, USA) PET/CT scanner. CT images were obtained during breath-holding using the following parameters: detector row configuration, 16×1.25 mm; tube voltage, 120–140 kVp; maximum tube current, 220 mA; beam collimation, 20.0 mm; table speed, 27.5 mm/rotation; pitch,

1.375:1; helical thickness, 3.75 mm and 512×512 matrix. Attenuation-correction was done. Images were reconstructed in transaxial, coronal and sagittal planes. Prior to PET/CT examination, diluted iodinated nonionic contrast material was given orally for bowel opacification. We did not administer intravenous iodinated contrast media. The fused PET/CT images for each scan were evaluated by a board-certified nuclear medicine specialist with 13 years of experience and by a board-certified radiologist with 14 years of experience, in consensus, together at the same setting.

Quantification parameters

Regions of interest (ROI) were manually drawn in the form of circles and placed on the axial images of primary lesions and LNs, so that the highest uptake area and maximum standardized uptake value (SUV_{max}) in the ROI were determined. The SUV_{max} value was calculated using the following formula: $SUV_{max} = \text{maximum activity in ROI (MBq/mL)} / [\text{injected dose (MBq)} / \text{body weight (g)}]$. A breast lesion with a visually detectable increased focal uptake was accepted as the primary tumour. The LNs with a SUV_{max} equal to or more than 2.5 were accepted as malignant [20,21]. SUV_{max} of primary breast tumours (SUV_{max-T}), and tumour size which was determined by measuring the maximum tumour diameters were obtained in the non-LABC and LABC groups. SUV_{max} values of ipsilateral axillary LNs (SUV_{max-LN}) and LN size, measured as the maximum short axis diameter of ipsilateral axillary LNs, were determined in the non-LABC and LABC groups. Moreover, the number of these LNs in the LABC group was also obtained. The frequencies of metastatic locoregional LNs in the LABC group were expressed as percentages. With regard to the metastatic axillary LNs, the ones with the highest SUV values within a particular region were selected. The NT ratio was calculated by dividing SUV_{max-LN} by SUV_{max-T} [22]. Mean NT ratios of axillary LNs were obtained and compared. The presence of multifocal and/or multicentric breast tumours in both groups was evaluated to obtain their frequencies in percentages. The frequencies of the patients' stages and the frequencies of short-term remote metastasis development in non-LABC and LABC patients were given in percentages.

Statistical analysis

Means, standard deviations, and 95% confidence intervals (CI) were calculated for all the quantitative variables. PET/CT parameters between-LABC and LABC groups, between stages I–III and between patients with and without short-term remote metastasis development in the LABC group were compared using the t test (p -values < 0.05 were considered as statistically significant). Correlations between tumour size and SUV_{max-T} within each group, correlations between LN size and SUV_{max-LN} in the LABC group, correlations between PET/CT parameters of primary tumours and those of metastatic ipsilateral axillary LNs in the LABC group were calculated using Pearson's correlation coefficient. All analyses were done with SPSS software (version 16.0; SPSS Inc; Chicago, IL, USA).

Results

The patients were staged according to the American Joint Committee on Cancer (AJCC) (edition 7) staging

Table 1. Distribution of the number (% , n) of patients in non-LABC and LABC groups according to the AJCC staging criteria.

	Stage I	Stage IIA	Stage IIB	Stage IIIA	Stage IIIC
Non-LABC group (n=6)	50% (n=3/6)	50% (n=3/6)			
LABC group (n=17)			11.8% (n=2/17)	47% (n=8/17)	41.2% (n=7/17)

LABC – locally advanced breast cancer.

Table 2. Initial PET/CT parameters in stages I–III, given as mean \pm SD.

	Stage I (n=3/23)	Stage II (n=5/23)	Stage III (n=15/23)	P values
Tumour size (mm)	18.40 \pm 1.96 (%95 CI: 13.50–23.29)	30.22 \pm 10.37 (%95 CI: 17.34–43.09)	35.97 \pm 22.25 (%95 CI: 23.64–48.30)	p<0.05
LN size (mm)	9.36 \pm 0.32 (%95 CI: 8.56–10.16)	10.04 \pm 0.72 (%95 CI: 9.13–10.94)	17.54 \pm 8.81 (%95 CI: 12.66–22.42)	p<0.05
SUV _{max} -LN	0.83 \pm 0.20 (%95 CI: 0.31–1.35)	1.61 \pm 0.90 (%95 CI: 0.49–2.73)	6.52 \pm 4.88 (%95 CI: 3.82–9.23)	p<0.05
SUV _{max} -T	3.58 \pm 1.43 (%95 CI: 0.01–7.14)	7.30 \pm 2.45 (%95 CI: 4.25–10.34)	7.42 \pm 5.60 (%95 CI: 4.32–10.52)	p<0.05
NT ratio	0.209 \pm 0.062 (%95 CI: 0.053–0.364)	0.222 \pm 0.100 (%95 CI: 0.097–0.347)	0.996 \pm 0.601 (%95 CI: 0.663–1.329)	p<0.05

SD – standard deviation; CI – confidence interval; Tumour size – maximum tumour diameter; LN size – maximum short axis diameter of LN; LN – axillary lymph nodes; T – tumour; NT ratio – SUV_{max} of LN/SUV_{max} of tumour. P values <0.05 are considered as statistically significant.

criteria [23]. Staging of the patients in the non-LABC and LABC groups is given in Table 1. PET/CT parameters (the mean values of tumour size, LN size, SUV_{max}-T, SUV_{max}-LN and NT ratios) in stages I–III were statistically different (p<0.05), which is presented and compared in Table 2. The mean values of initial PET/CT parameters in the LABC group were significantly higher than those of the non-LABC group (p<0.05) (Table 3). The correlation between tumour size and SUV_{max}-T values in the non-LABC group was statistically significant (r=0.644, p=0.005). The correlation between tumour size and SUV_{max}-T values in the LABC group was statistically significant (r=0.658, p=0.004). In the LABC group, the mean number of metastatic axillary LNs was 5.47 \pm 4.09 (%95 CI: 3.36–7.57) and a statistically significant correlation between the size and the SUV_{max}-LN value of metastatic axillary LNs (r=0.773, p=0.000) was found. In the LABC group, we found several other significant correlations, including the correlation between tumour size and metastatic axillary LN size (r=0.772, p=0.000), between SUV_{max}-T value and metastatic axillary LN size (r=0.682, p=0.003), correlation between SUV_{max}-T and SUV_{max}-LN values (r=0.833, p=0.000), and between tumour size and the SUV_{max}-LN value (r=0.519, p=0.033). The percentage of the metastatic involvement of axillary LNs in the LABC group was 100% (n=17/17), whereas the percentage of the metastatic involvement of IM, SC and IC LNs in the same group was found to be 17.6% (n=3/17) for each location. Ipsilateral, multifocal and/or multicentric breast tumours were detected in 23.5% of cases (n=4/17) in the LABC group, whereas no such lesions were found in the non-LABC group. Short-term remote metastasis rates in the non-LABC and LABC groups were 0% (n=0/5) and 25% (n=3/12), respectively. In the LABC group, initial PET/CT parameters of the followed-up patients with and without

short-term remote metastases were statistically different (p<0.05), which is presented and compared in Table 4.

Discussion

LABC was defined as breast cancer in stages IIB and IIIA/B/C [18,19]. Detection of occult LN metastasis is particularly significant in LABC because of its high tendency to recur and develop early remote metastases [24,25]. Most patients with LABC receive neoadjuvant chemotherapy as initial treatment, and in these patients the initial extent of disease has serious influence on subsequent treatment [26]. The indications for neoadjuvant chemotherapy can be determined more precisely with FDG-PET, because overtreatment of patients who are considered to have a more favourable prognosis can be avoided [12]. Because of these reasons, we categorized our patients as non-LABC and LABC with the aid of FDG-PET/CT in order to avoid unnecessary treatment in patients with non-LABC and to prepare a strict follow-up program for an early detection of possible relapses and metastases in patients with LABC. Conventional imaging tools, US, mammography and contrast-enhanced MRI have been used to obtain detailed information on the primary BC tumour and metastatic locoregional LNs. However, they are not considered as sufficient imaging methods for a precise detection of metastatic axillary LNs [27]. PET/CT was recommended as a standard tool for staging of BC patients because of its value in the detection of locoregional LN metastases [28]. In a study including 137 biopsy-proven BC patients, it was concluded that FDG-PET/CT was a specific imaging modality for the prediction of axillary LN metastases, which provided a selective approach to either SLNB or ALND [29]. Although the sensitivity of FDG-PET/CT is a subject

Table 3. Initial PET/CT parameters and their statistical significance in non-LABC and LABC groups, given as mean ±SD with (%95 CI) and P value.

	Non-LABC group (n=6)	LABC group (n=17)	P value
Tumour size (mm)	26.41±11.60 (%95 CI: 14.23–38.59)	34.52±21.24 (%95 CI: 23.60–45.45)	P=0.003
LN size (mm)	9.71±0.78 (%95 CI: 8.89–10.53)	16.71±8.57 (%95 CI: 12.30–21.12)	P=0.000
SUV _{max} -LN	0.82±0.17 (%95 CI: 0.63–1.01)	6.06±4.74 (%95 CI: 3.62–8.50)	P=0.000
SUV _{max} -T	5.07±2.54 (%95 CI: 2.40–7.74)	7.53±5.28 (%95 CI: 4.82–10.25)	P=0.005
NT ratio	0.184±0.057 (%95 CI: 0.124–0.245)	0.918±0.605 (%95 CI: 0.607–1.229)	P=0.001

LABC – locally advanced breast cancer; SD – standard deviation; CI – confidence interval; Tumour size – maximum tumour diameter; LN size – maximum short axis diameter of LN; LN – axillary lymph nodes; T – tumour; NT ratio – SUV_{max} of LN/SUV_{max} of tumour. P values <0.05 are considered as statistically significant.

Table 4. Initial PET/CT parameters and their statistical significance in followed-up patients of LABC group with and without short-term remote metastasis, given as Mean ±SD with P value.

	Cases with remote metastasis (n=3)	Cases without remote metastasis (n=9)	P value
Tumour size (mm)	59.53±38.08	32.94±11.87	P=0.000
LN size (mm)	26.86±15.70	16.10±4.88	P=0.000
SUV _{max} -LN	13.08±4.49	4.32±3.84	P=0.010
SUV _{max} -T	16.00±5.51	5.97±3.61	P=0.001
NT ratio	0.818±0.014	0.755±0.303	P=0.000

LABC – locally advanced breast cancer; SD – standard deviation; Tumour size – maximum tumour diameter; LN size – maximum short axis diameter of LN; LN – axillary lymph nodes; T – tumour; NT ratio – SUV_{max} of LN/SUV_{max} of tumour. P values <0.05 are considered as statistically significant.

of debate [13,27–31], its high specificity was found useful in evaluating metastatic axillary LNs [13,27–31] and in obtaining information on metastatic involvement of other locoregional LNs, including IM LNs and SC LNs [32]. In a study group of 325 patients with BC, the positive predictive value of PET to demonstrate the disease in axillary LNs was found to be 96% [33]. In our study, we could be able to detect the metastatic involvement of axillary LNs and extra-axillary (IM, SC, IC) LNs in patients with LABC by FDG-PET/CT imaging.

The effect of tumour size and the extent of metastatic axillary LN involvement on prognosis were emphasized in many studies [22,33–36]. In our study, the mean tumour size of the LABC patients with metastatic LNs was significantly larger than that of the non-LABC patients who have a more favourable prognosis. The mean values of tumour size, LN size, SUV_{max}-T, SUV_{max}-LN and NT ratios of our patients directly correlated with their clinical status and showed statistically significant increase as the stage of the disease advanced. Furthermore, the above-mentioned PET/CT parameters in LABC patients, who developed remote metastases during a short-term follow-up, were significantly higher than those of the LABC patients without remote metastases, which meant poorer prognosis.

Already in the early studies with FDG, increased “radiotracer” uptake of the BC mass had been well defined [37]. Quantification of FDG uptake in breast tumors provide objective criteria to differentiate malignant tissue [38]. In recent years, several PET/CT studies have been performed to determine SUV_{max} values of the primary tumour in BC patients, which is an important predictor of tumour behaviour [15,17,39–41]. In a study including primary BC patients, researchers found that primary tumour FDG uptake (SUV_{max}) was significantly higher in tumours which had an unfavourable prognosis [41]. In a PET/CT study including 152 patients with primary BC, authors concluded that a high SUV_{max} level significantly correlated with tumour invasive size and LN metastases, and a high uptake would be a predictor of the aggressivity of BC [15]. In a study with 164 patients, mean SUV_{max}-T was significantly higher in patients with recurrent BC than in those without a recurrence [42]. In a PET/CT study including 55 patients with IDC, high SUV_{max}-T values were significantly related to a higher tumour size and grade, higher stage and positive LN metastatic status [43]. Similarly to the above-mentioned studies, our LABC group with a high burden of metastatic axillary LNs had larger tumours with much higher SUV_{max}-T values, as compared to the non-LABC group with no demonstrable metastatic LNs. In our

study, the significant correlation between tumour size and SUV_{max} -T values in both the non-LABC and LABC groups made us consider that the size and metabolism of the tumour are closely related to each other. This is most probably because of the increased aggressivity of BC and unfavourable changes in tumour behaviour as the time proceeds and tumour grows further. In a relatively large scale study, SUV_{max} -T values in patients with negative LNs and metastatic LNs were 4.6 ± 3.6 and 7.9 ± 5.2 , respectively [43]. In another large-scale study including 171 operable invasive BC patients, mean SUV_{max} -T values in axillary LN-positive and LN-negative groups were 6.165 and 3.954, respectively [22]. SUV_{max} -T was significantly higher in BC patients with progression compared to patients who were disease-free (10.6 ± 5.1 vs. 4.7 ± 3.5) [43]. All these results are similar to ours, which were 5.07 ± 2.54 in the non-LABC group with negative LNs and 7.53 ± 5.28 in the LABC group with metastatic LNs respectively. Such similar results obtained from different studies suggest that tumoural SUV_{max} is a reproducible and reliable parameter for the quantification and assessing prognosis in breast cancer patients. In a large-scale study, quantification of SUV was emphasized by stating that the SUV of 4.0 might have been optimal to predict prognosis [15]. Similarly, our non-LABC group with lower stages of cancer as compared to the LABC group, had a mean SUV_{max} -T value similar to the above-mentioned cut-off value (4.0) representing good prognosis.

For BC patients initial staging, which is closely related to metastatic involvement of locoregional LNs, has a major significance in determining prognosis. In a large-scale study including 24,740 BC cases, survival rates of patients with four or more metastatic axillary LNs showed a prominent decrease compared to patients with similar tumour size [35]. In the pathologic classification of the AJCC (edition 7), which is based on ALND with or without SLNB, four or more metastatic axillary LN represents a critical increase of the pathological stage from pN1 to pN2 [23]. The SUV_{max} value of metastatic axillary LNs before treatment can be used as a predictor of disease-free survival. In a PET/CT study including 65 IDC patients who had metastatic axillary LNs without remote metastasis, SUV_{max} -LN with a cutoff value of 2.8 was significantly higher in patients with recurrence than in those who were disease-free, and SUV_{max} -LN was reported to be helpful in predicting the outcome [16]. In a study including 203 patients with cT1-T3N0 BC, SUV_{max} -T was measured and it was concluded that tumoural FDG uptake was significantly related to tumour size and the number of metastatic axillary LNs [44]. It was also stated that axillary LN involvement and increased tumor size were correlated with higher SUV_{max} values [40]. Increased nodal FDG uptake was suggested to reflect intense proliferation of nodal BC cells [16]. Similarly, in our LABC patients, who were classified most commonly as stage 3 with poorer prognosis and who had unfavourable PET/CT parameters (relatively increased tumour size and SUV_{max} -T), we demonstrated a relatively high number of metastatic axillary LNs (5.47 ± 4.09) with a relatively high SUV_{max} -LN value (6.06 ± 4.74). Moreover, the significant correlation between LN size and SUV_{max} -LN of metastatic axillary LNs in our study seems to be due to the increased F-18 FDG uptake of tumour cells which abundantly infiltrated and enlarged these LNs. Furthermore,

significant correlations between tumour size and the size of metastatic axillary LNs, SUV_{max} -T and size of metastatic axillary LNs, SUV_{max} -T and SUV_{max} -LN were found in our LABC group. Primary tumour size was stated to be predictive of metastatic involvement of axillary LNs [33], SUV_{max} -T was reported to increase with tumor grade [15, 17, 39] and strong relationships were found among SUV_{max} values, BC size and metastatic involvement of axillary LNs [40]. Similarly, the correlations in our LABC group also indicate that PET/CT parameters of the primary BC mass have prominent effect on the parameters of metastatic axillary LNs. However, it was stated that false-negative FDG PET/CT in the evaluation of the axillary involvement was present particularly because of the small size of LNs and due to the limitations in the anatomic resolution of PET, which was reported to be 5–6 mm [8]. Since micrometastases cannot be excluded by a negative PET/CT, we consider that one should carefully evaluate PET/CT features of the primary mass, as we propose in our study, in order to predict an occult axillary LN metastasis.

Recently, "NT ratio" was introduced as a new PET/CT parameter and was found to be useful in evaluating metastatic LNs in non-small cell lung cancer [45] and BC [22]. In the above-mentioned study with BC patients, researchers found that the NT ratio differed significantly between LN positive (0.500) and LN negative cases (0.316). Moreover, they emphasized the usefulness of the NT ratio in quantifying axillary macrometastasis similarly to that of nodal SUV, especially in cases with tumoural SUV greater than 2.5 [22]. Similarly, in our study the mean NT ratio of the LABC group (0.918 ± 0.605) was significantly higher than that of the non-LABC group (0.184 ± 0.057), and we concluded that the NT ratio can be used as a promising quantitative parameter for the evaluation of axillary LNs suspected to be metastatic.

Detection and evaluation of IM LNs has significance in the assessment of BC patients as a whole [9]. In most cases, IM LN metastases are associated with metastatic axillary LNs, but isolated IM LN involvement can also occur [46]. The presence of IM LN metastases means that the disease should be classified as at least stage III [8, 23], and metastatic IM LNs are associated with decreased survival rates due to increased remote metastases [8, 47]. A nearly 3-fold increase of the mortality risk was predicted in patients with metastatic IM LNs [47], and demonstration of metastatic IM LNs causes critical changes in treatment planning [28,32,48]. For all these reasons, imaging of a metastatic IM LN has ultimate significance and FDG PET or PET/CT were reported to be superior to conventional methods in detecting IM LN involvement [49–52]. Lymphoscintigraphy and related procedures for IM LNs are less helpful and much more difficult than for axillary LNs [8]. As a noninvasive imaging modality, FDG PET/CT seems to play a greater role in detection of metastatic IM LNs. In our study, we were able to detect metastatic IM LNs in 17.6% of patients in the LABC group, which was critical for initial staging of these patients. Detection of metastatic SC or IC LNs increases the stage of the disease to IIIC [23]. In our study, we could also demonstrate metastatic SC or IC LNs in 17.6% of patients in the LABC group, which directly influenced disease staging, as mentioned above.

Our study had some limitations, mostly due its retrospective design and because of the relatively small sample sizes. Firstly, all of our patients had IDC. Therefore, our results seem to be restricted to IDC patients, and we could not compare PET/CT features of this type of tumour with other types of invasive BC. Secondly, because of the limited number of cases with metastatic IM, SC and IC LNs, we could not correlate PET/CT parameters of the primary tumours and those of metastatic extra-axillary locoregional LNs. Thirdly, we could not compare SUV_{max} values of the primary tumour with other clinicopathological parameters including estrogen receptor (ER), progesterone receptor (PR) and human epidermal growth factor receptor2 (HER2) expression. Lastly, we could not correlate our findings with long-term disease-free survival in our patients for the evaluation of the long-term prognostic value of our results. Nevertheless, we consider that the number of our patients was sufficient to demonstrate the usefulness of PET/CT for evaluating patients in both the non-LABC and LABC group, patients in stages I–III, and patients with or without

remote metastases in the LABC group. The relationship between PET/CT parameters of the primary BC mass and those of metastatic axillary LNs in the LABC group could also be studied.

Conclusions

Our patients with LABC had relatively larger primary tumours with a relatively higher SUV_{max}-T values, which indicated aggressivity of BC at the time of initial diagnosis. We have found significant correlations between PET/CT parameters of primary tumours and those of metastatic axillary LNs. PET/CT is a reproducible, noninvasive imaging modality which is useful in the evaluation of both the primary BC mass and its relationship with metastatic axillary LNs.

Conflicts of interest

The authors declare that they have no conflicts of interest.

References:

- Greenlee RT, Murray T, Bolden S, Wingo PA: Cancer statistics, 2000. *Cancer J Clin*, 2000; 50(1): 7–33
- <http://www.cancer.gov/types/breast>
- <http://www.cancerresearchuk.org/about-cancer/type/breast-cancer/about/types/invasive-ductal-breast-cancer>
- Uçmak Vural G, Şahiner I, Demirtaş S et al: Sentinel lymph node detection in contralateral axilla at initial presentation of a breast cancer patient: case report. *Mol Imaging Radionucl Ther*, 2015; 24(2): 90–93
- Robertson LJ, Hand F, Kell MR: FDG-PET/CT in the staging of local/regional metastases in breast cancer. *Breast*, 2011; 20(6): 491–94
- Eubank WB, Mankoff DA, Vesselle HJ et al: Detection of locoregional and distant recurrences in breast cancer patients by using FDG PET. *Radiographics*, 2002; 22(1): 5–17
- Saez RA, McGuire WL, Clark GM: Prognostic factors in breast cancer. *Semin Surg Oncol*, 1989; 5(2): 102–10
- Liu Y: Role of FDG PET-CT in evaluation of locoregional nodal disease for initial staging of breast cancer. *World J Clin Oncol*, 2014; 5(5): 982–89
- Krishnamurthy S: Current applications and future prospects of fine-needle aspiration biopsy of locoregional lymph nodes in the management of breast cancer. *Cancer*, 2009; 117(6): 451–62
- Langer I, Guller U, Berclaz G et al: Morbidity of sentinel lymph node biopsy (SLN) alone versus SLN and completion axillary lymph node dissection after breast cancer surgery: A prospective Swiss multicenter study on 659 patients. *Ann Surg*, 2007; 245(3): 452–61
- Scalfani LM, Baron RH: Sentinel lymph node biopsy and axillary dissection: Added morbidity of the arm, shoulder and chest wall after mastectomy and reconstruction. *Cancer J* 2008; 14(4): 216–22
- Inoue T, Yutani K, Taguchi T et al: Preoperative evaluation of prognosis in breast cancer patients by [(18F)2-Deoxy-2-fluoro-D-glucose-positron emission tomography. *J Cancer Res Clin Oncol*, 2004; 130(5): 273–78
- Veronesi U, De Cicco C, Galimberti VE, Fernandez JR et al: A comparative study on the value of FDG-PET and sentinel node biopsy to identify occult axillary metastases. *Ann Oncol*, 2007; 18(3): 473–78
- Grabellus F, Sheu SY, Bachmann HS et al: The XbaI G>T polymorphism of the glucose transporter 1 gene modulates 18F-FDG uptake and tumor aggressiveness in breast cancer. *J Nucl Med*, 2010; 51(8): 1191–97
- Ueda S, Tsuda H, Asakawa H et al: Clinicopathological and prognostic relevance of uptake level using 18F-fluorodeoxyglucose positron emission tomography/computed tomography fusion imaging (18F-FDG PET/CT) in primary breast cancer. *Jpn J Clin Oncol*, 2008; 38(4): 250–58
- Song BI, Lee SW, Jeong SY et al: 18F-FDG uptake by metastatic axillary lymph nodes on pretreatment PET/CT as a prognostic factor for recurrence in patients with invasive ductal breast cancer. *J Nucl Med*, 2012; 53(9): 1337–44
- Groheux D, Giacchetti S, Moretti JL et al: Correlation of high 18F-FDG uptake to clinical, pathological and biological prognostic factors in breast cancer. *Eur J Nucl Med Mol Imaging*, 2011; 38(3): 426–35
- Hortobagyi GN, Buzdar AU, Strom EA et al: Primary chemotherapy for early and advanced breast cancer. *Cancer Lett*, 1995; 90(1): 103–9
- Trudeau ME, Chapman JA, Guo B et al: A phase I/II trial of epirubicin and docetaxel in locally advanced breast cancer (LABC) on 2-weekly or 3-weekly schedules: NCIC CTG MA.22. *Springerplus*, 2015; 4: 631
- Straver ME, Aukema TS, Olmos RA et al: Feasibility of FDG PET/CT to monitor the response of axillary lymph node metastases to neoadjuvant chemotherapy in breast cancer patients. *Eur J Nucl Med Mol Imaging*, 2010; 37(6): 1069–76
- Yang JH, Nam SJ, Lee TS et al: Comparison of intraoperative frozen section analysis of sentinel node with preoperative positron emission tomography in the diagnosis of axillary lymph node status in breast cancer patients. *Jpn J Clin Oncol*, 2001; 31(1): 1–6
- Futamura M, Asano T, Kobayashi K et al: Prediction of macrometastasis in axillary lymph nodes of patients with invasive breast cancer and the utility of the SUV lymph node/tumor ratio using FDG-PET/CT. *World J Surg Oncol*, 2015; 13: 49
- <https://cancerstaging.org/references-tools/quickreferences/Documents/BreastSmall.pdf>
- Lee JH: Radionuclide methods for breast cancer staging. *Semin Nucl Med*, 2013; 43(4): 294–98
- Al-Husaini H, Amir E, Fitzgerald B et al: Prevalence of overt metastases in locally advanced breast cancer. *Clin Oncol (R Coll Radiol)*, 2008; 20(5): 340–44
- Whitman GJ, Strom EA: Workup and staging of locally advanced breast cancer. *Semin Radiat Oncol*, 2009; 19(4): 211–21
- Fuster D, Duch J, Paredes P et al: Preoperative staging of large primary breast cancer with [18F]fluorodeoxyglucose positron emission tomography/computed tomography compared with conventional imaging procedures. *J Clin Oncol*, 2008; 26(29): 4746–51
- Koolen BB, Valdés Olmos RA, Elkhuisen PH et al: Locoregional lymph node involvement on 18F-FDG PET/CT in breast cancer patients scheduled for neoadjuvant chemotherapy. *Breast Cancer Res Treat*, 2012; 135(1): 231–40
- Kim J, Lee J, Chang E et al: Selective sentinel node plus additional non-sentinel node biopsy based on an FDG-PET/CT scan in early breast cancer patients: single institutional experience. *World J Surg*, 2009; 33(5): 943–49

30. Heusner TA, Kuemmel S, Hahn S et al: Diagnostic value of full-dose FDG PET/CT for axillary lymph node staging in breast cancer patients. *Eur J Nucl Med Mol Imaging*, 2009; 36(10): 1543–50
31. Ueda S, Tsuda H, Asakawa H et al: Utility of 18F-fluoro-deoxyglucose emission tomography/computed tomography fusion imaging (18F-FDG PET/CT) in combination with ultrasonography for axillary staging in primary breast cancer. *BMC Cancer*, 2008; 8: 165
32. Bernsdorf M, Berthelsen AK, Wielenga VT et al: Preoperative PET/CT in early-stage breast cancer. *Ann Oncol*, 2012; 23(9): 2277–82
33. Pritchard KI, Julian JA, Holloway CM et al: Prospective study of 2-[¹⁸F]fluorodeoxyglucose positron emission tomography in the assessment of regional nodal spread of disease in patients with breast cancer: An Ontario clinical oncology group study. *J Clin Oncol*, 2012; 30(12): 1274–79
34. Rosen PR, Groshen S, Saigo PE et al: A long-term follow-up study of survival in stage I (T1N0M0) and stage II (T1N1M0) breast carcinoma. *J Clin Oncol*, 1989; 7(3): 355–66
35. Carter CL, Allen C, Henson DE: Relation of tumor size, lymph node status, and survival in 24,740 breast cancer cases. *Cancer*, 1989; 63(1): 181–87
36. Wu SG, He ZY, Li Q et al: Prognostic value of metastatic axillary lymph node ratio for Chinese breast cancer patients. *PLoS One*, 2013; 8(4): e61410
37. Minn H, Soini I: [¹⁸F]fluorodeoxyglucose scintigraphy in diagnosis and follow up of treatment in advanced breast cancer. *Eur J Nucl Med*, 1989; 15(2): 61–66
38. Avril N, Bense S, Ziegler SI et al: Breast imaging with fluorine-18-FDG PET: quantitative image analysis. *J Nucl Med*, 1997; 38(8): 1186–91
39. Jung NY, Kim SH, Choi BB et al: Associations between the standardized uptake value of (18)F-FDG PET/CT and the prognostic factors of invasive lobular carcinoma: in comparison with invasive ductal carcinoma. *World J Surg Oncol*, 2015; 13: 113
40. Sanli Y, Kuyumcu S, Ozkan ZG et al: Increased FDG uptake in breast cancer is associated with prognostic factors. *Ann Nucl Med*, 2012; 26(4): 345–50
41. Koolen BB, Vrancken Peeters MJ, Wesseling J et al: Association of primary tumour FDG uptake with clinical, histopathological and molecular characteristics in breast cancer patients scheduled for neoadjuvant chemotherapy. *Eur J Nucl Med Mol Imaging*, 2012; 39(12): 1830–38
42. Zhang X, Wu F, Han P: The role of (18)F-FDG PET/CT in the diagnosis of breast cancer and lymph nodes metastases and micrometastases may be limited. *Hell J Nucl Med*, 2014; 17(3): 177–83
43. Song BI, Hong CM, Lee HJ et al: Prognostic value of primary tumor uptake on F-18 FDG PET/CT in patients with invasive ductal breast cancer. *Nucl Med Mol Imaging*, 2011; 45(2): 117–24
44. De Cicco C, Gilardi L, Botteri E et al: Is [¹⁸F] fluorodeoxyglucose uptake by the primary tumor a prognostic factor in breast cancer? *Breast*, 2013; 22(1): 39–43
45. Cerfolio RJ, Bryant AS: Ratio of the maximum standardized uptake value on FDG-PET of the mediastinal (N2) lymph nodes to the primary tumor may be a universal predictor of nodal malignancy in patients with nonsmall-cell lung cancer. *Ann Thorac Surg*, 2007; 83(5): 1826–30
46. Katz MS, Schapira L, Harisinghani MG, Hughes KS: Palpable right breast mass in a pregnant woman. *Nat Clin Pract Oncol*, 2005; 2(4): 218–21
47. Yao MS, Kurland BF, Smith AH et al: Internal mammary nodal chain drainage is a prognostic indicator in axillary node-positive breast cancer. *Ann Surg Oncol*, 2007; 14(10): 2985–93
48. Madsen E, Gobardhan P, Bongers V et al: The impact on post-surgical treatment of sentinel lymph node biopsy of internal mammary lymph nodes in patients with breast cancer. *Ann Surg Oncol*, 2007; 14(4): 1486–92
49. Eubank WB, Mankoff DA, Takasugi J et al: [¹⁸F]fluorodeoxyglucose positron emission tomography to detect mediastinal or internal mammary metastases in breast cancer. *J Clin Oncol*, 2001; 19(15): 3516–23
50. Choi YJ, Shin YD, Kang YH et al: The effects of preoperative (18) F-FDG PET/CT in breast cancer patients in comparison to the conventional imaging study. *J Breast Cancer*, 2012; 15(4): 441–48
51. Tatsumi M, Cohade C, Mourtzikos KA et al: Initial experience with FDG-PET/CT in the evaluation of breast cancer. *Eur J Nucl Med Mol Imaging*, 2006; 33(3): 254–62
52. Mittal BR, Manohar K, Kashyap R et al: The role of (18)F-FDG PET/CT in initial staging of patients with locally advanced breast carcinoma with an emphasis on M staging. *Hell J Nucl Med*, 2011; 14(2): 135–39