


Contents lists available at [ScienceDirect](https://www.sciencedirect.com)

Trauma Case Reports

journal homepage: www.elsevier.com/locate/tcr

Case Report

Transverse capitellar shear fracture with interposed radial head fragment. A previously unclassified type of distal humeral fracture[☆]

Jens Böttcher^{*}, Paul Martineau

Montreal General Hospital, McGill University Montreal, Montreal, Canada
 Ospedale Beata Vergine Mendrisio, 6850 Mendrisio, Switzerland

ARTICLE INFO

Keywords:

Capitellum fracture classification
 Radial head fracture
 Transversal shear fracture
 Capitellum fracture
 Frontal shear fracture

ABSTRACT

This is the first description of a transverse shear fracture on the radial capitellum. So far only fractures in the frontal plane have been classified. MRI examinations in radial head fractures type Mason II–III shows that osteocondral fractures of radial capitellum are much more common than previously thought (10–30%). Treatment of this type of fracture is similar to frontal shear fractures.

Patient history

Consultation in our emergency room of a 68-year-old woman presenting after direct fall on the right elbow of with pain and limitation of extension of the elbow joint. The initial standard elbow X-rays in AP/lateral plane revealed a defect in the radial head. Essentially a Mason type II fracture of the radial head but without being able to identify the missing bony fragment and additionally with a subtle radio-opacity in the joint space ([Photo 1](#)). Due to the high index of suspicion and the important clinical symptoms, a computed tomography scan was performed demonstrating a transverse shear fracture at the capitellum with an interposed fragment of the Mason II fracture ([Photo 2](#)).

Operative technique

Supine position of the patient, with arm table. The procedure was performed with a tourniquet. A Kocher approach was performed for the open reduction the fracture. The interposed radial head fragment was removed from the fracture site of the distal humerus. [Photo 3](#) shows the fracture gap at the distal humerus and the defect at the radial head. Fixation of the radial head fragment was performed with two 2 mm screws (Compact Hand, Synthes GmbH, Oberdorf, Switzerland). The shear fragment from the capitellum included approximately 20% cartilage coverage. This piece was fixed with 2 headless compression screws (Acutrak headless compression screw micro, Rue de Bray, France) ([Photo 4](#)). X-ray control after fixation ([Photo 5](#)). Post-operatively, we instituted immediate functional rehabilitation with unrestricted pronation and supination, flexion and extension without axial loading of the distal radius. At 2 week control the pain on the Visual analog scale (VAS) 1.5. Range of motion extension – flexion 0–15–130°, pro- and supination symmetrical with the uninjured extremity. 3 month control with full functional recovery, ASES score 100, Quick DASH 0, symmetrical range of motion, except for a lag of extension of 5° ([Photos 6 and 7](#)).

[☆] The article has not been published or presented on a public occasion/journal.

^{*} Corresponding author at: Ospedale Beata Vergine Mendrisio, 6850 Mendrisio, Switzerland.

E-mail address: jens.boettcher@eoc.ch (J. Böttcher).

<https://doi.org/10.1016/j.tcr.2019.100231>

Accepted 21 July 2019

Available online 29 July 2019

2352-6440/ © 2019 The Authors. Published by Elsevier Ltd. This is an open access article under the CC BY-NC-ND license (<http://creativecommons.org/licenses/by-nc-nd/4.0/>).

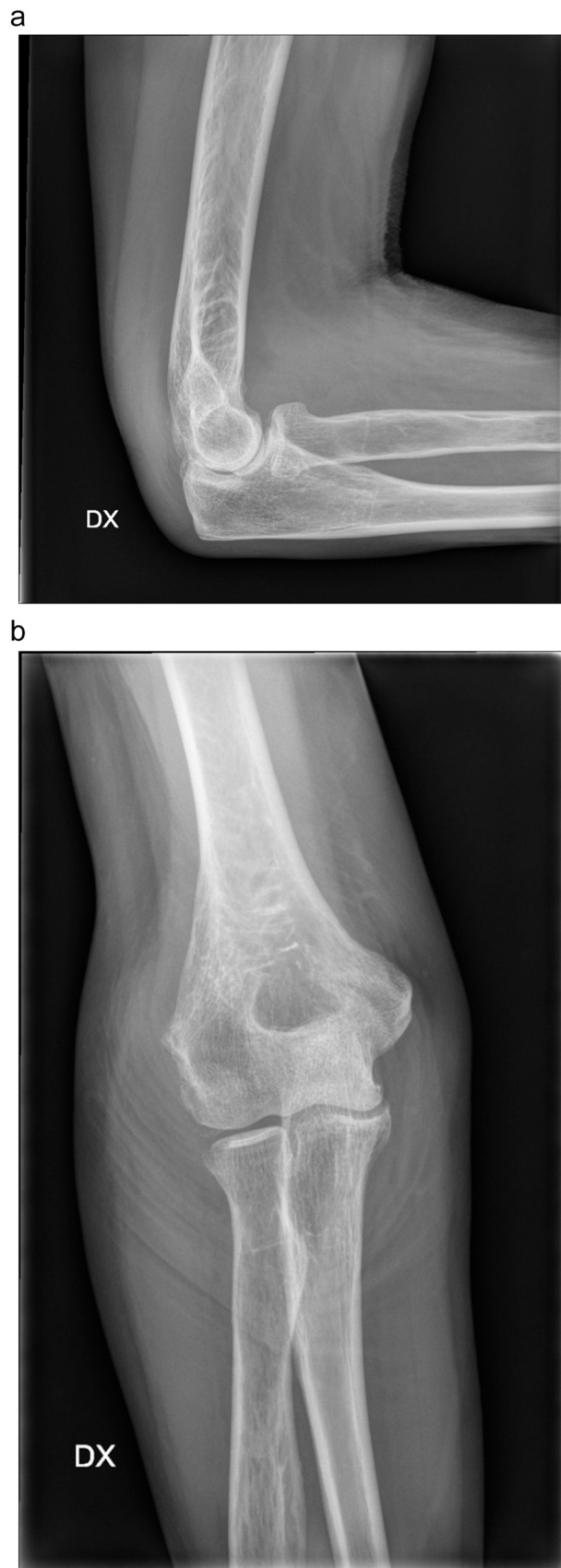


Photo 1. Preoperative x- ray of the elbow Lateral /AP: small fragment inside the laterale joint line, defect on the radial head.

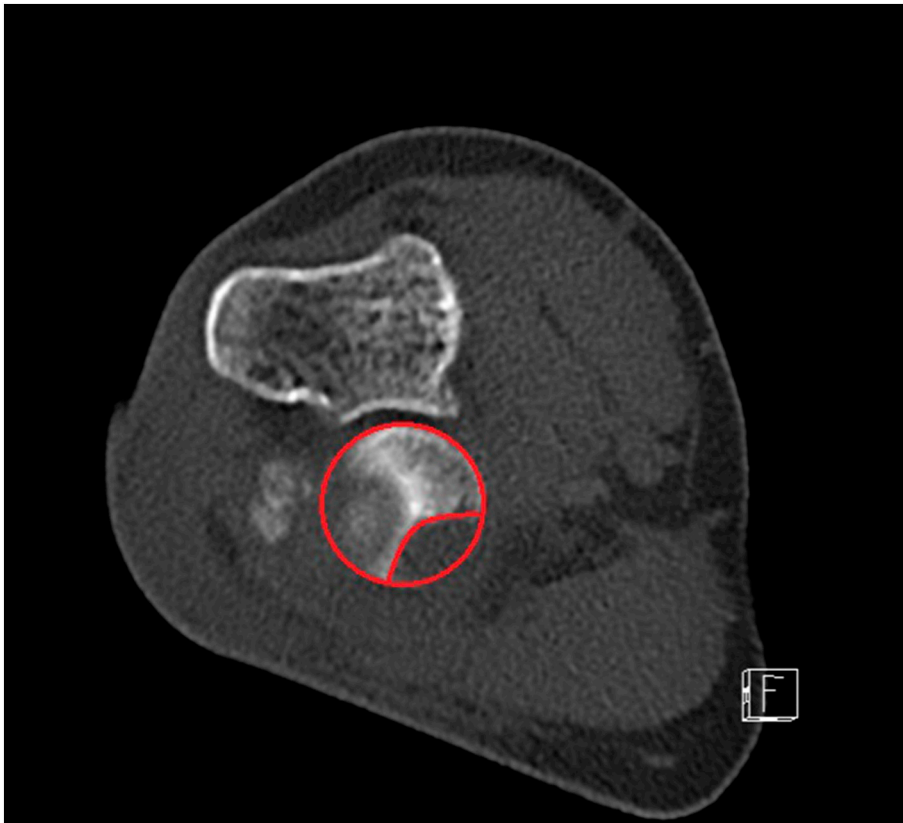


Photo 2. Preoperative axial CT scan showing the defect on the radial head.

Discussion

Isolated fractures of the capitellum are very rare, occurring at a rate of about 1.5 per 100,000 population with female dominance [1]. Regarding capitellar fractures, existing fracture classifications always describe the shearing in the frontal plane with varying extents, such as, for example, in the McKee modified Bryan and Morrey classification [2]. In this classification, a type II (Kocher Lorenz) is described as an osteochondral shearing in the coronal plane. The AO also describes only the frontal or sagittal fracture planes. Ring described 5 types in 2003 [3] after retrospective analysis of 21 primary articular capitellar fractures. However, all types were frontal plane variants. Another described classification of capitellum and trochlear fractures is the Dubberley Classification [4], which is based on a retrospective fracture analysis of over 10 years operated and controlled 28 patients. Again, three fracture types of the capitellum and the trochlear are described, the fracture plane is in the frontal in all three types: type 1 capitellum with lateral trochlear, type 2 capitellum with trochlear as one fragment and type 3 capitellum and trochlear as a separate fragments.

Ring noted in his case study [3] the poor correlation of fracture description with standard X-rays compared to the intraoperative findings, therefore he recommends the wide indication for preoperative computed tomography, which we can only confirm in our case.

Concomitant fractures, as in the case described, are reported within 21–37% [1,5] of capitellar fractures.

Our patient described a direct fall on the bent elbow. Amis [6] examined the fracture mechanism in 40 cadaveric elbows. He was able to reproduce the typical frontal plane fracture of the capitellum by indirect trauma with full elbow extension, and once by direct force application to a 90° flexed elbow. Radial head fractures were all produced due to indirect trauma to the elbow flexed between 0 and 80°. The analysis of the fracture pattern of our patient would be more likely to indicate an indirect trauma to the distal radius with axial impact to the radial head on the capitellum in a flexed elbow joint. Unfortunately, Amis had not investigated any indirect trauma at flexion degrees over 80°.

Rhyou [7] published a retrospective analysis of pre-operative MRI to better understand the fracture mechanism of radial head and coronoid fractures. He concluded that radius head without coronoid fractures originated mainly from valgus stress with bone edema

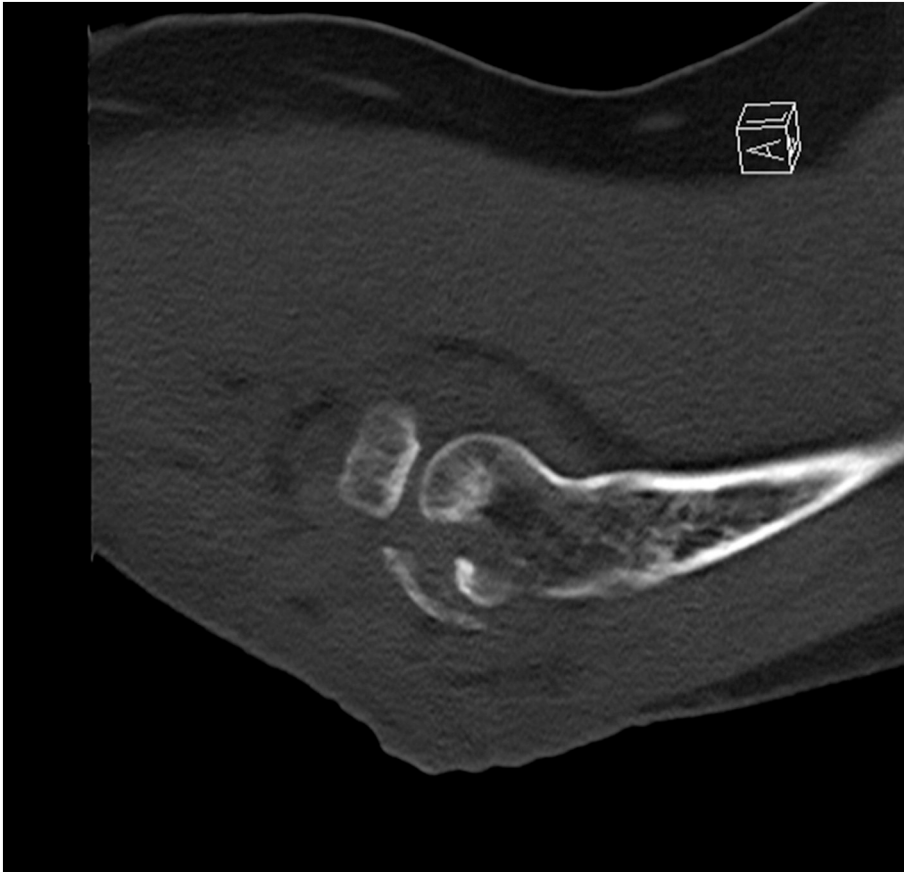


Photo 3. Preoperative sagittal CT scan showing the interposed fragment of the radial head and the shear fragment of the capitellum.

on the capitellum and ulnar side ligament injury. We therefore assume that during the fall on the bend elbow a valgus vector on his forearm was probably present. We believe this valgus stress has provoked the radial head fracture in first line. Only in this case, it was not only a bone edema on the capitellum.

Van Riet [8] had studied concomitant injuries of 333 radial head fractures, with 16% coronoid fractures and 14% elbow dislocations, 2% capitellum fractures, but unfortunately did not describe exact fracture morphology. Nalbantoglu [9] systematically examined his surgically treated radial head fractures and found presence of capitellar cartilage damage in 10 of 51 patients (19%) always at the inferior lateral side of the capitellum. A systematic MRI examination after 46 radial head fractures by Klaas [10] was able to detect capitellum injuries in 39%, with osteochondral defects in 13%. Itamura [11] detected 7 osteochondral defects (29%) in 24 isolated Mason II and III fractures with the MRI. The types of defects are not described in detail in both MRI studies, however, the Klaas study shows an MRI image which indicates a chondral damage in the transverse plane.

Conclusion

Treatment-requiring capitellum fractures are very rare, however, considering the MRI examinations for radial head fractures, probably much more frequently than indicated in the literature. If one would systematically perform CT/MRI examination for Mason II and III injuries, we suppose that the transverse fracture plane would be seen more frequent.

In a simple X-ray, the size and extension of the fracture is often underestimated.

This is the first time description of a transverse plane shear fracture of the capitellum, the treatment and recovery is similar to the frontal shear fractures.

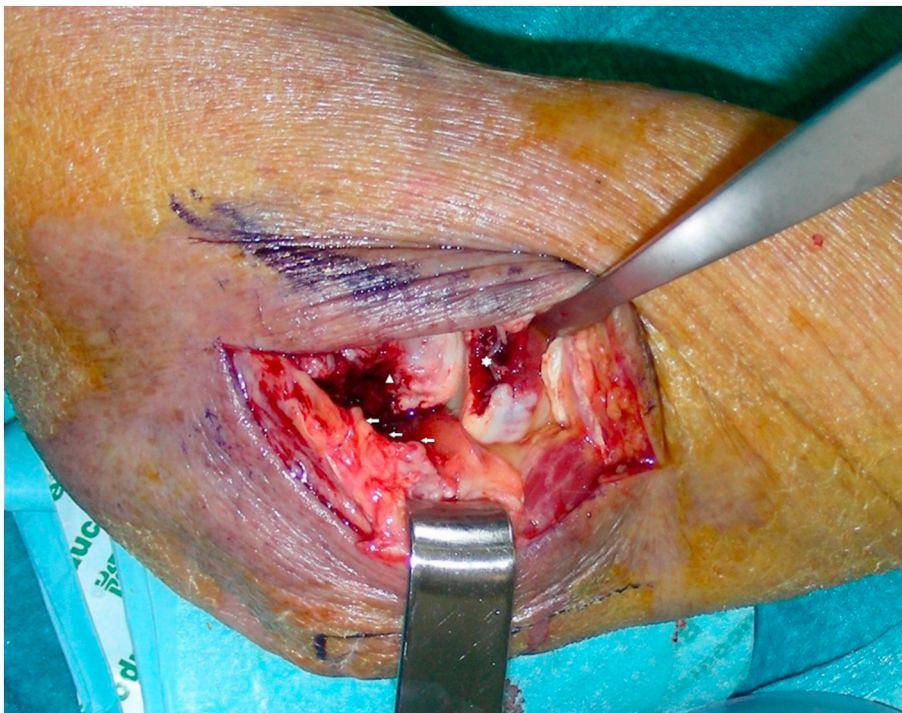


Photo 4. Intraoperative defect on the radial head (star), defect on the Capitellum (triangle), shear fragment (arrows).

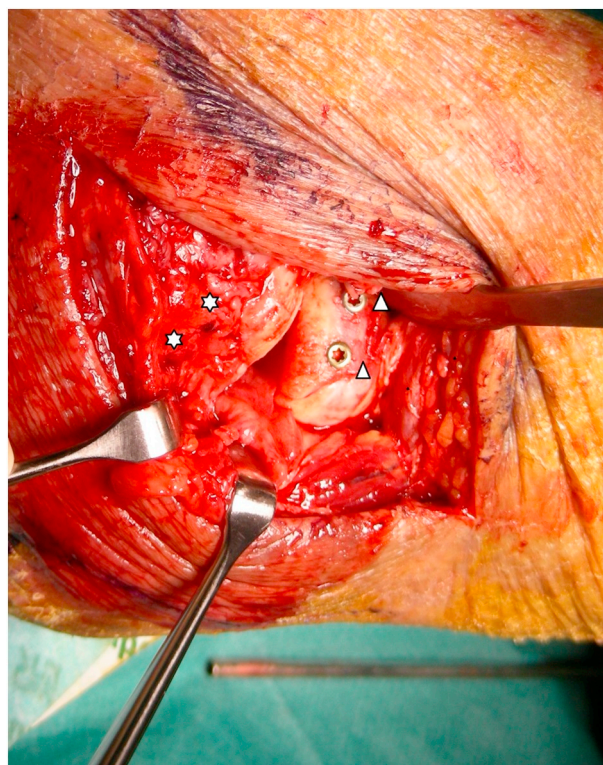


Photo 5. Intraoperative: screw fixation of the radial head fragment (triangles), headless screw fixation of the shear fragment (stars).

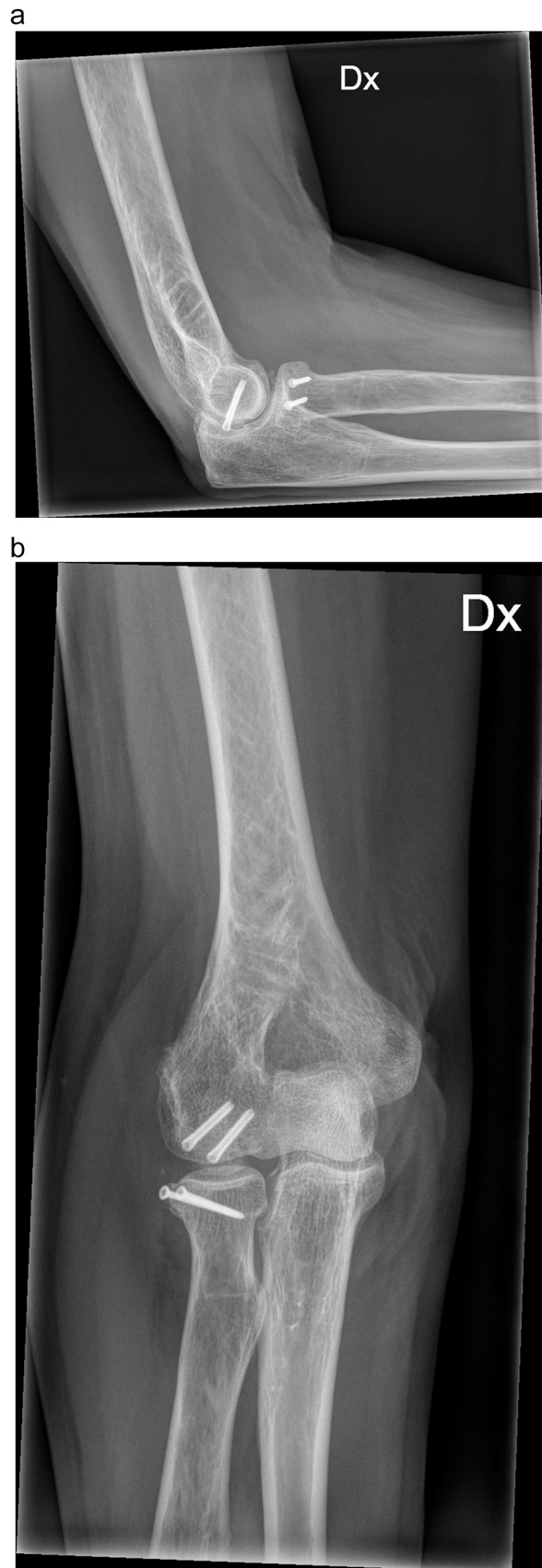

Photo 6. 3 Months x- ray controll Ap / lateral with healed fracture.

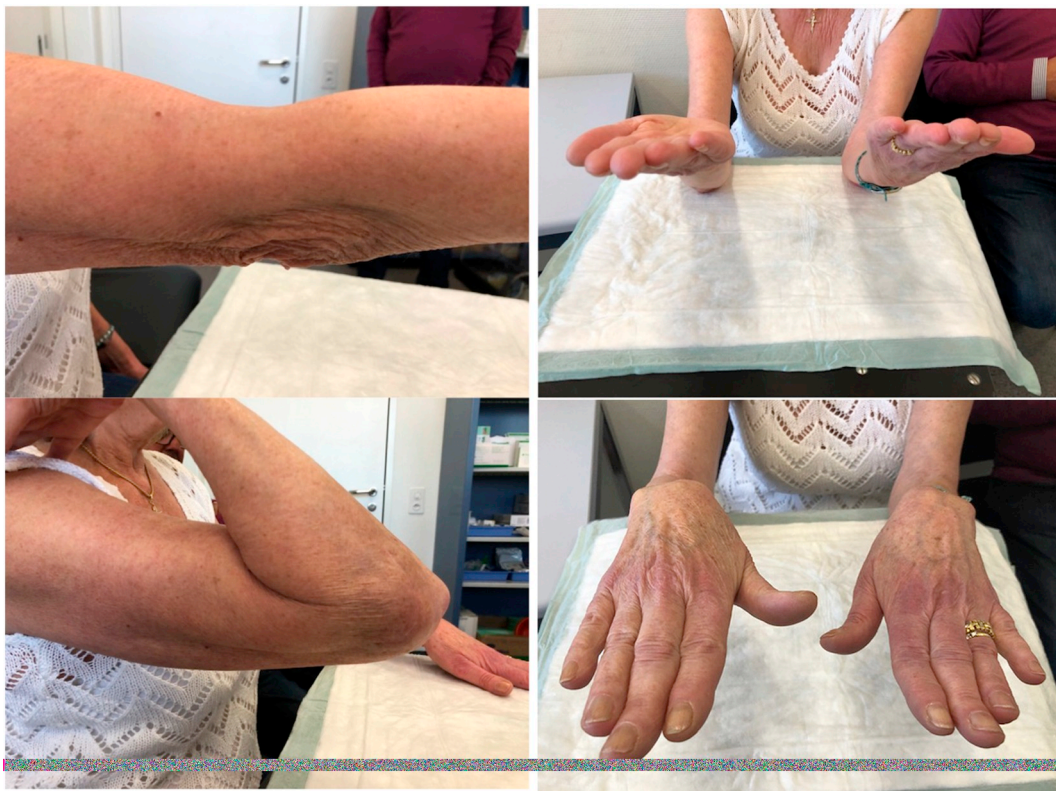

Photo 7. 3 Months controll with functional results.

References

- [1] A.C. Watts, A. Morris, C.M. Robinson, Fractures of the distal humeral articular surface, *J. Bone Joint Surg. (Br.)* 89-B (2007) 510–515.
- [2] M. McKee, J.B. Jupiter, H.B. Bamberger, Coronal shear fractures of the distal end of the humerus, *J. Bone Joint Surg. Am.* 78-A (1) (1996) 49–54.
- [3] D. Ring, J.B. Jupiter, L. Gulotta, Articular fractures of the distal part of the humerus, *J. Bone Joint Surg. Am.* 85-A (2) (2003) 232–238.
- [4] J.H. Dubberley, K.J. Faber, J.C. MacDermid, et al., Outcome after open reduction and internal fixation of capitellar and trochlear fractures, *J. Bone Joint Surg. Am.* 88-A (1) (2006) 46–54.
- [5] V. Rausch, M. Königshausen, T.A. Schildhauer, et al., Fractures of the capitellum humeri and their associated injuries, *Obere Extrem.* 13 (2018) 33–37.
- [6] Amis AA, Miller JH: The mechanisms of elbow fractures. An investigation using impact test in vitro. *Injury* 26(3), 163–168.
- [7] I.H. Rhyou, J.H. Lee, K.B. Kim, What injury mechanism and patterns of ligament status are associated with isolated coronoid, isolated radial head, and combined fractures, *Clin. Orthop. Relat. Res.* 475 (2017) 2308–2315.
- [8] Van Riet RP, Morrey BF, O'Driscoll SW, et al. Associated injuries complication radial head fractures, a demographic study. *Clin. Orthop. Relat. Res.* 441, 351–355.
- [9] U. Nalbantoglu, A. Gereli, B. Kocaoglu, et al., Capitellar cartilage injuries concomitant with radial head fractures, *J. Hand Surg. Am.* 33 (9) (2008) 1602–1607.
- [10] L. Kaas, J.L. Turkenburg, R.P. van Riet, et al., Magnetic resonance imaging findings in 46 elbows with a radial head fracture, *Acta Orthop.* 81 (3) (2010) 373–376.
- [11] Itamura J, N. Roidis, R. Mirzayan, et al., Radial head fractures: MRI evaluation of associated injuries, *Shoulder Elbow Surg.* 14 (4) (2005) 421–424.