



Contents lists available at ScienceDirect

Gynecology and Minimally Invasive Therapy

journal homepage: www.e-gmit.com

Letter to the Editor

Case report of a rare pure uterine lipoma treated by laparoscopic hysterectomy



To the Editor,

We herein present a case of a pure lipoma, arising from the uterine fundus, coincidental with an ovarian tumor. Both masses were successfully resected with laparoscopy.

A 60-year-old woman (gravida 3, para 2) was referred to our hospital with both an ovarian and a uterine tumor, which were found by her physician during a routine physical checkup. Her past medical history contained nothing particular to this event. Importantly, she did not present with any related symptoms, such as abdominal pain or abnormal genital bleeding. The patient's serum tumor markers for CA125, carcinoembryonic antigen (CEA), and CA19-9 were all in the normal range, and her uterine cervical cytology was negative.

Transvaginal ultrasonography revealed a hyperechogenic tumor (25 mm in diameter) in the fundus of the uterus (Figure 1). Transvaginal ultrasonography showed a second mass (55 mm in diameter), containing both hyperechogenic and isoechoic regions, in the right ovary.

Magnetic resonance imaging (MRI) was applied to investigate the ovarian tumor; it also described the tumor in the uterine myometrium, with a high intensity pattern in both the T1/T2 weighted sequences, and the MRI signal dropped out in the fat suppression series. The tumor of the uterus was preoperatively suspected of being a lipoleiomyoma, lipoma, or some other neoplastic malignancy.

The contents of the right ovarian tumor were suppressed in the MRI fat suppression series. This suggested that the ovarian tumor was a mature cystic teratoma (Figure 2).

Laparoscopy-assisted vaginal hysterectomy and bilateral salpingo-oophorectomy were performed. The gross weight of the combined uterus and left adnexa was 118 g. The gross findings for the posterior uterine wall showed a yellow-colored soft tumor of 25 mm in diameter (Figure 3). The contents of the right ovarian tumor were hair and fatty tissue (figures not shown).

Microscopic examination of the posterior uterine wall showed atrophic endometrium with an intramural tumor composed of benign mature adipose tissue. The tumor was clearly delineated from the normal myometrium and no smooth muscle cells or fibrous elements were seen within the tumor (Figure 4).

The final histopathology confirmed a diagnosis of a pure lipoma of the uterus, and of a mature cystic teratoma of the right ovary. The patient has since recovered, without any complications, and she was discharged on the 8th postoperative day.

Lipomatous tumors of the uterus are generally benign neoplasms, and are always at least partially composed of adipose tissue. They can be separated into entirely pure or mixed-cell tumor types.

The mixed-cell-type tumors, such as lipoleiomyoma or fibrolipoma, are the predominant form of lipomatous tumors; they are composed of smooth muscle or fibrous tissue intermingled with adipocytes.^{1,2} A pure lipoma, by contrast, consists totally of adipose cells; any smooth muscle cells present are peripherally displaced. A pure uterine lipoma is quite rare; only a few have ever been reported,¹ with the estimated incidence among uterine tumors considered to be in the range of 0.03–0.2%.^{2,3}

Notably, lipomatous tumors of the uterus include the malignant liposarcoma.² Malignant liposarcoma can be characterized by cellular pleomorphism, brisk mitotic activity, lipoblasts and infiltrative margin, and specific immunohistochemical findings; these characteristics are highly useful in differentially distinguishing liposarcomas from benign uterine lipomatous tumors.⁴

It is still unclear how lipomas arise within the uterus, a tissue in which fatty tissue is thought to not normally exist. Many hypotheses have been espoused to explain the development of a pure lipoma; they include misplaced embryonic mesodermal cells retaining a potential for lipoblast differentiation, totipotent mesenchymal cell transformation, and metaplasia of smooth muscle cells into adipose cells.^{1,2,5}

Pure lipoma occurs mainly in postmenopausal woman between the ages of 50 years and 70 years, and it is commonly

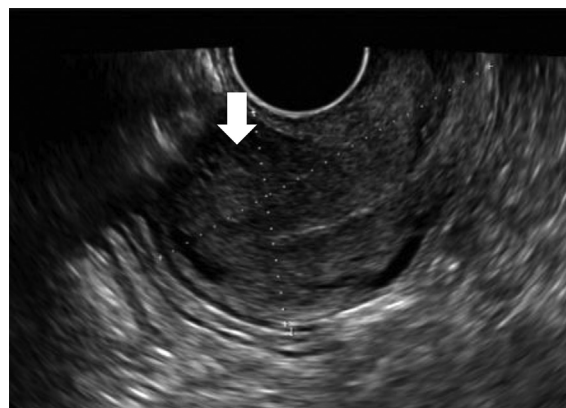


Figure 1. Transvaginal sonography imaging. Hyperechogenic tumor was detected in the fundus of the uterus (arrows).

Conflicts of interest: The authors report no conflicts of interest.

<http://dx.doi.org/10.1016/j.gmit.2016.04.004>

2213–3070/Copyright © 2016, The Asia-Pacific Association for Gynecologic Endoscopy and Minimally Invasive Therapy. Published by Elsevier Taiwan LLC. This is an open access article under the CC BY-NC-ND license (<http://creativecommons.org/licenses/by-nc-nd/4.0/>).

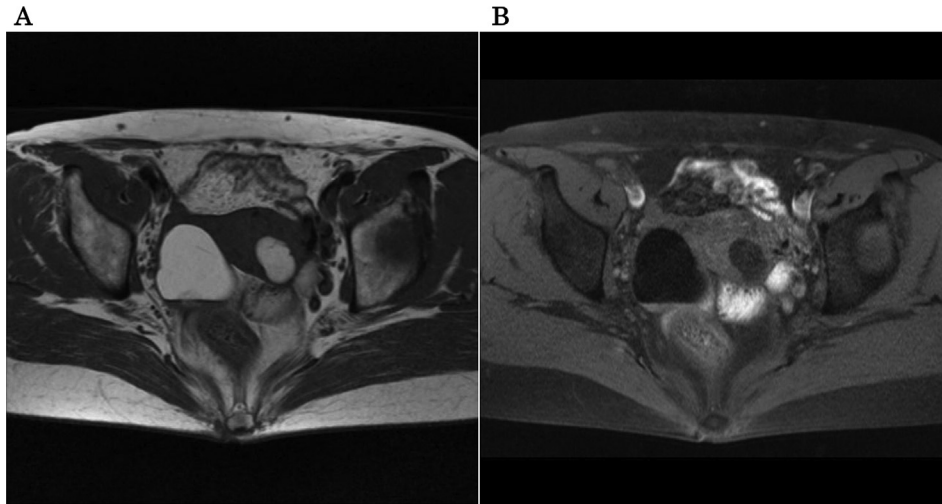


Figure 2. Transverse magnetic resonance imaging (MRI). (A) T1-weighted image. Both the right ovarian tumor and the posterior uterine myometrium tumor show high intensity. (B) Fat-suppression image. Both tumors have signal dropout due to fat.

associated with obesity.^{1,3} Although most pure lipoma patients are asymptomatic, it has been reported that some patients have presented with a palpable abdominal mass, abdominal pain, pelvic discomfort, or abnormal postmenopausal uterine bleeding. These symptoms are similar to those for leiomyomas; however, leiomyomas more commonly occur in younger, premenopausal women.³

During a preoperative examination, MRI has been reported to be useful in helping provisionally diagnose a lipoma, because it can provide evidence of fat content, occasionally with a chemical shift artifact.³ It has been reported that MRI can help to differentiate a pure lipoma from a lipoleiomyoma.⁶ However, it has also been reported that preoperative diagnosis of liposarcoma by MRI is difficult and is not definitive.

It is also reported that ultrasonography is useful to diagnosis uterine lipoma; strong hyperechogenicity associated with absence of color flow should be sufficient to prevent confusion with uterine myomas in most cases.^{3,7}

Pure lipoma is a benign disease with a good prognosis, as its malignant conversion is quite rare. The limited literature that exists suggests that asymptomatic lipomas should be conservatively observed.³ By contrast, surgical resection should be considered in the ultra-rare symptomatic cases. Laparoscopic surgery is a good choice for this pathway because it is less invasive.

When deciding upon surgery, it is important to be cognizant that, in contrast to leiomyomas, lipomas occur mainly in postmenopausal women. With the rareness of lipoma occurrence, and the devastating consequences of an improper diagnosis of the benign versus malignant tumor type, the preoperative diagnosis of a lipoma in premenopausal women would be difficult and postoperative surgical confirmation should be necessary. Furthermore, a malignant liposarcoma should be completely ruled out.¹

In the case presented in this report, the patient did not have any symptoms of a uterine tumor, and the findings of ultrasonography and of MRI preoperatively indicated a benign lipoma of the uterus. However, because the coexisting ovarian tumor had a significant risk for a rupture or torsion to occur, and because of a decisive pathological confirmation of a benign uterine tumor, we made the decision to conduct a proactive surgical procedure for this particular case. Because it is less invasive than a laparotomy, we chose to perform a laparoscopy-assisted vaginal hysterectomy and bilateral salpingo-oophorectomy, which was successful, and no recurrence has been noted.

In conclusion, the physician should be aware that a uterine lipoma is an extraordinarily rare tumor and as such it is sometimes

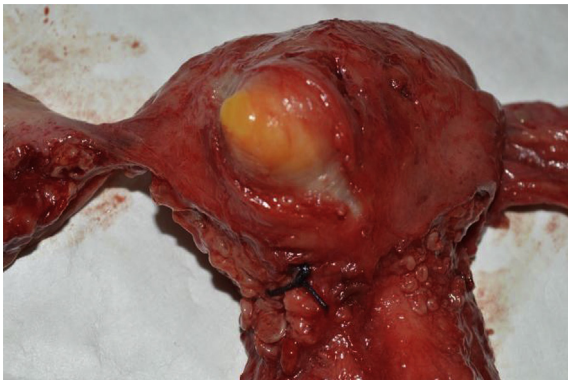

Figure 3. Gross findings of the surgically resected uterus (posterior uterine view). A yellowish 25-mm tumor is present within the uterine posterior wall.

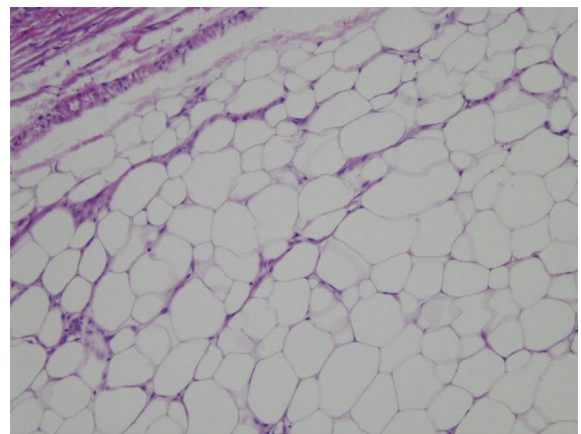


Figure 4. Microscopic image of the uterine tumor (H&E staining; original magnification $\times 100$). The pure lipoma, consisting only of mature adipocytes (with a lack of spindle-shaped smooth muscle cells or fibrous tissue) is clearly circumscribed (upper left) from the normal uterine myometrium. H&E = hematoxylin and eosin.

very difficult to diagnose. MRI imaging can be helpful for a preoperative diagnosis, but good histopathological confirmation is necessary. Conservative management can be chosen for the asymptomatic patients. If surgical treatment is decided upon, minimally invasive laparoscopic surgery can be a better choice.

References

1. Mignogna C, Di Spiezio Sardo A, Spinelli M, et al. A case of pure uterine lipoma: immunohistochemical and ultrastructural focus. *Arch Gynecol Obstet.* 2009;280:1071–1074.
2. Fernandes H, Naik CN, Swethadri GK, Bangera I, Miranda D. Pure lipoma of the uterus: a rare case report. *Indian J Pathol Microbiol.* 2007;50:800–801.
3. Wijesuriya SM, Gandhi S. A pure uterine lipoma: a rare, benign entity. *BMJ Case Rep.* 2011. <http://dx.doi.org/10.1136/bcr.07.2011.4425>.
4. McDonald AG, Dal Cin P, Ganguly A, et al. Liposarcoma arising in uterine lipoleiomyoma: a report of 3 cases and review of the literature. *Am J Surg Pathol.* 2011;35:221–227.
5. Vilallonga R, Garcia A, Castellvi J, Fort JM, Armengol M, Ramon y Cajal S. Lipoma of the uterine corpus: exceptional eventuality combined with an ovarian thecoma. *Case Rep Med.* 2009. <http://dx.doi.org/10.1155/2009/340603>.
6. Chu CY, Tang YK, Chan TS, Wan YH, Fung KH. Diagnostic challenge of lipomatous uterine tumors in three patients. *World J Radiol.* 2012;4:58–62.
7. Serafini G, Martinoli C, Quadri P, Specca S, Crespi G, Venturino E. Lipomatous tumors of the uterus: ultrasonographic findings in 11 cases. *J Ultrasound Med.* 1996;15. quiz 195–199.

Serika Kanao*, Takashi Miyatake, Asuka Tanaka, Masumi Takeda, Ai Miyoshi, Mayuko Mimura, Masaaki Nagamatsu, Takeshi Yokoi
 Department of Obstetrics and Gynecology, Sensyu Regional Medical Center for Women's and Children's Health, Kaizuka City Hospital, Osaka, Japan

* Corresponding author. Department of Obstetrics and Gynecology, Kaizuka City Hospital, 3-10-20 Hori Kaizuka, Osaka, 597-0015, Japan.

E-mail address: celica1104@gmail.com (S. Kanao).

15 December 2015
 Available online 14 June 2016