

A graft-free scleral sleeve technique of Ahmed Glaucoma Valve implantation in refractory glaucoma- Rising to the challenge of COVID-19 pandemic

Richa Gupta

We describe a case of 63-year-old woman, with primary open-angle glaucoma (POAG) who presented to us in the COVID era with uncontrolled intraocular pressure (IOP) on maximum medical therapy (MMT) in the right eye (OD), previously operated twice for trabeculectomy in (OD), and once in left eye (OS). A modified graft-free surgical technique of inserting the Ahmed Glaucoma valve (AGV) tube through a scleral sleeve was employed. Visual acuity and IOP remained stable during 6-month follow-up period.

Key words: Ahmed glaucoma valve, COVID-19 pandemic, glaucoma drainage device, refractory glaucoma

Though glaucoma drainage devices (GDDs) remain the mainstay of management in eyes with refractory glaucoma, its implantation in the prevailing COVID-19 pandemic has become a challenge in the light of potential transmission of SARS-CoV-2^[1] through the donor scleral graft, used to cover the AGV tube.

We showcase a modified technique of graft-free insertion of the AGV tube (AGV; model P7, New World Medical Inc, Rancho Cucamonga, CA, USA) through an intra-scleral sleeve.

Case Report

A 63-year-old woman presented to our institute with painful diminution of vision in right eye (OD) since 1 month. Previous surgical history included cataract surgery with intra-ocular lens (IOL) implantation in OD, trabeculectomy done twice in OD and once in OS. The corrected distance visual acuity (CDVA) was 20/200 and 20/80 for OD and OS respectively, and the IOP was 40 mm Hg in OD and 11 mm Hg in OS on topical

beta-blocker, alpha-agonist, prostaglandin analog and topical and oral carbonic anhydrase inhibitor. Examination of OD showed hazy cornea with epithelial edema, IOL in place, failed flat blebs and superior 200 degree of peri-limbal fibrosis. Gonioscopy revealed scarred stomas with open angles. Near total cupping of the optic disc was noted on dilated fundus examination. A high IOP on MMT, with two failed trabeculectomies and an advanced glaucomatous cupping prompted us to urgently plan an AGV implantation, but to eliminate the risk of potential transmission, an intra-scleral route was adopted which was graft-free.

Surgical technique

Following peribulbar anesthesia and corneal traction suture, a fornix-based conjunctival flap was created in superior temporal quadrant (STQ). Scleral thinning was noted in the area of the planned scleral tunnel, so this site was abandoned. Conjunctiva and Tenon's capsule were dissected in the supero-nasal quadrant (SNQ).

After priming, AGV plate was placed in the sub-Tenon's pocket and anchored to the sclera with 9-0 nylon (Aurodon, Aurodon, Madurai, India) sutures 9 mm behind the limbus. A 3 × 5 mm lamellar scleral tunnel, with its proximal end at 3.5 mm from limbus was created with crescent blade, through which the AGV tube was passed [Fig. 1a]. It was trimmed, bevel up and inserted into the sulcus through a 23 gauge port, 2.5 mm behind limbus in SNQ [Fig. 1b]. The uncovered 1 mm of the tube was fixed to the sclera with 9-0 nylon sutures. Conjunctival flap was then closed using 8-0 polyglactin sutures (Vicryl, Johnson and Johnson, Aurangabad, India).

Postoperatively, the patient received cycloplegic drops and intensive steroids, tapered over next 8 weeks. First day post-operative IOP was 10 mmHg. AGV was well positioned with its tube well covered with conjunctiva [Fig. 2a] and the end visible in the sulcus in SNQ [Fig. 2b]. Patient achieved useful CDVA of 20/60 at the final follow-up of 6 months. IOP remained stable with no encountered hypertensive phase.

Discussion

Trans-conjunctival erosion of GDD tubes can lead to devastating complications such as hypotony, phthisis and endophthalmitis. Most often, a scleral or pericardial patch graft is used to cover the tube to reduce these risks.^[2] Severe acute respiratory syndrome coronavirus 2 (SARS-CoV-2) infection associated respiratory disease- COVID-19 (2019-nCoV) has not only tremendously affected the world, but also has seen dramatic reduction in the number of cornea donors.^[3]

This is an open access journal, and articles are distributed under the terms of the Creative Commons Attribution-NonCommercial-ShareAlike 4.0 License, which allows others to remix, tweak, and build upon the work non-commercially, as long as appropriate credit is given and the new creations are licensed under the identical terms.

For reprints contact: WKHLRPMedknow_reprints@wolterskluwer.com

Cite this article as: Gupta R. A graft-free scleral sleeve technique of Ahmed Glaucoma Valve implantation in refractory glaucoma- Rising to the challenge of COVID-19 pandemic. Indian J Ophthalmol 2021;69:1623-5.

Access this article online	
Quick Response Code:	Website: www.ijjo.in
	DOI: 10.4103/ijjo.IJO_3654_20

C L Gupta Eye Institute, Ram Ganga Vihar Phase 2 (Ext.), Moradabad, Uttar Pradesh, India

Correspondence to: Dr. Richa Gupta, C L Gupta Eye Institute, Ram Ganga Vihar Phase 2 (Ext.), Moradabad - 244 001, Uttar Pradesh, India. E-mail: richa_kmc@rediffmail.com

Received: 10-Dec-2020

Revision: 21-Jan-2021

Accepted: 13-Feb-2021

Published: 21-May-2021

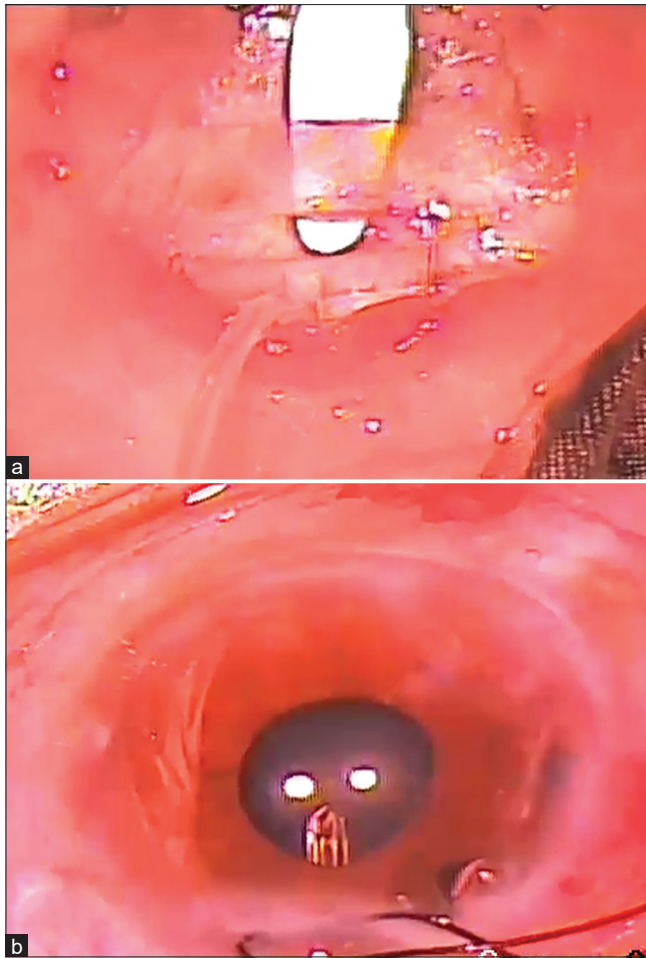


Figure 1: (a) Lamellar scleral tunnel created with crescent blade for passage of AGV tube. (b) Insertion of the tube in sulcus

Furthermore, although there is no evidence to substantiate that harvested grafts from COVID-19 patients can lead to a systemic infection, a potential risk exists due to the presence of ACE2 and TMPRSS2 expressions in cornea.^[1]

In these unprecedented times, it is a challenge to harvest sclera for tube coverage during the conventional AGV implantation. There are few published reports in which authors have explored the safety, procedural time and cost benefit of graft free AGV implantation, and have described various techniques for the same. In their retrospective cohort study, Gdih *et al.* found a success rate of 83% in 84 eyes implanted with graft-free AGV and 2.4% and 0% of conjunctival and scleral erosion by 2 years.^[4] Kalamkar *et al.* have described use of intra-scleral method for tube fixation, along with a limbal based partial thickness scleral flap (5 mm × 3 mm) at limbus to cover the tube before it entered the anterior chamber.^[5] Comparative series of graft free scleral tunnel versus scleral patch graft by Rivera *et al.*^[6] and Pakravan *et al.*^[7] reported tube erosions in the later, but not in former group of patients. Alternate techniques like use of 6-mm graft free scleral tunnel,^[8] needle-generated scleral tunnel, without a tube-covering patch^[9] and long scleral flap, augmented with Tenon advancement and duplication^[10] have also been described in literature.

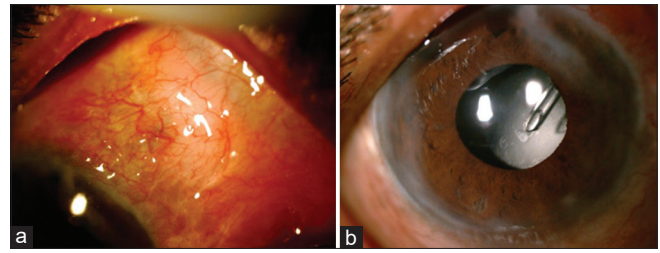


Figure 2: (a) Tube well covered with conjunctiva at 6 months. (b) Clear cornea with AGV tube visible in SNQ sulcus

Our report describes a modified graft-free implantation of AGV tube through a scleral tunnel, to avoid application of a scleral allograft patch.

Conclusion

We propose the technique of AGV tube implantation through a graft free, scleral sleeve as a simple, effective and time efficient modification, keeping in mind the risks of transmission of COVID-19 with the conventional technique of using a scleral patch graft. It is a safer option in complex glaucomas needing GDDs, without increasing tube related complications and compromising on the surgical outcome.

Declaration of patient consent

The authors certify that they have obtained all appropriate patient consent forms. In the form the patient(s) has/have given his/her/their consent for his/her/their images and other clinical information to be reported in the journal. The patients understand that their names and initials will not be published and due efforts will be made to conceal their identity, but anonymity cannot be guaranteed.

Financial support and sponsorship

Nil.

Conflicts of interest

There are no conflicts of interest.

References

- Ma D, Chen CB, Jhanji V, Xu C, Yuan XL, Liang JJ, *et al.* Expression of SARS-CoV-2 receptor ACE2 and TMPRSS2 in human primary conjunctival and pterygium cell lines and in mouse cornea. *Eye (Lond)* 2020;34:1212-9.
- Gedde SJ, Scott IU, Tabandeh H, Luu KK, Budenz DL, Greenfield DS, *et al.* Late endophthalmitis associated with glaucoma drainage implants. *Ophthalmology* 2001;108:1323-7.
- Toro M, Choragiewicz T, Posarelli C, Figus M, Rejdak R; On Behalf of European COVID-19 Cataract Group (#EUROCOVCAT). Early impact of COVID-19 outbreak on the availability of cornea donors: Warnings and recommendations. *Clin Ophthalmol* 2020;14:2879-82.
- Gdih G, Jiang K. Graft-free Ahmed valve implantation through a 6 mm scleral tunnel. *Can J Ophthalmol* 2017;52:85-91.
- Kalamkar C, Radke N, Mukherjee A, Radke S. A new surgical technique of intra-scleral tube fixation in Ahmed Glaucoma Valve implantation: 'Scleral Sleeve Method'. *Saudi J Ophthalmol* 2017;31:234-7.
- Rivera J, Leuenberger EU, Yap-Veloso MI. A retrospective review of autologous scleral flap versus donor scleral graft. *Philipp J Ophthalmol* 2008;33:17-21.

7. Pakravan M, Hatami M, Esfandiari H, Yazdani S, Doozandeh A, Samaeili A, *et al.* Ahmed glaucoma valve implantation: Graft-free short tunnel small flap versus scleral patch graft after 1-year follow-up: A randomized clinical trial. *Ophthalmol Glaucoma* 2018;1:206-12.
 8. Lim R, Karydis A, Taylor S. A scleral tunnel graft-free technique in Ahmed glaucoma valve (AGV) implantation. *Investig Ophthalmol Vis Sci* 2016;57:5617.
 9. Albis-Donado O, Gil-Carrasco F, Romero-Quijada R, Thomas R. Evaluation of Ahmed glaucoma valve implantation through a needle-generated scleral tunnel in Mexican children with glaucoma. *Indian J Ophthalmol* 2010;58:365-73.
 10. Totuk G, Kabadayi K, Colakoglu A, Ekizoglu N, Aykan U. A novel surgical technique for prevention of Ahmed glaucoma valve tube exposure: Long scleral flap augmented with Tenon advancement and duplication. *BMC Ophthalmol* 2018;18:226.
-