



# Duplicate Left-Sided Vagus Nerve: Intraoperative Imaging, Management, and Placement

Nicholas Zacharewski<sup>1</sup> Brendan D. Killory<sup>2</sup>

<sup>1</sup>Department of Neurosurgery, Hartford Hospital, Hartford, Connecticut, United States

<sup>2</sup>Department of Neuroscience, Trinity College, Hartford, Connecticut, United States

**Address for correspondence** Nicholas Zacharewski, Brendan Killory, MD, Hartford Healthcare Medical Group Department of Neurosurgery, 85 Seymour St Suite 1003, Hartford, CT 06117, United States (e-mail: brendan.killory@hhchealth.org).

J Neurol Surg Rep 2023;84:e59–e60.

## Abstract

**Introduction** Duplicate cranial nerves are fundamentally rare anatomical variants. Few case reports have documented cranial nerve duplication. One previous case report has reported a vagus nerve with a smaller secondary accessory nerve component. We present the first reported case of duplicate vagus nerves identical in size and thickness with otolaryngological diagnostic confirmation.

**Case Description** A 25-year-old woman with seizures refractory to medical management decided to undergo placement of a vagus nerve stimulator. During carotid sheath microdissection, two parallel nerve tracts were identified. The two nerves were identical in size and width. Proximal dissection confirmed that the two nerves were independent of one another and neither was a branching segment. To confirm duplicate vagus nerves, otolaryngology was consulted intraoperatively and the duplicate nerves were verified. The vagus nerve stimulator was placed in typical fashion around the medial nerve.

**Conclusion** This is the first reported case of duplicate vagus nerves identical in size and with confirmation by otolaryngology. The authors would like to highlight the operative management of the vagus nerve stimulator placement as well as integrity of the diagnostic conclusions based on size, further dissection, and specialist consultation.

## Keywords

- ▶ vagus nerve
- ▶ duplicate
- ▶ seizure
- ▶ vagus nerve stimulator
- ▶ microdissection

## Introduction

The vagus nerve is the 10th cranial nerve that originates at the medulla and innervates the laryngeal aspect of the neck, thorax, and abdomen. In refractory epileptic management, the vagus nerve can be stimulated through a surgically introduced vagus nerve stimulation (VNS; LivaNova, United States) to reduce seizure frequency in patients. During this procedure, the vagus nerve is identified after opening the carotid sheath. During VNS placement surgery, proper anatomical landmarks, knowledge, and identification are crucial

for limiting complications and increasing the likelihood for improvement in patient outcome. This case will discuss an exceedingly rare variant in vagus nerve anatomy as well as the intraoperative management of the patient and seizure treatment outcomes.

## Case Presentation

A 25-year-old woman presented with a 16-year history of primarily absence seizures with rare occurrence of

received  
January 13, 2022  
accepted  
August 12, 2022

DOI <https://doi.org/10.1055/s-0043-1768713>.  
ISSN 2193-6358.

© 2023. The Author(s).

This is an open access article published by Thieme under the terms of the Creative Commons Attribution-NonDerivative-NonCommercial-License, permitting copying and reproduction so long as the original work is given appropriate credit. Contents may not be used for commercial purposes, or adapted, remixed, transformed or built upon. (<https://creativecommons.org/licenses/by-nc-nd/4.0/>)

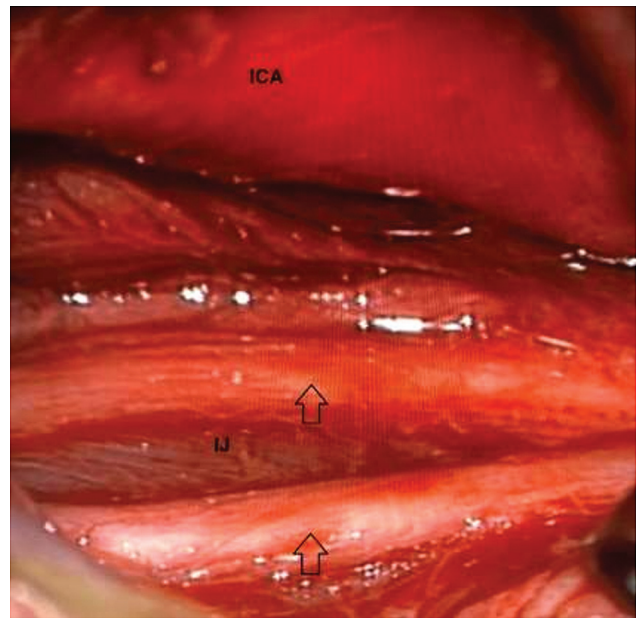
Georg Thieme Verlag KG, Rüdigerstraße 14, 70469 Stuttgart, Germany

generalized tonic-clonic seizures. The patient's seizures were refractory to medical management with four medications and agreed to surgery for VNS. Two 1.5-inch incisions were planned, just below the angle of the mandible in the left neck and just above the axilla in the left chest. The first aspect of the VNS placement in the chest was unremarkable. In the neck, a combination of sharp and blunt dissection was used to create an avascular plane anterior to the sternocleidomastoid down to the carotid sheath, which was opened between the internal carotid artery and internal jugular vein. Opening of the sheath with microdissection was used to sharply free 5 cm of the nerve circumferentially. There were duplicate vagal nerves of the same caliber running parallel to each other. Upon proximal dissection, the nerves were determined to be independent and not branches of each other. We obtained an intraoperative ENT consultation who agreed with the presence of two vagal nerves. We consulted with the VNS engineers, who recommended we choose a single nerve to stimulate rather than wrapping around both. We chose the deeper/more medial nerve. The electrode was tunneled between the two incisions and then all three anchors were secured around the nerve in the correct orientation. The lead was secured distally in a gentle loop and attached to the generator in the chest. The patient is currently 8 months post-VNS placement, tolerating the device well, and working with a neurologist to optimize settings for the stimulator. She has reported throat tightening with adjustments, which is typical with VNS. Her seizure frequency has not changed significantly since the device placement.

## Discussion

The documentation of a duplicate vagus nerve is remarkable. A review of the literature has reported numerous cases of 6th and 11th cranial nerve anomalies; however, there remains only one other documentation of a 10th cranial nerve duplication in a 2019 case report.<sup>1-4</sup>

The only other duplicate vagus nerve documentation discussed two nerves in an accessory setting unequal in size to each other.<sup>5</sup> In our case, the identical nerves needed to be differentiated for VNS placement. The identification was complicated by the two nerves being of the same diameter and thickness, with one more medial and another more lateral in the carotid sheath. The two traveled in parallel running the length of the visible sheath (→Fig. 1) and proximal dissection did not identify a branching point. We consulted the VNS biomedical engineers, who recommended selecting either nerve for stimulation rather than attempting to stimulate both. Unfortunately, our patient's seizure frequency has not significantly improved since surgery, but she is working with her neurologist to optimize her device setting. She has reported the sensation of throat tightening with adjustments to the stimulation current, which is typical with VNS.



**Fig. 1 Intraoperative view.** Microsurgical view shows surgical corridor into carotid sheath. Duplicate nerves labeled with arrows. ICA, internal carotid artery; IJ, internal jugular vein.

## Conclusion

This case is of a duplicate vagus nerve in a 25-year-old woman and the first true duplicate vagus nerve reported in the literature. The authors would also like to highlight the intraoperative management of the nervous anomaly and our patient's excellent early clinical outcome from surgery. Longer follow-up will be required to determine if stimulating a single duplicate vagal nerve will significantly improve her epilepsy.

### Conflict of Interest

None declared.

## References

- 1 Wysiadecki G, Polguy M, Topol M. An unusual variant of the abducens nerve duplication with two nerve trunks merging within the orbit: a case report with comments on developmental background. *Surg Radiol Anat* 2016;38(05):625–629
- 2 Ozveren MF, Sam B, Akdemir I, Alkan A, Tekdemir I, Deda H. Duplication of the abducens nerve at the petroclival region: an anatomic study. *Neurosurgery* 2003;52(03):645–652, discussion 651–652
- 3 Papagianni E, Kosmidou P, Fergadaki S, Pallantzias A, Skandalakis P, Filippou D. Spinal accessory nerve duplication: a case report and literature review. *Case Rep Otolaryngol* 2018; 2018:1027831
- 4 Tubbs RS, Ajayi OO, Fries FN, Spinner RJ, Oskouian RJ. Variations of the accessory nerve: anatomical study including previously undocumented findings-expanding our misunderstanding of this nerve. *Br J Neurosurg* 2017;31(01):113–115
- 5 Labuschagne JJ, Hammer N. Duplicated vagus nerve in adolescence: case report and review of literature. *World Neurosurg* 2019;131:180–185