












Cite this article as: Bonalumi G, Giambuzzi I, Barbone A, Ranieri C, Cavallotti L, Trabattoni P *et al.* A call to action becomes practice: cardiac and vascular surgery during the COVID-19 pandemic based on the Lombardy emergency guidelines. *Eur J Cardiothorac Surg* 2020;58:319–27.

# A call to action becomes practice: cardiac and vascular surgery during the COVID-19 pandemic based on the Lombardy emergency guidelines

Giorgia Bonalumi <sup>a,\*†</sup>, Ilaria Giambuzzi <sup>a,b,†</sup>, Alessandro Barbone <sup>c</sup>, Camilla Ranieri<sup>d</sup>, Laura Cavallotti<sup>a</sup>, Piero Trabattoni<sup>a</sup>, Moreno Naliato <sup>a</sup>, Gianluca Polvani<sup>a,b</sup>, Lucia Torracca<sup>c</sup>, Stefano Pelenghi <sup>e</sup>, Franco Ragni<sup>f</sup>, Claudio Francesco Russo <sup>g</sup>, Francisco Guerra<sup>h</sup>, Santi Trimarchi <sup>b,i</sup>, Efrem Civilini <sup>c</sup>, Federico Romani<sup>g</sup>, Raffaello Bellosta <sup>j</sup>, Sergio Losa<sup>h</sup>, Maurizio Roberto <sup>a,†</sup> and Francesco Alamanni <sup>a,b,†</sup>, on behalf of the Hub&Spoke Study Investigators

<sup>a</sup> Department of Cardiovascular Surgery, Centro Cardiologico Monzino-IRCCS, Milan, Italy

<sup>b</sup> DISCO University of Milan, Milan, Italy

<sup>c</sup> Department of Cardiovascular Surgery, Humanitas Clinical and Research Center-IRCCS, Rozzano, Milan, Italy

<sup>d</sup> Health Care Management, Centro Cardiologico Monzino-IRCCS, Milan, Italy

<sup>e</sup> Division of Cardiovascular Surgery, Fondazione-IRCCS Policlinico San Matteo Pavia, Pavia, Italy

<sup>f</sup> Vascular Surgery Unit, Fondazione-IRCCS Policlinico San Matteo Pavia, Pavia, Italy

<sup>g</sup> Cardiovascular Surgery Unit, ASST Grande Ospedale Metropolitano Niguarda, Milan, Italy

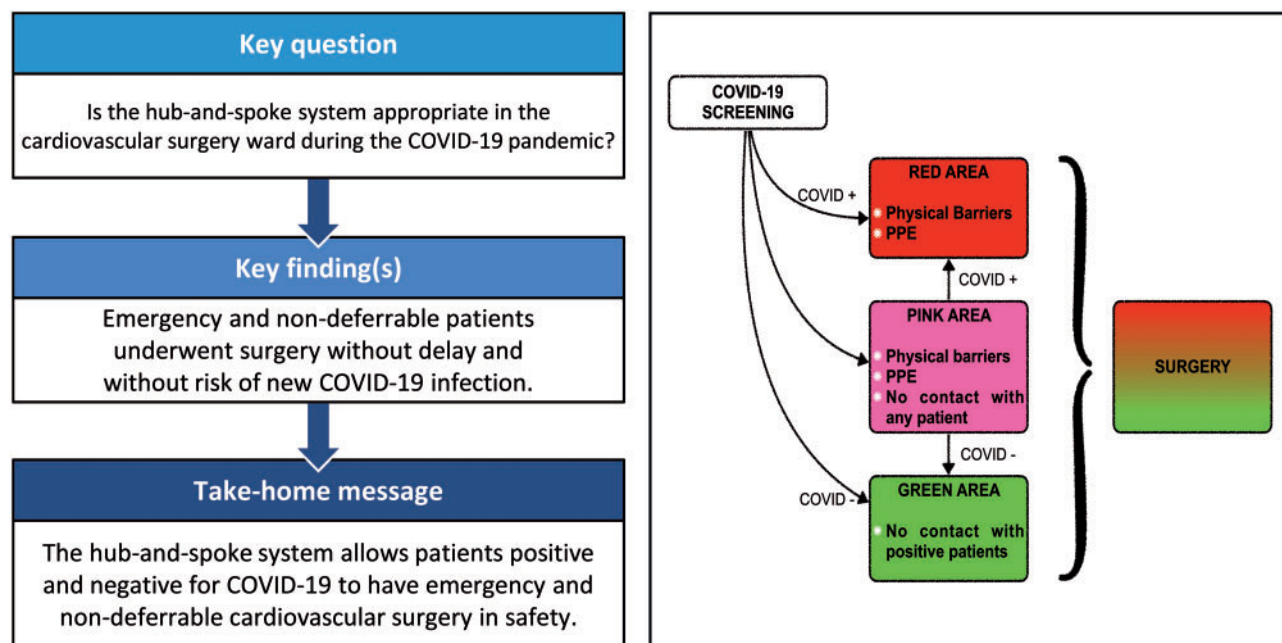
<sup>h</sup> Cardiovascular Surgery, IRCCS Sesto San Giovanni Multimedica, Sesto San Giovanni, Milan, Italy

<sup>i</sup> Vascular Surgery Department, IRCCS Ca' Granda Ospedale Maggiore Policlinico, University of Milan, Milan, Italy

<sup>j</sup> Vascular Surgery Unit, Cardiovascular Surgery Department, Poliambulanza Foundation Hospital, Brescia, Italy

\* Corresponding author. Department of Cardiovascular Surgery, Centro Cardiologico Monzino-IRCCS, Via Carlo Parea 4, 20100 Milan, Italy. Tel: +39-3383989007; e-mail: giorgia.bonalumi@cardiologicomonzino.it (G. Bonalumi).

Received 22 April 2020; received in revised form 28 April 2020; accepted 5 May 2020



<sup>†</sup>The first two authors contributed equally to this work.

<sup>‡</sup>The last two authors contributed equally to this work.

## Abstract

**OBJECTIVES:** During the Severe Acute Respiratory Syndrome–Coronavirus-2 (SARS-CoV-2) pandemic, Northern Italy had to completely reorganize its hospital activity. In Lombardy, the hub-and-spoke system was introduced to guarantee emergency and urgent cardiovascular surgery, whereas most hospitals were dedicated to patients with coronavirus disease 2019 (COVID-19). The aim of this study was to analyse the results of the hub-and-spoke organization system.

**METHODS:** Centro Cardiologico Monzino (Monzino) became one of the four hubs for cardiovascular surgery, with a total of eight spokes. SARS-CoV-2 screening became mandatory for all patients. New flow charts were designed to allow separated pathways based on infection status. A reorganization of spaces guaranteed COVID-19-free and COVID-19-dedicated areas. Patients were also classified into groups according to their pathological and clinical status: emergency, urgent and non-deferrable (ND).

**RESULTS:** A total of 70 patients were referred to the Monzino hub-and-spoke network. We performed 41 operations, 28 (68.3%) of which were emergency/urgent and 13 of which were ND. The screening allowed the identification of COVID-19 (three patients, 7.3%) and non-COVID-19 patients (38 patients, 92.7%). The newly designed and shared protocols guaranteed that the cardiac patients would be divided into emergency, urgent and ND groups. The involvement of the telematic management heart team allowed constant updates and clinical discussions.

**CONCLUSIONS:** The hub-and-spoke organization system efficiently safeguards access to heart and vascular surgical services for patients who require ND, urgent and emergency treatment. Further reorganization will be needed at the end of this pandemic when elective cases will again be scheduled, with a daily increase in the number of operations.

**Keywords:** Cardiovascular surgery • Coronavirus disease 2019 • Hub-and-spoke

### ABBREVIATIONS

COVID-19	Coronavirus disease 2019
CT	Computed tomography
ER	Emergency room
ICU	Intensive care unit
LVAD	Left ventricular assist device
ND	Non-deferrable
THT	Telematic heart team
TTE	Transthoracic echocardiogram

## INTRODUCTION

In December 2019, coronavirus disease 2019 (COVID-19) was first reported in Wuhan, China [1]. This disease was caused by a new coronavirus, called Severe Acute Respiratory Syndrome–Coronavirus-2 (SARS-CoV-2) [2]. In contrast to past epidemics, which took years to spread around the world, the new virus reached Europe in a few months [3], with the first official case identified in Northern Italy on February 18 [4] and leading to the Italian outbreak. COVID-19 is a systemic disease [5], presenting with interstitial pneumonia (computed tomographic scan is the gold standard for diagnosis) [6–8], but it can also have a paucisymptomatic course [9]. The rate of newly infected patients increased daily on a logarithmic scale, especially in Lombardy, the most populated region in Italy (about 10 million inhabitants), forcing the Italian government to take extraordinary measures to contain the infection. Quarantine and the closure of non-essential activities were enforced.

The National Health Care System, in accordance with Italy's universal welfare principles, was put under extreme pressure. Almost every hospital was completely reorganized in order to meet the needs of the COVID-19 patients. New areas and new intensive care units (ICUs) dedicated to patients with COVID-19

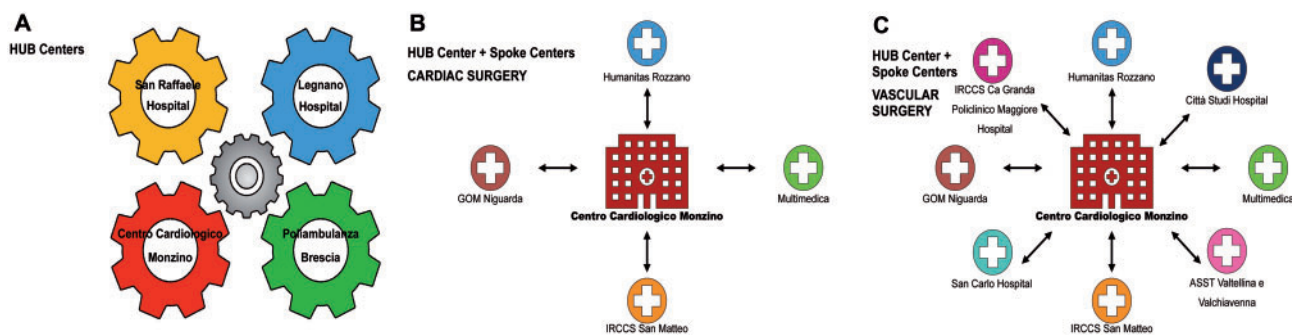
were set up. As a result, all elective activities were postponed or cancelled.

A dedicated pathway had to be created to guarantee access to the best possible health care treatment, i.e. for emergency, urgent or non-deferrable (ND) cases. To ensure such a system, the Health Care Lombardy Regional System promoted the hub-and-spoke organization system on March 8 [10]. This system had been used successfully in the past [11–13]. On March 8, 7375 Italian patients were infected with SARS-CoV-19, 650 of whom were in critical condition. In Lombardy, there were 3372 and 399 cases, respectively [14]. In this scenario, heart and vascular surgical activities had to be reorganized. Four reference and enrolment hub hospitals were identified. Other hospitals, the spokes, which treating almost entirely COVID-19 patients, became peripheral referral centres. Hubs had to identify different dedicated pathways for COVID-19-positive and -negative patients. The main tasks of the hubs were to admit and treat patients (24/7) coming from the cardiovascular spokes [15]. Our goal was to analyse our flow charts and examine the pathways designed for COVID-19-positive and -negative patients.

## MATERIALS AND METHODS

The four adult cardiac and vascular surgery hospitals identified as hubs were the Centro Cardiologico Monzino (Monzino), San Raffaele Hospital, Legnano Hospital and Poliambulanza Brescia. Each hub had its own spokes for cardiac and vascular surgery [16] (Fig. 1). San Donato Hospital was the paediatric cardiac surgery hub.

The surgical pathways had three simultaneous surgical teams on call at all times (two independent cardiac teams and one vascular team). Three different pathways were created: one for COVID-19-negative patients (green path), one for patients waiting for the screening result (pink path) and one for COVID-19-positive patients (red path). The postoperative ICU was split into



**Figure 1:** Diagram of the hub-and-spoke system. **(A)** Interconnections between cardiovascular surgery hubs that cooperate and exchange information during weekly briefings. **(B)** Interconnections between a cardiac surgery hub and its spokes. **(C)** Interconnections between vascular surgery hub and its spokes.

two areas by a new dividing wall to create physical separation between COVID-19-positive and -negative patients. All procedures were carried out according to shared Italian Society of Cardiac Surgery Recommendations [17].

### Hub-and-spoke and regional coordination

The first step was to coordinate the different hubs. To ensure sharing of the workload, resources and surgical priorities, a weekly briefing was held among all the hubs. The goal was to obtain an update on the number of ICU beds available among the hubs, because the access rate to each area was unprecedented and unpredictable (Monzino, up to 11; San Raffaele, up to 20; Legnano, up to eight; and Poliambulanza Brescia, up to six) and on the number of operations to be performed and to share ongoing strategies and surgical indications.

### Surgical priorities and screening

The second step involved setting up a new surgical waiting list that was shared between the hub and its own spokes. In the pre-COVID-19 era, each hospital scheduled its own referred patients using an institutional waiting list. This waiting list always took into account the recommendations of the National Health Care System: high priority patients, i.e. those with rapidly progressing diseases, were in class A (mandatory hospitalization within 30 days), whereas class B–D patients had less severe clinical presentations, were without priority and were on 60-day, 180-day and 12-month waiting lists, respectively [18]. At present, in this war-like reality, only class A cases, defined as ND, were included on a new hub-and-spoke shared waiting list and were treated independently from the cases deemed urgent and emergency. The overall criteria listed in Table 1 were defined by a task force of expert cardiovascular surgeons from all hub-and-spoke networks and were in agreement with EuroSCORE emergency/urgent definitions and in agreement with Italian Health Organization recommendations [19].

Each urgent or scheduled patient had a mandatory screening for SARS-CoV-2, which always included a chest computed tomography (CT) scan, nasal swab, corporal temperature monitoring and blood tests. The clinical discussion and daily surgical programme for ND patients included all members of the telematic heart team (THT), one goal being to allow surgeons from the spokes to perform surgery on their own referred patients in the hub. Daily morning briefings were held internally at the Monzino hospital to

monitor every aspect of all in-patients (COVID-19 status, number of available beds) and to share news from the Health Care Lombardy Regional System and the national government.

### Pathway organization

Each new patient was considered COVID-19-positive and kept isolated in a dedicated hospital area called the 'pink area' while waiting for the screening result. If the screening result was negative (negative medical history for suspected contact, absence of fever or interstitial pneumonia on a chest CT scan, negative results from the nasal swab), the patient was transferred to the 'green area' (COVID-19-free area). If the test results were positive (chest CT scan indicative of interstitial pneumonia and/or positive results from the nasal swab), the patient was transferred to a dedicated zone called the 'red area', a separate zone with physical barriers and heavy use of personal protective equipment to protect working personnel, where only patients with COVID-19 were hospitalized.

### Emergency and urgency

In case of emergency or urgency (Fig. 2), the on-call surgeon could choose between two strategies: either wheel the patient rapidly to the operating room or keep the patient in the emergency room (ER) for further assessment. In both cases, the nasal swab and the CT scan were performed in the shortest possible time. Thanks to our internal laboratory, the swabs results were obtained within 3 h or before the end of the operation in the case of an emergency procedure.

In cases of emergency surgery, the patient was considered and treated as positive for SARS-CoV-2 by the health care staff, who wore personal protective equipment, until screening results were available. At the end of the procedure, depending on the screening result, the patient was transferred to the appropriate dedicated ICU area.

In cases of urgent surgery, the patient was screened and held in a pink area (in the ER), isolated from other patients until the results were available. If the results of the screening test were positive, the surgical indication had to be confirmed by the THT and the procedure was possibly postponed if clinical conditions allowed.

### Non-deferrable patients

A different flow chart was designed for ND cases (Fig. 3). Cases were discussed in the THT. If the patient presented from home,

**Table 1:** Definitions of emergency, urgent and non-deferrable cardiac and vascular cases in the coronavirus disease 2019 era

Pathology	Indications
Aortic disease	<ul style="list-style-type: none"> <li>• Acute aortic dissection/intramural haematoma (exclusion criteria: age &gt;80 years; coma; stroke; visceral organ malperfusion)</li> <li>• Ascending aortic aneurysm <math>\geq 60</math> mm</li> <li>• Ascending aortic aneurysm 55–60 mm in Marfan syndrome, yearly growth &gt;5 mm, uncontrolled arterial hypertension</li> </ul>
Severe aortic stenosis	<ul style="list-style-type: none"> <li>• Symptomatic for syncope, angina, NYHA functional class IIIb–IV</li> </ul>
Severe aortic regurgitation	<ul style="list-style-type: none"> <li>• Acute pulmonary oedema with left ventricular dysfunction or haemodynamic instability</li> </ul>
Severe mitral stenosis	<ul style="list-style-type: none"> <li>• Haemodynamic instability or acute pulmonary oedema</li> </ul>
Acute mitral regurgitation	<ul style="list-style-type: none"> <li>• Papillary muscle or chordal rupture determining acute pulmonary oedema</li> </ul>
Cardiac ischaemic disease	<ul style="list-style-type: none"> <li>• Cardiac rupture or acute interventricular defect</li> <li>• Untreatable unstable angina</li> <li>• Left main coronary artery stenosis &gt;70%</li> <li>• Subocclusive stenosis of left main coronary artery or anterior interventricular coronary artery</li> </ul>
Acute endocarditis	<ul style="list-style-type: none"> <li>• Emergency (guidelines criteria)</li> <li>• Urgent (guidelines criteria)</li> </ul>
Prosthesis dysfunctions	<ul style="list-style-type: none"> <li>• Heart failure</li> <li>• Urgent if non-dischargeable</li> </ul>
Masses	<ul style="list-style-type: none"> <li>• Left atrial myxoma</li> <li>• Other masses with high embolic risk</li> </ul>
Acute limb ischaemia	
Ruptured aneurysm	
Chronic limb ischaemia	<ul style="list-style-type: none"> <li>• Leriche III–IV grade</li> </ul>
Thoracic and thoraco-abdominal aorta	<ul style="list-style-type: none"> <li>• Diameter &gt;7 cm</li> <li>• Rapid growth (&gt;1 cm in 6 months)</li> <li>• Lesion instability at CT scan (blister, fissuring thrombus)</li> </ul>
Abdominal aorta	<ul style="list-style-type: none"> <li>• Diameter &gt;6.5 cm</li> <li>• Rapid growth (&gt;1 cm in 6 months)</li> <li>• Lesion instability on CT scan (blister, fissuring thrombus)</li> </ul>
Carotid stenosis	<ul style="list-style-type: none"> <li>• Symptomatic</li> <li>• Stenosis &gt;90%, monolateral and asymptomatic</li> <li>• Ulcerated plaque</li> </ul>

CT: computed tomography; NYHA: New York Heart Association.

the screening was performed upon arrival and the patient was kept in the pink waiting area. Once the screening result was available, non-COVID-19 patients were transferred to the green area, whereas patients with COVID-19 were evaluated according to clinical status: Rehospitalization was foreseen after the quarantine period with a new COVID-19 screening or, in the case of a poor clinical condition, the patient was transferred to a COVID-19 centre for further care.

If the ND patient was referred from another hospital (a spoke), a first COVID screening was performed before arranging transfer: a second screening was performed upon arrival in the pink area. Negative patients were moved to the green area to wait for a surgical procedure. Patients positive for COVID-19 were transferred back to the spoke/COVID-19 centre for therapy.

The THR discussion, with the reasons for acceptance or refusal of the surgical indications, was recorded in a dedicated database that was updated by the hub staff.

## RESULTS

A total of 70 patients have been referred to the hub-and-spoke system as of this writing (April 18) (Figure 4). The screening results were obtained prior to the end of the emergency/urgent operation, and only three vascular emergency patients (7.3%) were positive for the virus. Few cases deemed 'non-transferable' by the THT were operated on in the spoke, but most patients were treated in the hub (Table 2).

## Emergency cases

Three COVID-19-positive patients were treated (7.3%) (Fig. 2). One man, over 80 years old, was accepted to our hub with critical lower limb ischaemia. He presented at the ER with left lower limb pain, functional impotence, thermal gradient and dry gangrene of the second toe of his left foot. After being hospitalized in the pink area and having a CT angiography scan of his lower limb performed, a distal superficial left femoral artery obstruction was found. Therapy with prostanoids, cardioaspirin and enoxaparin was started while waiting for the SARS-CoV-2 screening results. Anamnesis included superficial femoral and popliteal-tibial obstructing arteriopathy (already evaluated in another hospital last October), arterial hypertension, pulmonary disease, atrial fibrillation, Horton arteriopathy and a history of prostate cancer (treated with radiochemotherapy); he had a demanding chronic home therapy: apixaban, prednisone, irbesartan, fluticasone + vilanterol, pregabalin and buprenorphine. SARS-CoV-2 screening was positive. The CT scan revealed bilateral ground glass areas, and the results of the nasal swab were positive. The patient was hospitalized in the red area. After 3 days, a mediolateral femoral and popliteal artery percutaneous transluminal angioplasty was performed successfully. After the procedure, the patient was returned to the red area. Specific therapy with ritonavir/lopinavir and hydroxychloroquine was administered for the following 5 days. After significant pulmonary improvement on the CT scan, the patient was discharged for quarantine at home (in agreement with the family and local authorities) with



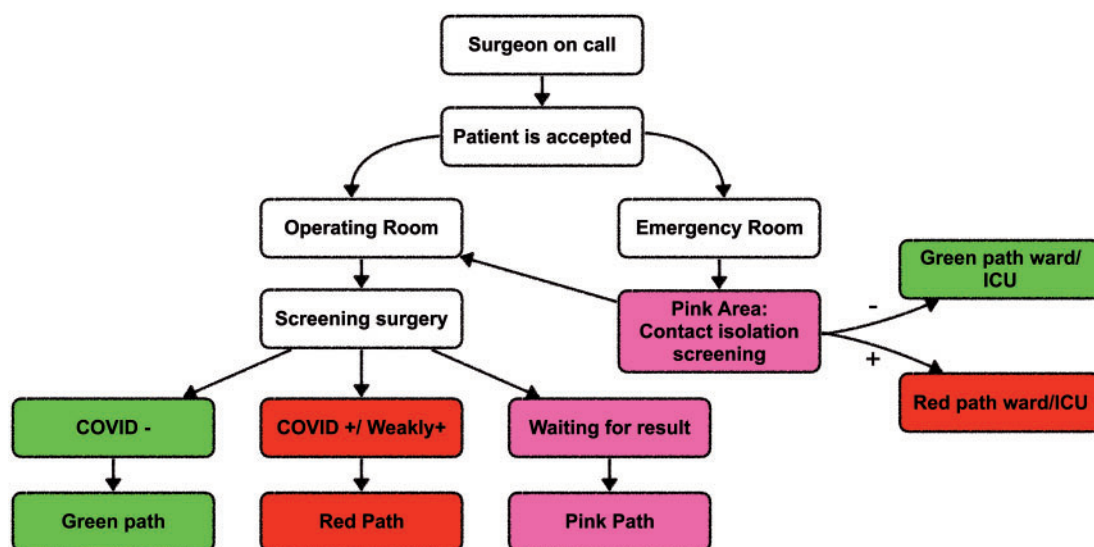


Figure 2: Flow chart for emergency and urgent cases. COVID: coronavirus disease; ICU: intensive care unit.

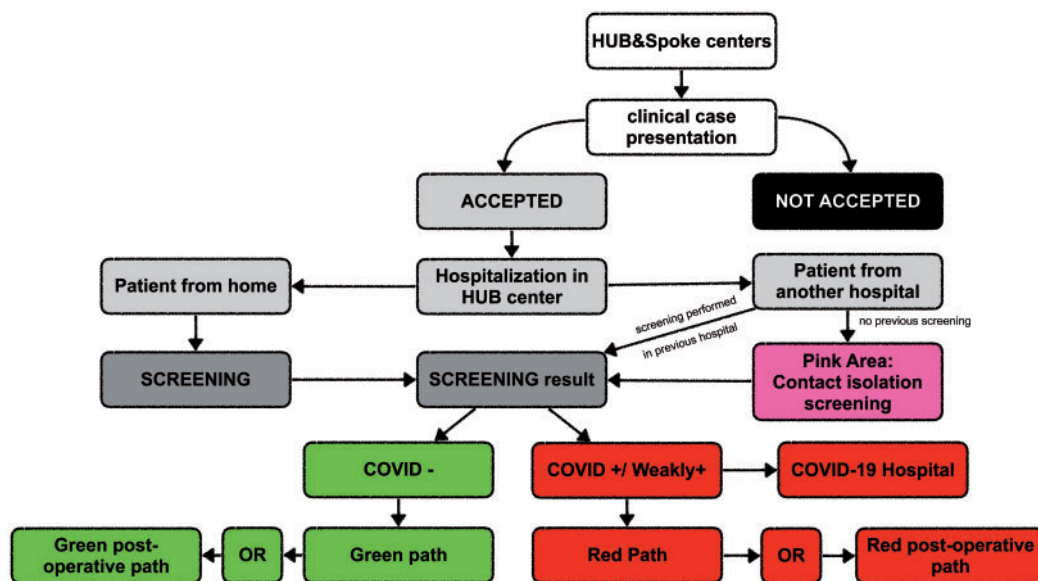


Figure 3: Flow chart for non-deferrable cases. COVID: coronavirus disease; OR: operating room.

pharmacological therapy consisting of apixaban, aspirin 100 mg and clopidogrel.

If the results of the screening for COVID-19 were negative, the emergency patient was treated in accordance with the shared protocols (Fig. 2). For example, a 60-year-old man with a recently implanted left ventricular assist device (LVAD) (Jarvik 2000, Jarvik Heart Inc., New York, NY, USA) for end stage heart failure presented at our hospital with dyspnoea, hum from the device and increase of energy consumption by the LVAD. After the COVID-19 screening result was negative, the patient was immediately hospitalized through the green path for treatment of a high suspicion of device thrombosis (despite anticoagulant and antithrombotic therapy and a correct international normalized ratio range). The diagnosis was confirmed by a transoesophageal echocardiogram, which showed a severe smoke-like effect in the left ventricle with serious flow reduction. The patient had an LVAD replacement through an anterior thoracotomy, using

cardiopulmonary bypass with a beating heart. Afterwards, the patient was transferred to the green area ICU. He is currently in the ICU; he has acute kidney failure, treated by continuous veno-venous haemofiltration, haemorrhagic stroke with left hemi-syndrome and difficulty being weaned from mechanical ventilation, which required a tracheostomy. He is constantly also monitored for COVID-19. The reason for the LVAD thrombosis is still under investigation due to the correct international normalized ratio and antiplatelet therapy observed. At present, concomitant infections are excluded.

### Non-deferrable cases

In the case of ND patients, the approach depends on general morbidity and frailty (Fig. 3). A man over 70 years old presented to the ER of the spoke hospital, complaining of dyspnoea and

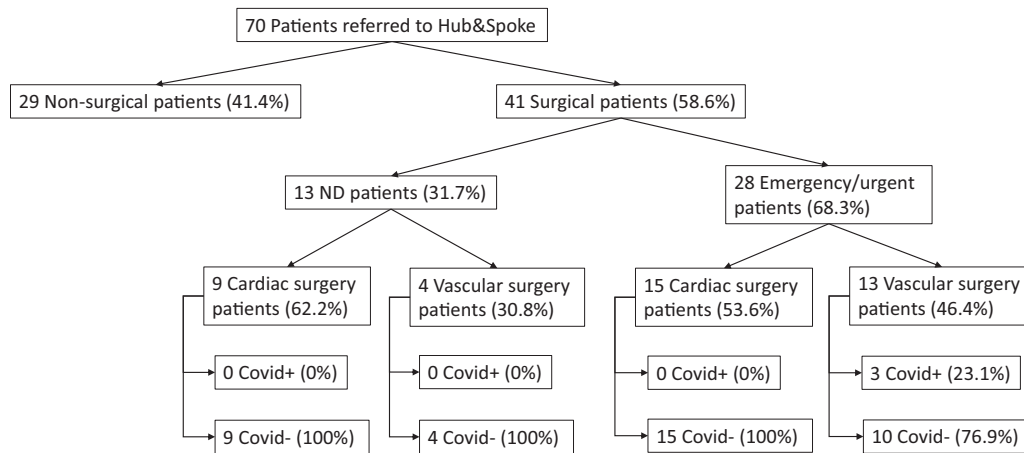


Figure 4: Patients referred to the hub-and-spoke system

Table 2: Operations performed at the spoke hospital

Type of procedure	Negative for COVID-19	Hospital	Diagnosis
Salvage procedure (7)	7 (100%)	Spoke	6 cardiac operations <ul style="list-style-type: none"> <li>• 2 unstable endocarditis</li> <li>• 2 heart ruptures</li> <li>• 1 acute mitral regurgitation after PTCA</li> <li>• 1 aortic rupture</li> </ul> 1 vascular operation <ul style="list-style-type: none"> <li>• Ruptured aortic abdominal aneurysm</li> </ul>
Heart transplant (1)	1 (100%)	Spoke	Catastrophic myocardial infarctions, unresponsive to PTCA and maximal mechanical support

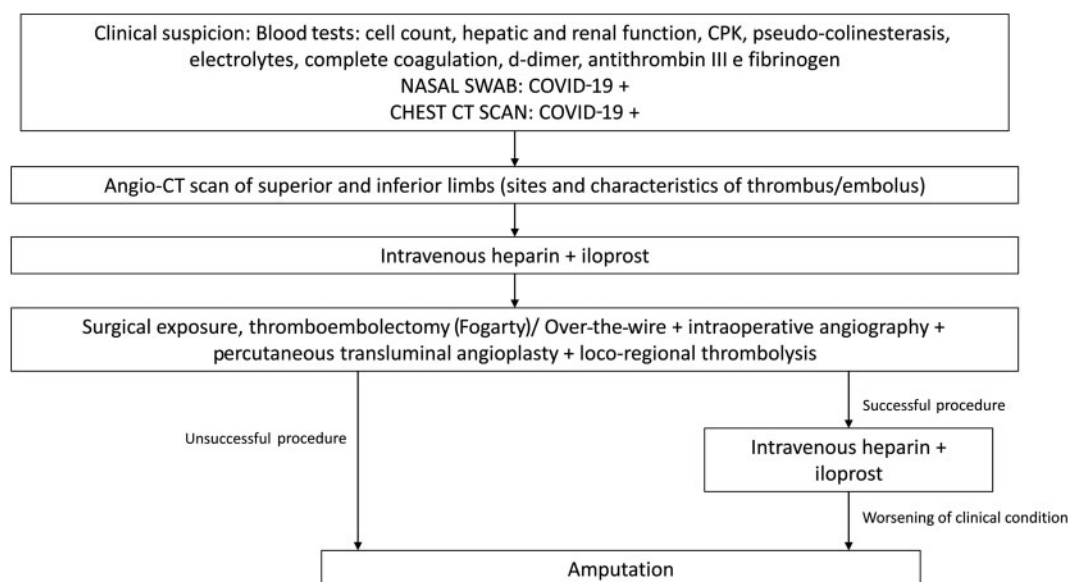
COVID-19: coronavirus disease 2019; PTCA: percutaneous transluminal coronary angioplasty.

night orthopnoea; he had a recent history of respiratory syndrome causing chest pain that was treated with antibiotic therapy. During hospitalization, he had a SARS-CoV-2 nasal swab screening (results were negative). The CT scan showed pleural effusion, pulmonary oedema, no COVID-19 pneumonia, an aortic root aneurysm (56 mm × 53 mm diameter) and subocclusive stenosis of the left internal carotid artery. The transthoracic echocardiogram (TTE) demonstrated severe aortic valve regurgitation, 30% ejection fraction and end-diastolic volume 180 ml. No severe stenosis was found on coronary angiography scans. The case was therefore discussed with our THT. The patient met the criteria to be classified as ND, so he was transferred from the spoke to the hub. He was accepted in the ER, had a second screening and was hospitalized in the pink area. Unfortunately, the result of the swab test was positive for COVID-19. Consequently, the patient was moved to the red area. Considering the recent respiratory syndrome and the positive COVID-19 screening result, the THT decided to transfer the patient back to the COVID-19 area of the spoke for appropriate medical care.

The pathway was slightly different for a patient who presented directly at the hub hospital (Fig. 3). He was a 55-year-old man, hospitalized in the pink area of the ER. He had chest pain that had started 30 min earlier that irradiated to the interscapular area and to the left arm. He had diabetes, an ascending aortic aneurysm and previous vascular correction of an isthmic aortic coarctation. An echocardiogram showed subendocardial ischaemia. The TTE showed severe aortic regurgitation and normal cardiac function. The chest CT scan showed a 3-mm increase in the known aortic root aneurysm, absence of critical coronary stenosis and no signs of COVID-19. The results of the nasal swab were negative. The patient was hospitalized in the coronary unit area of the green path and discussed in the THT, finally approved as ND. Three days later, he had a Bentall-De Bono procedure with the implant of an aortic biological prosthesis (29 mm) sutured to a 30-mm diameter aortic root Valsalva prosthesis using cardiopulmonary bypass. After the procedure he was transferred to the green area of the ICU; 3 days later he was readmitted to the green area of the ward. Due to new chest pain, he had a CT scan, diagnostic for right pulmonary artery thromboembolism (no haemodynamic instability on the TTE). Adequate therapy was introduced and after 5 days, following a CT scan (negative for disease progression), he was discharged.

## Deferrable cases

A young Asian woman with bicuspid aortic valve endocarditis had aortic valve replacement with a mechanical prosthesis. An aortic paravalvular leak was documented on a follow-up TTE. She reported only chest pain in the previous month and denied recent trips to China or contact with suspected COVID-19-positive cases. She was hospitalized in the ER. She had a CT scan (showed a pseudoaneurysm of a non-coronary sinus, no signs of SARS-CoV-2), a nasal swab (results negative for COVID-19), blood tests, an arterial blood gas test and a transoesophageal echocardiogram (confirmed the paravalvular leak). She spent a few days in the hospital because she was unsure about undergoing surgery. During the stay, she had a fever of 38°C (100.4°F); therefore, a second nasal swab and a second chest CT were performed. The results of the swab were positive and the CT scan showed a new, small suspected ground glass area in the right lung. The patient



**Figure 5:** Flow chart for treatment of acute limb ischaemia. COVID-19: coronavirus disease 2019; CPK: creatine phosphokinase; CT: computed tomography.

was immediately transferred to the red area and started dedicated pharmacological therapy with hydroxychloroquine together with lopinavir + ritonavir, an interrupted oral anticoagulant and enoxaparin. After THT discussion, to preserve the long-term prognosis of the patient and after being evaluated as 'not an emergency case', she was discharged to home to continue drug therapy. Her health status was monitored through the Monzino TeleCardiology System. The patient will be rediscussed after she recovers from COVID-19.

## DISCUSSION

As far as we know, we were the first European region to reorganize the cardiovascular surgery wards in reaction to the SARS-CoV-2 pandemic. Moreover, our reorganization has been supported by recently published indications from the Italian Society of Cardiovascular Surgery [17]. This reorganization was necessary to deal with the cardiovascular emergencies and to guarantee support to hospitals completely dedicated to COVID-19.

In addition to the need to separate patients who test positive from those who test negative for SARS-CoV-2, it is also important to identify the positive patients to offer them the best treatment. Patients who are positive for COVID-19 show some differences compared with standard cardiac surgery patients in the management of anaesthesia and intensive care, especially in the immediate postoperative period [20].

The outbreak forced us to rearrange our therapeutic protocols to deal with the novel discoveries regarding SARS-CoV-2, which seemed to interact with the coagulation cascade [21]. We noticed an increased number of patients with increased risk of thrombosis. Not only did patients with a known chronic peripheral arteriopathy suffer from acute ischaemia, but some healthy patients had completely obliterated peripheral arteries, causing an increase in patients coming to the ER. Vascular surgeons in Monzino, together with their colleagues from Brescia,

implemented a new shared protocol for treating patients with COVID-19 with acute limb ischaemia (Fig. 5). They combined surgical and pharmacological therapy using different doses and timing of intravenous heparin administration and intralesion thrombolysis, related to the higher risk of recurrences and worse clinical pictures showed by these patients [22]. The previously described emergency SARS-CoV-2-positive patient, despite long-term therapy with an oral anticoagulant, had acute ischaemia. Moreover, he also had long-term therapy with cortisone, currently part of COVID-19 therapy [23, 24], and irbesartan, even if its protective role is still being discussed [25, 26]. It is possible that his long-term therapy had a protective role with a milder course of the disease, despite the limb ischaemia.

This organizational structure allowed us to treat not only emergency/urgent patients, but also ND patients. We thereby avoided worsening of the clinical conditions of frail and morbid patients. The division into three different areas guaranteed protection for health care personnel and patients who had test results negative for COVID-19.

In our experience, only seven patients needed immediate salvage surgery at the spoke hospital, which rendered the COVID-19 status irrelevant compared to the patient's survival. One patient was transferred to the spoke hospital (transplant centre) to have a heart transplant. The spoke hospital had an ICU dedicated to transplant patients, therefore guaranteeing a COVID-19-free pathway.

Despite this well-defined pathway for cardiovascular emergencies, the number of patients presenting to our hospitals has been low. Official data are not yet available, but it seems that the Lombardy region recorded roughly a 60–80% reduction in emergency operations.

It is possible to speculate on this unexpected drop in cardiovascular emergencies. It might be that lockdown reduced stressful life situations and therefore reduced the hypertensive peaks that could lead to aortic dissection or myocardial infarction throughout the day.

A second possibility is that patients with cardiovascular issues may already have been hospitalized for COVID-19. We know that cardiovascular diseases dramatically worsened the prognosis of patients with COVID-19 and that eventually more of these patients would die of COVID-19 and that the deaths would be classified as COVID-19 deaths rather than as cardiovascular deaths.

Moreover, the reduced number of cardiac operations and cardiological procedures may have depended on the timing of presentation to the ER. The feeling, confirmed by physicians coming from other Italian regions, is that patients were afraid of contracting SARS-CoV-2 in the hospital. Therefore, even those patients whose symptoms were highly suggestive of cardiovascular conditions might have avoided the hospitals or might not have received immediate medical attention, because the rescue teams were extremely busy with the COVID-19 outbreak.

## CONCLUSIONS

The Italian COVID-19 outbreak strained the National Health System of Northern Italy, especially in Lombardy. The hub-and-spoke system was an effective way to face the pandemic and to guarantee efficient treatment and implementation of cardiac and vascular procedures.

As can happen during a war, the pandemic caused by COVID-19 totally changed our habits and lifestyle, reducing self-confidence. Contrary to a war scenario, we had to fight against an invisible and totally unknown enemy, more dangerous and more lethal. After experiencing feelings of surprise, discomfort and unpreparedness, we rearranged the hospital system, sharing technological tools and ideas. Like a real war cabinet, we held daily and weekly briefings. A THT was set up through digital platforms. While respecting privacy, we shared a huge amount of on-line imaging and clinical data. The on-duty and on-call shifts were completely rearranged, creating a mixed team including spoke and hub surgeons. The newly nominated hub-and-spoke committee urgently approved new temporary guidelines, flow charts, new serological and diagnostic tests and pharmacological and surgical treatments. To prevent a system failure, a 'COVID-19 backup shift' was created: A spare shift, in case of a sick surgeon, according to military reservists, is always 'ready for action'.

In a pandemic, the hub-and-spoke system is an effective way to guarantee access to cardiac and vascular surgical procedures. Further studies are needed to quantify the number of cardiovascular patients who died of SARS-CoV-2. At the end of the pandemic, with the resumption of elective procedures and a daily increase in surgical activities, further reorganization will be required.

## SUPPLEMENTARY MATERIAL

Supplementary material is available at *EJCTS* online.

**Conflict of interest:** none declared.

## Author contributions

**Giorgia Bonalumi:** Conceptualization; Methodology; Writing—original draft; Writing—review & editing. **Ilaria Giambuzzi:** Conceptualization;

Methodology; Writing—original draft; Writing—review & editing. **Alessandro Barbone:** Writing—original draft; Writing—review & editing. **Camilla Ranieri:** Methodology; Resources; Writing—review & editing. **Laura Cavallotti:** Writing—review & editing. **Piero Trabattoni:** Writing—review & editing. **Moreno Naliato:** Writing—review & editing. **Gianluca Polvani:** Writing—review & editing. **Lucia Torracca:** Writing—review & editing. **Stefano Pelenghi:** Writing—review & editing. **Claudio Francesco Russo:** Writing—review & editing. **Francisco Guerra:** Writing—review & editing. **Santi Trimarchi:** Writing—review & editing. **Efrem Civilini:** Writing—review & editing. **Federico Romani:** Writing—review & editing. **Raffaello Bellosta:** Writing—review & editing. **Franco Ragni:** Writing—review & editing. **Sergio Losa:** Writing—review & editing. **Maurizio Roberto:** Conceptualization; Project administration; Supervision; Validation; Visualization; Writing—review & editing. **Francesco Alamanni:** Conceptualization; Project administration; Supervision; Validation; Visualization; Writing—review & editing.

## REFERENCES

- [1] Zhu N, Zhang D, Wang W, Li X, Yang B, Song J *et al.* A novel coronavirus from patients with pneumonia in China, 2019. *N Engl J Med* 2020;382:727–33.
- [2] World Health Organization. Novel Coronavirus—China. 2020. <https://www.who.int/csr/don/12-january-2020-novel-coronavirus-china/en/> (20 April 2020, date last accessed)
- [3] Short KR, Kedzierska K, van de Sandt CE. Back to the future: lessons learned from the 1918 influenza pandemic. *Front Cell Infect Microbiol* 2018;8:343.
- [4] Ministero Della Salute, Italia. <http://www.salute.gov.it/portale/nuovocoronavirus/dettaglioContenutiNuovoCoronavirus.jsp?area=nuovoCoronavirus&id=5351&lingua=italiano&menu=vuoto> (20 April 2020, date last accessed)
- [5] Li X, Wang L, Yan S, Yang F, Xiang L, Zhu J *et al.* Clinical characteristics of 25 death cases with COVID-19: a retrospective review of medical records in a single medical center, Wuhan, China. *Int J Infect Dis* 2020;94:128–32.
- [6] Chan JF, Yuan S, Kok KH, To KK, Chu H, Yang J *et al.* A familial cluster of pneumonia associated with the 2019 novel coronavirus indicating person-to-person transmission: a study of a family cluster. *Lancet* 2020;395:514–23.
- [7] Chen N, Zhou M, Dong X, Qu J, Gong F, Han Y *et al.* Epidemiological and clinical characteristics of 99 cases of 2019 novel coronavirus pneumonia in Wuhan, China: a descriptive study. *Lancet* 2020;395:507–13.
- [8] Huang C, Wang Y, Li X, Ren L, Zhao J, Hu Y *et al.* Clinical features of patients infected with 2019 novel coronavirus in Wuhan, China. *Lancet* 2020;395:497–506.
- [9] Hamzelou J. Coronavirus spreads. *New Sci* 2020;245:8.
- [10] Lombardy Regional Council Ordinance (DGR) n° XI/2906. 2020. <https://www.regione.lombardia.it/wps/wcm/connect/5e0deec4-caca-409c-825b-25f781d8756c/DGR+2906+8+marzo+2020.pdf?MOD=AJPERES&CACHEID=ROOTWORKSPACE-5e0deec4-caca-409c-825b-25f781d8756c-n2.vCsc> (22 May 2020, date last accessed).
- [11] Elrod JK, Fortenberry JL Jr. The hub-and-spoke organization design revisited: a lifeline for rural hospitals *BMC. Health Serv Res* 2017;17(Suppl. 4):795.
- [12] Elrod JK, Fortenberry JL Jr. The hub-and-spoke organization design: an avenue for serving patients well. *BMC Health Serv Res* 2017;17(Suppl. 1):457
- [13] Marzegalli M, Fontana G, Sesana G, Grieco N, Lombardi F, Elena C *et al.* Cardiological emergency network in Lombardy. *G Ital Cardiol (Rome)* 2008;9(Suppl. 1):565–625.
- [14] Italian National Institute of Health. Report on COVID-19 Mortality. Italian National Health Institute. <https://www.epicentro.iss.it/coronavirus/> (20 April 2020, date last accessed).
- [15] Chieragato A, Volpi A, Gordini G, Ventura C, Barozzi M, Caspani MLR *et al.* How health service delivery guides the allocation of major trauma patients in the intensive care units of the inclusive (hub and spoke) trauma system of the Emilia Romagna Region (Italy). A cross-sectional study. *BMJ Open* 2017;7:e016415.
- [16] Kurihara H, Bisagni P, Faccincani R, Zago M. COVID-19 outbreak In Northern Italy viewpoint of the Milan area surgical community. *J Trauma Acute Care Surg* 2020;doi:10.1097/TA.0000000000002695.



- [17] Bonalumi G, di Mauro M, Garatti A, Barili F, Gerosa G, Parolari A *et al.* The COVID-19 outbreak and its impact on hospitals in Italy: the model of cardiac surgery. *Eur J Cardiothorac Surg* 2020;57:1025–8.
- [18] Ministero della salute, Italia, National Plan for Hospital Waiting List, 2019–2021. <http://www.salute.gov.it/portale/listeAttesa/dettaglioPubblicazioniListeAttesa.jsp?lingua=italiano&id=2824> (20 April 2020, date last accessed)
- [19] New EuroSCORE II. <http://euroscore.org> (20 April 2020, date last accessed).
- [20] He Y, Wei J, Bian J, Guo K, Lu J, Mei W *et al.* Chinese society of anesthesiology expert consensus on anesthetic management of cardiac surgical patients with suspected or confirmed coronavirus disease 2019. *Cardiothorac Vasc Anesth* 2020;34:1397–1401.
- [21] Yin S, Huang M, Li D, Tang N. Difference of coagulation features between severe pneumonia induced by SARS-CoV2 and non-SARS-CoV2. *J Thromb Thrombolysis* 2020; doi:10.1007/s11239-020-02105-8.
- [22] Tan CW, Low JGH, Wong WH, Chua YY, Goh SL, Ng HJ. Critically ill COVID-19 infected patients exhibit increased clot waveform analysis parameters consistent with hypercoagulability. *Am J Hematol* 2020; doi: 10.1002/ajh.25822.
- [23] Russell B, Moss C, George G, Santaolalla A, Cope A, Papa S *et al.* Associations between immune-suppressive and stimulating drugs and novel COVID-19—a systematic review of current evidence. *Ecancermedicallscience* 2020;14:1022.
- [24] Russell B, Moss C, Rigg A, Van Hemelrijck M. COVID-19 and treatment with NSAIDs and corticosteroids: should we be limiting their use in the clinical setting? *Ecancermedicallscience* 2020;14: 1023.
- [25] Meng J, Xiao G, Zhang J, He X, Ou M, Bi J *et al.* Renin-angiotensin system inhibitors improve the clinical outcomes of COVID-19 patients with hypertension. *Emerg Microbes Infect* 2020;9:757–60.
- [26] Danser AHJ, Epstein M, Batlle D. Renin-angiotensin system blockers and the COVID-19 pandemic: at present there is no evidence to abandon renin-angiotensin system blockers. *Hypertension* 2020;75: 1382–5.